

Case Report

Unilateral Choroidal Osteoma with Evidence of Choroidal Neovascularization Based on Ocular Coherence Tomography Angiography

Courtney M. Crawford¹, Okezie C. Igboeli^{2*}

¹Department of Ophthalmology, North Texas Retina Consultants, USA

²Department of Ophthalmology, Carl R. Darnall Army Medical Center, USA

***Corresponding author**

Okezie C. Igboeli, Department of Ophthalmology, Carl R. Darnall Army Medical Center, 36065 Santa Fe Drive, Fort Hood, TX 76544, USA, Tel: 254-288-8491; Fax: 254-286-7105; Email: Igboeli@gmail.com

Submitted: 02 November 2016

Accepted: 16 January 2017

Published: 18 January 2017

ISSN: 2333-6447

Copyright

© 2017 Igboeli et al.

OPEN ACCESS

Keywords

- Choroidal osteoma
- Choroidal neovascularization
- Anti-Vascular Endothelial Growth Factor

Abstract

Purpose: Choroidal osteoma is a rare tumor which features intraocular bone formation. This tumor can be complicated by choroidal neovascularization which is a cause of impaired vision in this condition. We present a case of choroidal osteoma with choroidal neovascularization as a complication.

Methods: Case report with clinical and angiographic correlation.

Results: A 16 year old female presented with a choroidal osteoma in the left eye complicated by choroidal neovascularization. The patient was treated with Bevacizumab; an intravitreal anti-Vascular Endothelial Growth Factor (Anti-VEGF). Following treatment there was improvement in vision as well as resolution of the choroidal neovascular membrane.

Conclusion: We present a case of choroidal osteoma with choroidal neovascular membranes. Subfoveal choroidal neovascularization (CNV) associated with choroidal osteoma may be safely treated with bevacizumab. Larger studies are required to fully evaluate the management and long-term outcomes of anti-VEGF therapy for CNV associated with choroidal osteoma.

Disclosures: The authors have no financial or proprietary disclosures or conflict of interest with this submission. The views expressed in this submission do not reflect the views, opinions, or policies of the Army or any branch of the Department of Defense.

INTRODUCTION

Choroidal osteoma is a rare tumor associated with intraocular bone formation. It is often an incidental finding on routine examination but can also present as a cause of decreased vision. We present the case of a young female with a choroidal osteoma as well as brief review of the literature with regards to the evaluation and management of choroidal osteomas.

CASE PRESENTATION

A 16 year old female presented to the New England Eye Center with a chief complaint of decreased vision and metamorphopsia in the left eye. The symptoms started three months prior to presentation and remained unchanged from onset. There were no other visual complaints at the time of presentation. She denied

any prior ocular history; this was her first eye exam. On review of systems, there was no history of recent or chronic illness such as diabetes mellitus, no steroid use, no recent medication use, no prior eye disease, and no prior history of surgery. The patient also denied any family history of significant vision loss or eye pathology.

Initial work up began with a comprehensive examination of both eyes. Her visual acuity was 20/20 OD, and 20/25-2 OS. Intraocular pressure was measured as 14 OU. Anterior segment exam was unremarkable in both eyes. Dilated fundus examination of the right eye was unremarkable. In the left eye, dilated fundus examination revealed an amelanotic choroidal lesion encompassing the macula with overlying pigment changes at the level of the retinal pigmented epithelium (RPE). Intraretinal

hemorrhage and subretinal fluid were observed in the inferior macula (Figure 1).

Ancillary testing to include optical coherence tomography (OCT), intravenous fluorescein angiography, Indocyanine green (ICG) chorioangiography and B-scan ultrasonography were performed. Intravenous fluorescein angiography (to include autofluorescence) was unremarkable in the right eye but showed a pattern of spickled hyperfluorescence in the left eye (Figure 2). ICG angiography showed early hypofluorescence intermixed with areas of hyperfluorescence (Figure 3). OCT showed distortion of the choroidal anatomy and subretinal fluid in a juxtafoveal location (Figure 4). Ultrasonography revealed high reflectivity of the lesion with shadowing beyond lesion (Figure 5). The differential diagnosis for yellow or amelanotic choroidal lesions includes Choroidal osteomas; Amelanotic Melanoma (usually seen in middle-aged or older patients without any sex predilection as compared to choroidal osteomas which are typically seen in young females. There is also typically more elevation with less well defined margins with a choroidal melanoma) [1]; Circumscribed choroidal hemangioma (may have overlying fibrous metaplasia, but typically dome-shaped with smooth margins and cystoid changes of the retina) [1]; Choroidal Metastasis (indistinct margins, often associated with serous retinal detachments) [1]; Disciform scar in Age-Related Macular Degeneration (usually more centered in the macula and less commonly juxtapapillary in location) [1]; and sclerochoroidal calcification (usually in older adults, this is a yellow-white choroidal lesion seen typically in the superotemporal or inferotemporal mid-periphery) [2]; This is not an all-inclusive list but includes some of the conditions considered.

Following the evaluation, a diagnosis of choroidal osteoma was made. The diagnosis as well as the natural history of the disease was discussed with the patient. She elected to proceed with observation and scheduled a one month follow up visit.

The patient did not follow up until 2 months after her initial presentation. She now had a complaint of increasing loss of vision and worsening metamorphopsia in the left eye. These symptoms were causing difficulty with reading. Her visual acuity was now 20/40-1 in the left eye. Repeat dilated fundus examination showed increased subretinal fluid in the left eye. A repeat fluorescein angiography was performed (Figure 6) and was concerning for increased leakage compared to the prior exam. Optical coherence tomography angiography was performed and showed a choroidal neovascular membrane (Figure 7).

Given the presence of a choroidal neovascular membrane, the decision was made to initiate anti-vascular endothelial growth factor (anti-VEGF) therapy with 0.5mg of intravitreal bevacizumab. The patient was given an intravitreal injection of bevacizumab as the first of 3 monthly injections. One month later, she had gained one line of vision and was now 20/30 from 20/40-1 at her previous visit. On exam, there was a new area of intraretinal hemorrhage noted on the inferior aspect of the lesion. The second injection of intravitreal bevacizumab was given and she scheduled another one month follow up visit. The following month, her vision was retained at 20/30. There was no new intraretinal hemorrhage on exam. She received the third intravitreal injection and followed up one month later. By this time, the choroidal neovascular membrane had resolved.

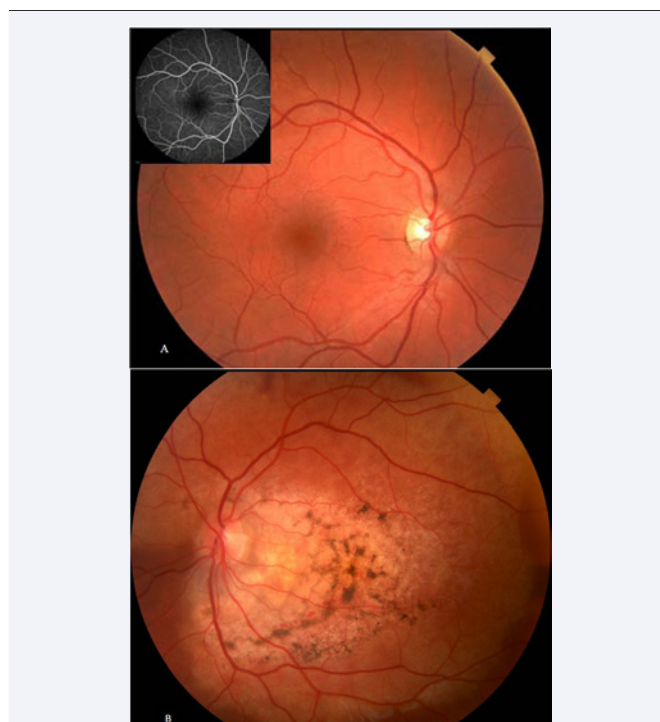

Figure 1 Fundus Photos. The right eye (A) is unremarkable with inset showing unremarkable fluorescein angiogram of the same eye. The left eye (B) shows a Yellow/amelanotic Choroidal lesion with overlying retinal pigment epithelium (RPE) pigment changes encompassing the macula with intraretinal hemorrhage and subretinal fluid in the inferior macula.

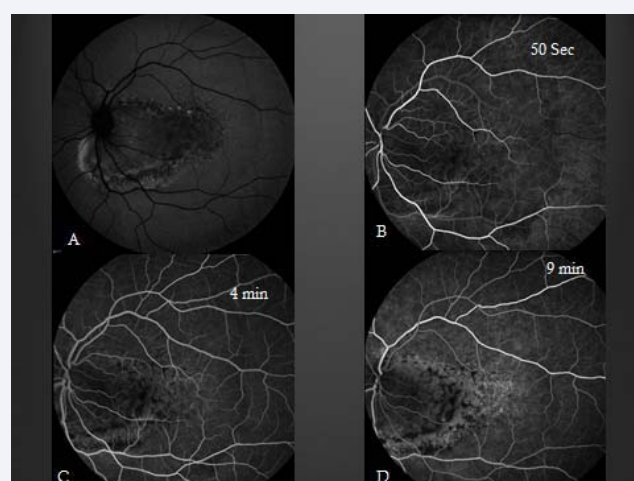

Figure 2 Fluorescein angiography of the left eye; Red free (A) showing hyper-autofluorescence intermixed with hypo-autofluorescence. Early (B), mid-phase (C), and late phase (D) of intravenous fluorescein angiography showing spickled hyperfluorescence with late staining in areas of thinned RPE.

DISCUSSION

Choroidal osteomas are predominately found in the juxtapapillary and macular region of young women (90%), in the second and third decades of life [1]. They are typically

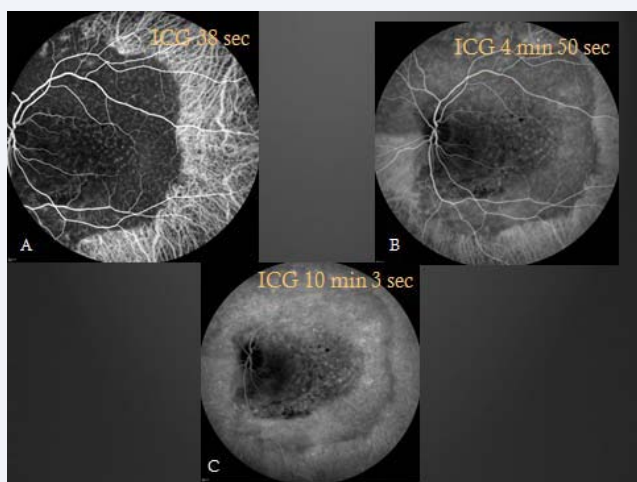


Figure 3 Indocyanine green angiography images showing early hypofluorescence (A) in areas of the lesion with hyperfluorescence of intralésional vessels. The Mid-phase (B) also reveals hypofluorescence with hyperfluorescence of intralésional vessels. Late in the study (C), there is persistent hypofluorescence albeit less pronounced.

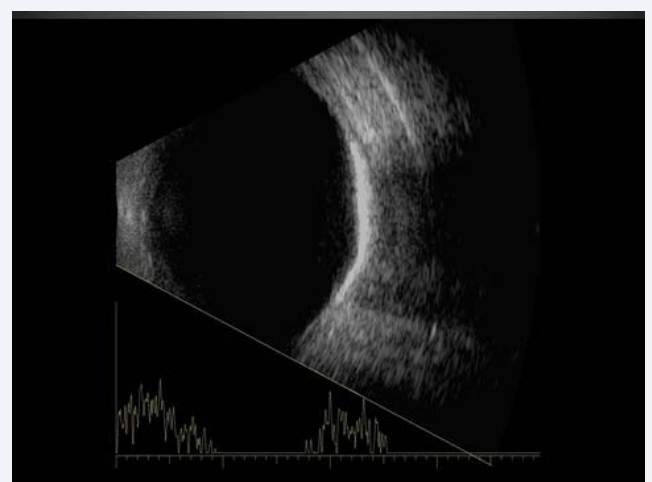


Figure 5 B-scan ultrasonography showing high reflectivity of the lesion with shadowing beyond the lesion.

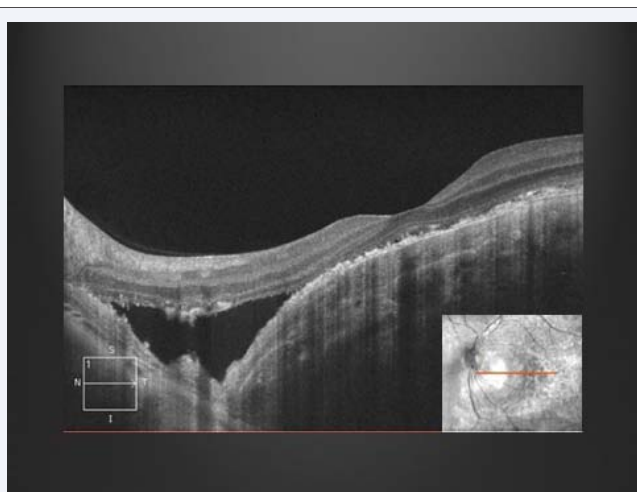


Figure 4 Optical coherence tomography shows distortion of the choroidal anatomy and subretinal fluid.

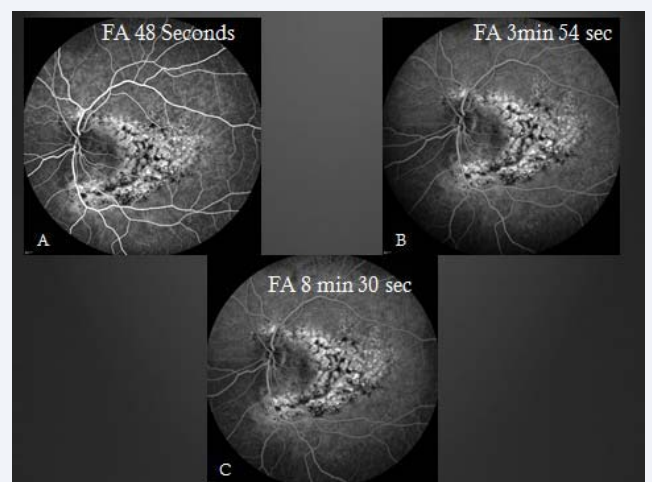


Figure 6 Repeat fluorescein angiography; A similar pattern is seen in early (A), mid-phase (B) and late in the study revealing hyperfluorescence in areas of thinned retinal pigment epithelium and late staining. There is notably increased hyperfluorescence compared to her prior study (Figure 2).

found in otherwise healthy eyes in sharp contrast to other eyes in which bone formation may be found: Phthisis bulbi and cyclitic membranes. They generally occur sporadically with only a few cases of familial choroidal osteomas in the literature [3]. Choroidal osteomas are unilateral 75% of the time [1]. They may be asymptomatic, or may cause visual symptoms such as blurring of vision, metamorphopsia, or visual field defects corresponding to the tumor location [1]. Tumor growth was reported in 41% of 22 cases over 10 years [4] and size ranges have been reported as anywhere from 2-22mm in basal dimension and 0.5-2.5mm in elevation [4]. Decalcification of the tumor may occur spontaneously or may be induced by laser treatment and the rate of partial or complete decalcification is reported as 28% of choroidal osteomas by 5 years and 46% at 10 years [5].

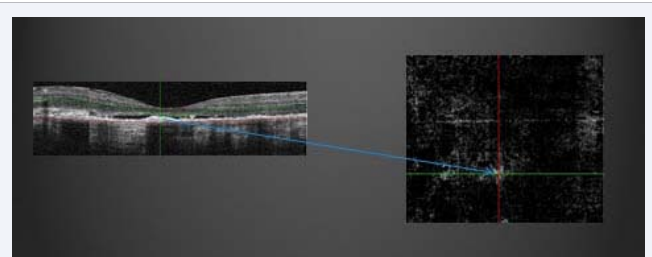


Figure 7 Optical coherence tomography angiography showing choroidal neovascular membrane and corresponding location on OCT.

Choroidal neovascularization (CNV) has been noted in association with choroidal osteomas and is a known cause of late decreased vision [1]. The typical presentation is a complaint

of new metamorphopsia or scotoma and a finding of serous or hemorrhagic detachment of the macula is not uncommon. One study found a CNV rate of 22% at 5 years and 51% at 10 years [6] while another study reported a rate of 31% at 5 years, 47% at 10 years and 56% at 20 years [4]. The exact etiology or pathogenesis of CNV in choroidal osteomas remains unclear.

CNV associated with choroidal osteomas is often an indication for treatment due in part to the high association of CNV with decreased vision. Reasons for decreased vision in CNV include subretinal fluid, subretinal hemorrhage, retinal pigment epithelium atrophy and/or photoreceptor atrophy. Some of the treatment modalities previously employed in the treatment of CNV associated with choroidal osteomas include argon laser photocoagulation [7,8], transpupillary thermotherapy (TTT) [9], and photodynamic therapy (PDT) [10,11]. Surgical evacuation of the choroidal neovascular membrane has been reported [12] but the visual outcome was not favorable. More recently, anti-VEGF agents have become the mainstay in the treatment of choroidal neovascularization associated with various diseases such as age-related macular degeneration, diabetic retinopathy, presumed ocular histoplasmosis syndrome, high myopia, and choroidal osteomas. No large clinical trials have evaluated the use of anti-VEGF for choroidal neovascularization associated with choroidal osteomas; however, a number of case studies have published their findings and have reported improved vision and resolution of CNV.

Our patient gained a line of vision after the first treatment and retained her vision throughout the course of the treatment. At the time of this publication, the patient had been followed for a little over 12 months and retained visual acuity of 20/30 in the left eye and did not develop any new choroidal neovascularization. She did not enjoy the dramatic improvements in vision seen in some prior reports on the use of bevacizumab in the treatment of choroidal osteoma-related CNV. One study showed an improvement in VA from CF at 1.5 meters to 20/125 following 2 treatments of monthly injections of intravitreal bevacizumab (0.5mg) with resolution of the neovascular membrane [13]. Another study showed improvement of VA from 20/125 to 20/25 with regression of the neovascular membrane 6 weeks following one treatment with intravitreal bevacizumab [14]. A point worth noting is the fact that our patient's presenting visual acuity was not as severely affected as some of the patients in referenced studies. Treatment with ranibizumab has also been reported [15] with improvement in vision and resolution of the neovascular membrane.

Choroidal osteoma is a well-studied rare tumor of the choroid which may be asymptomatic or may lead to impaired vision in some cases. Choroidal neovascularization associated with choroidal osteoma is also well known and can be managed with anti-VEGF agents. Our patient's response to therapy is consistent with the existing reports on the use of anti-VEGF for

the management of CNV in choroidal osteoma. Larger and more robust studies are needed to fully evaluate the use of anti-VEGF in the management of choroidal osteoma-related CNV and to record long-term results, adverse effects if any, and to standardize the treatment regimen if possible.

REFERENCES

1. Shields CL, Shields JA, Augsburger JJ. Choroidal Osteoma. *Surv Ophthalmol*. 1988; 33: 17-27.
2. Kanski JJ, Bowling B. *Clinical Ophthalmology: A Systematic Approach*, 7th ed. Elsevier, New York. 2011.
3. Noble KG. Bilateral choroidal osteoma in three siblings. *Am J Ophthalmol*. 1990; 109: 656-660.
4. Aylward GW, Chang TS, Pautler SE, Gass JD. A long-term follow-up of choroidal osteoma. *Arch Ophthalmol*. 1988; 116: 1337-1341.
5. Trimble SN, Schatz H. Decalcification of a choroidal osteoma. *Br J Ophthalmol*. 1991; 75: 61-63.
6. Shields CL, Sun H, Demirci H, Shields JA. Factors predictive of tumor growth, tumor decalcification, choroidal neovascularization, and visual outcome in 74 eyes with choroidal osteoma. *Arch Ophthalmol*. 2005; 123: 1658-1666.
7. Grand MG, Burgess DB, Singerman LJ, Ramsey J. Choroidal osteoma. Treatment of associated subretinal neovascular membranes. *Retina*. 1984; 4: 84-89.
8. Gurelik G, Lonzeville Y, Safak N, Ozdek SC, Hasanreisoglu B. A case of choroidal osteoma with subsequent laser induced decalcification. *Int Ophthalmol*. 2001; 24: 41-43.
9. Shukla D, Tanawade RG, Ramasamy K. Transpupillary thermotherapy for subfoveal choroidal neovascular membrane in choroidal osteoma. *Eye (Lond)*. 2006; 20: 845-847.
10. Singh AD, Talbot JF, Rundle PA, Rennie IG. Choroidal neovascularization secondary to choroidal osteoma: Successful treatment with photodynamic therapy. *Eye (Lond)*. 2005; 19: 482-484.
11. Blaise P, Duchateau E, Comhaire Y, Rakic JM. Improvement of visual acuity after photodynamic therapy for choroidal neovascularization in choroidal osteoma. *Acta Ophthalmol Scand*. 2005; 83: 515-516.
12. Foster BS, Fernandez-Suntay JP, Dryja TP, Jakobiec FA, D'Amico DJ. Clinicopathologic reports, case reports, and small case series: Surgical removal and histopathologic findings of a subfoveal neovascular membrane associated with choroidal osteoma. *Arch Ophthalmol*. 2003; 121: 273-276.
13. Narayanan R, Shah VA. Intravitreal bevacizumab in the management of choroidal neovascular membrane secondary to choroidal osteoma. *Eur J Ophthalmol*. 2008; 18: 466-468.
14. Ahmadieh H, Vafi N. Dramatic response of choroidal neovascularization associated with choroidal osteoma to the intravitreal injection of bevacizumab (avastin). *Graefes Arch Clin Exp Ophthalmol*. 2007; 245: 1731-1733.
15. Song MH, Roh YJ. Intravitreal ranibizumab in a patient with choroidal neovascularization secondary to choroidal osteoma. *Eye (Lond)*. 2009; 23: 1745-1746.

Cite this article

Crawford CM, Igboeli OC (2017) Unilateral Choroidal Osteoma with Evidence of Choroidal Neovascularization Based on Ocular Coherence Tomography Angiography. *JSM Ophthalmol* 5(1): 1049.