

## Case Report

# Acute Visual Loss Secondary to Choriocapillaries Occlusion at the Time of Intravitreal Bevacizumab Injection for Age Related Macular Degeneration with Exacerbation of Kidney Disease: Case Report

Arwa Azmeh\*

Department of ophthalmology, Damascus University, Syria

## \*Corresponding author

Azmeh A, Department of ophthalmology, Damascus University, Almuassat University Hospital, Mazzeh Square, Damascus, Syria, Tel: 963-944-363703; Email: arwarefina@gmail.com

Submitted: 30 March 2017

Accepted: 26 June 2017

Published: 28 June 2017

ISSN: 2333-6447

## Copyright

© 2017 Azmeh

## OPEN ACCESS

## Keywords

- Choriocapillaries occlusion
- Kidney disease
- Acute visual loss
- Intravitreal bevacizumab
- Age related macular degeneration

## Abstract

**Aim:** To report a case of acute visual loss at the time of intravitreal bevacizumab injection, with exacerbation of chronic kidney disease

**Methods:** A 79 –years- old male, had acute visual loss to hand motion HM immediately at the time of intravitreal bevacizumab injection for age related macular degeneration AMD, which progressed to no light perception NLP one hour later. Intraocular pressure measurements IOP and fundus examinations were done at the time of injection, 1 hour, 1 day, 1 week and 1 month post injection. Carotid Doppler imaging CDI was performed 1 day post injection. B scan ultrasonography and OCT were done at follow-ups.

**Results:** Patient's IOP was normal at the time of injection, 1 hour, 1 day, 1 week and 1 month post injection, with continued perfusion of central retinal artery CRA and normal appearance of optic disc. At 1 day post injection retinal and subretinal hemorrhages around posterior pole were noticed, with exudative macular detachment. 1 week later macular detachment resolved and at 1 month macula became extensively atrophic. Final visual acuity was NLP. CDI revealed atherosclerotic changes on both sides. 1 month post injection patient had an acute attack of chronic kidney failure.

**Discussion:** Visual loss was thought to be caused by choriocapillaries occlusion secondary to intravitreal bevacizumab. Exacerbation of chronic kidney disease was caused by reduction in systemic VEGF levels post intravitreal bevacizumab.

**Conclusion:** Possible effects of intravitreal bevacizumab on systemic, retrobulbar and ocular circulation should always be kept in mind when facing unexplained acute visual loss post injection.

## ABBREVIATIONS

HM: Hand Motion; NLP: No Light Perception; AMD: Age Related Macular Degeneration; CDI: Carotid Doppler Imaging; IOP: Intraocular Pressure; OCT: Ocular Coherence Tomography; FA: Fluorescein Angiography; ICG: Indocyanine Angiography; CRA: Central Retinal Artery; VEGF: Vascular Endothelial Growth Factor; ATE: Arterial Thromboembolic Events; COPD: Chronic Obstructive Pulmonary Disease; BRVO: Branch Retinal Vein Occlusion; LE: Left Eye; CF: Counting Fingers; VA: Visual Acuity; OR: Operating Room; WBC: White Blood Count; MRA: Magnetic Resonance Angiography; CRAO: Central Retinal Artery Occlusion; AION: Anterior Ischemic Optic Neuropathy; OIS: Ocular Ischemic Syndrome; PCA: Posterior Ciliary Arteries; OA: Ophthalmic Artery; RI: Resistant Index; CDI: Color Doppler Imaging; BFV: Blood Flow Velocity

## INTRODUCTION

Several vascular adverse events have been reported with systemic intravenous administration of bevacizumab for treatment of solid cancers including arterial thromboembolic events (ATE), myocardial infarction, stroke, hypertension, gastrointestinal perforations, and kidney disease [1-4]. These observations have been extended to patients receiving intravitreal VEGF inhibitors for treatment of age related macular degeneration AMD and retinal vascular diseases [5].

We are reporting a case of acute painless visual loss, which we thought it was secondary to choriocapillaries occlusion at the time of intravitreal bevacizumab injection for AMD with exacerbation of chronic kidney disease.

## CASE PRESENTATION

A 79 years old patient has systemic hypertension and chronic pulmonary obstructive disease COPD since long time. He uses oxygen mask for at least 8 hours daily at home and he has chronic cough. He is not diabetic. He is known to have exudative AMD in right eye RE since year 2008 treated with intravitreal bevacizumab on as needed basis (total of 10 injections) with no previous complications. This eye has history of old infero-temporal branch retinal vein occlusion BRVO with collaterals since year 2000.

Left eye LE has cicatricial AMD since 2005 with visual acuity VA of counting fingers CF 1m. He is pseudophakic in both eyes.

Before last injection patient's best corrected visual acuity was 20/40 in RE. Due to the appearance of new subfoveal and juxtafoveal large intraretinal cystoid spaces on OCT we decided to give an additional intravitreal bevacizumab injection in RE.

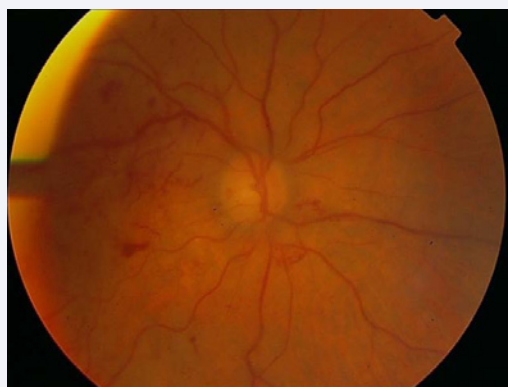1.25 mg intravitreal bevacizumab was injected in RE (in Feb 2016) in the usual sterile manner in the operating room OR. As our routine, the eye was massaged immediately after injection and was felt to be soft with no transit elevation in intraocular pressure IOP. But immediately after injection while the patient was still in the OR, VA in RE dropped to hand motion HM. Indirect fundus examination of RE revealed clear fundus view with normal retinal vasculature and normal appearance optic disc. IOP was measured, it was 15 mmHg. We thought that this drop in VA might be due to prolonged light adaptation after being exposed to the microscope light. One hour later VA in RE dropped to no light perception NLP in spite of normal IOP (14 mmHg) and perfused retinal vessels and absence of optic disc changes.

On examination the next day post injection, VA was still NLP in RE. The patient has no pain, no redness of the eye. IOP was 16mmHg. Both pupils were equal and not dilated. Anterior segment was quiet. REfundus examination revealed the following: Optic disc appeared normal in color and contour; retinal veins and arteries were perfused; old collateral vessels in the detached macula and inferior to optic disc were seen; the retina was not pale with no signs of cherry red spot and the vitreous was clear with no signs of inflammation. A localized exudative high macular detachment was seen involving macula and the area of the superior arcade with no retinal holes or tears. Peripheral retina was completely attached in all four quadrants. Few retinal and subretinal hemorrhages were seen in the detached retina, which were not noticed on the day of injection (Figures 1,2). B scan ultrasonography revealed localized serous macular detachment with attached peripheral retina (Figure 3).

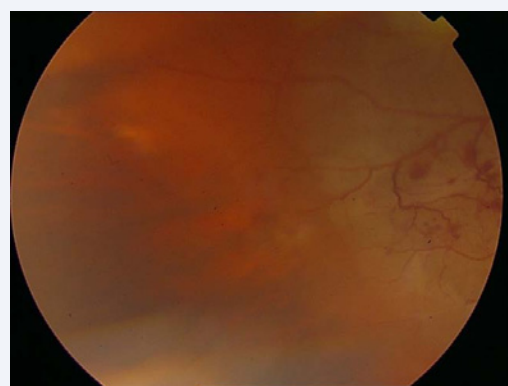
Carotid Doppler imaging CDI was done. It revealed atherosclerotic changes with no partial or complete obstruction in both sides

Fluorescein angiography FA and Indocyanine angiography ICG were ordered to evaluate the retinal and choroidal circulation, in addition to magnetic resonance angiography MRA to evaluate the retrobulbar vascular system.

1 week post injection the patient's VA was still NLP in RE. His right pupil was not dilated, but slightly larger than the left pupil and seemed to be not reactive to direct light. Anterior segment



**Figure 1** Color fundus photograph of right eye 1 day post injection showing normal optic disc and perfused retinal vessels with few retinal hemorrhages in posterior pole.

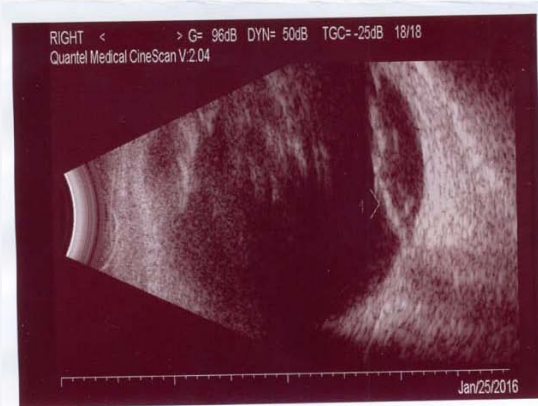
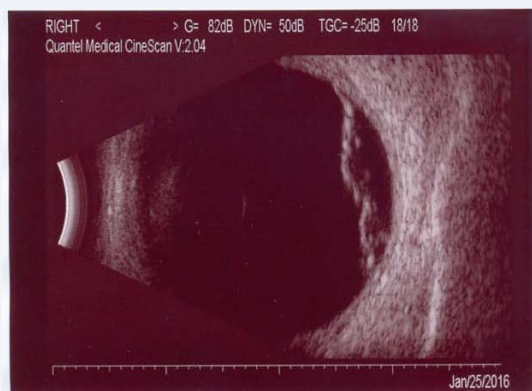
**Figure 2** Color fundus photograph of right eye 1 day post injection showing borders between temporal detached macula and attached retina. Note old temporal macular collaterals.

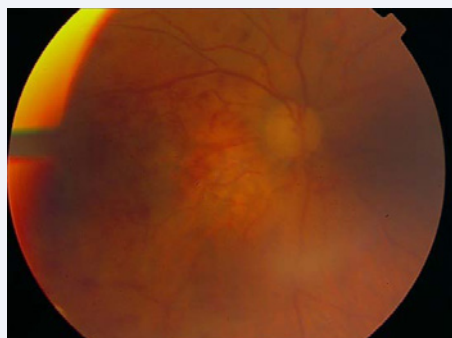
was quiet with normal IOP (16 mmHg). Vitreous was clear and fundus was seen clearly: Optic disc normal in color and contour as before. Retinal arteries and veins were perfused with significant regression of macular detachment and more obvious scattered subretinal and intraretinal hemorrhages around the posterior pole (Figure 4).

OCT revealed significant improvement of macular detachment with no retinal thickening or infarction (Figure 5). B scan ultrasonography showed nearly total regression of macular detachment with clear vitreous (Figure 6). The patient refused to have the ordered FA, ICG and MRA done due to his psychological fears.

1 month Post-injection the patient came complaining of urinary tract infection (E.Coli) causing hematuria. He can't pass his urine and is using urinary catheter. He has severe general weakness (the patient can't walk and is lying all time in bed). He has no appetite. He is not comfortable with breathing and he is now using oxygen mask all the time. He has fallen down few days ago and broke his scapular acromion. He has anemia with reduced hemoglobin and normal white blood count WBC and platelets Pl count. His blood urea and creatinine were elevated (227 mg/L, 3.7 mg/dl respectively).



**Figure 3** B scan ultrasonography of right eye 1 day post injection. (Upper photo) localized macular retinal detachment, (Lower photo) macular detachment extending to optic disc.



**Figure 4** Color fundus photograph of right eye 1 week post injection, showing no change in optic disc and retinal vessels with more obvious subretinal and intraretinal hemorrhages in posterior pole after regression of macular detachment.

His eye exam revealed that VA in RE was still NLP. Pupil was not dilated. IOP was 16 mmHg. RE fundus examination revealed that optic disc appearance was as previous exams with perfused retinal vessels. Retinal and subretinal hemorrhages were still there (Figure 7), exudative macular detachment totally resolved, and the macula looked very atrophic (Figure 8). OCT confirmed the severe retinal and choroidal atrophy (Figure 9). B scan

ultrasonography revealed no macular detachment (Figure10). A nephrologist was consulted and a diagnosis of acute attack of chronic kidney failure was established after thorough work out.

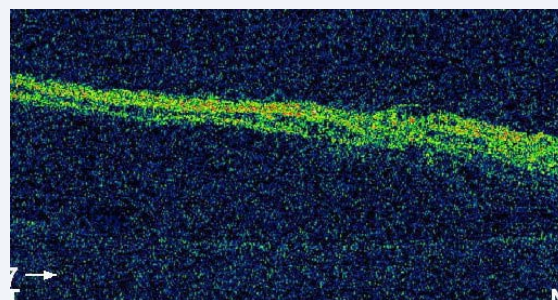
## DISCUSSION

Intravitreal anti-vascular endothelial growth factor (VEGF) agents were found to transit rapidly into the bloodstream after administration [6,7]. These agents are very potent, and there are several lines of evidence that imply that these small doses could potentially have vascular ocular and systemic adverse effects [8] and cause injury in organs that are reliant on VEGF, such as the kidney [9].

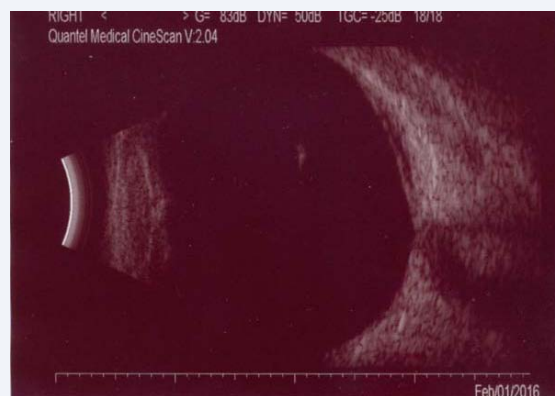Taking in consideration that VEGF has a protective and a regenerative effect on endothelial cells [10,11], these vascular ocular and systemic side-effects, are related to the inhibition of vascular endothelial growth factor [3,12-14].

Several studies in AMD patients on retrobulbar blood flow in posterior ciliary arteries (PCA), central retinal artery (CRA) and ophthalmic artery (OA) using color Doppler imaging (CDI) confirmed the effect of intravitreal bevacizumab on decreasing the blood flow in PCA in the early post injection period starting from 1 day till 4 weeks post injection [15-17].

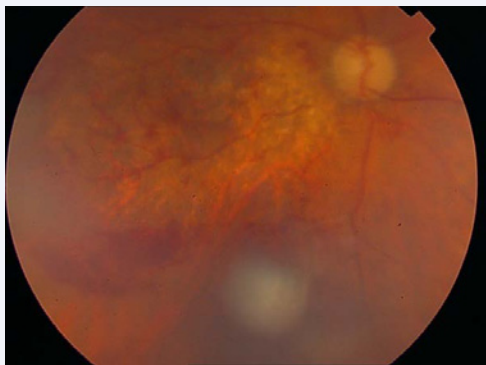
As an anti-VEGF, bevacizumab may induce arterial



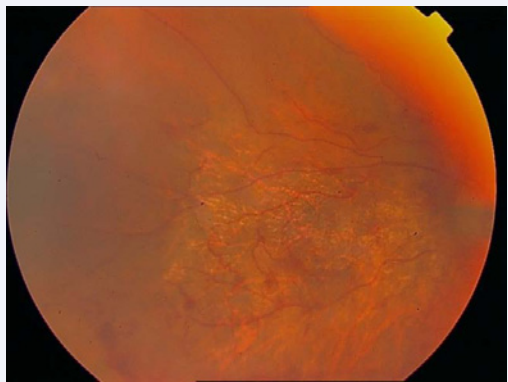
**Figure 5** OCT of right eye 1 week post injection showing improvement of macular detachment with less subretinal fluid and no retinal thickening. RPE layer appears as a very thin line in the lower part of the photo.



**Figure 6** Bscan ultrasonography of right eye 1 week post injection. Nearly total regression of macular detachment with residual small amount of subretinal fluid in macula.



**Figure 7** Color fundus photograph of right eye 1 month post injection showing that retinal and subretinal hemorrhages were still there with no change in optic disc and retinal vessels appearance.



**Figure 8** Color fundus photograph of right eye 1 month post injection showing extensive atrophy in macula after macular detachment has totally resolved.

thromboembolism by exposing subendothelial procoagulant phospholipids, by inhibiting VEGF-induced endothelial regeneration [13], and by reducing the production of nitric oxide and prostacyclin, thus predisposing to thromboembolic events [12]. This may lead to thrombus formation and occlusion of choriocapillaries lumen and decrease in blood flow velocities with increase in resistant index RI of choroidal vessels

Furthermore bevacizumab may reduce the number of fenestrations in normal choriocapillaries in rat eyes [18]. This reduction may be the reason for increased resistance to blood flow on CDI noticed as increased RI and decreased blood flow velocity BFV of PCA.

Peters et al. [19], studied ultrastructural effects of intravitreal bevacizumab in the primate eye, and found significant changes in the choriocapillaries as early as 24 hours after injection which normalized or partly normalized at day 14.

Our patient had immediate acute visual loss to HM at the time of intravitreal bevacizumab injection, which progressed to NLP one hour later post injection. His IOP was not elevated at the time of injection, 1 hour and 1 day post injection (15mmHg, 14mmHg, 16mmHg respectively) with continued perfusion of central retinal

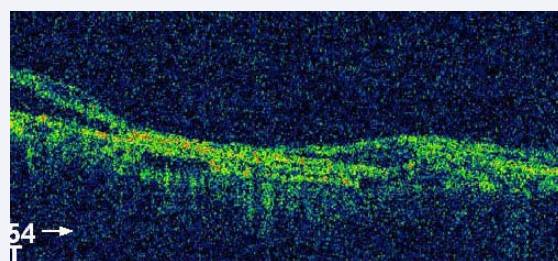
artery at all intervals. Also Optic disc remained non edematous and was not pale at all intervals. So visual loss was not caused by IOP elevation or central retinal artery occlusion CRAO or anterior ischemic optic neuropathy AION.

The first day post injection VA remained NLP and we noticed the presence of many retinal and subretinal hemorrhages around posterior pole not extending to the periphery (hemorrhages were not present on the day of injection). These hemorrhages were accompanied by localized exudative high macular detachment confirmed by OCT and B scan ultrasonography.

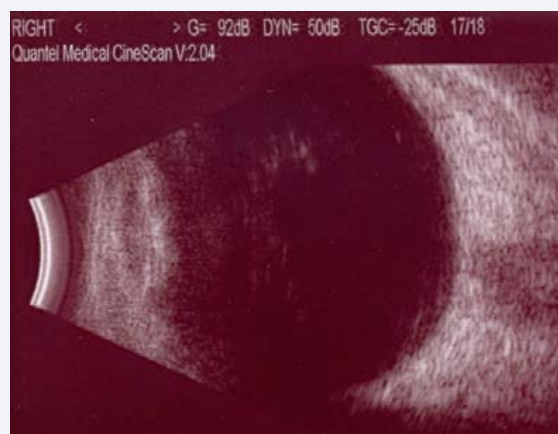
CDI was done and revealed atherosclerotic changes with no significant lumen narrowing, and this also excluded ocular ischemic syndrome OIS as a cause of visual loss. FA and ICG were ordered to evaluate the retinal and choroidal circulation, as well asMRA to evaluate the retrobulbar vascular system, but the patient was not psychologically ready to have them.

1 week later the macular exudative detachment resolved spontaneously and 1 month later there was extensive macular atrophy confirming the choroidal complication with stable appearance of retinal vessels and optic disc. Final visual acuity remained NLP.

In regard to the above observations, the most probable reason for acute visual loss to NLP in our patient was occlusion of choriocapillaries secondary to bevacizumab injection causing exudative macular detachment and intraretinal and subretinal



**Figure 9** Central macular OCT reveals extensive retinal and choroidal atrophy after exudative macular detachment has resolved.



**Figure 10** B scan ultrasonography of right eye 1 month post injection showing total regression of macular detachment.

hemorrhages around posterior pole. Unfortunately we could not proof our speculation with FA, ICG, and MRA as the patient refused doing these tests. We did not notice any signs of intraocular inflammation at any time post injection, which made us exclude any possible inflammatory etiology for the macular exudative detachment; furthermore we do not believe that the macular lesion could be of mechanical origin secondary to the jet flow of the injection, as we always inject in a gentle manner while the needle shaft is directed anteriorly and not towards the retina. We have been routinely using intravitreal bevacizumab for treating exudative AMD and retinal vascular diseases since 2006 and have done thousands of injections, and this was the first time we encountered such a devastating complication.

In addition to ocular vascular complication, 1 month post injection as the patient was feeling very weak, a complete blood analysis was done and it was positive for low hemoglobin and elevated blood urea and creatinine. Further investigation by nephrologist revealed acute attack of chronic kidney failure. Considering that the patient was not dehydrated, we thought that his exacerbated kidney failure could be attributed to systemic reduction in VEGF secondary to intravitreal bevacizumab [20], as the patient had the predisposing risk factor of chronic renal failure and this renal reaction might be of the same etiology as his unusual ocular vascular reaction.

## CONCLUSION

Possible side effects of intravitreal bevacizumab on systemic, retrobulbar and ocular circulation should always be kept in mind when facing unexplained acute visual loss post injection. These devastating side effects should be considered before treatment in patients with compromised ocular and systemic vascular conditions who have a greater predisposition for these complications of VEGF inhibition, such as old patient's age, carotid insufficiency, poorly controlled diabetes mellitus, Ischemic CRVO, Ischemic ocular syndrome, previous myocardial infarction, previous stroke and early kidney disease.

## REFERENCES

1. Tolentino M. Systemic and ocular safety of intravitreal anti-VEGF therapies for ocular neovascular disease. *Surv Ophthalmol.* 2011; 56: 95-113.
2. Gordon MS, Cunningham D. Managing patients treated with bevacizumab combination therapy. *Oncology.* 2005; 69: 25-33.
3. Scappaticci FA, Skillings JR, Holden SN, Gerber HP, Miller K, Kabbinavar F, et al. Arterial thromboembolic events in patients with metastatic carcinoma treated with chemotherapy and bevacizumab. *J Natl Cancer Inst.* 2007; 99: 1232-1239.
4. Csaky K, Do DV. Safety implications of vascular endothelial growth factor blockade for subjects receiving intravitreal anti-vascular endothelial growth factor therapies. *Am J Ophthalmol.* 2009; 148: 647-656.
5. Arnott C, Punnia-Moorthy G, Tan J, Sadeghipour S, Bursill C, Patel S. The vascular endothelial growth factor inhibitors ranibizumab and aflibercept markedly increase expression of atherosclerosis-associated inflammatory mediators on vascular endothelial cells. *PLOS.* 2016; 11: e0150688.
6. Colucciello M. Systemic safety of intravitreal anti-VEGF therapy: are concerns real or theoretical? *Retinal Physician.* 2015; 12: 14-16.
7. Avery RL, Castellarin AA, Steinle NC, Dhoot DS, Pieramici DJ, See R, et al. Systemic pharmacokinetics following intravitreal injections of ranibizumab, bevacizumab or aflibercept in patients with neovascular AMD. *Br J Ophthalmol.* 2014; 98: 1636-1641.
8. Avery RL. What is the evidence for systemic effects of intravitreal anti-VEGF agents, and should we be concerned? *Br J Ophthalmol.* 2014; 98: i7-i10.
9. Avery RL. Are there systemic safety concerns with anti-VEGF injections? *Retinal physician.* 2015; 12: 14-16.
10. Gonzalez-Pacheco FR, Deudero JJ, Castellanos MC, Castilla MA, Alvarez-Arroyo MV, Yagu ES, et al. Mechanisms of endothelial response to oxidative aggression: protective role of autologous VEGF and induction of VEGFR2 by H2O2. *Am J Physiol Heart Circ Physiol.* 2006; 291: 1395-1401.
11. Infanger M, Kossmehl P, Shakibaei M, Baatout S, Witzing A, Grosse J, et al. Induction of three-dimensional assembly and increase in apoptosis of human endothelial cells by simulated microgravity: impact of vascular endothelial growth factor. *Apoptosis.* 2006; 11: 749-764.
12. Zachary I. Signaling mechanisms mediating vascular protective actions of vascular endothelial growth factor. *Am J Physiol Cell Physiol.* 2001; 280: C1375-C1386.
13. Kilickap S, Abali H, Celik I. Bevacizumab, bleeding, thrombosis, and warfarin. *J Clin Oncol.* 2003; 21: 3542.
14. Huang ZL, Lin KH, Lee YC, Sheu MM, Tsai RK. Acute vision loss after intravitreal injection of bevacizumab (avastin) associated with ocular ischemic syndrome. *Ophthalmologica.* 2010; 224: 86-89.
15. Toklu Y, Cakmak HB, Raza S, Anayol A, Asik E, Simsek S. Short-term effects of intravitreal bevacizumab (Avastin) on retrobulbar hemodynamics in patients with neovascular age-related macular degeneration. *Acta Ophthalmol.* 2011; 89: e41-45.
16. Bonnin P, Pournaras JA, Lazrak Z, Cohen SY, Legargasson JF, Gaudric A, et al. Ultrasound assessment of short-term ocular vascular effects of intravitreal injection of bevacizumab (avastin) in neovascular age-related macular degeneration. *Acta Ophthalmol.* 2010; 88: 641-645.
17. Mete A, Saygili O, Mete A, Bayram M, Bekri N. Effects of intravitreal bevacizumab (avastin) therapy on retrobulbar blood flow parameters in patients with neovascular age-related macular degeneration. *J Clin Ultrasound.* 2010; 38: 66-70.
18. Shimomura Y, Hirata A, Ishikawa S, Okinami S. Changes in choriocapillaris fenestration of rat eyes after intravitreal bevacizumab injection. *Graefes Arch Clin Exp Ophthalmol.* 2009; 247: 1089-1094.
19. Peters S, Heiduschka P, Julien S, Ziemssen F, Fietz H, Bartz-Schmidt KU. The Tubingen Bevacizumab Study Group, Schraermeyer U. Ultrastructural findings in the primate eye after intravitreal injection of bevacizumab. *Am J Ophthalmol.* 2007; 143: 995-1002.
20. Pellé G, Shweke N, Duong Van Huyen JP, Tricot L, Hessaïne S, Frémeaux-Bacchi V, et al. Systemic and kidney toxicity of intraocular administration of vascular endothelial growth factor inhibitors. *Am J Kidney Dis.* 2011; 57: 756-759.

**Cite this article**

Azmeh A (2017) Acute Visual Loss Secondary to Choriocapillaries Occlusion at the Time of Intravitreal Bevacizumab Injection for Age Related Macular Degeneration with Exacerbation of Kidney Disease: Case Report. *JSM Ophthalmol* 5(2): 1053.