

Review Article

Patellofemoral Instability: Anatomy, Classification, Aetiology and Review of Treatment Options

Pastides PS^{1*}, Dodd M² and Gupte CM¹¹Department of Trauma and Orthopaedics, St Mary's Hospital, UK²Department of Trauma and Orthopaedics, Swansea University Hospital Morriston, UK***Corresponding author**

Philip Pastides, St Mary's Hospital, Praed Street, London W2 1NY, E-mail: ppastides@hotmail.com

Submitted: 01 October 2014**Accepted:** 08 October 2014**Published:** 10 October 2014**Copyright**

© 2014 Pastides et al.

OPEN ACCESS**Keywords**

- Patellofemoral syndrome
- Treatment
- Literature review

Abstract

Patellofemoral instability and pain is a troublesome condition, affecting people in a significant manner. Its aetiology is multifactorial and can be related to either a soft tissue, bony or combination of soft tissue and bony pathology.

Soft tissue pathology can be divided into static (medial patellofemoral ligament, capsular structures and laxity) and dynamic (muscular (especially the vastusmedialis muscle) and neuromuscular control of quadriceps and gluteus muscles). Bony pathology can be divided into proximal (patella and trochlea morphology and position) and distal (Q angle and tibial tubercle/trochlear groove distance).

Treatment can include physiotherapy, bracing or surgery. Surgical options include proximal and distal soft tissue procedures (such as medial patellofemoral ligament reconstruction or patellar tendon transfer) or bony procedures (trochleoplasty, tibial tubercle transfer). The choice of treatment method depends on underlying pathology, patient preference and success of previous therapy. We propose an anatomically based method of assessment and review the literature to assess the outcomes of the various available treatment methods.

INTRODUCTION

Patellofemoral instability can be a disabling condition and most commonly affects young patients. Primary patellar dislocation has been reported to occur at rates of 5.8 per 100 000, with recurrence following conservative management occurring between 15% and 44% [1,2]. Even without recurrence, a significant proportion of patients continue to suffer with pain and instability after the initial dislocation [3]. Furthermore, it has been shown that people with long term patellofemoral pain show significantly more depression, hostility, passive attitude, mental distress and lower levels of self perceived health compared to a matched group of people without anterior knee pain [4,5]. Treatment for this condition is multifactorial and dependant on establishing the correct diagnosis, predisposing factors and addressing them appropriately.

Bony structure of the patellofemoral joint

The patella is the largest sesamoid bone in the body, situated within the quadriceps tendon. The anterior surface is slightly convex in shape and divided into three parts. The quadriceps tendon inserts into the rough superior third and continues

superficially to cover the anterior surface and form the deep fascia, which is adherent to the bone. The middle third of the patella has numerous vascular orifices. The inferior third is the insertion point of the patella tendon.

The posterior surface of the patella is divided in an inferior and superior portion. The inferior portion is non-articulating and represents up to a quarter of the patellar height. The remainder of the surface forms the superior portion, which is the articulating surface and covered by hyaline cartilage. The cartilaginous posterior surface is further divided by a rounded vertical ridge. It has a large, lateral portion for articulation with the lateral condyle of the femur and a smaller, medial portion for articulation with the medial condyle of the femur. The medial and lateral facets are divided into superior, middle and inferior facets. There is a seventh facet termed the 'odd facet' located medially to the medial facet. This does not articulate with the femur until flexion exceeds 90 degrees [6].

With increasing knee flexion, the contact pressure moves proximally on the patella up to the superior pole and onto the quadriceps tendon. These contact pressures and tracking path

within the trochlear can be affected by the osseous geometry of the patella.

Patellar dysplasia

Wiberg [7-10], has described three basic shapes of the patella (Figure 1) based on the position of the vertical ridge; type 1: medial and lateral facets are roughly of the same length; type 2: is the most common and occurs when the medial facet is only around half the length of the lateral facet and type 3: lateral facet makes up the majority of the posterior surface (medial facet is so far medial that the central ridge is barely noticeable).

CLINICAL ASSESSMENT

Identification of the causative factors underlying PFJ pathology is dependent on detailed history and full examination of the affected knee.

Relevant history (non-exhaustive list) includes:

- [1] History of trauma to knee
- [2] Did the kneecap dislocate if so did it reduce spontaneously. How often has this occurred?
- [3] Is pain or instability the main symptom. Anterior pain is more difficult to resolve with surgery than instability [11].
- [4] Is there an activity type (eg running, skiing, squatting, jumping) that make the pain or instability worse?
- [5] What treatment has taken place so far: if physiotherapy has been given, what form did this take?
- [6] How do the symptoms affect the patient's day to day life or sporting aspirations?

A comprehensive clinical examination underpins the diagnosis and management and should include:

- [1] Alignment and Q angle

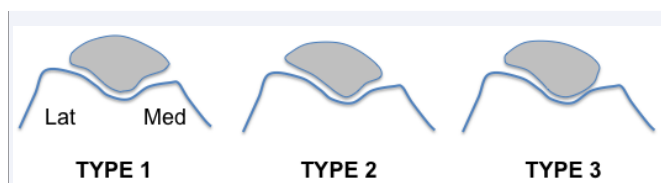


Figure 1 Trochlear anatomy and trochlear dysplasia. The trochlear surface of the femur is divided into two facets, medial and lateral. Proximally, they are in continuity with a shallow groove conforming to the contours of the distal patellar articular surface. Curving distally and posteriorly, this groove deepens to become the intercondylar notch. The cartilaginous covering of the trochlea is thinner than that on the undersurface of the patella. The lateral facet of the trochlea tends to be larger and extend more proximally than the medial facet. This lateral facet acts as a buttress to prevent lateral subluxation of the patella and helps to centre the patella in the trochlear as the knee moves from 15 degrees through to full knee flexion. A normal sulcus angle has been quoted as between 135-140 degrees. A flattened lateral trochlea can lead to patella instability. Dejour classified trochlear dysplasia into four types; type A: normal shape but shallow, type B: markedly flattened or convex trochlea, type C: trochlear facet asymmetry with high lateral facet and hypoplastic medial facet, type D: type C with an associated vertical link ("cliff") between the facets [8]. A radiological study by Davies et al. [9] found that the mean sulcus angle for type A knee was 140.4°, type B 143.1°, type C 149° and for type D 171°.

- [2] gait (antalgic, varus or valgus thrust)
- [3] Swelling (indicates an irritable knee or damage to intracapsular structures)
- [4] Patellofemoral joint examination: patellar tilt tracking, patellar quadrant movement (medial and lateral indicating tightness of medial and lateral structures), patellar apprehension, medial and lateral facet tenderness and tenderness of the fat pad and patellar tendon.
- [5] hyperlaxity examination (for example a Beighton score [12])
- [6] Completion of knee (cruciate and collateral ligaments, menisci) and hip examination

RADIOLOGICAL ASSESSMENT

The clinical examination should be supplemented with radiological examination of the knee. Initially, radiographs of the affected knee should be requested, including a weight bearing AP, lateral and skyline view of the affected (and normal) knee. Merchant views performed with the knee at 30 degrees of flexion provide a good plain film representation of patellar position in the trochlea. The radiology of patella alta and patellofemoral dysplasia also needs to be considered [13].

Further imaging modalities, such as CT and MRI should be requested following the clinical findings

TREATMENT OF PFJ INSTABILITY

Neural pathway and the role of physiotherapy

Physiotherapy and activity modification form the mainstay of initial management of PFJ instability. Physiotherapy includes:

- [1] Patient education as to the underlying pathology
- [2] Muscle strength and conditioning: in particular inner quadriceps (vastus medialis obliquus) and gluteal muscle strengthening. A systematic review and meta-analysis investigating the association between recruitment of the vastus medialis oblique (VMO) relative to the vastus lateralis (VL) muscle demonstrated a delayed onset of VMO activation relative to VL in patients complaining of anterior knee pain compared to those without [14].
- [3] proprioception exercises [15,16].
- [4] Lateral releases/iliotibial band stretches and releases in the case of tight lateral structures [reference]. As previously mentioned, the position of the patella within the trochlear throughout its movement arises from a careful balance of the surrounding soft tissue structures. There is evidence to suggest that patients suffering with anterior knee pain have an imbalance of muscle firing and subtle gait abnormalities. Thijs et al. [17] showed how 36/84 military cadets developed patellofemoral symptoms within 6 weeks during their military training. Gait analysis showed that they had significantly more laterally distributed pressure on initial contact and slower maximal velocity of change of lateral to medial direction of the centre of pressure during the gait phase transition.
- [5] Patellar taping has a role in managing PFL instability. A

Cochrane review by Callaghan and Selfe [18], looking at available and published randomised controlled trials only, concluded that based on the available evidence, there is insufficient conclusion on the effects of taping, whether used on its own or as part of a treatment programme. It is worth mentioning that the authors were only able to include 5 small trials with a total of approximately 200 participants.

There is no agreed rehabilitation regimen for the treatment of PFJ instability and there is a distinct lack of high quality studies in the literature comparing treatment options [19]. These include quadriceps strengthening, stretching, specific warm-up and warm-down sequences, core stability and hip strengthening [10]. Which regimen is best is difficult to decide, however a recent systematic review and meta-analysis of randomised trials only, concluded the beneficial effects of foot orthoses with and without multimodal physiotherapy over flat inserts, closed chain exercises over open chain exercises) and patella taping in conjunction with exercise rather than exercise alone [20]. Conversely, a prospective randomised study over a five year period by Witvrouw et al showed a slight benefit in open over closed kinetic chain exercises in terms of pain and swelling [21].

Role of bracing

Immobilisation of the knee in extension has been performed for PFJ pain for decades. However, initial attempts at immobilisation utilized plaster treatment. This led to muscle atrophy, prolonged stiffness and persistent anterior knee pain [22].

More recently, brace therapy has been shown to decrease the risk of recurrent dislocation and pain [23]. It has been shown that patella bracing reduces patellofemoral pressure by influencing patellar and knee kinematics, and by redistributing load across the joint [24]. However there appears to be little overall consensus on how to prescribe brace therapy for patellofemoral syndrome and the regimen appears to be related to individual physician preferences [25]. The senior authors use a regime of bracing with progressive increase in permitted flexion over 6-8 weeks (eg 0-45 degrees for 2 weeks, 0-60 degrees for 2 weeks and 0-90 degrees for a further 2 weeks). During the period of bracing, physiotherapy can maintain knee movement within prescribed range, muscle condition and swelling management.

Surgery for PFJ instability

The role of surgery in PFJ instability is controversial and varies according to treating surgeon, and centre in which the patient is being treated. The decision to perform surgery is influenced by:

- [1] Failure of conservative management/physiotherapy
- [2] Clinical or radiological evidence of structural abnormality eg lateral tightness, increased Q angle, medial patellofemoral ligament rupture, bony dysplasia.

SOFT TISSUE PROCEDURES

Lateral retinacular release (LRR)

A tight lateral retinaculum can lead to altered biomechanics and tracking of the patella, which may predispose to lateral patellar

subluxation or dislocation. In such cases, a lateral retinacular release (LRR) can be performed usually via an arthroscopic route. This has historically been a common procedure, but more recently concerns have been raised regarding weakening the lateral structures, especially in hyperlax patients. This can lead to excessive medial translation of the released patella, especially if a distal realignment is performed [26,27].

Some questions have been raised as to whether using electrocautery to perform this procedure can lead to adverse effects and weakness of the lateral structures of the patella. Arnoczky et al. [28] and Medvecky et al. [29] have shown that the application of heat to collagen tissues results in denaturing and collapsing the collagen triple helix which results in a shortening of the retinacular fibres and hence tightening of the tissue. Furthermore, Woods et al. [30] measured the quadriceps strength and outcomes measured after complete arthroscopic release of the vastuslateralis tendon in twenty patients who had recurrent patellar dislocation. Bilateral quadriceps strength was tested both pre and post operatively using an isokinetic dynamometer. Follow-up averaged 27 months (range, 24-43 months). There were no redislocations. Mean quadriceps strength improved by a mean of 28% (from 32.3 to 41.4 N x m). The mean quadriceps torque ratio (involved/uninvolved) improved significantly from a preoperative value of 63% (31/51 N x m) to 80% (42/52 N x m) at follow-up ($P = .017$). Fourteen patients (70%) increased quadriceps torque, and 6 patients (30%) decreased quadriceps torque. The IKDC score improved from 45 points preoperatively to 76 points at follow-up ($P = .001$). The SF-36 physical component summary scores improved from 38 points preoperatively to 50 points at follow-up ($P = .007$), and the SF-36 physical functioning subscale scores improved from 53 points to 86 points ($P = .015$).

Certain authors have investigated the effect of performing an arthroscopic lateral release and medial reefing of the patella. 41 patients (45 knees) with a history of patellar instability underwent surgery for arthroscopic realignment under Halbrecht [31]. Of the 29 knees available at final follow up, 23 were actual dislocators and 6 were subluxators. All patients underwent a patella realignment utilizing an all-inside arthroscopic technique. Medial retinacular sutures were introduced percutaneously using an epidural needle. An arthroscopic lateral release was then performed with a standard electrocautery device. The Lysholm score improved from 41.5 preoperatively to 79.3 postoperatively. When patients were asked to evaluate their results on a simple subjective rating scale, 27 (93%) felt that they were significantly better, 1 patient felt that she was worse, and 1 felt that there was no change. Patients reported an improvement in pain from 7.1 preoperatively to 2.4 postoperatively ($P < .05$). Crepitus improved from 6.6 preoperatively to 2.5 postoperatively ($P < .05$). Swelling improved from 6.0 to 0.8 ($P < .05$). Instability improved from 8.2 to 0.8 ($P < .05$).

Ricchetti et al. [32] performed a systematic review of the literature to compare surgical success of LRR or LRR with medial soft-tissue realignment (MR) for recurrent lateral patellar instability. All studies involving either open or arthroscopic LRR or LRR with MR. Fourteen of these studies met our inclusion criteria; 7 evaluated LRR alone, 6 evaluated LRR with MR, and 1 study looked at both isolated LRR and LRR with MR. Fourteen studies met inclusion criteria. There were 247 knees with a

minimum 2-year follow-up after LRR and 220 after LRR with MR. In the LRR patients, there were 56 cases (probability 0.227, odds 0.293) of recurrent lateral patellar instability, 26 (probability 0.105; odds 0.118) of which were patients experiencing postoperative patellar dislocations and 30 (probability 0.121, odds 0.157) of which were patients experiencing postoperative patellar subluxations. In the LRR with MR patients, there were 14 cases (probability 0.064, odds 0.068) of recurrent instability, 12 (probability 0.054, odds 0.058) of which were postoperative dislocations and 2 (probability 0.009, odds 0.010) of which were postoperative subluxations. The frequency-weighted success with respect to instability ranged from 43.9% to 100%, with a mean success of 77.3% (95% CI, 74.7% to 80.0%) in the LRR studies and ranged from 80% to 98.3% with a mean success of 93.6% (95% CI, 93.0% to 94.3%) in the LRR with MR studies. The odds of recurrent instability after an isolated LRR were significantly greater than after combined LRR and MR with respect to the reported prevalence of any postoperative instability symptoms ($P < .001$), patellar dislocation ($P = .045$), and patellar subluxation ($P < .001$). The use of isolated LRR yields significantly inferior long-term results with respect to recurrent lateral patellar instability postoperatively.

The senior authors reserve lateral release for patients with:

[1] Clinically tight lateral structures (greater than 2 quadrant difference between medial and lateral glides and lateral tilt)

[2] nohyperlaxity

[3] Excessive lateral patellar pressure syndrome [26]

MEDIAL REEFING

In cases where the patellar pull appears to be deficient medially, some surgeons advocate reefing of the medial structures in isolation, without the need for a lateral retinacular release. Miller et al. [33] reported on such a case series. Twenty-four patients (25 knees) underwent arthroscopically assisted medial reefing in isolation and were observed for an average of 60 months. Ninety-six percent (24/25) were satisfied with their results, and all patients would have the same procedure performed again. Subjective symptom scores improved significantly. Average Lysholm knee and Tegner activity scores improved significantly improved from 54 to 91 and 3.3 to 6.2 respectively. Significant improvement was seen in patellar mobility, apprehension, and patellofemoral tenderness with compression. Range of motion, muscle atrophy, and tilt did not change significantly. Congruence angles improved from 4.4 degrees to -2.5 degrees ($P = .009$), lateral patellofemoral angles improved from 5.5 degrees to 8.7 degrees ($P = .011$), and lateral patellar displacement improved from 2.0 to 0.2 mm ($P < .044$). There were no recurrent dislocations or subluxations.

THE MEDIAL PATELLOFEMORAL LIGAMENT (MPFL)

The medial patellofemoral ligament (MPFL) has been shown to be the primary static soft tissue stabiliser of the patellofemoral joint. Studies have shown that almost all cases of acute dislocation of the patella causes a degree of MPFL damage [34], especially lateral dislocations [35]. Therefore it would appear logical that

repairing this important ligament would lead to a more stable patella. Two systematic reviews within the last few years have reviewed the literature and concluded repair of the MPFL leads to good functional results [36,37]. How the repair is performed is still controversial, with various options described in the literature regarding repair of the MPFL, including suture repair, anchors and tendon grafting.

Cadaveric studies have shown that the MPFL has a mean tensile strength of 208 N (SD 90) at 26 mm (SD 7) of displacement. The strengths of various surgical techniques after repair have been shown to be less; sutures alone, 37 N (SD 27); bone anchors plus sutures, 142 N (SD 39); blind-tunnel tendon graft, 126 N (SD 21); and through-tunnel tendon graft, 195 N (SD 66) [35].

However, reconstruction of the MPFL is a technically demanding procedure with a relatively high level of post operative complications. In a review of 179 knees that underwent MPFL reconstruction over a 6 year period, Parikh et al. [38] found complications occurred in 16.2% of cases, with almost half resulting from technical problems. Major complications included recurrent lateral patellar instability (8 patients), knee motion stiffness with flexion deficits (8 patients), patellar fractures (6 patients), and patellofemoral arthrosis/pain (5 patients). Eighteen of 38 (47%) complications were secondary to technical factors and were considered preventable.

Causes of unsatisfactory results of MPFL reconstruction include:

[1] Patella fracture

[2] Inadequate or excessive tensioning of the MPFL graft

[3] Femoral tunnel malpositioning. The senior author prefers to drill the femoral tunnel under radiological guidance in order to avoid femoral tunnel malpositioning, as described by Schoettle et al. (Figure 2 and 3) [39].

There is no agreed consensus on how to perform this reconstruction. Lenschow et al. [40] compared the structural properties of 5 different fixation strategies for a free porcine tendon graft at the patella in Medial Patellofemoral Ligament (MPFL) reconstruction under cyclic loading and load to failure testing; 3.5-mm titanium anchor, transosseous 1-mm braided polyester suture, interference screw fixation, medial bone bridge and transpatellar tunnels. In the bone bridge group, 60% of all specimens failed during cyclic testing. Fixation by transosseous sutures showed significantly less stiffness compared with all other techniques ($P < .05$). The bone bridge technique showed significantly lower load to failure compared with all other techniques ($P < .05$). The differences between the other groups were not significant.

Fisher et al. [37] systematically reviewed the evaluated efficacy of MPFL reconstruction, rehabilitation and patient outcomes for safely returning patients to sports. A total of 21 studies encompassing 510 knees were included. To highlight the lack of a single best reconstructive technique, 14 different fixation methods were described. The most common construct used was a semitendinosis autograft, followed by a gracilis autograft. Furthermore, no agreed post operative rehabilitation regimen exists and they found a distinct lack of high level evidence

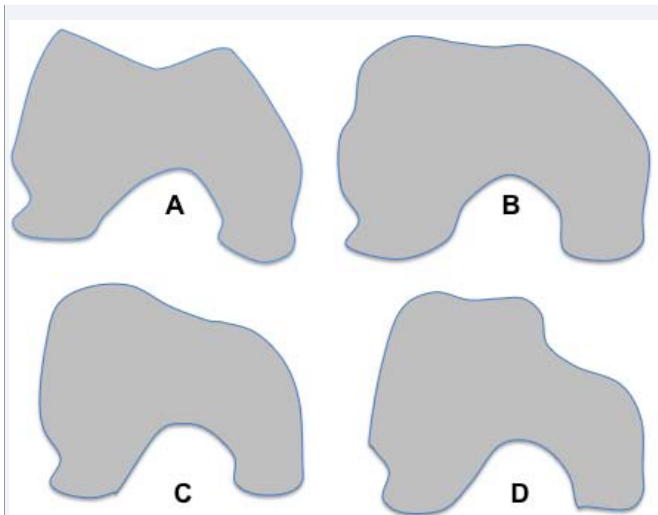


Figure 2 Aetiology of patellar instability. The causes of patella instability are multifactorial. The patella is held within the patellofemoral joint via a synergistic effect of osseous morphology and soft tissue restraints, the latter encompassing both passive (ligaments/capsule) and active (muscle) stabilisers. A single or combination of factors may be abnormal and hence a thorough and structured approach to treatment must be sought.

The term 'chondromalacia patellae' (meaning "softening of the patellar cartilage"), introduced by Aleman [10] in 1928, has now become synonymous with patellofemoral joint related pain, but is not a pathological diagnosis in itself. The senior author prefers the term "patellar chondropathy" as a more accurate term denoting a pathological change in the patellar articular cartilage.

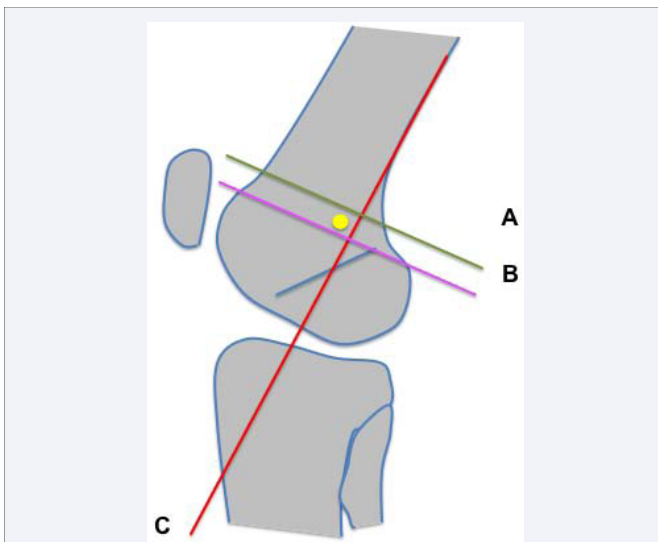


Figure 3 The optimum positioning of the femoral tunnel for a MPFL reconstruction, depicted by the yellow circle, is located 1mm anterior to a line extending from the posterior cortex extension line (C) and 2.5mm distal to the posterior origin of the medial femoral condyle (A) and proximal to the level of the posterior point of the Blumensaat line (B).

studies; the mean Coleman methodology score was 58.7. Overall patient satisfaction and outcome following MPFL reconstruction and rehabilitation were shown to improve patient outcome and ability to perform routine activities of daily living regardless of

the particular reconstruction method or graft construct used. This was a similar conclusion to that drawn by other systematic reviews [41,42].

Another key step following MPFL reconstruction is the post operative rehabilitation program. This is an area that is poorly described in the literature and that appears to be directed by individual surgeon practice. A systematic review by Fisher et al. [37], which also reviewed post operative rehabilitation regimens, found that the level of description was generally limited to acute care rehabilitation with insufficient progressive exercise descriptions. The senior author recommends a regimen that includes

[1] Assisted weight bearing

[2] Brace regimen: 0-30 degrees for 2 weeks followed by 30 degree increments every 2 weeks. The brace is removed at 6-9 weeks post operatively.

BONY PROCEDURES

Patella height correction

Patella alta is a recognized risk factor for patella, noted in one study to be present in 24% of episodic dislocations compared to 3% in normal controls [43]. It has also been identified as predictor of recurrent instability in patients sustaining patella dislocation [44,45]. The reason for the resulting instability is likely to be multifactorial; a decreased contact area between the patella and the trochlear leading to decreased resistance to lateral translation [46,47] enhanced further by a longer patella tendon allowing excessive motion in the coronal plane [48].

Magnussen et al. [50] performed a systematic review to identify published surgical techniques to treat episodic patella dislocation in the setting of patella alta in skeletally mature patients. Those studies that related to the treatment of patellofemoral pain only, rather than dislocation, were excluded. They included five retrospective studies of 203 knees in 168 patients in total. All studies performed a distal tibial tubercle distalisation. Tibial tubercle non union and proximal tibial fracture incidence rates were both 0.6%. The risk of recurrent dislocation is 1.75% (range 0-4.9%) and patella apprehension 26.3% (range 15-33%). Three studies reported on functional outcomes with good to excellent results in all patients.

Tibial tubercle osteotomy procedures

The quadriceps angle (Q-angle) represents the angle between the vector of action of the quadriceps and the patellar tendon. An increased Q-angle has been associated with an increased risk of patellar instability, although there is disagreement on its reliability and validity. Patella instability can be treated surgically by adjusting the location of the tibial tubercle and thus realigning the tendinous attachment of the patella to make the joint more stable. There are several methods that have been described to measure patella height on a standard radiograph. Its position can be measured in relation to the femur (direct method) or to the tibia (indirect), the latter tending to be the most commonly used methods [51].

The tibial tubercle transfer is a very versatile procedure in

that the degree of medialisation, anteriorisation or distal translation of the tubercle can be adjusted according to a preoperative plan for each patient. For example, a patient with pure lateral translation can undergo a pure medialisation, whereas one with lateral translation and patella alta, could undergo a medialisation and slight distalisation of the tubercle. Malpositioning of the patella in the sagittal plane (ie patella alta) can be treated by moving the tubercle distally in cases of patella alta, leading to good results [50]. In cases of patella subluxation and an increased Q angle, the tibial tubercle can be medialised, a technique known as the Elmslie-Trillat procedure [52] or variants of this procedure.

Results for these procedures show acceptable functional outcomes. In a follow up study of 24 knees in patients with a mean age of 31 years at the time of surgery who underwent Elmslie-Trillat procedures, Naveed et al. [53] reported good or excellent outcome at 4 years in 19 knees (79.2%), while 15 knees (62.5%) were reported the same outcome at long-term follow-up (mean 12 years, range 10-15 years). They did however note that 12 patients with pre operative lower grade chondral damage (grade 1 to 2) showed early to moderate signs of osteoarthritis on radiographs, six out of ten knees with higher grade chondral damage (grade 3 to 4) showed marked evidence of osteoarthritis and four of these had undergone a knee replacement. Karataglis et al. [13] reported similar satisfactory results and functional outcomes in 44 knees with an average follow up of 40 months.

In a retrospective study reporting on functional outcomes of 18 knees, Endres and Wilke [54] performed Roux-Elmslie-Trillat procedures (release of the lateral retinaculum, a medial capsular plication and medialisation of the tuberosity) in 18 patients. Subjective results of the operation were classed as excellent or good in 16 of the 18 patients ten years after surgery. The pre and ten year follow up average Knee Society and Tegner scores improved significantly from 74.5 to 87.7 and from 3.4 to 4.6 respectively.

The tibial tuberosity to trochlear groove (TT-TG) distance, calculated via a CT or MRI scan, has been described as an objective and reproducible method to determine the position of the tuberosity, with a very high interrater, intermethod and interperiod reliability rate [43,55,56]. In fact, comparing this measurement to the Q angle shows that the latter is not a reliable indicator of patella instability [57]. In cases when there is concern over degeneration of the patellofemoral joint or an increased 'Q', the tubercle can be medialised and displaced anteriorly (Fulkerson procedure), in order to decrease the contact pressure across the trochlear and realign the tibial tuberosity [58,59]. Using this method, it has been suggested that asymptomatic patients have a mean TT-TG distance of 13mm whilst those with instability average 15mm [56]. The Fulkerson procedure has been modified by several surgeons, but results have still been encouraging [60].

TROCHLEOPLASTY

Trochlear dysplasia and its association and congruency with the tracking patella is a recognised cause of recurrent dislocation and anterior knee, occurring in up to 85% of cases. The diagnosis is made when a true lateral radiograph of the knee demonstrates

the crossing sign, the trochlear bump and a decrease in trochlear depth. The crossing sign refers to the floor line of the trochlear sulcus crossing the anterior border of the femoral shaft. The trochlear bump represents a prominent anterior extension of the trochlear groove in relation to the projection of the anterior cortex of the distal femur [43].

Trochleoplasty is a surgical procedure designed to improve patellofemoral tracking by remodeling the trochlear groove. There have been various surgical techniques described to achieve this, however the underlying principle remains the same; to create a more congruent and stable articulation between the patella and the trochlear during tracking. Techniques described include elevation of the lateral facet of the dysplastic trochlear via an osteotomy [61] and deepening of the femoral trochlear by removing some of the central subchondral bone [62]. Von Knoch et al. [63] described a technique of raising an osteochondral flap from the trochlear and then using burrs to fashion a sulcus. This was modified by Blond and Schottle [64], who performed this procedure arthroscopically. All techniques appear to have similar satisfactory results. However there is a significant incidence of stiffness after trochleoplasty, and some studies have described the need for postoperative manipulation under anaesthetic of the knee of up to 46% [65,66].

Proposed approach to managing PFJ instability/pain

As evident from our review, the management of PFJ pain and instability is multifactorial and challenging problem with an agreed consensus on principle management strategies but a wide variety of techniques to achieve them.

We advocate the use of a simple anatomical based approach to assess the patient and plan appropriate treatment. In the case of an acute presentation, efforts must be made to promptly reduce the joint and then proceed to obtain appropriate imaging in order to identify any acute pathology which can then be managed either operatively or non operatively. For chronic presentations, the clinician must isolate whether the pathology is related to the proximal or distal portion of the patella, and then whether it is related the pathology is due to a soft tissue or osseous structure. Based on this assessment, treatment options can then be instigated. In cases of isolated articular cartilage loss or osteoarthritis, the clinician needs to decide whether surgical options to attempt and restore the cartilage is appropriate or arthroplasty surgery should be considered.

DISCUSSION AND CONCLUSION

Patellofemoral pain and instability is a common and difficult condition to treat. Paramount to the treatment is the need to accurately localize the pathology; the reason for it may be multifactorial and thus require a combination of operative and non operative techniques to both soft tissue structures and the osseous structures. We present an anatomical approach to managing this condition and propose that considering anterior knee pain in this manner will enable surgeons to manage patients in a more effective manner.

REFERENCES

1. Fithian DC, Paxton EW, Stone ML, Silva P, Davis DK, Elias DA.

- Epidemiology and natural history of acute patellar dislocation. *Am J Sports Med.* 2004; 32: 1114-1121.
2. Hawkins RJ, Bell RH, Anisette G. Acute patellar dislocations. The natural history. *Am J Sports Med.* 1986; 14: 117-120.
 3. Smith TO, Davies L, Chester R, Clark A, Donell ST. Clinical outcomes of rehabilitation for patients following lateral patellar dislocation: a systematic review. *Physiotherapy.* 2010; 96: 269-281.
 4. Jensen R, Hystad T, Baerheim A. Knee function and pain related to psychological variables in patients with long-term patellofemoral pain syndrome. *J Orthop Sports Phys Ther.* 2005; 35: 594-600.
 5. Carlsson AM, Werner S, Mattlar CE, Edman G, Puukka P, Eriksson E. Personality in patients with long-term patellofemoral pain syndrome. *Knee Surg Sports Traumatol Arthrosc.* 1993; 1: 178-183.
 6. Goodfellow J, Hungerford DS, Zindel M. Patello-femoral joint mechanics and pathology. 1. Functional anatomy of the patello-femoral joint. *J Bone Joint Surg Br.* 1976; 58: 287-290.
 7. Wiberg G. Roentgenographic and anatomic studies on the femoro-patellar joint. *Acta Orthop Scand* 1941; 12: 319-410
 8. Dejour H, Walch G, Neyret P, Adeleine P. [Dysplasia of the femoral trochlea]. *Rev Chir Orthop Reparatrice Appar Mot.* 1990; 76: 45-54.
 9. Davies AP, Costa ML, Shepstone L, Glasgow MM, Donell S. The sulcus angle and malalignment of the extensor mechanism of the knee. *J Bone Joint Surg Br.* 2000; 82: 1162-1166.
 10. Aleman O. Chondromalacia posttraumatica patellae. *Acta Chir Scand* 1928; 63: 149-190
 11. Post WR. Anterior knee pain: diagnosis and treatment. *J Am Acad Orthop Surg.* 2005; 13: 534-543.
 12. Beighton P, Solomon L, Soskolne CL. Articular mobility in an African population. *Ann Rheum Dis.* 1973; 32: 413-418.
 13. Karataglis D, Green MA, Learmonth DJ. Functional outcome following modified Elmslie-Trillat procedure. *Knee.* 2006; 13: 464-468.
 14. Chester R, Smith TO, Sweeting D, Dixon J, Wood S, Song F. The relative timing of VMO and VL in the aetiology of anterior knee pain: a systematic review and meta-analysis. *BMC Musculoskelet Disord.* 2008; 9: 64.
 15. Jerosch J, Prymka M. Knee joint proprioception in patients with posttraumatic recurrent patella dislocation. *Knee Surg Sports Traumatol Arthrosc.* 1996; 4: 14-18.
 16. Vengust R, Strojnik V, Pavlovic V, Antolic V, Zupanc O. The effect of proprioceptive training in patients with recurrent dislocation of the patella. *Cell Mol Biol Lett.* 2002; 7: 379-380.
 17. Thijs Y, Van Tiggelen D, Roosen P, De Clercq D, Witvrouw E. A prospective study on gait-related intrinsic risk factors for patellofemoral pain. *Clin J Sport Med.* 2007; 17: 437-445.
 18. Callaghan MJ, Selfe J. Patellar taping for patellofemoral pain syndrome in adults. *Cochrane Database Syst Rev.* 2012; 4: CD006717.
 19. Barton CJ, Webster KE, Menz HB. Evaluation of the scope and quality of systematic reviews on nonpharmacological conservative treatment for patellofemoral pain syndrome. *J Orthop Sports Phys Ther.* 2008; 38: 529-541.
 20. Collins NJ, Bisset LM, Crossley KM, Vicenzino B. Efficacy of nonsurgical interventions for anterior knee pain: systematic review and meta-analysis of randomized trials. *Sports Med.* 2012; 42: 31-49.
 21. Witvrouw E, Danneels L, Van Tiggelen D, Willems TM, Cambier D. Open versus closed kinetic chain exercises in patellofemoral pain: a 5-year prospective randomized study. *Am J Sports Med.* 2004; 32: 1122-1130.
 22. Armstrong BM, Hall M, Crawford E, Smith TO. A feasibility study for a pragmatic randomised controlled trial comparing cast immobilization versus no immobilization for patients following first time patellar dislocation. *Knee* 2012; 19: 696-702
 23. Lun VM, Wiley JP, Meeuwisse WH, Yanagawa TL. Effectiveness of patellar bracing for treatment of patellofemoral pain syndrome. *Clin J Sport Med.* 2005; 15: 235-240.
 24. Bohnsack M, Halcour A, Klages P, Wilharm A, Ostermeier S, Rühmann O. The influence of patellar bracing on patellar and knee load-distribution and kinematics: an experimental cadaver study. *Knee Surg Sports Traumatol Arthrosc.* 2008; 16: 135-141.
 25. Solinsky R, Beaupre GS, Fredericson M. Variable criteria for patellofemoral bracing among sports medicine professionals. *PM R.* 2014; 6: 498-505.
 26. Merican AM, Kondo E, Amis AA. The effect on patellofemoral joint stability of selective cutting of lateral retinacular and capsular structures. *J Biomech.* 2009; 42: 291-296.
 27. Merican AM, Kondo E, Amis AA. The effect on patellofemoral joint stability of selective cutting of lateral retinacular and capsular structures. *J Biomech.* 2009; 42: 291-296.
 28. Senavongse W, Amis AA. The effects of articular, retinacular, or muscular deficiencies on patellofemoral joint stability: a biomechanical study in vitro. *J Bone Joint Surg Br.* 2005; 87: 577-582.
 29. Arnoczky SP, Aksan A. Thermal modification of connective tissues: Basic science considerations and clinical implications. *J Am Acad Orthop Surg.* 2000; 8: 305-313.
 30. Medvecky MJ, Ong BC, Rokito AS, Sherman OH. Thermal capsular shrinkage: Basic science and clinical applications. *Arthroscopy.* 2001; 17: 624-635.
 31. Woods GW, Elkousy HA, O'Connor DP. Arthroscopic release of the vastus lateralis tendon for recurrent patellar dislocation. *Am J Sports Med.* 2006; 34: 824-831.
 32. Halbrecht JL. Arthroscopic patella realignment: An all-inside technique. *Arthroscopy.* 2001; 17: 940-945.
 33. Ricchetti ET, Mehta S, Sennett BJ, Huffman GR. Comparison of lateral release versus lateral release with medial soft tissue realignment for the treatment of recurrent patellar instability: a systematic review. *Arthroscopy* 2007; 23: 463-468.
 34. Miller JR, Adamson GJ, Pink MM, Fraipont MJ, Durand P Jr. Arthroscopically assisted medial reefing without routine lateral release for patellar instability. *Am J Sports Med.* 2007; 35: 622-629.
 35. Nomura E, Horiuchi Y, Inoue M. Correlation of MR imaging findings and open exploration of medial patellofemoral ligament injuries in acute patellar dislocations. *Knee.* 2002; 9: 139-143.
 36. Mountey J, Senavongse W, Amis AA, Thomas NP. Tensile strength of the medial patellofemoral ligament before and after repair or reconstruction. *J Bone Joint Surg Br.* 2005; 87: 36-40
 37. Shah JN, Howard JS, Flanigan DC, Brophy RH, Carey JL, Lattermann C. A systematic review of complications and failures associated with medial patellofemoral ligament reconstruction for recurrent patellar dislocation. *Am J Sports Med.* 2012; 40: 1916-1923.
 38. Fisher B, Nyland J, Brand E, Curitt B. Medial patellofemoral ligament reconstruction for recurrent patellar dislocation: a systematic review including rehabilitation and return to sports efficacy. *Arthroscopy* 2010; 26: 1384-1394
 39. Parikh SN, Nathan ST, Wall EJ, Eismann EA. Complications of medial patellofemoral ligament reconstruction in young patients. *Am J Sports Med.* 2013; 41: 1030-1038.

40. Schöttle PB, Schmeling A, Rosenstiel N, Weiler A. Radiographic landmarks for femoral tunnel placement in medial patellofemoral ligament reconstruction. *Am J Sports Med.* 2007; 35: 801-804.
41. Lenschow S, Schliemann B, Gestring J, Herbolt M, Schulze M, Kösters C. Medial patellofemoral ligament reconstruction: fixation strength of 5 different techniques for graft fixation at the patella. *Arthroscopy.* 2013; 29: 766-773.
42. Buckens CF, Saris DB. Reconstruction of the medial patellofemoral ligament for treatment of patellofemoral instability: a systematic review. *Am J Sports Med.* 2010; 38: 181-188.
43. Smith TO, Walker J, Russell N. Outcomes of medial patellofemoral ligament reconstruction for patellar instability: a systematic review. *Knee Surg Sports Traumatol Arthrosc.* 2007; 15: 1301-1314.
44. Dejour H, Walch G, Nove-Josserand L, Guier C. Factors of patellar instability: an anatomic radiographic study. *Knee Surg Sports Traumatol Arthrosc.* 1994; 2: 19-26.
45. Larsen E, Lauridsen F. Conservative treatment of patellar dislocations. Influence of evident factors on the tendency to redislocation and the therapeutic result. *Clin Orthop Relat Res.* 1982; : 131-136.
46. Thaunat M, Erasmus PJ. Recurrent patellar dislocation after medial patellofemoral ligament reconstruction. *Knee Surg Sports Traumatol Arthrosc.* 2008; 16: 40-43.
47. Stefanik JJ, Zhu Y, Zumwalt AC. Association between patella alta and the prevalence and worsening of structural features of patellofemoral joint osteoarthritis: the multicenter osteoarthritis study. *Arthritis Care Res* 2010; 62: 1258-1265.
48. Ward SR, Powers CM. The influence of patella alta on patellofemoral joint stress during normal and fast walking. *Clin Biomech (Bristol, Avon).* 2004; 19: 1040-1047.
49. Neyret P, Robinson AH, Le Coultre B, Lapra C, Chablat P. Patellar tendon length--the factor in patellar instability? *Knee.* 2002; 9: 3-6.
50. Magnussen RA, De Simone V, Lustig S, Neyret P, Flanigan DC. Treatment of patella alta in patients with episodic patellar dislocation: a systematic review. *Knee Surg Sports Traumatol Arthrosc.* 2014; 22: 2545-2550.
51. Phillips CL, Silver DA, Schranz PJ, Mandalia V. The measurement of patellar height: a review of the methods of imaging. *J Bone Joint Surg Br.* 2010; 92: 1045-1053.
52. TRILLAT A, DEJOUR H, COUETTE A. [DIAGNOSIS AND TREATMENT OF RECURRENT DISLOCATIONS OF THE PATELLA]. *Rev Chir Orthop Reparatrice Appar Mot.* 1964; 50: 813-824.
53. Naveed MA, Ackroyd CE, Porteous AJ. Long-term (ten- to 15-year) outcome of arthroscopically assisted Elmslie-Trillat tibial tubercle osteotomy. *Bone Joint J.* 2013; 95-95B: 478-85.
54. Endres Stefan, Wilke Axel. A 10 year follow up study after Roux-Elmslie-Trillat treatment for cases of patellar instability. *BMC Musculoskelet Disord.* 2011; 12: 48.
55. Koëter S, Horstmann WG, Wagenaar FC, Huysse W, Wymenga AB, Anderson PG. A new CT scan method for measuring the tibial tubercle trochlear groove distance in patellar instability. *Knee.* 2007; 14: 128-132.
56. Schoettle PB, Zanetti M, Seifert B, Pfirrmann CW, Fucentese SF, Romero J. The tibial tuberosity-trochlear groove distance; a comparative study between CT and MRI scanning. *Knee.* 2006; 13: 26-31.
57. Cooney AD, Kazi Z, Caplan N, Newby M, St Clair Gibson A, Kader DF, et al. The relationship between quadriceps angle and tibial tuberosity-trochlear groove distance in patients with patellar instability. *Knee Surg Sports Traumatol Arthrosc.* 2012; 20: 2399-2404.
58. Cohen ZA, Henry JH, McCarthy DM, Mow VC, Ateshian GA. Computer simulations of patellofemoral joint surgery. Patient specific models for tuberosity transfer. *Am J Sports Med.* 2003; 31: 87-98.
59. Beck PR, Thomas AL, Farr J, Lewis PB, Cole BJ. Trochlear contact pressures after anteromedialization of the tibial tubercle. *Am J Sports Med.* 2005; 33: 1710-1715.
60. Jack CM, Rajaratnam SS, Khan HO, Keast-Butler O, Butler-Manuel PA, Heatley FW. The modified tibial tubercle osteotomy for anterior knee pain due to chondromalacia patellae in adults: A five-year prospective study. *Bone Joint Res.* 2012; 1;1: 167-173.
61. Amis AA, Oguz C, Bull AM, Senavongse W, Dejour D. The effect of trochleoplasty on patellar stability and kinematics: a biomechanical study in vitro. *J Bone Joint Surg Br.* 2008; 90: 864-869.
62. Verdonk R, Jansegers E, Stuyts B. Trochleoplasty in dysplastic knee trochlea. *Knee Surg Sports Traumatol Arthrosc.* 2005; 13: 529-533.
63. von Knoch F, Böhm T, Bürgi ML, von Knoch M, Bereiter H. Trochleoplasty for recurrent patellar dislocation in association with trochlear dysplasia. A 4- to 14-year follow-up study. *J Bone Joint Surg Br.* 2006; 88: 1331-1335.
64. Blønd L, Schöttle PB. The arthroscopic deepening trochleoplasty. *Knee Surg Sports Traumatol Arthrosc.* 2010; 18: 480-485.
65. Beaufils P, Thaunat M, Pujol N, Scheffler S, Rossi R, Carmont M. Trochleoplasty in major trochlear dysplasia: current concepts. *Sports Med Arthrosc Rehabil Ther Technol.* 2012; 4: 7.
66. Donell ST, Joseph G, Hing CB, Marshall TJ. Modified Dejour trochleoplasty for severe dysplasia: operative technique and early clinical results. *Knee.* 2006; 13: 266-273.

Cite this article

Pastides PS, Dodd M, Gupte CM (2014) Patellofemoral Instability: Anatomy, Classification, Aetiology and Review of Treatment Options. *Ann Orthop Rheumatol* 2(4): 1035.