

## Case Report

# Subtendinous Fibroma of the Flexor Sheath in a Fifteen-Year Old Boy Presenting as a Painful Swelling of the Finger

Stephanie Hili\*, Anna Allan and Maxim Horwitz

Department of Plastic Surgery, Chelsea and Westminster Hospital, England

## \*Corresponding author

Stephanie Hili, Department of Plastic Surgery, Chelsea and Westminster Hospital, 44 George Street, Salisbury, SP2 7BB, London, UK. Tel: 0044 7876528872; Email: stef.hili@doctors.org.uk

Submitted: 18 November 2015

Accepted: 27 December 2015

Published: 29 December 2015

## Copyright

© 2015 Hili et al.

## OPEN ACCESS

## Keywords

- Hand swellings
- Fibroma of flexor sheath
- Paediatric hand surgery

## Abstract

Swellings of the hand are commonly caused by ganglion cysts, giant cell tumours or epidermoid inclusion cysts. We present an unusual case of a swelling in the digit of a 15 year old male resulting from a fibroma of the tendon sheath. The case was not only unusual in terms of the histological nature of the swelling, but also in the position of the tumour. The mass was located deep to the flexor tendons. Careful dissection and partial sacrifice of the digital pulley system was necessary to ensure complete excision and consequently reduce the risk of recurrence.

## ABBREVIATIONS

MRI: Magnetic Resonance Imaging; PIP: Proximal Inter-Phalangeal

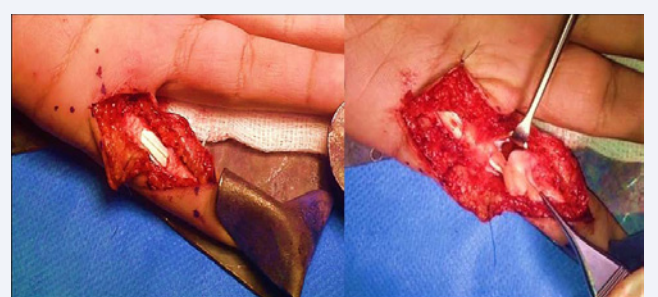
## INTRODUCTION

Painless lesions of the hand are frequently due to a ganglion, a giant cell tumour of the tendon sheath or an epidermoid inclusion cyst. Fibromas of the tendon sheath are benign, slow-growing fibrous tumours. They were first described by [1]. They typically arise in the hand between the ages of 20 to 50 years, and can be associated with a history of trauma. They are often adherent to a tendon or tendon sheath in the hand or foot. Whilst this tumour has been reported in the literature by [2] in 1994 and [3,4] in 2014, there have been no such reports in children.

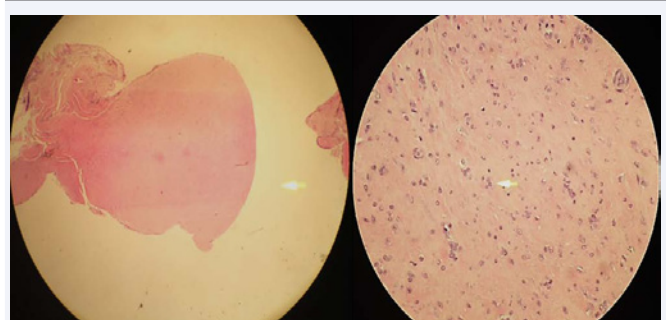
## CASE PRESENTATION

A 15 year old, right-hand-dominant teenager presented to the outpatient clinic with a 6 month history of swelling and discomfort over the volar aspect of his left little finger. The swelling irritated him on playing sports and was uncomfortable in full flexion (Figures 1,2).

Examination revealed a 2cm swelling along the flexor sheath over the proximal phalanx and A1 pulley region of his left little finger. The range of movement of his left little finger was limited to a 50% composite flexion arc. Extension was not affected. All joints of the hand were stable and there was no specific point tenderness suggestive of a glomus tumour. Plain radiographs did not demonstrate any underlying bony pathology. Ultrasound examination showed a 1.8 cm x 0.9cm x 0.4 cm mass interposed



**Figure 1** Intra-operative appearances – initial dissection did not reveal any abnormality. Division of the A3 pulley and retraction of the flexor tendons revealed an irregular mass in a subtendinous position.



**Figure 2** Histology of the lesion - low power scanning (left) demonstrates well circumscribed polypoid nodule; the plump fibroblasts without atypia making the up the lesion can be noted on higher magnification.

between the flexor tendons and volar aspect of the proximal phalanx, likely consistent with a giant cell tumour. A MRI scan was also performed to delineate the mass and further elucidate its nature. The scans demonstrated a high signal lesion, suggestive of either a giant cell tumour or diffuse tenosynovitis. In view of these findings, and the decreased range of movement resulting from the mass, it was decided to proceed with surgical excision under general anesthetic.

A Brunner's incision centered over the palpable fullness was used for exposure. No lesion was initially evident superficial to the flexor tendons. The skin incision was extended to the distal palmar crease proximally and the level of the A4 pulley distally, followed by a longitudinal incision through the A3 pulley. This revealed a soft tissue mass originating from the posterior aspect of the flexor sheath deep to the flexor tendons. The irregular-shaped tumour was directly overlying the proximal phalanx and PIP joint. Dissection of the mass from the overlying tendons was commenced distally. The A1 pulley had to be divided in order to allow dissection of the mass proximally. Complete excision of the tumour was carried out with preservation of the digital neurovascular bundles, the flexor tendons and the A2 pulley.

Histopathological examination of the mass demonstrated a relatively ill-defined spindle cell and fibrocollagenous lesion with prominent blood vessels, hyaline fibrosis and occasional foci with storiform patterns. The spindle cells lacked significant atypia, and no giant cells were seen. These appearances were consistent with a benign fibroma of the tendon sheath.

Hand therapy was started five days post-operatively to improve range of motion. On surgical follow-up four weeks post-op, the boy had complete functional recovery and a painless full range of movement at the metacarpophalangeal joint and interphalangeal joints. At 9 months post-operatively he still had full range of movement with no evidence of recurrence.

## DISCUSSION

This case was unusual both in terms of the histological nature

as well as the position of the tumour. Fibromatous conditions of the paediatric hand are not common and must be kept in mind. Very rare conditions such as juvenile fibromatosis can occur in children's hands too and these may need both medical and surgical intervention and their location can be diverse. Though this case was a simple benign and non-aggressive lesion, it does alert the surgeon to the need to consider other diagnoses besides the common ones. Due to the intricate dissection required in this case, we would recommend that either a regional or general anesthetic is planned if there is a chance that the lesion may be lying under the flexor tendons, as a simple ring block with a digital tourniquet would not be satisfactory.

Sub-flexor lesions are rarely encountered and a review of the literature revealed only one similar case, described by [2] in 2004, in a 25 year old female, and none in children. Such tumours require careful dissection to ensure complete excision and consequently reduce the risk of recurrence. In this case, a fine balance between excessive surgical dissection and protection of the delicate flexor mechanism had to be achieved to ensure clearance of the mass.

Clinicians should be aware of this possible diagnosis. Knowledge of the possible sub-flexor location of such lesions can also aid the hand surgeon with pre-operative planning and accurate patient consent.

## REFERENCES

1. Buxton St. J. D. Tumours of tendon and tendon sheaths. *Br J Surg*. 1923; 10: 469-474.
2. Millon SJ, Bush DC, Garbes AD. Fibroma of tendon sheath in the hand. *J Hand Surg Am*. 1994; 19: 788-793.
3. Al-Qattan MM. Fibroma of tendon sheath of the hand: a series of 20 patients with 23 tumours. *J Hand Surg Eur*. 2014; 39: 300-305.
4. Chung EB, Enzinger FM. Fibroma of tendon sheath. *Cancer* 1979; 44: 1945-1954.

### Cite this article

Hili S, Allan A, Horwitz M (2015) Subtendinous Fibroma of the Flexor Sheath in a Fifteen-Year Old Boy Presenting as a Painful Swelling of the Finger. *Ann Orthop Rheumatol* 3(4): 1060.