

## Case Report

# The Painful Limb in a Child

Mohamed Mohamed\*, Rohit Singhal, Jamie Howie and Eugene Toh

Department of Surgery, Trauma and Orthopaedics, Southport District General Hospital, England, Southport

\*Corresponding author

Mohamed Mohamed, Southport General District Hospital, England, Tel: 01-704 704-925; Email: Mohamed.mohamed5@nhs.net

Submitted: 16 February 2016

Accepted: 01 April 2016

Published: 04 April 2016

Copyright

© 2016 Mohamed et al.

OPEN ACCESS

Keywords

- Limping child
- Stress fractures
- Malignancy
- Infection

## Abstract

Stress fractures are an uncommon injury in children and often present diagnostic dilemmas. They may have features both clinically and radiologically in common with infection and malignancy. Early suspicion is critical in order to eliminate the need for invasive investigations, incorrect treatment and distress to both child and parent. We report the case of a 12 year old boy who presented with unilateral leg pain and subsequently diagnosed with bilateral proximal tibial stress fractures and a unilateral proximal fibula stress fracture. Stress fracture is an uncommon diagnosis in children thus it is important to maintain a high index of suspicion and if necessary to investigate for and exclude the possibility of more sinister pathologies such as infection or neoplasm.

## ABBREVIATIONS

MRI: Magnetic Resonance Imaging; ESR: Erythrocyte Sedimentation Rate; CRP: C Reactive Protein; FBC: Full Blood Count

## INTRODUCTION

Stress fractures in children whilst rare are becoming more prevalent as children participate in sports at an increasingly elite level and at a younger age. The pain is not usually severe and as a result their presentation to the orthopaedic department is often delayed. Missing a stress fracture in a lower extremity especially in long bones could be detrimental due to the risk of displacement, chronic pain and pseudarthrosis.

Stress fracture is an important differential diagnosis in children presenting with bone pain. Lower limbs are the main site, particularly the tibia, proximal fibula and metatarsals [1]. Due to the very rapid periosteal new-bone response, the diagnosis is challenging in the paediatric population and differential diagnoses that must be excluded include osteoid osteoma, acute osteomyelitis, chronic sclerosing osteomyelitis, osteogenic sarcoma, Ewing's sarcoma and acute leukaemia [2].

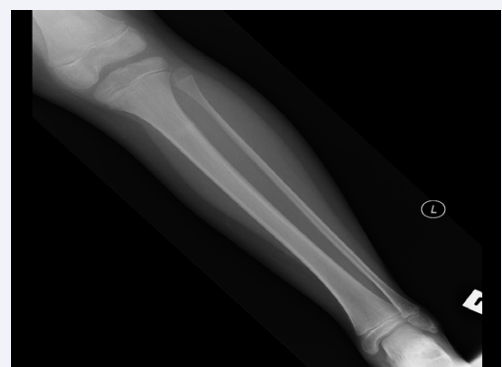## CASE PRESENTATION

A 12 year old Caucasian male child presented to the orthopaedic outpatient clinic with a two month history of right leg pain. This was exacerbated by weight bearing, exercise and the pain gradually worsened with time. There was no specific history of trauma or significant change in physical activity. The child was not overly athletic but did participate in physical education lessons in school. His mother was concerned because he had started to walk with an antalgic gait and was no longer able to participate in physical education lessons due to the pain. The pregnancy and birth were uneventful and he met all his developmental milestones. There was no family history of

bone, joint or growth abnormalities. The patient did not have any systemic features of concern such as weight loss, night sweats or lethargy.

On examination the patient appeared healthy and his height, weight and body mass index (BMI) were appropriate for his age. Further examination of his hips, knees and ankles were normal. There was an area of point tenderness overlying the right proximal tibia which was described as 7/10 pain. There was no overlying swelling or skin changes. Examination of his contralateral limb was entirely normal.

Initial radiographs of the tibia and fibula demonstrated a mildly sclerotic band in the proximal left tibia, potentially indicative of stress fracture (Figure 1). Following this magnetic resonance imaging (MRI) of the lower limb was performed to confirm the diagnosis and exclude more sinister pathologies. MRI of the tibia and fibula demonstrated high signal changes within the proximal tibia in the meta-diaphyseal region with evidence of some cortical thickening and linear low signal areas seen in



**Figure 1** Initial radiograph demonstrating a lack of clarity of a small area of the lateral cortex of the proximal tibia, associated with an impression of a mildly sclerotic horizontal band.

the posterior margin of the cortex in both the proximal tibia, suggestive of a degree of periosteal reaction. This did not involve the soft tissues, and could represent secondary changes to stress fracture. A focal area of change was seen in the proximal fibula on the right which could be related to stress fracture (Figure 2). In addition to this the patient had routine blood tests including bone profile, erythrocyte sedimentation rate (ESR), c-reactive protein (CRP), full blood count (FBC), renal and liver profile and vitamin C and D levels all of which were normal.

Due to ongoing pain the patient was placed into a Sarmiento cast whilst awaiting repeat MR imaging and allowed to weight bear as tolerated. Following a month in the Sarmiento cast the patient was given a Beckham boot; however he chose not to wear this as his pain settled. Follow up MRI at 3 months advised by the radiologist showed that the stress fractures had healed as there was no evidence of marrow oedema (Figure 3).

He was followed up in the orthopaedic clinic for a total of 8 months. Four months since initial presentation to the

orthopaedic department the patient remained pain free and well however underwent a further MRI scan of his lower limbs to ensure no other pathology was present and to ensure that the stress fractures had healed.

## DISCUSSION

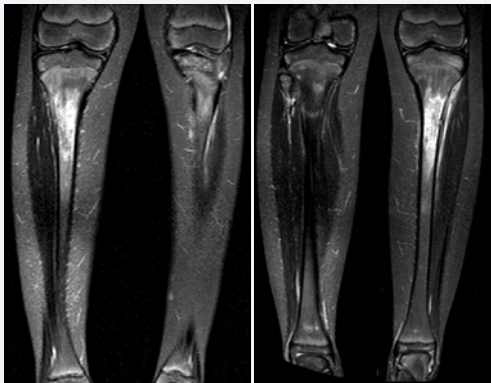
Stress fractures in children are rare. The pain is not usually severe and as a result children present to the orthopaedic department after some delay. Initial radiographs do not usually reveal gross pathology and careful examination is required often producing tenderness but not swelling around the area of the fracture. Missing a stress fracture in lower extremity especially in long bones could be deleterious due to the risk of displacement, pseudoarthrosis and chronic pain. Initial radiographs are often inconclusive and further imaging is recommended. Due to the very rapid periosteal response in the paediatric population and radiographic appearance this has differential diagnosis should exclude osteoid osteoma, acute osteomyelitis, chronic sclerosing osteomyelitis, osteogenic sarcoma, Ewing's sarcoma and acute leukaemia. Therefore it is important to undertake further imaging to further evaluate the lesion and to exclude malignancy. MRI is sensitive in the detection of subtle osteochondral and non-displaced fractures. Computed tomography (CT) scanning usually shows increased bone marrow density, endosteal and periosteal new bone formation and soft tissue oedema [3]. However, CT scanning may rarely show fracture lines that are not seen on plain radiography and due to the high radiation dose is not the first line investigation [4].

Risk factors for the development of stress fractures include the type of sport, changes of physical routine, skeletal abnormalities such as bone mass, bone structure and leg length discrepancy, which can alter the load on the bones [5]. The most commonly involved cortex of the shaft of the tibia was the posteromedial cortex [6]. In adults, the proximal tibia stress fracture described invariably involves the anteromedial metaphysis [7]. It seems that in the skeletally immature population the tibial stress fracture pattern is different [8]. The different site of cortex involvement between children and adults may represent fatigue of different muscle groups during exercise.

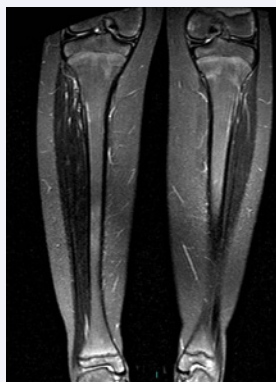The treatment of stress fractures consists of avoidance of weight bearing. After the full range of motion without pain is achieved, weight bearing is gradually reinstated as tolerated by the patient. Cast immobilisation is used for patients in whom weight bearing cannot be controlled. If the condition is untreated, pseudoarthrosis and chronic pain is likely to develop [9]. Due to the high turnover of bone and rapid remodelling seen in the paediatric population, periods of immobilisation are not as extensive as in adults.

## REFERENCES

1. Greaney RB, Gerber FH, Laughlin RL, Kmet JP, Metz CD, Kilcheski TS, et al. Distribution and natural history of stress fractures in U.S. Marine recruits. *Radiology*. 1983; 146: 339-346.
2. Warden SJ, Burr DB, Brukner PD. Stress fractures: pathophysiology, epidemiology, and risk factors. *Curr Osteoporos Rep*. 2006; 4: 103-109.
3. Horev G, Korenreich L, Ziv N, Grunebaum M. The enigma of stress



**Figure 2** Initial MRI STIR sequence demonstrating a high signal changes seen within the proximal tibia in the metadiaphyseal region with evidence of some cortical thickening and linear low signal areas seen in the posterior margin of the cortex in both the proximal tibia, suggestive of a degree of periosteal reaction. No soft tissue component. There is also a focal area of change seen in the proximal fibula on the right which could be related to stress fracture.



**Figure 3** MRI at 3 months follow up demonstrating resolution of the marrow oedema in the proximal right tibial metaphysis. A little residual oedema persists in the proximal left tibial metaphysis.

- fractures in the pediatric age: clarification or confusion through the new imaging modalities. *Pediatr Radiol.* 1990; 20: 469-471.
4. Tyrrell PN, Davies AM. Magnetic resonance imaging appearances of fatigue fractures of the long bones of the lower limb. *Br J Radiol.* 1994; 67: 332-338.
  5. Bennell KL, Malcolm SA, Thomas SA, Reid SJ, Brukner PD, Ebeling PR, et al. Risk factors for stress fractures in track and field athletes. A twelve-month prospective study. *Am J Sports Med.* 1996; 24: 810-818.
  6. Snyder RA, Koester MC, Dunn WR. Epidemiology of stress fractures. *Clin Sports Med.* 2006; 25: 37-52.
  7. Milgrom C, Finestone A, Segev S, Olin C, Arndt T, Ekenman I. Are overground or treadmill runners more likely to sustain tibial stress fracture? *Br J Sports Med.* 2003; 37: 160-163.
  8. Bennell KL, Brukner PD. Epidemiology and site specificity of stress fractures. *Clin Sports Med.* 1997; 16: 179-196.
  9. Speed CA, Fordham JN, Cunningham JL. Simultaneous bilateral tibial stress fractures in a 15-year-old milkman--a case report. *Br J Rheumatol.* 1996; 35: 905-907.

**Cite this article**

Mohamed M, Singhal R, Howie J, Toh E (2016) *The Painful Limb in a Child.* *Ann Orthop Rheumatol* 4(2): 1066.