

## Case Report

# Preliminary Results of Treatment of Early Onset Scoliosis Using Magnetic Growing Rods

Cornelius Wimmer<sup>1,2,3</sup>, ElsayedShaheen<sup>4</sup>, Thomas Pfandlsteiner<sup>1</sup>, and Ahmed Ezzat Siam<sup>1,5</sup>

<sup>1</sup>Department of Spinal Surgery and Scoliosis Center, Schön Klinik Vogtareuth, Germany

<sup>2</sup>Private Medical University (PMU), Austria

<sup>3</sup>University Hospital, Austria

<sup>4</sup>Department of Orthopedics and Traumatology, Al Azhar University, Egypt

<sup>5</sup>Spine Unit, El Hadara University Hospital, Egypt

**\*Corresponding author**

Cornelius Wimmer, Department of Spinal Surgery and Scoliosis Center, Schön Klinik Vogtareuth, Krankenhausstrasse 20,83569 Vogtareuth, Germany, Email: profwimmer@t-online.de

Submitted: 13 June 2016

Accepted: 30 December 2016

Published: 02 January 2017

**Copyright**

© 2017 Wimmer et al.

**OPEN ACCESS****Keywords**

- Scoliosis
- EOS
- Neuromuscular scoliosis
- Magnetic rod
- Growing rod
- MCGR

**Abstract**

**Purpose:** Reporting preliminary results of MCGR.

**Study design:** A prospective uncontrolled, single-center, single-surgeon, clinical and radiological study

**Patient sample:** Between November 2012 and March 2015, 14 children with EOS were treated using MCGR

**Outcome measures:** Preoperative, postoperative and final follow-up (FFU) whole spine radiographs were reviewed to determine the degree of spinal deformity and correction, measured using Cobb angle. T1-S1 length was calculated. Clinical notes to determine number of rod lengthening procedures using remote control device and to record any complications during surgery or FU period.

**Methods:** Mean age was 12.1 years, 2 boys and 12 girls, nine children had primary correction by MCGR; five of them had neuromuscular, three infantile and one congenital scoliosis. All had a dual MCGR implanted. The remaining five patients had previously undergone other growing rod operation before converting to MCGR implant.

**Results:** Mean pre-operative Cobb angle of the primary group was 73.4°, postoperative 34.8° (51.3% correction), FFU 28.8°. Mean initial percentage of the lengthening was 18.4%. Thoracic kyphosis changed significantly from preoperative mean of 48.7° to 31.2° postoperatively (p=0.008). Of the revision group, mean pre-operative Cobb angle was 49.6°, postoperative 41.1° (16.5% correction) and 40.3° at FFU. Mean initial percentage lengthening was 6.9%. One patient had wound infection, two had pull-out of proximal screws, one sustained a breakage of a single-rod construct 6 months after surgery and was replaced by a double magnetic-rod construct.

**Conclusions:** In our consecutive series of patients treated with MCGR we found that scoliosis was well controlled. Cobb angle was significantly reduced following surgery in patients who had MCGR performed as a primary procedure. Generally, the correction was maintained at FFU. Comparing our results for MCGR and other growing rod techniques, they are comparable, without need to repeated surgery.

**INTRODUCTION**

Early-onset scoliosis (EOS) has been defined as significant spinal deformity beginning before the age of 7 years [1]. It may be infantile idiopathic, congenital or neuromuscular [2]. If untreated, it leads usually to cosmetic disfigurement and pulmonary insufficiency [3]. The goals of treatment are to control the deformity, allow growth of the spine and chest wall and to improve pulmonary function. Bracing is commonly used for early intervention, but it is not effective in many cases [4-7].

Harrington [8] recommended distraction instrumentation without fusion for children less than ten years of age to allow continuous spinal growth. Moe et al. [9], popularized

instrumentation without fusion and included periodic lengthening to achieve deformity correction and spinal growth.

Fusion procedures in this age group adversely affect spinal growth and pulmonary alveolar development that can lead to thoracic insufficiency. The main disadvantage of traditional growing rod systems is the requirement for multiple surgical procedures to lengthen the rods as the patient grows [10]. These operations have high rates of complications including wound infection, rod breakage, anchor failure or prominence of the implant [11,12].

With technological advances over recent years, magnetically controlled growing rod systems (MCGR) have been developed

to address the drawbacks of traditional systems, allowing lengthening procedures to be performed in one-day clinic under control of an externally applied magnet remote control device. Recently, this technology has been reported to be safe and effective at short-term follow-up (FU) [13-15].

We are reporting our preliminary results of a magnetically controlled growing rod (MCGR), which eliminates the need for repeated surgical procedures and anesthesia.

## PATIENT AND METHODS

Between November 2012 and March 2015, 14 children with EOS were treated in a single institution using MCGR with prospective collection of data. The inclusion criteria were EOS of different etiology, failed operative treatment, failed non-operative treatment with bracing or observation and progression of the curvature. Patients with pace maker or expected to require MRI, younger than two years old or weighing less than 11.5 kg have been excluded. Informed consent has been signed by one or both parents of every child to be included in this prospective study. All procedures were done in accordance with ethical standards of Helsinki Declaration.

Preoperative, immediate postoperative and final follow-up (FFU) whole spine radiographs were assessed to determine the degree of spinal deformity and correction, measured using Cobb angle. Routinely, radiographs have been done of the whole spine in standing position, or in sitting, when standing was not possible by the patient, in addition to a fulcrum bending view at the apex of the primary curve. This view was done only in the patients without prior surgical treatment (primary implantation). Fulcrum flexibility and flexibility-bending correction index (FBCI) have been calculated as described by Luk et al. [16]. T1-S1 length was calculated on anteroposterior (AP) views. Clinical notes to determine number of rod lengthening procedures using remote control device and to record any complications during surgery or FU period. All images were measured by three individuals. Any discrepancy in measurement values was discussed and a final measurement was agreed by consensus. Growth rates were calculated based on the T1-S1 increase in length between postoperative and FFU radiographs.

The mean age of the children included in the series was 12.1 years (6.2-15.8). There were two boys and 12 girls. Skeletal maturity was assessed using Risser staging [17] and by evaluating the triradiate cartilage. All operations were performed by the senior author (CW). Nine children had primary correction by MCGR; five of them had neuromuscular scoliosis, three had infantile scoliosis and one child had congenital scoliosis. All have a dual MCGR implanted.

The remaining five patients had previously undergone VEPTR (vertical expandable prosthetic titanium rib) or growing rod operation before having an MCGR implant. The change to MCGR was considered in children who had significant remaining growth potential (Risser 0-I) and having problems with traditional growing rods and/or repeated surgical distraction. Three of these children had neuromuscular scoliosis. A dual MCGR construct was implanted for two cases and single rod for one case. The other two cases had infantile scoliosis.

The MCGR implant is made of titanium and includes a telescopic actuator portion that holds a small internal magnet. Rotation of the magnet, by the use of remote control, causes the rod to lengthen or shorten. The levels of implantation and fixation were determined by the type of curve and the underlying pathology with the proximal fixation being usually at the level of T2-T4 and the distal instrumentation at the neutral vertebra. In severe neuromuscular cases, distal instrumentation was continued to the pelvis using iliac screws.

## SURGICAL PROCEDURE AND FOLLOW-UP PROTOCOL

Under general anesthesia, with the patient prone, and routinely with intra-operative neuromonitoring, two separate posterior proximal and distal skin incisions were made over the foundation levels. In the revision cases we used the whole length of the previous scar to remove the previous metalwork and to implant the MCGR. A subperiosteal dissection was performed and the proximal and distal anchor sites prepared. A combination of hooks and pedicle screws were used as anchors. The magnetic rods (MCGR Ellipse technology, Irvine, California) were contoured, tested and inserted submuscular either as a single-rod or a dual-rod construct. Local bone graft was used at the exposed foundation levels to achieve a limited fusion and stability at the anchor sites. The distractions were performed by an electrically powered remote controller. The remote control was placed externally over the patient's spine at the level of the actuator portion of the rod, which contained a magnet. The magnetic field from the latter was identified using an external magnet that was attracted to the rod magnet. When activated, the external remote control causes the magnet of the implanted device to rotate. The spinal distractions were performed on a one-day inpatient procedure basis without the need for anesthesia or analgesia. Each patient was given an appointment at four-month intervals for distraction. In general, the spine was distracted by about 10 mm every 4 months with the aim to do this at a faster rate than the predicted spinal growth to allow for better curve correction. All distractions were done by one surgeon (CW) and the procedure itself lasted less than one minute.

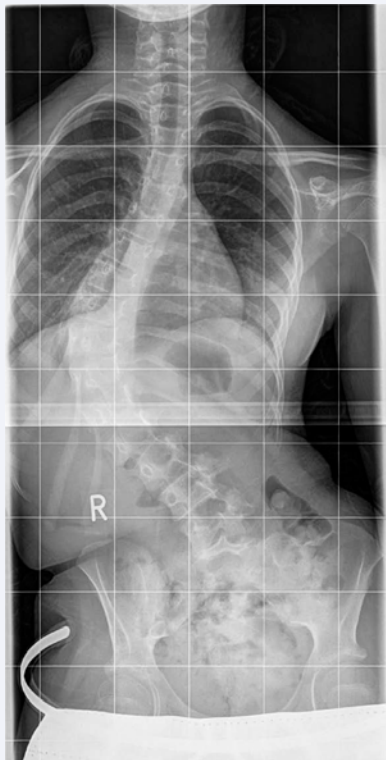
## STATISTICAL ANALYSIS

Descriptive statistics (mean, minimum, maximum and standard deviation) have been used to summarize numerical variables related to the patients and radiographic measurements, when appropriate. Comparison of the pre-operative and post-operative Cobb angles and the distance between T1 and S1, was evaluated using a non-parametric test (Wilcoxon Signed Rank Test). The statistical analysis has been calculated using SPSS v.13.0 software (IBM, Armonk, New York). A p-value <0.05 was considered statistically significant.

## RESULTS

### Patients with primary implantation of MCGR

This group included nine patients, three of them have not received any distractions yet. These were excluded from the statistics of the FFU. A total of 11 distractions have been performed. Mean pre-operative Cobb angle was  $73.4^{\circ} \pm 18.75^{\circ}$  ( $42^{\circ}$  -  $100^{\circ}$ ) (Figure 1), after fulcrum bending  $32.9^{\circ} \pm 6.95^{\circ}$  ( $24^{\circ}$



**Figure 1** Preoperative standing radiograph of a patient with infantile scoliosis of 68° Cobb angle, spinal length T1-S1 346 mm.

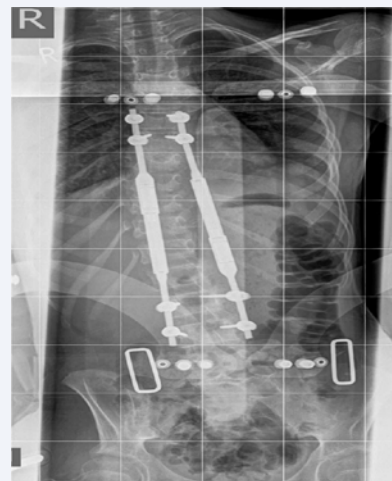-40.5°) and immediate postoperative Cobb angle of 34.8° ± 11.29° (15° -55°) (Figure 2), with a statistically significant difference (p=0.008) (51.3 % correction). Mean FBCI was 99.2%. Mean Cobb angle at FFU was 28.8° ± 8.47° (15° - 40°) (Figure 3). The change between direct postoperative Cobb angle to that at last FU was not statistically significant (p=0.279) (Table 2). Mean initial percentage of the lengthening was 18.4% (7.4-29.9%). Mean T1-S1 length for primary procedures was 332 ± 42.93mm, increasing to 391.3 ± 40.03 mm postoperatively (p=0.008) and 419.7 mm at final FU (Table 2). Mean spinal growth rate was 15.1 mm/year. Thoracic kyphosis changed significantly from preoperative mean of 48.7° ± 14.21° to 31.2° ± 9.36° postoperatively (p=0.008). At last FU, the mean thoracic kyphosis increased in this group to 36.6° ± 21.42° (p=0.345, no statistically significant loss of correction)

### Patients with secondary conversion to MCGR

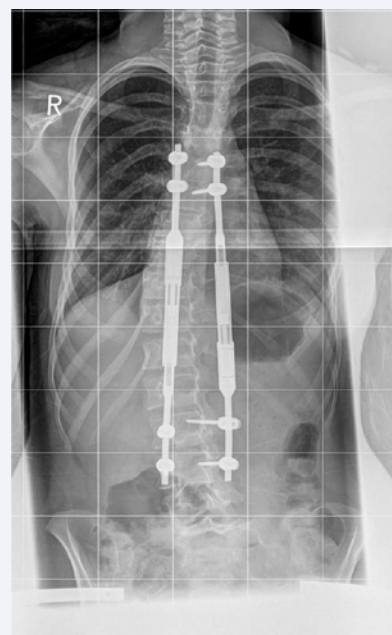This group included five patients, all with a minimum of one distraction. A total of 22 distractions have been done. Mean pre-operative Cobb angle was 49.6° ± 22.42° (17°-77°), with immediate postoperative Cobb angle of 41.1° ± 17.87° (12.1° - 68°) (16.5% correction). This was also statistically significant in this group (p=0.042). Mean Cobb angle at FFU was 40.3° ± 15.74° (18° - 60°) (Table 2). Mean initial percentage lengthening was 6.9 % (2.3-28.8). Mean T1-S1 length was 353.6mm, increasing to 380mm postoperatively (p=0.043) and a mean of 402mm at FFU (Table 2). One child has undergone final fusion surgery after two distractions. Excluding the case of proximal junctional kyphosis (PJK), the mean spinal growth rate was 7.5 mm/year.

### Complications

Within a mean FU period of 9.5 months, there were three complications in patients who had MCGR as a primary procedure (Table 1); one patient developed wound infection that was successfully treated with debridement and parenteral antibiotics. Two patients had pull-out of proximal screws 3 weeks and 8 months postoperatively. In the patients who had MCGR as a revision procedure there were two complications. One patient sustained a fracture of a single-rod construct 6 months after surgery and was converted to a double magnetic rod construct. The other case was already complicated with PJK after treatment by VEPTR. The same problem occurred again after conversion to MCGR. This led at the end to shortening of spinal length and



**Figure 2** Postoperative radiograph after treatment with MCGR. Cobb angle is 15° (correction 78%), initial lengthening of 12%.



**Figure 3** Radiograph at FFU (13 month) with Cobb angle of 15° and spinal length of 405 mm.

**Table 1:** Patients demography, type of scoliosis and surgery.

Patient	Age	Sex	Diagnosis	Group	Fixation level	Distractions	FBCI	Complications
1	10.6	f	Infantile	Revision	T4-L2	2	-	Proximal junctional kyphosis
2	13	f	Congenital	Primary	T2-L1	2	121.43	
3	10.1	f	Neuromuscular	Primary	T6-Ilium	3	88.7	
4	13.5	f	Infantile	Revision	T4-11	2	-	
5	13.4	f	Infantile	Primary	T4-L1	1	94.9	
6	15.8	m	Neuromuscular	Revision	T5-L3	4	.	
7	12.7	m	Neuromuscular	Primary	T3-L1	1	83.7	Pull-out of proximal screws
8	13	f	Infantile	Primary	T6-L3	3	132.8	
9	13.6	f	Infantile	Primary	T4-L3	1	137.7	Pull-out of proximal screws
10	10.1	f	Neuromuscular	Primary	T1-L5	0	74.9	Wound infection
11	13.5	f	Neuromuscular	Revision	T3-L3	2	-	Rod breakage
12	6.2	f	Neuromuscular	Revision	T3-Ilium	1	-	
13	9.4	f	Neuromuscular	Primary	5th rib (VEPTR) - Ilium	0	76.9	
14	14.8	f	Neuromuscular	Primary	T6-L5	0	81.4	

**Abbreviations:** FBCI: Fulcrum Bending Correction Index; VEPTR: Vertical Expandable Prosthetic Titanium Rib.

**Table 2:** different radiographic measurements of the patients at different stages of the treatment.

Patient	Cobb angle				Thoracic kyphosis T1-T12			Spinal length T1-S1 (mm)			
	Preoperative	Postoperative	Correction (%)	Last FU	Preoperative	Postoperative	Last FU	Preoperative	Postoperative	Lengthening (%)	Last FU
1	68.8°	52.6°	16.2° (23.5)	45°	79°	73°	80°	288	328	40 (13.9)	313
2	42°	25°	17° (40.5)	24°	66.3°	25°	42°	379	414	35 (9.2)	421
3	100°	32.6°	67.4° (67.4)	31°	24°	17°	4°	357	400	43 (12)	412
4	17°	12.1°	4.9° (28.8)	18°	67.1°	45.7°	66°	468	489	21 (4.5)	491
5	70°	42°	28° (40)	40°	48°	23°	34°	328	426	98 (29.9)	434
6	44.6°	36.9°	7.7° (17.3)	43°	56.9°	47.2°	62.6°	349	357	8 (2.3)	379
7	57.2°	37.2°	20° (35)	31°	65.2°	50°	71°	378	406	28 (7.4)	414
8	68°	15°	53° (77.9)	15°	50°	36°	35°	346	388	42 (12.1)	405
9	80°	30°	50° (62.5)	32°	54°	33°	33.5°	343	428	85 (24.8)	432
10	100°	55°	45° (45)	-	32°	29.5°	-	314	379	65 (20.7)	-
11	72.7°	56.3°	16.4° (22.6)	55°	76.7°	41.9°	35.6°	375	418	43 (11.5)	425
12	45°	48.6°	-3.6° (-8)	-	35.1°	34°	-	288	307	19 (6.6)	-
13	73°	41°	32° (43.8)	-	42°	33°	-	240	295	55 (22.9)	-
14	70°	35°	35° (50)	-	57°	34°	-	306	386	80 (26.1)	-

increase in thoracic kyphosis, but no loss of scoliosis correction. No complications occurred during or immediately after distraction procedures.

## DISCUSSION

Treatment of children with early onset scoliosis should focus not only on the spinal deformity but also on the growth of the chest wall and development of the lungs. If surgical correction is required and fusion is performed before completion of growth,

the child is left with a short trunk and a disproportionate body habitus. This may adversely affect lung development and result in respiratory insufficiency in the very young [8,18]. There is also a possibility of developing further deformity from the 'crankshaft' phenomenon [8,18].

This is a report of preliminary results of the relatively new technique of MCGR. In our consecutive series of patients treated with MCGR we found that scoliosis was well controlled. Cobb angle was significantly reduced following surgery in patients



who had MCGR performed as a primary procedure and this was maintained at FFU. The mean FBCI in this group of patients was 99.2%. This result is comparable to those reported by Luk et al. [19], who compared four different instrumentation systems with FBCI of 101, 103.5, 109.1 and 100.2%. For patients who had MCGR used as a revision procedure, Cobb angles were also maintained at FFU. Dannawi et al. [15], reported 32 % improvement in Cobb angle, compared with our initial correction of 43 %. Akbarnia et al. [13], also found a 43% improvement in Cobb angle following surgery in 14 patients who had MCGR performed as a primary procedure [13,15] and Cheung et al [14] who achieved 57% correction.

In comparison with the recent literature, T1-S1 initial lengthening was higher in our patients who had MCGR as a primary procedure. Our mean initial lengthening was 18.4%, compared with between 5.4 and 10 % reported by other studies using MCGR [13-15]. The mean initial T1- S1 lengthening in our patients who had MCGR as a revision procedure was 6.9%. The mean subsequent annual growth rate in our group of patients was more than anticipated in comparison with recent literature (15.1 mm/y). Considering the mean age of patients in our primary procedure group was 12.2 years, we would expect their annual spinal growth to be 10-12 mm/y [20]. Patients who had MCGR performed as a revision procedure were a little younger (mean age 11.9y) and their annual spinal growth rate is much less (7.5mm/y) according to age and also in comparison with patients of similar ages who have had MCGR rods in other studies [20]. Dannawi et al. [15], reported spinal growth rates of 10 mm/year and Cheung et al. [14], reported 15 mm/year.

The obvious benefit of the magnetic growing rod system is that repeat operations to perform rod lengthening are avoided, which is one of the main drawbacks of growing rods [3]. This is particularly useful in patients with high risk of complications from general anesthesia, such as respiratory tract infection [21]. In our study, only one of 14 patients developed a wound infection, which is better than any conventional growth rod series [11,21].

Implant-related complications such as rod fracture, anchor failure or prominence of the implant, were the most frequent complications in one series of growth rods [22]. Rod fractures are inevitable with non-fusion techniques. Yang et al. [23], identified several risk factors that increased the probability of rod breakage in a multicentre analysis of 322 patients with growing rods. These were single-rod constructs, rods of smaller diameter, stainless steel rods and ambulatory patients. By contrast, Thompson et al. [24], showed a higher rate of rod fracture in the dual-rod group despite the perceived greater stability provided by the construct. Klemme et al. [25], reported 33 implant-related problems in 25 patients (37%) including one death during rod exchange through a subfascial tunnel when the rod was deflected and transgressed the retroperitoneal space and thorax. In our study, there was one rod breakage in 14 patients, a lower incidence than that reported in conventional growing-rods [22], yet our FU was shorter. This case of rod breakage occurred in a patient with a progressive double curve and was primarily treated with a single rod. This resulted in increased the stress and bending moments on the rod and subsequent rod breakage. Importantly, it is well documented that the rate of complications increases in relation to the number

of surgical procedures performed. Yang et al. [23], reported, in 15 % of patients treated with traditional growing rods and as we found in our case of fracture it is more likely to occur in ambulant patients with single-rod constructs. In the series by Bess et al. [11], rod fracture occurred in 24 % of patients. Screw pullout occurred in two of our patients. This patient had a preoperative kyphosis and initial correction of coronal and sagittal balance was achieved; however, proximal fixation with screws failed and was revised to a hook construct.

Similar to other scoliosis corrections, we had a case of PJK. This was originally a complication of former treatment by VEPTR. The same problem occurred again after conversion to MCGR. This led at the end to shortening of spinal length and increase in thoracic kyphosis, but no loss of scoliosis correction. No complications occurred during our 22 distraction sessions, confirming the safety and simplicity of this procedure.

The main limitation of the MCGR procedure is potential increased radiation exposure from frequent radiographs. Although radiographic evaluation is important to ensure adequacy of control of scoliosis and also to detect implant related complications such as loss of distraction [14]. With further evaluation of magnetic growing rod technology the optimum interval for radiographic evaluation is likely to become apparent. Improving our understanding of the relationship between predicted and actual rod distraction lengths and the significance of partial loss of distraction may result in fewer radiographs being performed. Despite the small number of cases, this study represents an early experience with this new technology with a considerable complication rate. These complications may be prevented after establishment of this treatment method.

## CONCLUSION

In our consecutive series of patients treated with MCGR we found that scoliosis was well controlled. Cobb angle was significantly reduced following surgery in patients who had MCGR performed as a primary procedure. Generally, the correction was maintained at FFU. Comparing our results for MCGR and other growing rod techniques, they are comparable, without need to repeated surgery. The limitation of the study is the short follow up and relative small number of patients.

## REFERENCES

1. Akbarnia BA, Marks DS, Boachie-Adjei O, Thompson AG, Asher MA. Dual growing rod technique for the treatment of progressive early onset scoliosis: a multicenter study. *Spine*. 2005; 30: 46-57.
2. Campbell RM Jr, Smith MD. Thoracic insufficiency syndrome and exotic scoliosis. *J Bone Joint Surg Am*. 2007; 89: 108-122.
3. Campbell RM Jr, Smith MD, Mayes TC, Mangos JA, Willey-Courand DB, Kose N, et al. The characteristics of thoracic insufficiency syndrome associated with fused ribs and congenital scoliosis. *J Bone Joint Surg Am*. 2003; 85: 399-408.
4. McMaster MJ, Macnicol MF. The management of progressive infantile idiopathic scoliosis. *J Bone Joint Surg Br*. 1979; 61: 36-42.
5. Mehta MH. Growth as a corrective force in the early treatment of progressive infantile scoliosis. *J Bone Joint Surg Br*. 2005; 87: 1237-1247.
6. Robinson CM, McMaster MJ. Juvenile idiopathic scoliosis: curve

- patterns and prognosis in one hundred and nine patients. *J Bone Joint Surg Am.* 1996; 78: 1140-1148.
7. Sponseller PD, Thompson GH, Akbarnia BA, Glait SA, Asher MA, Emans JB, et al. Growing rods for infantile scoliosis in Marfan syndrome. *Spine (Phila Pa 1976).* 2009; 34: 1711-1715.
  8. Harrington PR. Treatment of scoliosis. Correction and internal fixation by spine instrumentation. *J Bone Joint Surg Am.* 1962; 44: 591-610.
  9. Moe JH, Kharrat K, Winter RB, Cummine JL. Harrington instrumentation without fusion plus external orthotic support for the treatment of difficult curvature problems in young children. *Clin Orthop Relat Res.* 1984; 185: 35-45.
  10. Smith JT, Campbell RM Jr. Magnetically controlled growing rods for spinal deformity. *Lancet.* 2012; 379: 1930-1931.
  11. Bess S, Akbarnia BA, Thompson GH, Sponseller PD, Shah SA, El Sebaie H, et al. Complications of growing-rod treatment for early onset scoliosis: analysis of one hundred and forty patients. *J Bone Joint Surg Am.* 2010; 92: 2533-2543.
  12. Farooq N, Garrido E, Altaf F, Dartnell J, Shah SA, Tucker SK, et al. Minimizing complications with single submuscular growing rods: a review of technique and results on 88 patients with minimum two-year follow-up. *Spine (Phila Pa 1976).* 2010; 25: 2252-2258.
  13. Akbarnia BA, Cheung K, Noordeen H, Elsebaie H, Yazici M, Dannawi Z, et al. Next generation of growth-sparing techniques. *Spine.* 2013; 38: 665-670.
  14. Cheung KM, Cheung JP, Samartzis D, Mak KC, Wong YW, Cheung WY, et al. Magnetically controlled growing rods for severe spinal curvature in young children: a prospective case series. *Lancet.* 2012; 379: 1967-1974.
  15. Dannawi Z, Altaf F, Harshavardhana NS, El Sebaie H, Noordeen H. Early results of a remotely-operated magnetic growth rod in early onset scoliosis. *Bone Joint J.* 2013; 95: 75-80.
  16. Luk KD, Cheung KM, Lu DS, Leong JC. Assessment of scoliosis correction in relation to flexibility using the fulcrum bending correction index. *Spine (Phila Pa 1976).* 1998; 23: 2303-2307.
  17. Risser JC. The iliac apophysis: an invaluable sign in the management of scoliosis. *Clin Orthop.* 1958; 11: 111-119.
  18. Karol LA, Johnston C, Mladenov K. Pulmonary function, radiographic measures, and quality of life in children with congenital scoliosis: an evaluation of patient outcomes after early spinal fusion. *Spine (Phila Pa 1976).* 2008; 33: 1242-1249.
  19. Luk KD, Lu DS, Cheung KM, Wong YW. A prospective comparison of the coronal deformity correction in thoracic scoliosis using four different instrumentations and the fulcrum-bending radiograph. *Spine (Phila Pa 1976).* 2004; 29: 560-563.
  20. Dimeglio A, Canavese F. The growing spine: how spinal deformities influence normal spine and thoracic cage growth. *Eur Spine J.* 2011; 21: 64-70.
  21. Wick J, Konze J. A magnetic approach to treating progressive early onset scoliosis. *AORN J.* 2012; 96: 163-173.
  22. Mineiro J, Weinstein SL. Subcutaneous rodding for progressive spinal curvatures: early results. *J Pediatr Orthop.* 2002; 22: 290-295.
  23. Yang JS, Sponseller PD, Thompson GH, Akbarnia BA, Emans JB, Yazici M, et al. Growing rod fractures: risk factors and opportunities for prevention. *Spine (Phila Pa 1976).* 2011; 36: 1639-1644.
  24. Thompson GH, Akbarnia BA, Kostial P, Poe-Kochert C, Armstrong DG, Roh J, et al. Comparison of single and dual growing rod techniques followed through definitive surgery: a preliminary study. *Spine (Phila Pa 1976).* 2005; 30: 2039-2044.
  25. Klemme WR, Denis F, Winter RB, Lonstein JW, Koop SE. Spinal instrumentation without fusion for progressive scoliosis in young children. *J Pediatr Orthop.* 1997; 17: 734-742.

#### Cite this article

Wimmer C, Shaheen E, Pfandlsteiner T, Siam AE (2017) Preliminary Results of Treatment of Early Onset Scoliosis Using Magnetic Growing Rods. *Ann Orthop Rheumatol* 5(1): 1077.