

Case Report

Regulated Negative Pressure Wound Therapy (RNPT) Combined Topclosure in the Treatment of Skin Defect for Open Fracture in Lower Extremity

Zhang Hongwei^{1#}, Wang Chaoyang^{2#}, Sun Jianhua³, DU Xinhui³, Fang Qinzhen³, and Moris Topaz^{4*}

¹School of Medicine, Shihezi University, Shihezi, Xinjiang 832008, China

²Orthopaedic department, First Affiliated Hospital, School of Medicine, Shihezi University, Shihezi, Xinjiang 832008, China

³Plastic Surgery Unit, Hillel Yaffe Medical Center, Hadera, Israel

⁴General Surgery Department, First Affiliated Hospital, School of Medicine, Shihezi University, Shihezi, Xinjiang 832008, China

[#]Zhang Hongwei and Wang Chaoyang contribute the same to this paper

***Corresponding author**

Mori Topaz, Plastic Surgery Unit, Hillel Yaffe Medical Center, Hadera, Department of Chemistry, Bar Ilan University, Ramat Gan, Israel, Tel: 8613070097110; Email: 771336777@qq.com

Submitted: 18 July 2016

Accepted: 20 April 2017

Published: 22 April 2017

Copyright

© 2017 Topaz et al.

OPEN ACCESS**Keywords**

- Regulated negative pressure wound therapy (RNPT)
- TopClosure
- Open fracture
- Skin defect
- Treatment

Abstract

Currently, open fracture in lower extremity is a common trauma, which can easily form the skin defect. If the skin defect become an ulcer or ulcer like wound, the treatments will encounter a sticky situation that is hard to heal. Although skin flap grafting, tissue stretching and expansion can be available in this situation, however, they all have disadvantages, such as time consuming, costly, and difficult to operate, etc.. In this case, we reviewed one novel treatment, RNPT (regulated negative pressure-assisted wound therapy) combined with Topclosure (skin stretching and wound closure-secure system), for an skin defect patient with lower extremity open fracture, which achieved sound outcome.

INTRODUCTION

Open fracture in lower extremity is the common trauma, which can easily form the skin defect if the local treatment goals are not satisfied, including prevention of infection, soft tissue coverage and fracture stabilisation. Fracture stabilisation can be achieved with internal fixation and external fixation, ring fixators, free or vascularized bone grafting along with allografts or bone substitutes [1,2]. The poor blood supply and high tension around the lower extremity wound tissue makes the treatment of the skin defect difficult. Currently, the traditional effective treatment methods are skin flap grafting, tissue stretching and expansion [3]. However, some of these modalities carry several disadvantages: first, complexity or high technical requirements, which limit the use in the treatment of skin defect in the primary hospitals. Second, high cost and long healing time. Third, affected by the surround environment, the flap can get to ischemia and

necrosis, which result in failure of treatment. Now a new method of wound healing, regulated negative pressure-assisted wound therapy (RNPT) combined with TopClosure (an innovative, simple, skin stretching and wound closure-secure system), was employed to treat the skin defect in lower extremity, which got a good result, and now we reviewed this case.

CLINIC DATA

27 year-old male patient, usually in good health, was admitted to hospital in Sept. 16th 2013, 4 hours after a traffic accident. His right lower extremity severely damaged and deformed accompanied by severe hurt and restricted function.

Physical examination showed as follows

Vital signs are stable. A 8 cm long irregular wound was exposed with a large area of contusion surrounded. Right lower

extremity deformed with abnormal movements.

X-ray showed: Right tibiofibula fractures

Primary diagnosis: Right tibiofibula open fractures

TREATMENT SCHEDULE

“Open reduction and locking titanium external skeletal fixation with regular vacuum drainage” was performed on the day the patient was admitted to the hospital. Antibiotic therapy was given to the patient at the same time.

On 29th Sept. The wound unhealed with much exudation. The exudate bacteria culture showed enterococcus faecalis infection. Ulcer like formed on the site of open fracture in the size of 8*5cm, depth 1.5cm. “Chronic ulcer repair” was performed with antibiotic treatment.

On 9th Oct. The wound surface unhealed with much more exudation. “Chronic ulcer repair and vacuum drainage” was performed.

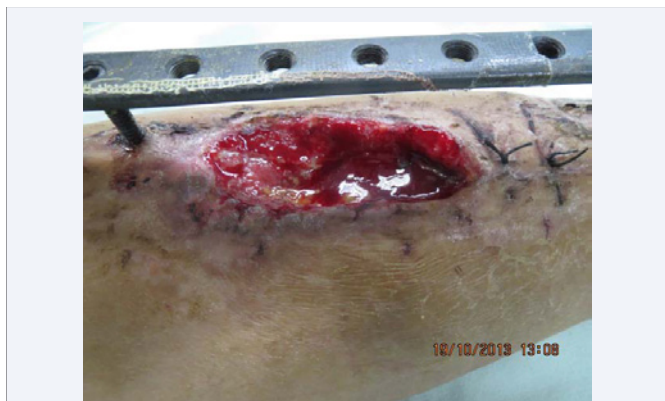

Figure 1 RNPT combined TopClosure before the treatment of right lower extremity chronic ulcer wound. 7cm×4cm×1cm in size, the surface showed relatively fresh with little necrotic tissue and exudation for the vacuum treatment before. However the growth of the wound was slow.

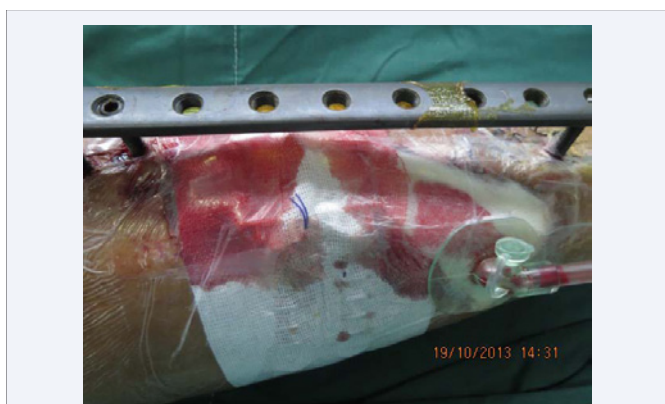

Figure 2 RNPT combined TopClosure when the surgery finished. The long arrow showed the regulated negative disc, which can avoid the secondary damage caused by duct under the vacuum. The short arrow showed the placement for TopClosure.

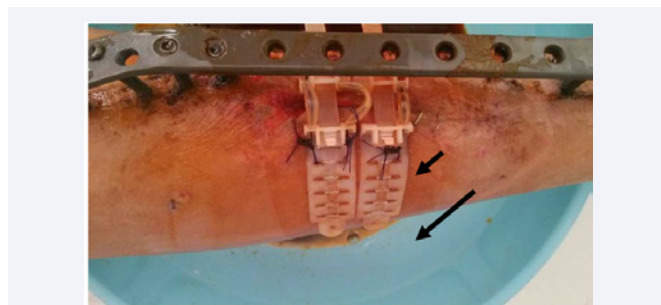


Figure 3 Day 6 after RNPT combined TopClosure treatment. It showed the ulcer totally closed without exudation. The long arrow showed the device of TopClosure. The short arrow showed the mobilizable belt that to adjust the force between two sides of the wound.

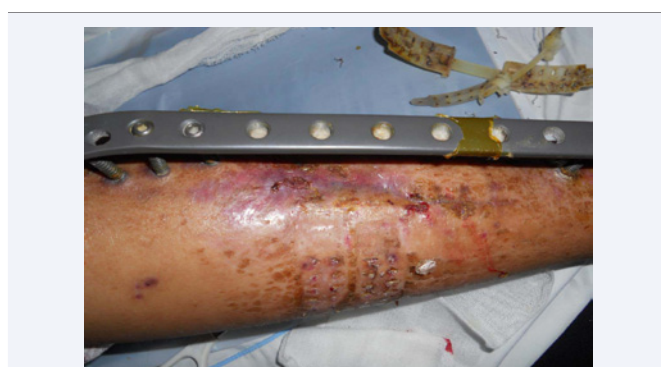

Figure 4 Day 9 after RNPT combined TopClosure treatment. It showed that the wound well recovered with the scab fall down. 2 days later, TopClosure was removed.

On 19th Oct. The wound surface still unhealed, in the size of 7*4cm, depth 1cm. Regulated negative pressure-assisted wound therapy (RNPT) and the TopClosure system (for skin stretching and a secure wound closure) was applied to help wound repair. The open wound nearly closed on the 3rd day after RNPT+ TopClosure surgery; it was totally closed on the 6th day and the scab fallen down on the 9th day.

MAIN DEVICES AND TECHNIQUES

The TopClosure® 3S System [3]: it comprises two attachment plates (AP) that are interconnected by a long, flexible approximation strap (AS). The APs are adhered to the skin by hypoallergenic, biocompatible adhesive on their undersurface for noninvasive application. Multiple pairs of oval openings along the longitudinal axis of the AP were designed for invasive attachment to the skin, using either staples or sutures. The AS links the opposing APs, enabling approximation and advancing the APs by incremental pull on the AS. The AS is completely inserted through the lock/release ratchet mechanism (L/RM) on the proximal AP until being secured by the AS's wings. Next, it is inserted into the L/RM on the opposing AP to allow gradual controlled stretching of the underlying skin. The AS is locked or released by lightly pressing or lifting the L/RM's lever. In this case, the stapler and suture line was used to help stick the plates.

RNPT [4]: the application of preset computer-regulated negative pressure, generated by a pump or wall vacuum, led by tubing to contact with the wound surface by a dressing or a

porous compressible mold sponge covered, and is air-tight sealed by a drape. In this case, the pressure was under 125 mmHg, continuous working model. In this pressure, the granulation tissue formation grew best [5]. The dressing changed every 4 days.

DISCUSSION

Ulcer-like wounds are common in diabetic foot and open fracture, especially when the open fracture happen in the lower extremities [6]. The efficacy of traditional treatments is poor, as the secondary skin ischemic damage can easily occur during the treatments, which can lead to necrosis. In modern, traditional medicine, human recombinant epidermal cell growth factor and hydrocolloid dressings, et al., combined with the vacuum therapy has been widely employed to manage the ulcer wounds. These methods can keep the wound surface in the dry and relatively clean status; however, the closure of the wound is slow. And slower the wound get closed, the higher of the wound infection rate, which goes further is amputation [7-10].

Based on the reorientation of the interwoven network of elastin and mainly collagen fibers provides the skin with the ability to stretch and expand [11,12]. Hirshowitz designed the Sure-Closure[®] skin-stretching system in 1993, which helped primary closure of relatively small- to medium-size skin defects [13]. However, the nature of its invasive, high margin tension that was leading at time to pressure necrosis limited its use [14,15]. Recently, Moris Topaz invented TopClosure skin-stretching system, harnessing the viscoelastic properties of the skin, which eliminate absolutely most of adverse effects of the traditional tension sutures and internal tissue expanders. This innovative device, which highly improved wound healing, can highly promoted the chronic skin defects. During the process of treatment, TopClosure can be adjusted through a mobilizable belt to get right tension for both sides of the wound in an easy way, which can help wound closing. Besides this, the RNPT system was substantially improved by Prof. Topaz to avoid the disadvantages like secondary skin damage, et al, resulted from the local skin ischemia and necrosis, can dramatically accelerate the wound healing [4,16].

RNPT combined TopClosure in the treatment of open wounds has been widely used in Israel, which can shorten treatment time and reduce the dress changing frequency, and achieved good efficacy. However, this wound closure system still need to be studied further with the methods of translational medicine, to further prove its advances and effectiveness.

ACKNOWLEDGMENT

This paper was supported by: Shihezi university high-level personnel launch scientific research project (RCZX201538); Application base research program of Xinjiang Production and Construction Corps (2016AG019). And we really show our appreciation to Prof. Moris Topaz for the selfless assistance in our center.

REFERENCES

1. Maurer RC, Dillin L. Multistaged surgical management of posttraumatic segmental tibial bone loss. *Clin Orthop Relat Res.* 1987; 216: 162-170.
2. Keating JF, Simpson AH, Robinson CM. The management of fractures with bone loss. *J Bone Joint Surg Br.* 2005; 87: 142-150.
3. Moris Topaz, Narin-Nard Carmel, Adi Silberman, Ming Sen Li, Yong Zhong Li. The TopClosure[®] 3S System, for skin stretching and a secure wound closure. *Eur J Plast Surg.* 2012; 35: 533-543.
4. Topaz M. Improved wound management by regulated negative pressure-assisted wound therapy and regulated, oxygen-enriched negative pressure-assisted wound therapy through basic science research and clinical assessment. *Indian J Plast Surg.* 2012; 45: 291-301.
5. Morykwas MJ, Faler BJ, Pearce DJ, Argenta LC. Effects of varying levels of subatmospheric pressure on the rate of granulation tissue formation in experimental wounds in swine. *Ann Plast Surg.* 2001; 47: 547-551.
6. Buchholz J, Mollenhoff G, Reckert M, Muhr G. Chronic venous insufficiency after open tibial fracture. An underestimated problem. *Chirurg.* 2000; 71: 1115-1120.
7. Huang He. Combined traditional Chinese and western medicine in the treatment of 39 cases of chronic ulcer wound. *People's Military Surg.* 2005; 48: 397.
8. Zhu Jianxin, Zhang Yaoming. Application of recombinant human epidermal growth factor on chronic ulcer wound. *Zhongguo Xiu Fu Chong Jian Wai Ke Za Zhi.* 2002; 16: 42-43.
9. Dumville JC, O'Meara S, Deshpande S, Speak K. Hydrogel dressings for healing diabetic foot ulcers. *Cochrane Database Syst Rev.* 2013; 7: CD009101.
10. Jianbing T, Biao C, Jiangting Z, Li Qin, Zhang Bin. A topical negative-pressure technique with skin flap transplantation to repair lower-limb wounds with bone exposure. *Int J Low Extrem Wounds.* 2012; 11: 299-303.
11. Renò F, Traina V, Cannas M. Mechanical stretching modulates growth direction and MMP-9 release in human keratinocyte monolayer. *Cell Adh Migr.* 2009; 3: 239-242.
12. Woo SLY, Gomez MA, Akeson WH. The time and history-dependent viscoelastic properties of the canine visco-elastic characteristics, which could be a result of fluid flow and/or structural medial collateral ligament. *J Biomech Eng.* 2009; 103: 293-298.
13. Hirshowitz B, Lindenbaum E, Har-Shai Y. A skin-stretching device for harnessing of the viscoelastic properties of the skin. *Plast Reconstr Surg.* 1993; 92: 260-270.
14. Marek DJ, Copeland GE, Zlowodzki M, Cole PA. The application of dermatotraction for primary skin closure. *Am J Surg.* 2005; 190: 123-126.
15. Abramson DL, Gibstein LA, Pribaz JJ. An inexpensive method of intraoperative skin stretching for closure of large cutaneous wounds. *Ann Plast Surg.* 1997; 38: 540-542.
16. Jinqing Li, Morris Topaz, Hong Tan, Yuejun Li, Wangzhou Li, Wenxing Xun, et al. Treatment of infected soft tissue blast injury in swine by regulated negative pressure wound therapy. *Ann Surg.* 2013; 257: 335-344.

Cite this article

Hongwei Z, Chaoyang W, Jianhua S, Xinhui DU, Qinzhen F, et al. (2017) Regulated Negative Pressure Wound Therapy (RNPT) Combined Topclosure in the Treatment of Skin Defect for Open Fracture in Lower Extremity. *Ann Orthop Rheumatol* 5(1): 1079.