

Research Article

The Posterior Muscles of the Auricle: Anatomy and Surgical Applications

Rivka Bendrihem¹, Christian Vacher^{2*} and Jacques Patrick Barbet³

¹Department of Dentistry, University of Paris-Descartes, France

²Department of Maxillofacial Surgery & Anatomy, University of Paris-Diderot, France

³Department of Pathology and Cytology, University of Paris-Descartes, France

***Corresponding author**

Christian Vacher, Department of Maxillofacial Surgery & Anatomy, University of Paris-Diderot, APHP, 100, Boulevard Général Leclerc, 92110 Clichy, France, Tel: 0033140875671; Email: christian.vacher@bjn.aphp.fr

Submitted: 19 December 2014

Accepted: 16 January 2015

Published: 19 January 2015

Copyright

© 2015 Vacher et al.

OPEN ACCESS**Keywords**

- Auricle
- Anatomy
- Prominent ears
- Muscle

Abstract

Objective: Prominent ears are generally considered as primary cartilage deformities, but some authors consider that posterior auricular muscles malposition could play a role in the genesis of this malformation.

Study design: Auricle dissections of 30 cadavers and histologic sections of 2 fetuses' ears.

Methods: Posterior area of the auricle has been dissected in 24 cadavers preserved with zinc chlorure and 6 fresh cadavers in order to describe the posterior muscles and fascias of the auricle. Posterior auricle muscles from 5 fresh adult cadavers have been performed and two fetal auricles (12 and 22 weeks of amenorhea) have been semi-serially sectioned in horizontal plans. Five µm-thick sections were processed for routine histology (H&E) or for immuno histochemistry using antibodies specific for the slow-twitch and fast-twitch myosin heavy chains in order to determine which was the nature of these muscles.

Results: The posterior auricular and the *transversus auriculae* muscles looked in most cases like skeletal muscles and they were made of 75% of slow muscular fibres. The histologic sections of the auricle in the fetus suggest that the *transversus auriculae* plays a role in the constitution of the antihelical fold. The *obliquus auriculae* muscle was rather a fascia than a muscle in adult dissections and in fetuses auricle sections.

Conclusion: Some cases of prominent ears are related to anomalies of the posterior muscles of the auricle.

INTRODUCTION

Prominent ears are the most common deformity of the external ear in children. The most commonly seen defects are a poorly developed anti helical fold and a prominent concha. These malformations are generally considered as primary cartilage deformities, but some authors consider that posterior auricular muscles malposition could play a role in the genesis of prominent ears. The posterior muscles of the auricle have been described for the first time at the end of the nineteenth century [1]. The authors described a posterior auricular muscle which is usually considered as a extrinsic muscle with a proximal insertion on the mastoid process and a distal one on the posterior aspect of the auricle, and two intrinsic muscles, the *transversus auriculae* and the *obliquus auriculae* which are considered as intrinsic muscles because there proximal and a distal insertions are both on the posterior aspect of the auricle. Some authors described these

muscles as fascias [1], considering their macroscopic morphology (more fibrous than muscular) and their function, which is still unclear. In order to determine the anatomy of these muscles in man and investigate if these muscles could play a role in the external morphology of the auricle, we performed a macroscopic and histologic study of these muscles in 30 adults' dissections and in two human fetuses.

MATERIALS AND METHODS

Macroscopic study

A dissection of the posterior aspect of one auricle has been performed in 24 cadavers preserved with zinc chloride and 6 fresh cadavers in order to describe posterior auricular fascias and muscles. The sex ratio was: 20 females versus 10 males. The mean age was 87.4 years old.

Microscopic study

The posterior face of the auricle has been dissected in five fresh cadavers (4 females and 1 male; mean age: 78.4) in order to harvest tissue from the regions of the posterior auricular, *transversus auriculae* and *obliquus auriculae* muscles, and from the subcutaneous fascia located between the cartilage and the skin. Two fetal auricles (12 and 22 weeks of amenorrhea) have been semi-serially sectioned in horizontal plans. All these different samples were fixed in 4% formalin and embedded in paraffin. 5 µm-thick sections were processed for routine histology (H&E) or for immuno histochemistry using antibodies specific for the slow-twitch and fast-twitch myosin heavy chains (MHCs); both slow and fast obtained from Novocastra WB-MHCs and WB-MHCf respectively) revealed by peroxidase with the avidin-biotin technique (Vectastain PK-4002). Both antibodies have been tested by their specificity on human muscle by Western blot analysis and by immuno cytochemistry on defined muscle blocs as previously described [2].

RESULTS

Macroscopic study

In all cases the posterior auricular muscle was present. Its proximal insertion was located on the mastoid portion of the temporal bone and its distal insertion into the *ponticulus* on the *eminentia conchae*. It looked as a muscle in all cases. This muscle presented a posterior fascial extension from the *concha* to the posterior aspect of the helical fold which constituted a subcutaneous fascia covering the whole surface of the auricle's posterior aspect (Figure 1). The *transversus auriculae* consisted of muscular fibres in 25/30 cases crossing the posterior aspect of the anti helical fold from one side to the other (Figure 2). The *obliquus auriculae* consisted of few tendinous fibres in 26/30 cases. It was made of muscular fibres in 4/30 cases.

Microscopic study

In adults, the posterior auricular muscle samples were made of skeletal muscle in all cases. The *transversus auriculae* muscle samples showed muscular fibers in all cases. In immunochemistry most of the muscular fibres coming from the posterior auricular muscle and the *transversus auriculae* were slow fibres (75%). The *obliquus auriculae* was made in one sample of some muscular fibres which were all slow fibres, and in the other samples no muscular fibres have been found. In fetal auricles, the posterior auricular muscle and the *transversus auriculae* have been identified, the *obliquus auriculae* was not possible to identify because of the absence of muscular fibres. The *transversus auriculae* had a proximal insertion on the whole posterior face of the concha and crossed the anti helical fold to insert on the posterior face of the helix (Figure 3).

DISCUSSION

In our study, considerable variations in the anatomy of the posterior muscles of the auricle have been found. The posterior auricular muscle always looks like a skeletal muscle and is made of 75% of slow muscular fibres (Figure 4). This muscle presented a posterior fascial extension from the scapha to the posterior aspect of the helical fold. The *transversus auriculae* muscle was made of muscular fibres in most cases (87%) in adults. It was also

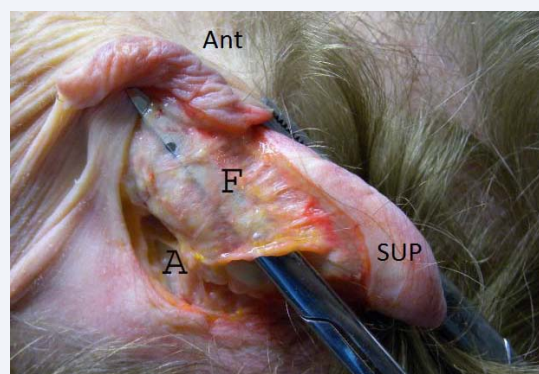


Figure 1 Dissection of the posterior aspect of the auricle (Ant = anterior, SUP = superior). The posterior auricular muscle presented a posterior fascial extension from the *concha* to the posterior aspect of the helical fold which constituted a subcutaneous fascia (F).

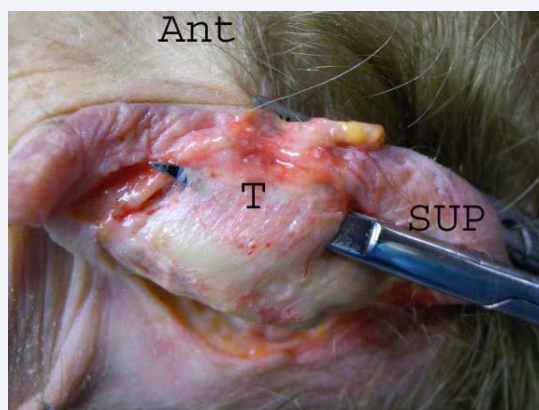


Figure 2 Dissection of the posterior aspect of the auricle (Ant = anterior, SUP = superior). The *transversus auriculae* muscle (T) was muscular in 25/30 cases.

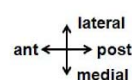
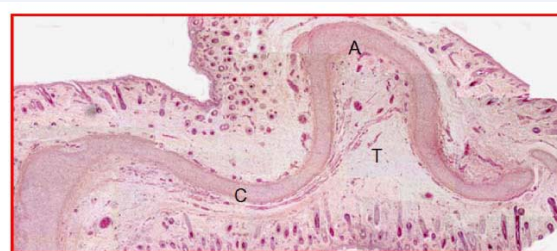


Figure 3 Longitudinal section (x15) of a fetal auricle aged of 22 weeks of amenorrhea. The *transversus auriculae* muscle (T) is running from the posterior aspect of the concha (C) to the anti helical fold (A).

made of 75% of slow muscular fibres. The histologic sections of the auricle in the fetus suggest that this muscle plays a role in the constitution of the anti helical fold. The *obliquus auriculae* muscle was rather a fascia than a muscle in adult dissections and in fetuses' auricle sections.

Many authors consider there is a relation between the posterior auricular muscle insertion site and ear projection [3]. In case of agenesis of posterior auricular muscle, an auricular hypermobility has been described [4]. Smith and Takashima reported a case of a young patient who was suffering of anencephaly and bilateral protruding ears. This patient presented no posterior auricular muscle on each side [5]. The authors concluded that the protruding auricle should be interpreted as a sign of muscular or neurological deficiency of the posterior auricular muscle rather than a sign of dysmorphogenesis of the auricular cartilage. The function of stabilization of this muscle is not the only one, in humans extrinsic auricular muscles respond to sound stimuli when studied with electromyographic techniques and maintain involuntary function [6]. Since Nicoletis [7] many techniques of transposition of the posterior auricular muscle have been described in the correction of prominent ears [8,9]. The extension of the posterior auricular fascia that we described is elevated by some authors as fascioperichondrial flaps with a distal and a proximal base in order to reduce the risk of complications [10].

The intrinsic muscles are usually considered as vestiges [11,12] and the role of the intrinsic muscles of the posterior auricle in prominent ears has been rarely studied. Zerlin dissected ten external auricles from anencephalic fetuses, and his results suggest that a normal antihelical fold is dependent on the presence of *transversus auriculae* and *obliquus auriculae* [13]. A case report of Stahl's ear in which the *transversus auriculae* muscle had an abnormal course has been described by authors who considered that this muscle was the cause of the deformity. The treatment was accomplished by cartilage incision and transposition of the muscle to its normal position with success [14]. In our study the orientation of the *transversus auriculae* perpendicular to the anti helical fold and the insertion of this muscle from one side to the other suggest there is a relation between this muscle and the morphology of the anti helical fold. Most of *transversus auriculae* muscular fibres are slow, which is in accordance of its presumed function in stabilizing the anti helical fold in a static way.

Modern otoplasty techniques fall into two broad surgical categories, cartilage sparing and cartilage cutting. Most of

techniques without cartilage section associate the anterior scoring method of Stengström [15,16] and the posterior suturing of the anti helical fold [17] and concha-mastoid sutures [18]. In Mustardetechnique, using mattress sutures to create and maintain the anti helical fold, we consider that these sutures perpendicular to the axis of the fold are replacing or reinforcing the *transversus auriculae*. In Furnas technique the sutures are replacing the posterior auricular muscle. Since Nicoletis, transposition of the posterior auricular muscle has been proposed as an anatomic correction of prominent ears.

CONCLUSION

This anatomic study suggests that auricle deformities are sometimes associated to anomalies of the posterior muscles of the auricle. Surgical techniques which tend to reinforce or replace the posterior auricular muscle (concha-mastoid suture or transposition of the muscle) or the *transversus auriculae* (Mustarde technique) have been proposed as an alternative to cartilage cutting techniques [19].

REFERENCES

- Gobrecht WH, Wilson E. A system of human anatomy, general and special. Philadelphia: Blanchard and Lea, 1858.
- Butler-Browne GS, Barbet JP, Thornell LE. Myosin heavy and light chain expression during human skeletal muscle development and precocious muscle maturation induced by the thyroid hormone. *Anat. Embryol.* 1990; 181:513-22.
- Guyuron B, DeLuca L. Ear projection and the posterior auricular muscle insertion. *Plast Reconstr Surg.* 1997; 100: 457-460.
- Hoogbergen MM, Schuurman AH, Rijnders W, Kon M. Auricular hypermobility due to agenesis of the extrinsic muscles. *Plast Reconstr Surg.* 1996; 98: 869-871.
- Smith DW. Protruding auricle: A neuromuscular sign. *Lancet.* 1978; 1: 747-749.
- Seiler R. [Muscles of the external ear and their function in man, chimpanzees and macaca]. *Gegenbaurs Morphol Jahrb.* 1974; 120: 78-122.
- Nicolétis C, Guerin-Surville H. Prominent ears: Transposition of the posterior auricular muscle on the scapha: A new technique. *Aesthetic Plast Surg.* 1978; 2: 295-302.
- Scuderi N, Tenna S, Bitonti A, Vonella M. Repositioning of posterior auricular muscle combined with conventional otoplasty: a personal technique. *J Plast Reconstr Aesthet Surg.* 2007; 60: 201-204.
- Yazici I, FindikÅŞioÄŸlu F, Ozmen S, Noyan N, Yavuzer R. Posterior auricular muscle flap as an adjunct to otoplasty. *Aesthetic Plast Surg.* 2009; 33: 527-532.
- Irkoren S, Kucukkaya D, Sivrioglu N, Ozkan HS. Using bilaterally fascioperichondrial flaps with a distal and a proximal base combined with conventional otoplasty. *Eur Arch Otorhinolaryngol.* 2014; 271: 1389-1393.
- Allison GR. Anatomy of the external ear. *Clin Plast Surg.* 1978; 5: 419-422.
- Allison GR. Anatomy of the auricle. *Clin Plast Surg.* 1990; 17: 209-212.
- Zerlin M, Van Allen MI, Smith DW. Intrinsic auricular muscles and auricular form. *Pediatrics.* 1982; 69: 91-93.
- Yotsuyanagi T, Nihei Y, Shinmyo Y, Sawada Y. Stahl's ear caused by an

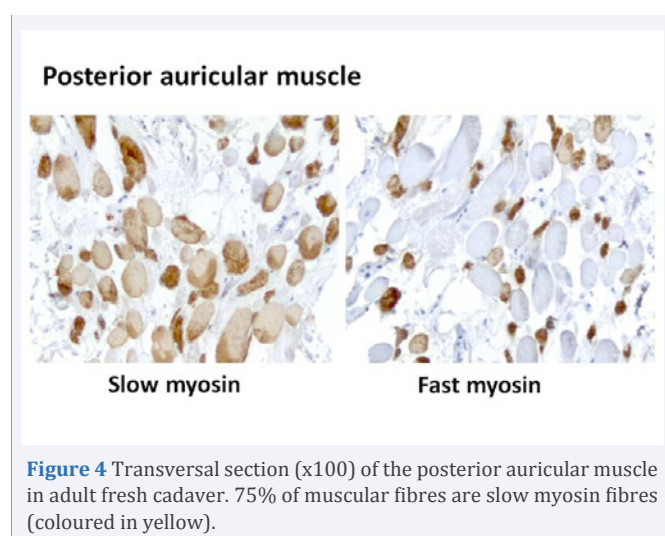


Figure 4 Transversal section (x100) of the posterior auricular muscle in adult fresh cadaver. 75% of muscular fibres are slow myosin fibres (coloured in yellow).

- abnormal intrinsic auricular muscle. *Plast Reconstr Surg.* 1999; 103: 171-174.
15. Stenstroem SJ. A "natural" technique for correction of congenitally prominent ears. *Plast Reconstr Surg.* 1963; 32: 509-518.
16. Stenström SJ. A simple operation for prominent ears. *Acta Otolaryngol.* 1966; 224:393.
17. Mustarde JC. Correction of prominent ears using buried mattress sutures. *Clin Plast Surg.* 1978; 5: 459-464.
18. Furnas DW. Correction of prominent ears by conchamastoid sutures. *Plast Reconstr Surg.* 1968; 42: 189-193.
19. Stucker FJ, Vora NM, Lian TS. Otoplasty: an analysis of technique over a 33-year period. *Laryngoscope.* 2003; 113: 952-956.

Cite this article

Bendrihem R, Vacher C, Barbet JP (2015) The Posterior Muscles of the Auricle: Anatomy and Surgical Applications. *Ann Otolaryngol Rhinol* 2(1): 1020.