

Research Article

Fully Endoscopic Stapes Surgery: Preliminary Results

Ali Özdek¹, Ömer Bayir^{1*}, Kemal Keseroğlu¹, Emel Cadallı Tatar¹, Bülent Öcal¹ and Mehmet Hakan Korkmaz²

¹Department of Otolaryngology and Head & Neck Surgery, Ministry of Health, Diskapi Yildirim Beyazıt Research Hospital, Turkey

²Department of Otolaryngology and Head & Neck Surgery, Yildirim Beyazıt University, Medical School, Turkey

*Corresponding author

Ömer Bayir, İrfan Bastuğ Str. Ministry of Health, Diskapi Yildirim Beyazıt Research Hospital, Department of Otolaryngology and Head & Neck Surgery, Altındağ, Ankara, Turkey, Tel: 90-506-672-62-87, Email: bayiromer@hotmail.com

Submitted: 18 December 2015

Accepted: 04 January 2016

Published: 06 January 2016

ISSN: 2379-948X

Copyright

© 2016 Bayir et al.

OPEN ACCESS

Abstract

Objectives: To present our preliminary results of endoscopic stapedectomy surgeries and also to discuss possible advantage and disadvantage of endoscope in otosclerosis surgery.

Methods: 29 patients who were conducted fully endoscopic stapedectomy procedure were involved and analyzed retrospectively in the study. Preoperative and postoperative pure tone averages and air-bone gaps were compared. Perioperative and postoperative complications were investigated.

Results: Audiologic improvement was achieved in 27 of 29 patients. Postoperative air-bone gap was within 10 dB in 23 years and between 10–20 dB in the 4 ears. Unfortunately, sensorineural hearing loss (not total) was observed in 2 patients.

Conclusion: Endoscopic transcanal stapedectomy seems a feasible and relatively safe surgical procedure. The main advantage of endoscope is that; it allows the better visualization of middle ear structure. It is possible to perform surgery completely by transcanal approach, even in narrow ear canals. The main disadvantages are that; it is a one handed surgery, lack of stereoscopic vision and it requires a learning curve.

Keywords

- Endoscope
- Stapedectomy
- Otosclerosis
- Endoscopic ear surgery
- Endoscopic stapedectomy

INTRODUCTION

Since the introduction of stapes surgery by Shea in 1956, numerous modifications of the classical stapes operation have been described in medical literature [1]. Small hall fenestra technique was defined, different prosthesis models were described and different instruments were developed to make fenestration. All these surgical procedures were performed under microscope until last several years. Microscopic surgery of otosclerosis was performed with a great success and minimal complication rates by many authors [2-5].

Endoscopes are being used increasingly in middle ear surgery in the last several years. At the beginning endoscopes were used only for diagnostic purposes, but they are now being used more and more for surgery of ear. Many anatomy-based papers have been published, showing the possible advantages of using endoscopes in ear surgery, especially for a better visualization of the structures and recesses within the tympanic cavity. Most of the surgeons prefer to use endoscopes in the surgery of infective middle ear diseases. Surgery of otosclerosis seems to be very suitable for exclusively endoscopic approach. However, there are only a few published articles in the literature regarding the endoscopic stapedectomy [1,6-10].

The aim of this study is to present our preliminary surgical results of endoscopic stapedectomy procedure and also to discuss possible advantage and disadvantage of endoscope use in otosclerosis surgery.

MATERIAL AND METHODS

This study was approved by our local ethical committee (2015-19/05). Charts of the patients who were operated with diagnosis of otosclerosis in period between March 2012 and June 2014 were retrospectively reviewed. Patients who were applied exclusively endoscopic transcanal stapedectomy procedures by same surgeon (AO) were included in the study. Pre- and postoperative audiometric datas including air and bone conduction thresholds, and air- bone gap (ABG) measurements at the four frequencies (0.5–1.0-2.0-3.0 kHz) were investigated. Postoperative audiometry is routinely performed at 1, 3, 6 and 12 months following surgery. Intraoperative and postoperative complications were also investigated.

Surgical Procedure

We used basically the same techniques and instruments, which are used in conventional ear surgeries beside of endoscopes. A fully endoscopic transcanal procedure was applied in all patients

using rigid endoscopes of 2.7-mm diameter, 18-cm length, 0° angle. All procedures were carried out under hypotensive general anesthesia. All the patients were placed in the same position for conventional ear surgeries, which are performed by microscope. The external ear canal was injected with lidocaine 1 % with 1:100,000 epinephrine. Vertical incisions were made at 6 and 12 hours level. Then one horizontal incision which merged them posteriorly at about 0.5-1 cm from the tympanic membrane. A posterior Tympanomeatal flap was elevated transmeatally under the vision of 0° endoscope and then transposed anteriorly. After that, middle ear was inspected carefully (Figure 1). Mobility of ossicular chain, status of round window and location of the facial nerve were inspected carefully. Although endoscopic view was enough to inspect the middle ear and stapes, small amount of bone was removed in the postero-superior part of the external ear canal to facilitate the placement of prosthesis. After than incudostapedial joint was disarticulated. Stapedius tendon was cut by micro-scissor. Stapes cruras were cut by crura scissor. Stapes suprastructure was removed. The distance between incus and footplate was measured. Small hall fenestra was performed by perforator hook (Figure 2). Flouroplastic piston was placed into this hole and fitted along the long process of the incus (Figure 3). Small amount of gelfoam was placed around the prosthesis. The tympanomeatal flap was repositioned, and the external auditory canal was filled with Gelfoam. This procedure was applied to 25 patients. Fiber optic CO₂ laser (Omni Guide, Cambridge, MA, USA) was used to make hole into the footplate and stapes prosthesis (Heinz Kurz GmbH, Dusslingen, Germany) was used to replace stapes in 4 patients.

Statistical Analyses

Statistical analyses were performed using Statistical Package for the Social Sciences (SPSS) version 20 (SPSS Inc.; Chicago, IL, USA). Wilcoxon signed rank test was used to compare preoperative and postoperative audiologic parameters. The significance level was set at $p < 0.05$.

RESULTS

There were 29 patients in the study group. Male/female ratio

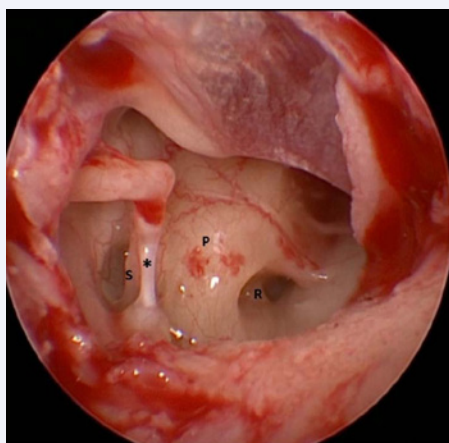


Figure 1 Endoscopic view of the right middle ear. S; stapes, P: Promontorium; R: Round Window; *: Stapedius Tendon.

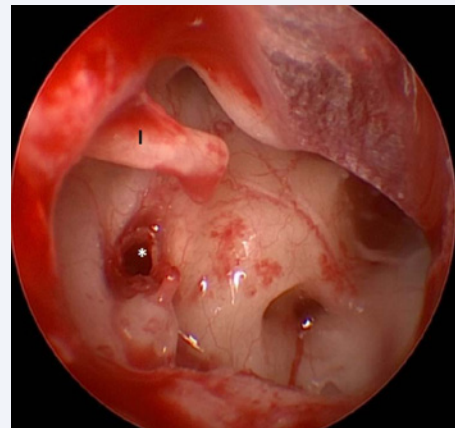


Figure 2 Fenestration of the right stapes footplate. I: Incus; *: Oval Window.

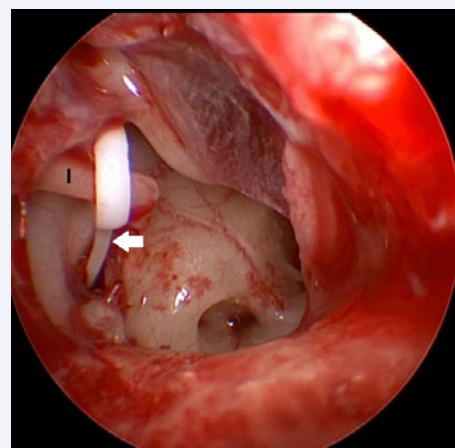


Figure 3 Placement of fluoroplastic piston prosthesis in the right ear. I: Incus; White arrow: prosthesis.

was 20/9. The mean age of the patients was 37 ± 10 (range 18-55) years. The mean follow-up period was 13 months (range 4-27 months). Sensorineural type hearing deterioration was observed in 2 (6.9%) patients. These two patients were excluded from further statistical analyses. Preoperative and postoperative average air conduction thresholds (AC) were 39.0 ± 6.2 dB and 11.5 ± 5.9 dB respectively ($p=0.000$) in the remaining 27 patients. Preoperative and postoperative average bone conduction thresholds (BC) were 4.0 ± 4.2 dB and 3.8 ± 4.0 dB respectively ($p=0.473$). Preoperative and postoperative average ABG were 35.0 ± 5.4 dB and 7.7 ± 4.8 dB respectively ($p=0.000$). The average postoperative ABG was within 10 dB in 23 (79%) patients and between 10-20 dB in the remaining 4 patients (14%).

Intraoperative complication was observed in 1 patient. Malleus was detached from incus accidentally in one patient. Malleus was reattached to incus by using bone cement. Although, ossicular system was reconstructed in this patient, average postoperative ABG was improved to 18 dB compared with preoperative 33 dB average ABG.

Severe vertigo and tinnitus were observed in early postoperative period in 2 patients. Weber was lateralized to contralateral ear in these two patients. Bone conduction thresholds were checked in first 24 hours. Sensorineural hearing loss (SNHL) was identified in these two patients. Gelfoams in the external ear canal were removed and medical treatment including systemic corticosteroid and Dextrane was applied. Unfortunately we couldn't achieve any improvement in hearing thresholds in these two patients. Postoperative BC thresholds of these two patients were 43 dB and 46 dB comparing with preoperative BC thresholds of 8 dB and 5 dB respectively.

DISCUSSION

Endoscopes became used more and more in ear surgery. Most important advantage of endoscope use in otology is its direct and easy access to least accessible part of the middle ear such as sinus tympani and epitympanum. Endoscopes provide wide angle and thus the entire area of the operation can be seen in one field. Use of angled telescopes gives the chance of visualization of most hidden part of the middle ear cavity. As the light source is located at the tip of the endoscope this allows the better visualization of middle ear structure. Another advantage of endoscope is that it is a minimal invasive technique. It requires less drilling than microscopic technique and usually there is no need incision.

The main disadvantage of endoscopic ear surgery is being one-handed surgical technique. Therefore it requires blood-free field [11-13]. There is a learning curve as happen in all-surgical procedures. To become an experienced surgeon in otology does not mean that you can do endoscopic ear surgery easily. Therefore, endoscopic stapedectomy is not an appropriate surgery to start endoscopic ear surgery.

Microscopic stapedectomy procedure is very well defined surgical procedure with a high success rate [14]. However it has some limitations. Although it is possible to perform transcanal approach in many patients, it requires endaural or post auricular approach in narrow ear canals. It is usually hard to see anterior crus of the stapes appropriately. Surgeon has to fracture anterior crus usually blindly. It usually requires drilling or curettage of ear canal to visualize the stapes. Endoscopic approach can overcome these limitations in stapedectomy.

First endoscopic stapedectomy procedure was published by Poe in 2000 and several papers were published since that time [1, 6, 7,10,15]. These early publications have promising results. Nogueira et al [10] published early results of 15 endoscopic stapedectomy procedures in 2011. They reported improvement of hearing threshold in 14 of 15 patients. Sarkar et al [7] published their results of endoscopic stapedectomy surgeries in 2013. They have 32 patients. They reported that they shifted to microscopic surgery in 2 patients due to perilymph gusher. This is a good example for showing the limitation of endoscopic stapedectomy surgery. Every surgeon should recognize and keep in mind that; endoscope does not replace the need for microscope in surgery. Therefore microscope should be available in the operating room in every endoscopic ear surgery. Surgeons should not hesitate to shift the microscopic surgery when needed.

Migirov and Volf [6] reported another advantage of endoscopic stapedectomy. Their study focused to preservation

of chorda tympani nerve (CTN) during the stapedectomy. They achieved to preserve CTN in all 8 endoscopic stapedectomy procedures. This is really important because chorda tympani damage may occur in 30% of cases in conventional microscopic stapedectomy procedure. It is more common if the bony canal in the posteriorsuperior quadrant is removed using a drill rather than a curette [16]. Unfortunately, our study didn't focus on CTN preservation. Our observation is that; possibility of anatomical preservation of CTN is much higher in endoscopic stapedectomy comparing with microscopic surgery.

Recently, Kojima et al compared endoscopic versus microscopic stapedectomy procedure [15]. Their study group involved 15 years in endoscopic stapedectomy group and 41 years in microscopic stapedectomy group. They reported that there were no differences of operating time or postoperative hearing between the endoscopic and microscopic groups. There was very little postoperative pain in the endoscopic group. Postoperative dizziness was mild in all patients who underwent endoscopic surgery. Drilling at the posteriorsuperior part of the external auditory canal was less extensive in the endoscopic group than in the microscopic group. They concluded that endoscopic surgery is particularly suitable for stapedia disease. Endoscopic stapes surgery can even be done in patients with a curved and narrow external auditory canal.

Over the last 20 years, the number of stapes operations performed has decreased steadily. Possible reasons for the reduction could be the fluoridation of water supplies and improvement of the quality of hearing aids. Yung et al investigated the learning curve in stapes surgery and its implication to training. They reported that only 900 stapedectomies were performed in England and Wales in year 2000 [17]. In their study, it took at least 60 to 80 cases for two different authors to reach a landmark point in their learning curves. Therefore as the number of practicing otolaryngologists steadily increases, it is inevitable that fewer cases of otosclerosis present to each surgeon. Endoscopic stapedectomy procedure can also facilitate the learning curve of surgical technique and anatomy for trainees. Since both the surgeon and assistants can view the monitor, the surgical anatomy and procedure can be understood more easily [15].

Although no SNHL was reported by previous limited number of endoscopic stapedectomy reports, we observed 2 SNHL in our series. Hopefully these are not total hearing loss. SNHL is the scariest complication of otosclerosis surgery. The cause is usually unknown and the incidence ranges from 0.6% to 3% in microscopic surgery [16]. The most common cause of permanent hearing loss is surgical trauma. We couldn't identify any reason for the occurrence of SNHL in these 2 patients. There was no recognized surgical trauma. We can speculate that heating effect of light source could be a possible cause for inner ear trauma. Kozin et al [17] demonstrated the heating effect of light source during the endoscopic procedures experimentally previously. Several authors also mentioned this potential side effect in their publications. However, there is no clinical evidence to support this potential harmful side effect [18]. Otosclerosis surgery is somewhat different from the other endoscopic middle ear surgeries. Fenestration of the oval window results with the direct exposure of inner ear structures to heating effect of light source.

Therefore exposure time can be a determining factor for the development of SNHL. We can advice that; light source power should be adjusted to the lowest settings that allows adequate visualization. In addition, surgeon should remove the endoscope from ear frequently and should clean the tip of the endoscope with antifog solution, which will help in cooling the endoscope [19].

We have also one complication during the intraoperative period. Malleus-incus detachment was occurred in this patient accidentally. Although we reattached the malleus to incus by using bone cement, 18 dB ABG was remained in this patient. Endoscopic ear surgery has a monocular vision; therefore adaptation to depth sensation requires experience. We have accomplished to finalize all surgeries endoscopically. But operating microscope was in the operating room and was ready to use when needed in all cases.

CONCLUSION

In conclusion, endoscopic transcanal stapedectomy seems a feasible and relatively safe surgical technique in limited case series. It is possible to perform a transcanal procedure nearly in all patients, even in the cases, which have narrow ear canal. However it shouldn't be handled as an alternative technique to microscopic surgery. Microscope and endoscope should be taught as complimentary instruments for each other. We believe that endoscopes will take much more place in the otologic surgery in the near future. However we need much more experience to set the surgical principles of endoscopic ear surgery.

REFERENCES

1. Poe DS. Laser-assisted endoscopic stapedectomy: a prospective study. *Laryngoscope*. 2000; 110: 1-37.
2. Vincent R, Sperling NM, Oates J, Jindal M. Surgical findings and long-term hearing results in 3,050 stapedotomies for primary otosclerosis: a prospective study with the otology-neurotology database. *Otol Neurotol*. 2006; 27: S25-47.
3. Fisch U. Stapedotomy versus stapedectomy. *Am J Otol*. 1982; 4: 112-117.
4. Kos MI, Montandon PB, Guyot JP. Short- and long-term results of stapedotomy and stapedectomy with a teflon-wire piston prosthesis. *Ann Otol Rhinol Laryngol*. 2001; 110: 907-911.
5. Persson P, Harder H, Magnuson B. Hearing results in otosclerosis surgery after partial stapedectomy, total stapedectomy and stapedotomy. *Acta Otolaryngol*. 1997; 117: 94-99.
6. Migirov L, Wolf M. Endoscopic transcanal stapedotomy: how I do it. *Eur Arch Otorhinolaryngol*. 2013; 270: 1547-1549.
7. Sarkar S, Banerjee S, Chakravarty S, Singh R, Sikder B, Bera SP. Endoscopic stapes surgery: our experience in thirty two patients. *Clin Otolaryngol*. 2013; 38: 157-160.
8. Tarabichi M, Ayache S, Nogueira JF, Al Qahtani M, Pothier DD. Endoscopic management of chronic otitis media and tympanoplasty. *Otolaryngol Clin North Am*. 2013; 46: 155-163.
9. Marchioni D, Alicandri-Ciuffelli M, Piccinini A, Genovese E, Monzani D, Tarabichi M, et al. Surgical anatomy of transcanal endoscopic approach to the tympanic facial nerve. *Laryngoscope*. 2011; 121: 1565-1573.
10. Nogueira Júnior JF, Martins MJ, Aguiar CV, Pinheiro AI. Fully endoscopic stapes surgery (stapedotomy): technique and preliminary results. *Braz J Otorhinolaryngol*. 2011; 77: 721-727.
11. Nogueira JF, Mattioli F, Presutti L, Marchioni D. Endoscopic anatomy of the retrotympanum. *Otolaryngol Clin North Am*. 2013; 46: 179-188.
12. Marchioni D, Piccinini A, Alicandri-Ciuffelli M, Presutti L. Endoscopic anatomy and ventilation of the epitympanum. *Otolaryngol Clin North Am*. 2013; 46: 165-178.
13. Tarabichi M. Endoscopic transcanal middle ear surgery. *Indian J Otolaryngol Head Neck Surg*. 2010; 62: 6-24.
14. Shea JJ Jr. Forty years of stapes surgery. *Am J Otol*. 1998; 19: 52-55.
15. Kojima H, Komori M, Chikazawa S, Yaguchi Y, Yamamoto K, Chujo K, et al. Comparison between endoscopic and microscopic stapes surgery. *Laryngoscope*. 2014; 124: 266-271.
16. Bajaj Y, Uppal S, Bhatti I, Coatesworth AP. Otosclerosis 3: the surgical management of otosclerosis. *Int J Clin Pract*. 2010; 64: 505-510.
17. Yung MW, Oates J, Vowler SL. The learning curve in stapes surgery and its implication to training. *Laryngoscope*. 2006; 116: 67-71.
18. Kozin ED, Lehmann A, Carter M, Hight E, Cohen M, Nakajima HH, et al. Thermal effects of endoscopy in a human temporal bone model: implications for endoscopic ear surgery. *Laryngoscope*. 2014; 124: E332-339.
19. Tarabichi M. Endoscopic management of limited attic cholesteatoma. *Laryngoscope*. 2004; 114: 1157-1162.

Cite this article

Özdek A, Bayir Ö, Keseroğlu K, Tatar EC, Öcal B, et al. (2016) Fully Endoscopic Stapes Surgery: Preliminary Results. *Ann Otolaryngol Rhinol* 3(1): 1085.