

Research Article

Prominent Ears: Impact of Combination of Techniques

Mohamed Elsayed Mohamed Mohamed^{1*}, Mohamed Ahmed Hassan², Samar Ahmed Kandil³, and Ahmed Fathy Mohamed Eldehn⁴

¹Department of Plastic Surgery, Ahmed Maher Teaching Hospital, Cairo, Egypt

²Department of Plastic Surgery, Ahmed Maher Teaching Hospital, Cairo, Egypt

³Department of Plastic Surgery, Ahmed Maher Teaching Hospital, Cairo, Egypt

⁴Department of ENT, Kasr Al-Ainy Medical School, Cairo, Egypt

***Corresponding author**

Mohamed Elsayed Mohamed Mohamed, 341, Port said Street, Department of Plastic Surgery, Ahmed Maher Teaching Hospital, Cairo, Egypt, Tel: 201-222547992, Email: Mghabn5777@yahoo.com; m.elsayed.tajmeel@gothi.cloud.gov.eg

Submitted: 23 May 2020

Accepted: 30 May 2020

Published: 31 May 2020

ISSN: 2379-948X

Copyright

© 2020 Mohamed Mohamed ME, et al.

doi: <https://dx.doi.org/10.47739/Otolaryngology.1239>

OPEN ACCESS**Keywords**

- Prominent ears
- Otoplasty
- Cartilage scoring
- Cartilage abrasions
- Suture techniques

Abstract

Purpose: Estimate the effect of combination of different otoplasty techniques and its effects of patients' psychological condition.

Methods: From January 2015 to July 2019, otoplasty for 30 patients complaining of bilateral prominent ears were done. Suture techniques were combined with scoring with no cartilage excision have been used to ensure symmetrical and adequate repair with no relapse from the surgery.

Results: 30 patients were operated. 28 patients were satisfied. 2 early complications occurred in the form of hematoma, which were evacuated and treated conservatively. Also, 2 late hypertrophic scarring of the post auricular sulci were treated with silicone gel and intra lesional injection of corticosteroids. Patient satisfaction was the utmost, with great impact on psychological status and lifestyle changes.

Conclusion: Combination of suture techniques and cartilage scoring with no cartilage excision in surgical management of protruding ears has a great role in restoring normal and symmetrical shape and greatly prevents relapse of the condition. Minimal of no complications could be guaranteed if combination is adequate. Post-operative psychological improvement and change in life style is well established.

Level of Evidence: Therapeutic, V.

INTRODUCTION

The auricle is complex anatomical structure that varies enormously from one person to another, even in the same person; there may be a difference between the 2 auricles. Prominent ear deformity is the most common abnormality of the external ear. It affects approximately 5% of the population [1].

When analyzing the main pathology of the prominent ear; there may be deep or hypertrophied concha, loss or absent antihelix or combination of the two findings. Isolated protruded ear lobule could be present [2].

There are too much techniques and procedures used for correction of prominent ear deformity which include cartilage excision, bending, suture techniques and scratching or scoring. The huge of different approaches indicates that there is not one clearly definitive technique with which to correct this deformity [3,4]. Numerous studies have shown that patients may suffer psychological distress, emotional trauma, changes in life style and appearance and behavioral problems [3].

The goal of this manuscript is to correct prominent ears in patients through combinations of techniques in such a way to avoid as much as possible the recurrence of this condition or complications, and also to evaluate the patient's psychological aspect, behavioral changes in life style after correction. Surgery of prominent ears aims at satisfying patients in a way with maximal symmetry and perfect outcome.

PATIENTS AND METHODS

From May 2015 to July 2019 thirty patients with bilaterally prominent ears were operated for correction of their conditions. Patients were recruited from Plastic Surgery and Otolaryngology outpatient clinics. Demographic data, pathology, complications, psychological impact after operation, patient satisfaction and follow up period were analysed.

METHODS

Preoperative assessment of the degree of anti-helical folding, depth of the concha, lobule deformity and the angle between the

helical rim and the mastoid plane was done. A questionnaire of 2 questions about the behavioural changes before and after operation was done. The first question for adults was; do your ears urge you to wear scarfs or caps or specific haircut? The second question for parents of children was; did your child have School fights, teasing or no desire to go to school?

- Surgical techniques which were used for the correction of the prominent ears were grouped into procedures used to create the anti-helical fold, to correct the conchal defect, and to restore lobule position. Creation of the Antihelical Fold was done through Combination of superficial Cartilage scoring and suture fixation. Mustarde and Furnas sutures were placed in the posterior cartilage that incorporated the full thickness of the cartilage and anterior perichondrium but not the anterior skin.
- Correction of the hypertrophied concha was done by suturing techniques and scoring. Non absorbable, full-thickness mattress sutures placed in the conchal cartilage and sutured it to the mastoid fascia. This was performed before correction of any antihelix defect. Finally, careful scoring was done.
- Correction of lobular position was done through modified fishtail correction, wedge-excision or a deep dermis-to-scalp periosteum sutures.

After careful hemostasis, the post auricular skin was excised from both sides of the incision. It was then closed using 5/0 non-absorbable sutures. An auricular template of Vaselinated gauze was used anteriorly and posteriorly on the auricle to guard against hematoma formation.

This dressing was checked in the second day, dressing changing was done day after day. It was removed at the fifth day post operatively.

RESULTS

The present work was carried out on 30 patients with bilateral protruding ears (16 males and 14 females). Their age ranged between (5-27 years), they were 8 adults and 22 children. 20 patients had combined pathology, 4 patients complained of isolated absence of antihelix; 2 patients had isolated deep concha and 4 patients had isolated protruding ear lobules (Figures 1-6).

Regarding patient satisfaction total patient satisfaction was 28 patients (94%) satisfaction. 18 patients were very satisfied, 10 patients were satisfied: 2 patients were not satisfied due to late sequelae of hypertrophic scarring.

Early complications occurred in 2 patients in the form of 2 unilateral hematoma formations in 2 different patients. Late complications occurred in 2 patients; hypertrophic scarring of the post auricular sulci. Two patients developed recurrence of the condition; one was due to traction on the ear by a colleague during training which was reoperated and no recurrence for one year follow up. The other patient subjected to trauma to the ear after one weak postoperative with partial relapse in one ear. This patient refused reoperation.

The 2 questions questionnaire about the influence of otoplasty operation revealed that; Parents of the 22 children

operated notified the change of their behavior in the form of (become happier, decreased aggressiveness at school, desire for shorter haircuts, desire to go to school regularly and decrease school absence). 6 adult male patients who confirmed the change of life style after operation in the form of change hair cut used to camouflage their prominent ears. one of them reported that he changed his career. The remaining 2 adult females showed that they became more self-confident.

Patients continued follow-up for about 6 months to 12 months post- operative with no late sequelae except for the 2 traumatic cases.

DISCUSSION

Protruding ears results from cartilage malformation during the intrauterine life. It affects structures of the auricle in the form of deep hypertrophied concha and loss of anti-helix or combination of these anatomical deformities [1]. The goal of otoplasty for correction of protruding ears is to restore the normal shape and position of both auricles. Surgeons are committed to reshape a new auricle which is symmetrical to a normal one as possible [2].

In the present study, 30 cases of bilaterally prominent ears presented by lack of antihelix and conchal hypertrophy. There were 16 males and 14 females. The age of patients ranged between 5-27 years. Among the 30 patients; 20 patients had combined pathology, 4 cases presented with only absent antihelix, 2 cases with isolated deep concha, 4 cases with isolated protruded ear lobule.

Ostior folding of the antihelix starts with anterior cartilage scoring and abrasion techniques are often used, especially in auricular cartilage of older ages [5,6].

Cartilage-sparing techniques primarily depend on the adequate placement of permanent sutures to achieve the desired degree of remodeling [7,8]. The combination of techniques using suture techniques and cartilage abrasions affords control over the long-term results and lowers incidence of relapse. Overcorrection or under-correction is not needed [9].

Cartilage-cutting and excision techniques potentially subject the ear to irreversible deformity. These are more difficult to predict or treat. Deformities may include irregularities, sharp edges, and overcorrection, which are difficult to treat in revision surgery [10-15].

In the current series we used both techniques for restoring normal shape of the auricle; suture techniques and superficial anterior scoring and abrasion. Cartilage excision was avoided to prevent occurrence of cartilage irregularities or sharp edges which is usually apparent as seen from front. This allowed achieving better form and symmetry and also easier to teach and understand for the young surgeons. During otoplasty ear lobule may protrude anteriorly. Many skin incisions or excisions have been described to restore lobule position. Many types of skin excisions, e.g. in the shape of a fish tail, a Z-plasty or an ellipse, in combination with fat resection in the area of the lobule may be applied. Despite numerous reports about successful repositions of the lobule, the skin-suture techniques alone cannot guarantee a successful long-term result due to the natural elasticity of the skin. [16-19].

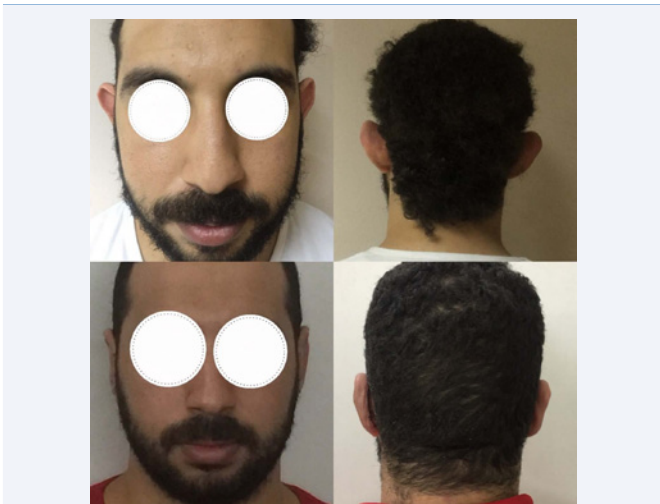

Figure 1 26 years male patient with bilaterally protruded ears. (a) Pre-operative anterior view. (b) Pre-operative posterior view. (c) Post-operative anterior view. (d) Post-operative posterior view.

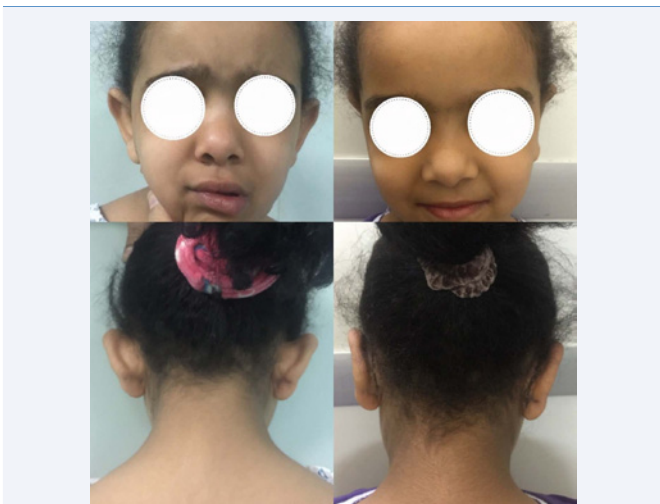

Figure 2 6 years female patient with bilaterally protruded ears. (a) Pre-operative anterior view. (b) Post-operative anterior view. (c) Pre-operative posterior view. (d) Post-operative posterior view.

In the current study, ear lobule repositioning occurred using both suturing and skin resection techniques to adjust the position of lobule for long term results, either in cases with isolated protruding lobules or in combined pathology.

At the end of the operation, excess retro-auricular skin can be excised with tension-free suture to prevent the formation of postoperative keloids or hypertrophic scarring [20,21]. In this study, Post auricular skin excision was done in all cases under tension-free condition to prevent the hypertrophic scarring or keloid formation, also to prevent the exposure of sutures.

Following protruding ears surgery, there may be early or late complications. Early complications include hematoma, infection, chondritis, pain, bleeding, and necrosis. Late ones may include keloid or hypertrophic scarring, suture complications, residual deformity, asymmetry, patient dissatisfaction and relapse

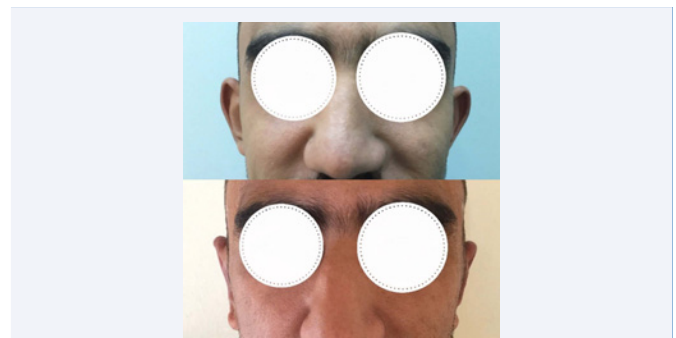


Figure 3 27 male patient with bilaterally protruded ears. (a) Pre-operative anterior view. (b) Post-operative anterior view.

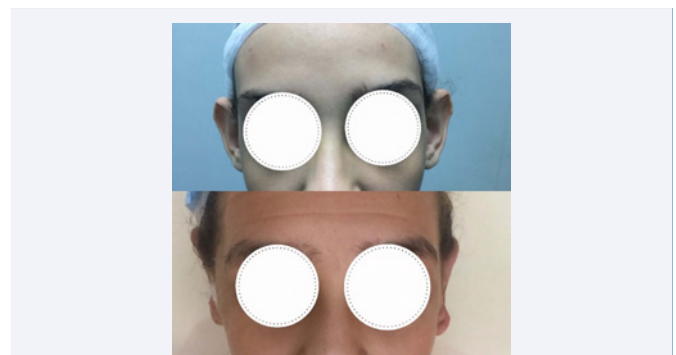


Figure 4 11 years female patient with bilaterally protruded ears. (a) Pre-operative anterior view. (b) Post-operative anterior view.

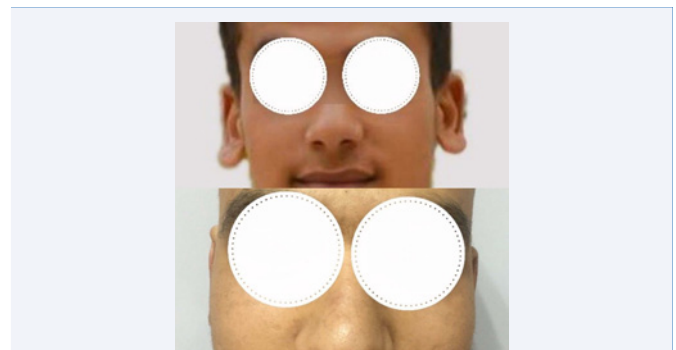


Figure 5 24 years male patient with bilaterally protruded ears. (a) Pre-operative anterior view. (b) Post-operative anterior view.

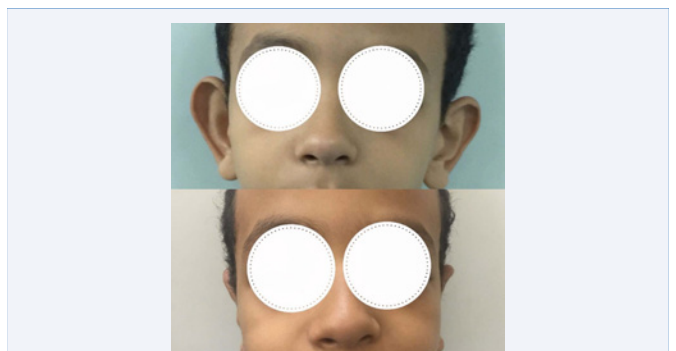


Figure 6 7 years male patient with bilaterally protruded ears. (a) Pre-operative anterior view. (b) Post-operative anterior view.

[1]. Hematoma is suspected if there is acute onset of severe, persistent, and often unilateral pain. Dressing should be removed and sutures released to evacuate the hematoma [3]. In this series there were only 2 unilateral hematomas in 2 different patients. Unilateral pain and compression sensation appeared at the second day post-operative. Each ear was treated by hematoma evacuation, saline irrigation and antibiotics. Daily observation for patients was done till discharge with no re-accumulation of hematoma.

Late complications, such as hypertrophic scars or keloids, may occur even months after otoplasty, follow-up of patients especially those with history of keloid tendency or hypertrophic

scarring is mandatory for one year. In addition, these patients should apply a scar ointment, which inhibits excessive collagen synthesis in the region of the scar [21] (Table 1).

In this series, 2 patients had bilateral hypertrophic scarring of the post auricular sulci of different degrees. Patients had a history of hypertrophic scarring. Treatment was done using silicone gel preparations and intra-lesional corticosteroid injections.

Series reported by Adamson and Messner showed that when using Mustarde and Furnas suture placement alone to achieve setback, Complete relapse is seen in almost one third of patients, and another third of patients demonstrate partial relapse. Relapse is a function of cartilage recoil from its intrinsic memory [22-24].

Table 1: Patient sheet: demonstrating pathological causes, procedures done, patient satisfaction and complications: (AH) refers to antihelix; (Sc.) scoring of cartilage; (Su) suturing techniques; (VS) very satisfied, (S) satisfied; (US) unsatisfied, complications early or Late, (2ry) for relapse.

	Age	Sex	Pathology			Surgical techniques						Satisfaction			Complications			
			AH	Concha	Lobule	Antihelix		Concha		Iobule		Skin	VS	S	US	Early	Late	2ry
						Sc.	Su	Sc.	Su.	Su.	Ex.							
1	27	M	#	#	-	#	#	#	#	-	-	#	#	-	-	-	-	-
2	26	M	#	#	#	#	#	#	#	#	#	#	-	-	-	#	-	#
3	23	M	-	-	#	-	-	-	-	#	#	-	#	-	-	-	-	-
4	5	F	#	#	-	#	#	#	#	-	-	#	#	-	-	-	-	-
5	6	M	#	#	-	#	#	#	#	-	-	#	-	#	-	-	-	-
6	6	M	#	-	-	#	#	-	-	-	-	-	-	#	-	-	-	-
7	11	F	#	#	-	#	#	#	#	-	-	#	-	-	#	-	#	-
8	7	M	#	#	-	#	#	#	#	-	-	#	#	-	-	-	-	-
9	6	F	#	#	-	#	#	#	#	-	-	#	#	-	-	-	-	-
10	5	F	#	#	-	#	#	#	#	-	-	#	#	-	-	-	-	-
11	6	F	#	#	-	#	#	#	#	-	-	#	-	#	-	-	-	-
12	19	M	#	#	#	#	#	#	#	#	#	#	#	#	-	-	#	-
13	9	F	-	-	#	-	-	-	-	#	#	-	-	#	-	-	-	-
14	8	F	#	#	#	#	#	#	#	#	#	#	-	#	-	-	-	-
15	24	M	#	#	-	#	#	#	#	-	-	#	#	-	-	-	-	-
16	6	F	#	#	#	#	#	#	#	#	#	#	-	#	-	-	-	-
17	6	M	#	#	-	#	#	#	#	-	-	#	#	-	-	-	-	-
18	8	F	#	-	-	#	#	-	-	-	-	-	-	#	-	-	-	-
19	7	M	-	#	-	-	-	#	#	-	-	#	#	-	-	-	-	-
20	6	F	#	#	#	#	#	#	#	#	#	#	-	#	-	#	-	-
21	7	M	-	#	-	-	-	#	#	-	-	#	#	-	-	-	-	-
22	9	M	#	#	-	#	#	#	#	-	-	#	#	-	-	-	-	-
23	6	F	#	#	-	#	#	#	#	-	-	#	#	-	-	-	-	-
24	27	M	-	-	#	-	-	-	-	#	#	-	-	#	-	-	-	-
25	7	F	#	#	#	-	#	#	#	-	-	#	#	-	-	-	-	-
26	8	M	#	-	-	-	#	#	-	-	-	-	#	-	-	-	-	-
27	24	M	#	#	-	-	#	#	#	-	-	#	#	-	-	-	-	-
28	6	F	-	-	#	-	-	-	-	#	#	-	-	#	-	-	-	-
29	7	M	#	#	#	#	#	#	#	#	#	#	#	-	-	-	-	-
30	23	F	#	-	-	#	#	-	-	-	-	-	#	-	-	-	-	-

Relapse is particularly likely for patients with stiff cartilage. Since most have noted a steady increase in cartilage thickness with age, adults are much more likely to have recurrences than children, especially young children. Others have been able to overcome relapse issues by combining anterior scoring techniques with posterior suture placement. Because the ear is essentially being molded and internally splinted by Mustarde sutures, cartilage scoring can be conservative, sufficient to release the cartilage spring only with no need for excision techniques [25-28].

In the current series, total 30 pairs of repaired prominent ears had no relapse except for 2 patients. Anterior scoring with aggressive scoring especially in older ages was combined with suture techniques to lower the incidence of relapse. The reasons for unilateral ears relapse in 2 different patients had no relation to the operation. It was just related to direct trauma to the repaired ears early post operative. One patient underwent surgical repair after 4 months post-operative. The other patient refused and was satisfied although some degree of relapse is present.

In 2008 Lourenço et al., showed in their study that many of the children in the study complained for years about their deformity with phrases such as "I do not want to go to school". Their parents confirmed that children "fearful and sad," "teasing and fights at school," and "is ashamed of people seeing his ears". After otoplasty, most of these complaints disappeared, and a great change in their social life is established [29].

In a study of Cooper-Hobson et al., Retrospective questionnaires were sent to all children aged 5 to 16 years (101 patients) who were on the hospital records having undergone otoplasty between 1999 and 2003, investigating social experiences, and experience of surgery. They found: 97% reported an increase in happiness; 92% reported an increase in self-confidence; 79% noted improved social experience; 100% reported bullying reduced or stopped [30].

Regarding patient satisfaction total patient satisfaction was (94%), 28 patients were satisfied. 18 patients were very satisfied, 10 patients were satisfied: 2 patients were not satisfied. Parents of the 22 children operated notified the change of their behavior in the form of (becoming happier, decreased aggressiveness at school, desire for shorter haircuts, desire to go to school regularly and decrease school absence). Among the 8 adults operated, there were 6 male patients who confirmed the change of life style after operation in the form of change hair cut used to camouflage their prominent ears.

CONCLUSION

Combination of suture techniques and cartilage scoring with no cartilage excision in surgical management of protruding ears has a great role in restoring normal and symmetrical shape. This combination greatly prevents relapse of the condition. Minimal of no complications could be guaranteed if combination is adequate. Post-operative psychological improvement and change in life style is well established.

REFERENCES

1. Jeffrey Janis, Rod Rohrich, Karol Gutowski. Otoplasty. *Plast Reconstr Surg.* 2005; 115: 60-72.

2. Patrick Kelley, Larry Hollier, Samuel Stal. Otoplasty: Evaluation, Technique, and Review. *J Craniofac Surg.* 2003; 14: 643-653.
3. Kausar Ali, BA Jesse D. Meaie, Renata S. Maricevich, Asaf Olshinka. The Protruding Ear: Cosmetic and Reconstruction. *Semin Plast Surg.* 2017; 31: 152-160.
4. JA Lourenço Gasques, JM Pereira de Godoy, EMT Navarro Cruz. Psychosocial Effects of Otoplasty in Children with Prominent Ears. *Aesth Plast Surg.* 2008; 32: 910-914.
5. Stenstrom SJ. A natural technique for correction of congenitally prominent ears. *Plast Reconstr Surg.* 1963; 32: 509.
6. Tan KH. Long-term survey of prominent ear surgery: a comparison of two methods. *Br J Plast Surg.* 1986; 39: 270.
7. Calder JC, Naasan A. Morbidity of otoplasty: a review of 562 consecutive cases. *Br J Plast Surg.* 1994; 47: 170.
8. Nielsen F, Kristensen S, Crawford M. Prominent ears: a follow-up study. *J Laryngol Otol.* 1985; 99: 221.
9. Weinzweig N, Chen L, Walter GS. Histomorphology of neochondrogenesis after antithelical fold creation: a comparison of three otoplasty techniques in the rabbit. *Ann Plast Surg.* 1994; 33: 371.
10. Madzharov MM. A new method of auriculoplasty for protruding ears. *Br J Plast Surg.* 1989; 42: 285.
11. I Pitanguy, P Müller, N Piccolo, E Ramalho, R Solinas. The Treatment of prominent ears: a 25-year survey of the island flap technique. *Aesthetic Plast Surg.* 1987; 11: 87.
12. Kaye BL. A simplified method for correcting the prominent ear. *Plast Reconstr Surg.* 1967; 40: 44.
13. Chait L, Nicholson R. One size fits all: a surgical technique for the correction of all types of prominent ears. *Plast Reconstr Surg.* 1999; 104: 190.
14. Luckett WH. A new operation for prominent ears based on the anatomy of the deformity. *Plast Reconstr Surg.* 1969; 43: 83.
15. Hinderer UT, Del Rio JL, Fregenal FJ. Otoplasty for prominent ears. *Aesthetic Plast Surg.* 1987; 11: 63.
16. Mustardé JC. The correction of prominent ears using simple mattress sutures. *Br J Plast Surg.* 1963; 16: 170.
17. Wood-Smith D. Otoplasty. In: Rees T, ed. *Aesthetic Plastic Surgery.* Philadelphia: Saunders; 1980; 833.
18. Kelley P, Hollier L, Stal S. Otoplasty: evaluation, technique, and review. *J Craniofac Surg.* 2003; 14: 643-653.
19. Lavy J, Stearns M. Otoplasty: techniques, results and complications - a review. *Clin Otolaryngol Allied Sci.* 1997; 22: 390-393.
20. Bloching M, Kippenhahn K, Knipping S, Berghaus A. Die Ohrmuschel-anlageplastik. *Medithek of the Deutsche Gesellschaft für Hals-Nasen-Ohrenheilkunde, Kopf- und Halschirurgie;* 2000.
21. Andreas Naumann. Otoplasty - Techniques, characteristics and risks. *Current Topics in Otorhinolaryngology - Head and Neck Surgery.* 2007; 6.
22. Adamson PA, McGraw BL, Tropper GJ. Otoplasty: critical review of clinical results. *Laryngoscope.* 1991; 101: 883.
23. Spira M. Otoplasty: what I do now-a 30-year perspective. *Plast Reconstr Surg.* 1999; 104: 834-840.
24. Elliot RA. Complications in the treatment of prominent ears. *Clin Plast Surg.* 1978; 5: 479.
25. Vuyk HD. Cartilage-sparing otoplasty: a review with longterm results. *J Laryngol Otol.* 1997; 111: 424.

26. Georgiade GS, Riefkohl R, Georgiade NG. *Aesthetic Plast Surg.* 1995; 19: 439.
27. Yugueros P, Friedland JA. Otoplasty: the experience of 100 consecutive patients. *Plast Reconstr Surg.* 2001; 108: 1045.
28. Messner AH, Crysedale WS. Clinical protocol and long-term results. *Arch Otolaryngol Head Neck Surg.* 1996; 122: 773-777.
29. Lourenço Gasques, Pereira de Godoy, Navarro Cruz. Psychosocial Effects of Otoplasty in Children with Prominent Ears. *Aesthetic Plast Surg.* 2008; 32: 910-914.
30. Cooper-Hobson G, Jaffe W. The benefits of otoplasty for children: further evidence to satisfy the modern NHS. *J Plast Reconstr Aesthet Surg.* 2009; 62: 190-194.

Cite this article

Mohamed Mohamed ME, Kandil SA, Hassan MA, , Mohamed Eldehn AF (2020) Prominent Ears: Impact of Combination of Techniques. *Ann Otolaryngol Rhinol* 7(2): 1239.