

Case Report

Myeloproliferative Neoplasm with FIP1L1-PDGFR α Fusion Presenting as Extramedullary Acute Myeloid Leukemia (Myeloid Sarcoma) in a Lymph Node

Jonathan Boyd^{1*}, Jun Zhang², Ramya Pinnamaneni², Ronald Mageau¹ and Ridas Juskevicius¹

¹Department of Pathology & Laboratory Medicine, Brody School of Medicine at East Carolina University, USA

²Division of Hematology-Oncology, Brody School of Medicine at East Carolina University, USA

***Corresponding author**

Ridas Juskevicius, Department of Pathology & Laboratory Medicine, Brody School of Medicine, East Carolina University, 600 Moye Blvd, Brody Medical Sciences Building 7S18, Greenville, NC 27858-4353, USA, Tel: 1-252-744-5007; Fax: 1-252-847-5394; E-mail: juskeviciusr@ecu.edu

Submitted: 23 November 2013

Accepted: 20 December 2013

Published: 21 December 2013

Copyright

© 2013 Boyd et al.

OPEN ACCESS

Keywords

- Myeloid sarcoma
- Myeloproliferative neoplasm
- Acute myeloid leukemia
- PDGFR α
- Hypereosinophilic syndrome

Abstract

Since its discovery 10 years ago, the FIP1L1-PDGFR α mutation has been associated with a wide spectrum of hematopoietic neoplasms which range from T-lymphoblastic leukemia/lymphoma, chronic eosinophilic leukemia, chronic myeloid leukemia, acute myeloid leukemia, myeloid sarcoma and systemic mastocytosis. Common between these neoplasms was eosinophilia and sensitivity to imatinib and other tyrosine kinase inhibitors. Here, we discuss the case of 51 year old man who presented with nodal myeloid sarcoma mimicking lymphoma as the presenting feature of his FIP1L1-PDGFR α myeloid neoplasm. His pelvic lymph node contained a diffuse infiltrate of blasts while his blood contained a normal white count with only mild eosinophilia. Bone marrow showed a mixed picture with areas of diffuse blasts and other areas of myeloproliferative neoplasm with eosinophilic predominance. Fluorescent in-situ hybridization demonstrated the del (4q12) and fusion of FIP1L1 and PDGFR α . The patient was treated with single agent imatinib with complete response. Our case represents the first FIP1L1-PDGFR α myeloid sarcoma to present as lymphadenopathy and only the fifth case of FIP1L1-PDGFR α myeloid sarcoma in all. The persistent remission attained in our case using only single agent imatinib reiterates the importance of identifying this mutation.

ABBREVIATIONS

MS: Myeloid Sarcoma, MPN: myeloproliferative neoplasm, HES: Hypereosinophilic Syndrome, AML: Acute Myeloid Leukemia, FIP1L1: Fip1-like 1, PDGFR α : Platelet-Derived Growth Factor Receptor Alpha, TKI: Tyrosine Kinase Inhibitor

INTRODUCTION

The FIP1L1-PDGFR α fusion protein is a constitutively active tyrosine kinase, which is extremely sensitive to the tyrosine kinase inhibitor (TKI) imatinib (250-fold more sensitive than BCR-ABL) which occurs as a cryptic deletion at 4q12 [1-3]. It was originally identified 10 years ago as a cause of idiopathic

hypereosinophilic syndrome (HES) and chronic eosinophilic leukemia [1]. Since then, it has subsequently been associated with presentations ranging from systemic mastocytosis, acute myeloid leukemia (AML), myeloid sarcoma (MS) and T lymphoblastic leukemia with eosinophilia [2-8]. It is variably associated with marked eosinophilia and may be associated with marrow involvement by atypical mast cells [1-4,8]. There is a marked male predominance and B12 and tryptase are often elevated [2,9]. These disorders respond well to tyrosine kinase inhibitor therapy and even AMLs with otherwise poor prognostic features when associated with this abnormality have been put into durable remission using imatinib [5]. Several additional fusion partners have been identified for PDGFR α (BCR, KIF5B,

CDK5RAP2, *STRN*, *ETV6*) which share a similar presentation [2]. Several *PDGFRA* mutations (T674I, D842V, S601P, L629P) have been identified which confer varying degrees of resistance to imatinib and other TKIs [1-3,6].

CASE PRESENTATION

A 51-year-old Caucasian male presented with severe back pain, night sweats, weight loss and bilateral lower extremity weakness for two weeks. Physical examination showed splenomegaly. The complete blood count (CBC) showed normal white cell count (4,000/ μ l) with mild eosinophilia (900/ μ l). No prior CBC data were available. Computed tomography (CT) showed bilateral pelvic lymphadenopathy and splenomegaly.

Fine needle aspiration (FNA) of a pelvic lymph node revealed a significant population of events with dim CD45 staining and low side scatter, corresponding to blasts. The blasts had an immature immunophenotype (dim CD11b, CD33, CD34, CD38, dim HLA-DR) most consistent with myeloid origin. There was dim expression of CD5, but no coexpression of TdT, cytoplasmic CD3 or any other B or T-cell antigens by the blasts. A diagnosis of extramedullary AML or myeloid sarcoma was made at that time (Figure 1).

Marrow biopsy section (Figure 2A) and aspirate were obtained from the iliac spine and demonstrated markedly hypercellular marrow (95%) with distinct areas containing extensive diffuse infiltrate of blasts (>80%). The blasts were intermediate to large in size and have round to oval slightly irregular nuclei with prominent nucleoli. There was significant associated eosinophilia. No normal hematopoietic elements were seen in the areas of the marrow containing the blast infiltrate. Other morphologically distinct areas seen on this biopsy had less infiltration by blasts but showed extensive eosinophilia with other more mature myeloid elements and occasional morphologically unremarkable megakaryocytes seen (Figure 2A). Reticulin stain showed marked diffuse increase in reticulin fibrosis (Figure 2C).

Touch preparations showed predominantly peripheral blood with rare bone marrow cells, including blasts. Cytochemical staining with butyrate esterase and myeloperoxidase (MPO) was performed with functional controls and showed rare cells to be positive for MPO and no cells staining for butyrate esterase. Immunohistochemical stains on the bone marrow biopsy sections demonstrated that blasts were CD34+/CD117+/CD43+ and were negative for Lysozyme and CD68 (Figure 2B). CD117+ mast cells were scattered throughout the areas of fibrosis but no mast cell aggregates were present.

Peripheral blood showed rare circulating blasts and abnormal eosinophils with atypical nuclei and features of degranulation. No prior blood counts or smears were available for evaluation. Serum vitamin B12 level was elevated at more than 2000 pg/mL (reference range 199 - 732 pg/mL). No serum tryptase measurement was performed. Electrocardiogram revealed atrial flutter with variable AV conduction and rapid ventricular response which responded to diltiazem therapy. Radionucleotide angiogram revealed normal biventricular wall motion and cardiac enzymes were below minimum detection limits (CKMB <0.2 ng/mL and troponin I <0.02 ng/mL).

Conventional cytogenetic analysis was not successful.

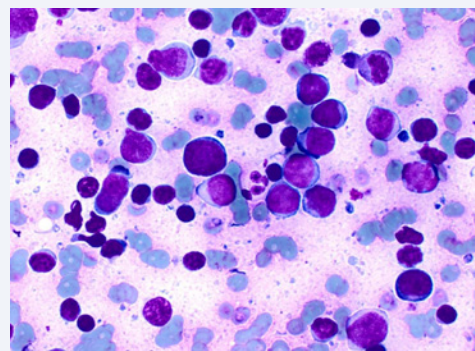


Figure 1 Fine needle aspirate of an inguinal lymph node showing a population of blasts (Diff-Quik, x400).

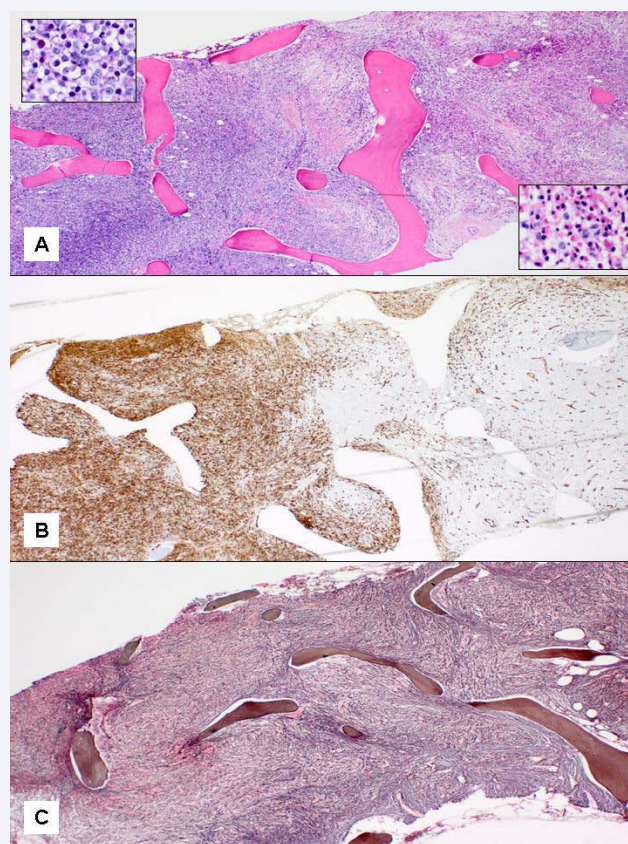


Figure 2 (A) - [Bone marrow biopsy section with diffuse infiltrate of blasts to the left and an adjacent area with predominance of mature eosinophils on the right (H&E, x40)] (B) - [Same area immunostained for CD34 (x40)] (C) - [Same area stained for reticulin (x40)].

Florescent in situ hybridization (FISH) using VYSIS 4q12 tricolor rearrangement probe revealed findings consistent with *FIP1L1-PDGFR* fusion (Figure 3). 1G1A signal indicates loss of LNX (CHIC2) [red] signal and one normal fusion signal containing intact LNX [red] probe. In addition, FISH was negative for *inv* (16), *BCR-ABL* fusion and abnormalities at 5q33 and 8p11.

The patient was treated with conventional induction chemotherapy with daunorubicin and cytarabine. Day 14 BM was acellular with focal fibrosis but no evidence of AML. Day 30 BM

was hypercellular with eosinophilia and fibrosis but no increase in blasts, consistent with chronic myeloproliferative neoplasm. Subsequently, the patient developed worsening of the back pain and lower extremity numbness. CBC at this time showed leukocytosis (9,900/ μ l) with absolute eosinophils of 3,000/ μ l. Magnetic resonance imaging (MRI) of the spine showed epidural/paraspinal tumor extending from T5 - L5 vertebrae with moderate cord compression at T11 (Figure 4A). A T11 laminectomy with epidural mass biopsy showed a myeloproliferative neoplasm with eosinophilia and fibrosis similar to BM. Imatinib was started at 400 mg/day. In two days the absolute eosinophils decreased 10 fold (to 300/ μ l). Neurological symptoms resolved in one week. Repeat MRI in two months showed near complete regression of the epidural tumor (Figure 4B). The patient has been on imatinib at 400mg daily for 10 months, and remains in complete clinical remission with histologically negative bone marrow, resolution of eosinophilia and interval complete or near complete resolution of enhancing epidural tissue throughout much of the thoracic and lumbar spine segments by MRI (Figure 4B). Follow up abdominal imaging to confirm resolution of lymphadenopathy and splenomegaly was not performed. Repeat FISH for *FIP1L1-PDGFR*A fusion was not performed. Because of uncertainty of the long term prognosis, our patient was referred for further consolidation with allogeneic stem cell transplantation.

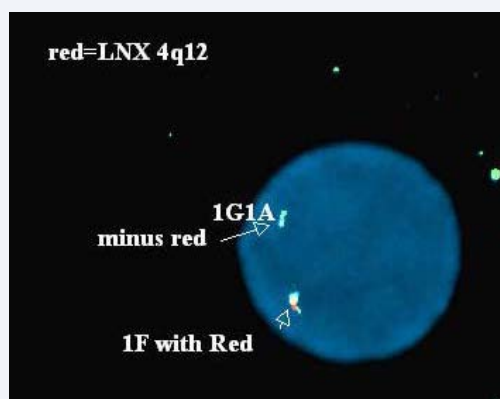

Figure 3 Nucleus of the bone marrow cell showing one tricolor green/red/aqua fusion signal and one green/aqua fusion signal. Absence of the red signal is due to the deletion of one copy of LNX (CHIC2) at 4q12 indicating the presence of the *FIP1L1-PDGFR*A fusion (FISH with Vysis LSI 4q12 Tricolor Rearrangement Probe).

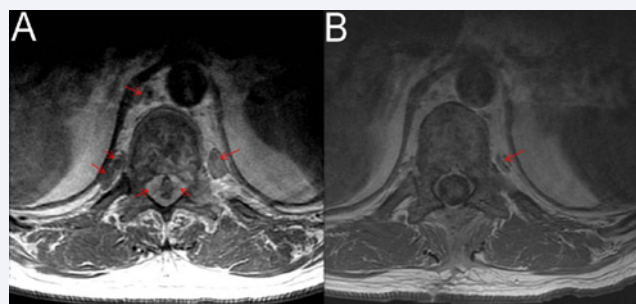


Figure 4 (A) - [Pretherapy MRI with paraspinal and epidural lesions indicated by the red arrows] (B) - [Post Imatinib treatment showing essentially complete resolution of the lesions].

DISCUSSION

Myeloproliferative neoplasms associated with *PDGFRA*, *PDGFRB* and *FGFR1* rearrangements constitute three rare distinct disease groups in the most current WHO 2008 classification of tumors of hematopoietic and lymphoid tissues [10]. These related neoplasms all result from formation of fusion gene encoding an aberrant tyrosine kinase. Eosinophilia is a characteristic feature but is not invariable. All three disorders can present as chronic MPNs with clinical and hematologic features influenced by the partner gene involved. The most common *PDGFRA* rearrangement seen is associated with *FIP1L1-PDGFR*A formed as a result of cryptic deletion at 4q12. MPNs with *PDGFRA* rearrangements usually present as chronic eosinophilic leukemia with end organ damage. Presentation of a myeloproliferative neoplasm with *FIP1L1-PDGFR*A fusion as an extramedullary AML (myeloid sarcoma) is exceedingly rare. We have identified four cases in the literature. Cools et al reported a 39-year-old man with complex cytogenetics and *FIP1L1-PDGFR*A fusion presenting with cranial palsies and paraspinal masses, who achieved complete hematological remission with imatinib but relapsed after 5 months due to T674I mutation in the fusion gene [1]. Vedy et al reported a 63-year-old male with AML with eosinophilia, myeloid sarcoma involving sphenoid, lumbar and cervical vertebrae, complex cytogenetics, *FLT3*-ITD and *FIP1L1-PDGFR*A fusion who achieved complete remission even after discontinuation of imatinib therapy [5]. Tang et al reported a 33-year-old male with *FIP1L1-PDGFR*A associated myeloproliferative neoplasm and myeloid sarcoma presenting as a subgaleal mass over occipital bone with bony destruction with complete molecular remission using imatinib alone [7]. Chen et al reported a subcutaneous *FIP1L1-PDGFR*A myeloid sarcoma with eosinophilia with durable remission on imatinib maintenance therapy [8]. Interestingly, all but one of these myeloid sarcomas were associated with either a paraspinal mass or a skull based lesion, similar to our case. To the best of our knowledge, this is the first case of this entity presenting as extramedullary AML in a lymph node, clinically mimicking lymphoma.

Traditional therapy for myeloid sarcoma is chemotherapy similar to acute myeloid leukemia while the patients with *PDGFRA* rearrangements have great responsiveness to imatinib [8]. Indeed, long term follow up on a case series of *FIP1L1-PDGFR*A cases demonstrated sustained remission even after withdrawal of imatinib. There was a median survival of 10 months for patients not treated with imatinib versus 94% survival at 200 months for the patients treated with imatinib [11]. Given the therapeutic implication and the fact that these tumors can present as AML in extramedullary sites as illustrated by our case, the importance of screening for *PDGFRA* rearrangement in patients presenting with AML and/or myeloid sarcoma with eosinophilia cannot be overemphasized.

ACKNOWLEDGEMENTS

We thank Dr. Joseph Lurido in Physician's East Radiology, Vidant Healthcare System for his expertise and help with radiographic images.

REFERENCES

1. Cools J, DeAngelo DJ, Gotlib J, Stover EH, Legare RD, Cortes J, et al. A tyrosine kinase created by fusion of the PDGFRA and FIP1L1 genes as a therapeutic target of imatinib in idiopathic hypereosinophilic syndrome. *N Engl J Med*. 2003; 348: 1201-1214.
2. Bain BJ. Myeloid and lymphoid neoplasms with eosinophilia and abnormalities of PDGFRA, PDGFRB or FGFR1. *Haematologica*. 2010; 95: 696-698.
3. Metzgeroth G, Walz C, Score J, Siebert R, Schnittger S, Haferlach C, et al. Recurrent finding of the FIP1L1-PDGFR fusion gene in eosinophilia-associated acute myeloid leukemia and lymphoblastic T-cell lymphoma. *Leukemia*. 2007; 21: 1183-1188.
4. Pardanani A, Ketterling RP, Li CY, Patnaik MM, Wolanskyj AP, Elliott MA, et al. FIP1L1-PDGFR in eosinophilic disorders: prevalence in routine clinical practice, long-term experience with imatinib therapy, and a critical review of the literature. *Leuk Res*. 2006; 30: 965-970.
5. Védý D, Muehlemaier D, Rausch T, Stalder M, Jotterand M, Spertini O. Acute myeloid leukemia with myeloid sarcoma and eosinophilia: prolonged remission and molecular response to imatinib. *J Clin Oncol*. 2010; 28: e33-35.
6. Sorour Y, Dalley CD, Snowden JA, Cross NC, Reilly JT. Acute myeloid leukaemia with associated eosinophilia: justification for FIP1L1-PDGFR screening in cases lacking the CBFβ-MYH11 fusion gene. *Br J Haematol*. 2009; 146: 225-227.
7. Tang TC, Chang H, Chuang WY. Complete response of myeloid sarcoma with FIP1L1-PDGFR -associated myeloproliferative neoplasms to imatinib mesylate monotherapy. *Acta Haematol*. 2012; 128: 83-87.
8. Chen D, Bachanova V, Ketterling RP, Begna KH, Hanson CA, Viswanatha DS, et al. A case of nonleukemic myeloid sarcoma with FIP1L1-PDGFR rearrangement: an unusual presentation of a rare disease. *Am J Surg Pathol*. 2013; 37: 147-151.
9. Klion AD, Noel P, Akin C, Law MA, Gilliland DG, Cools J, et al. Elevated serum tryptase levels identify a subset of patients with a myeloproliferative variant of idiopathic hypereosinophilic syndrome associated with tissue fibrosis, poor prognosis, and imatinib responsiveness. *Blood*. 2003; 101: 4660-4666.
10. Swerdlow SH, Campo E, Harris NL, Jaffe ES, Pileri SA, Stein H, et al, editors. *Classification of Tumours of Haematopoietic and Lymphoid Tissues*. 4th ed.: IARC-WHO; 2008. p61-73
11. Pardanani A, D'Souza A, Knudson RA, Hanson CA, Ketterling RP, Tefferi A. Long-term follow-up of FIP1L1-PDGFR-mutated patients with eosinophilia: survival and clinical outcome. *Leukemia*. 2012; 26: 2439-2441.

Cite this article

Boyd J, Zhang J, Pinnamaneni R, Mageau R, Juskevicius R (2013) Myeloproliferative Neoplasm with FIP1L1-PDGFR Fusion Presenting as Extramedullary Acute Myeloid Leukemia (Myeloid Sarcoma) in a Lymph Node. *Ann Clin Pathol* 1(1): 1006.