

Case Report

Dermoscopic, Confocal Microscopic, and Histologic Characteristics of an Atypical Presentation of Molluscum Contagiosum

Marez Megalla*, Tara Bronsnick, Omar Noor, Babar Rao

Department of Dermatology, Rutgers- Robert Wood Johnson School of Medicine, USA

*Corresponding author

Marez Megalla, 675 Hoes Lane, Piscataway, NJ, USA, Tel: 732-743-5484; Fax: 732-235-6568; E-mail: megallma@rwjms.rutgers.edu

Submitted: 19 November 2014

Accepted: 25 November 2014

Published: 27 November 2014

Copyright

© 2014 Megalla et al.

OPEN ACCESS

Keywords

- Molluscum
- Confocal
- Dermoscopy
- Henderson-Paterson bodies

Abstract

Molluscum Contagiosum is a common and easily diagnosed skin condition; however, in immunosuppressed patients, presentations may be atypical requiring biopsy. The histopathology of molluscum is nearly unmistakable with the Henderson-Paterson bodies being pathognomonic for the condition. Reflectance confocal microscopy (RCM) is a new, non-invasive technique which can be used to diagnose molluscum contagiosum. We present a 35-year-old male patient who presents with four umbilicated papules on his left abdomen following unsuccessful treatment for herpes zoster infection by his primary care physician. A quick bedside diagnosis of molluscum contagiosum was made using confocal microscopy (Vivascope 1500, Lucid Inc, Rochester, NY).

ABBREVIATIONS

RCM: reflectance confocal microscopy

INTRODUCTION

Molluscum contagiosum is a self-limited poxvirus that primarily infects children with a prevalence estimate of 8% [1]. Sexually active young adults and immunocompromised patients are also common populations affected by this virus. Transmitted by direct skin contact, molluscum contagiosum is characterized by flesh-colored, dome-shaped, umbilicated nodules filled with white, waxy material [2]. While most individual molluscum lesions clear on their own in two months, autoinoculation leads to a never-ending crop of papules. Immunocompromised patients, in particular, more commonly have refractive lesions with prolonged clearance times [2]. Treatments include potassium hydroxide, imiquimod, and cryotherapy. While both potassium hydroxide and cryotherapy produce results quicker than imiquimod, they are equally effective in the clearance of the papules [3,4]. Although there is no current vaccine for molluscum contagiosum, prevention would include not touching the infected skin or products, such as towels or clothing that have come in contact with the papules [5]. To lessen the time of clearance, patients should be advised to avoid scratching the lesion to prevent autoinoculation.

Diagnosis of molluscum contagiosum is often done clinically

or with histopathology, in which characteristic Henderson-Paterson bodies, representing intracytoplasmic assemblies of the virus, are pathognomonic [2]. Non-invasive measures such as dermoscopy and reflectance confocal microscopy may also be used for diagnosis. Dermoscopy allows for the visualization of vasculature and skin lesions with a magnification up to 100x [6]. Confocal microscopy obtains sharp 3D images of a skin lesion up to 200 μm in depth [7]. While dermoscopic patterns of molluscum have been analyzed, there is minimal documentation of molluscum's appearance under confocal microscopy.

CASE PRESENTATION

A 35 year old white male presented to a dermatology clinic with four umbilicated, pink papules on his left abdomen (Figure 1). For several weeks, the patient was treated with acyclovir for herpes zoster infection by his primary care physician without significant improvement. Although clinical presentation was atypical but consistent with molluscum contagiosum, dermoscopy and confocal microscopy was used to make a quick bedside diagnosis. On dermoscopy, the lesions were lobular, yellow papules with a mixed vascular pattern, including crown and radial vessels (Figure 2). Lobular papules (Figure 3) with oval-shaped bodies containing refractile structures, mimicking Henderson-Paterson bodies (Figure 4), were visualized on reflectance confocal microscopy (RCM) (Vivascope 1500, Lucid Inc., Rochester, NY). Due to its atypical presentation, the lesion

was also biopsied, which revealed classic Henderson-Paterson bodies on histology (Figure 5).

DISCUSSION

Molluscum contagiosum is a benign skin condition that is usually easy to diagnose. Atypical cases, especially in

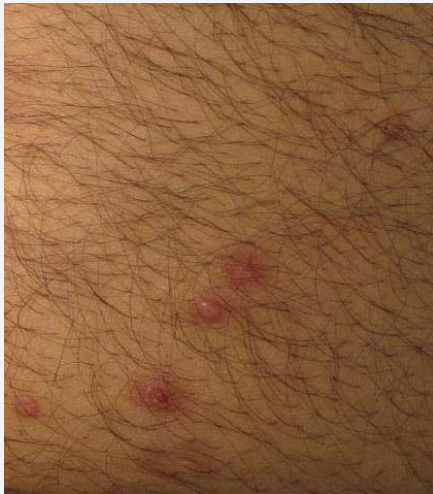

Figure 1 Four discrete, dome-shaped, umbilicated papules on the left abdomen.



Figure 2 Dermoscopy reveals a lobular papule with crown and radial vessels (10X).

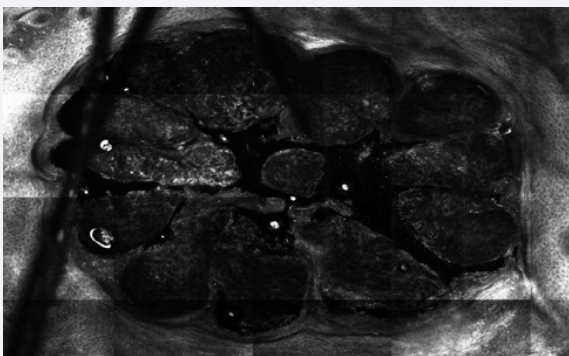


Figure 3 Reflectance confocal microscopy image of molluscum nodule at the level of the dermal-epidermal junction (depth of 200µm).

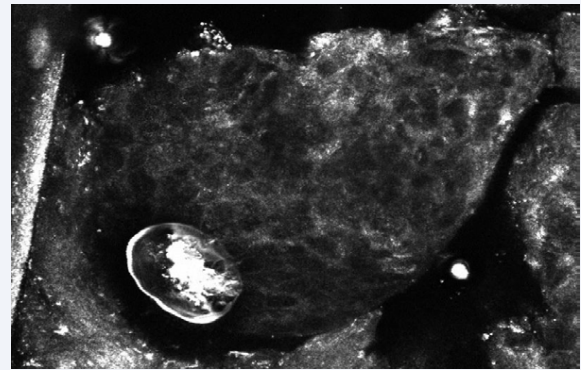


Figure 4 High-powered view of reflectance confocal microscopy image depicting an oval structure containing refractile structures (arrow) mimicking the Henderson Paterson bodies (depth of 50µm).

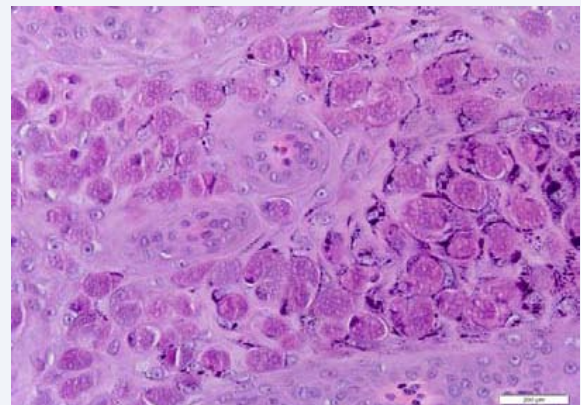


Figure 5 Histopathology of a typical molluscum contagiosum nodule with pathognomonic Henderson-Paterson bodies present in the dermis (H&E, 10X).

immunocompromised patients, may create diagnostic difficulties as molluscum nodules are often misinterpreted as fungal infections, herpes simplex [8], and other skin lesions. When clinical diagnosis is ambivalent, skin biopsy is usually diagnostic with pathognomonic Henderson-Paterson bodies. Non-invasive diagnostic tools such as dermoscopy and reflectance confocal microscopy may be helpful and avoid the need for biopsy in these cases.

When molluscum contagiosum papules were first analyzed under dermoscopy, they presented with a yellowish white central orifice circumscribed by vessels termed as “red corona” or red crown [9]. Identification of the presence of both structures, particularly the vascular pattern, is difficult to the unaided eye but was augmented with dermoscopy. While the crown vascular arrangement remains to be fairly common in papules, it is not the only arrangement described. Vasculature entering perpendicular to the orifice, termed radial vessels, and vessels appearing as small red dots within the papule, termed punctiform vessels, have also been described. The radial vessels can also be seen in a flower pattern, if they divide the papule into structures resembling flower petals. Papules can have also a mix of these vascular patterns, of which the crown and radial pattern was most common [10-12].

To our knowledge, there is only one other RCM report [13] of molluscum contagiosum, which reports the presence of refractile structures consistent with Henderson-Paterson bodies. The findings in our patient are consistent with previously reported dermoscopic, confocal, and histologic features of molluscum. This case highlights the utility of non-invasive diagnostic tools, especially RCM, in unusual presentations of molluscum contagiosum.

REFERENCES

1. Olsen JR, Gallacher J, Piguet V, Francis NA. Epidemiology of molluscum contagiosum in children: a systematic review. *Fam Pract.* 2014; 31: 130-136.
2. Chen X, Anstey AV, Bugert JJ. Molluscum contagiosum virus infection. *Lancet Infect Dis.* 2013; 13: 877-888.
3. Metkar A1, Pande S, Khopkar U. An open, nonrandomized, comparative study of imiquimod 5% cream versus 10% potassium hydroxide solution in the treatment of molluscum contagiosum. *Indian J Dermatol Venereol Leprol.* 2008; 74: 614-618.
4. Gamble RG, Echols KF, Dellavalle RP. Imiquimod vs cryotherapy for molluscum contagiosum: a randomized controlled trial. *Arch Dermatol.* 2012; 148: 109-112.
5. Choong KY, Roberts LJ. Molluscum contagiosum, swimming and bathing: a clinical analysis. *Australas J Dermatol.* 1999; 40: 89-92.
6. Wassef C, Mateus R, Rao B. Noninvasive Imaging Tools in the Management of Facial Pigmented Lesions. *Practical Dermatology.* 2011; 25-27.
7. Nwaneshiudu A, Kuschal C, Sakamoto FH, Anderson RR, Schwarzenberger K, Young RC. Introduction to confocal microscopy. *J Invest Dermatol.* 2012; 132: e3.
8. Angeleri A, Vighi S, Rocher AE, Peressini S, Palaoro LA. Usefulness of cytology in the diagnosis of molluscum contagiosum on skin papules. *Cytopathology.* 2012; 23: 344-345.
9. Vázquez-López F, Kreusch J, Marghoob AA. Dermoscopic semiology: further insights into vascular features by screening a large spectrum of nontumoral skin lesions. *Br J Dermatol.* 2004; 150: 226-231.
10. Ianhez M, Cestari Sda C, Enokihara MY, Seize MB. Dermoscopic patterns of molluscum contagiosum: a study of 211 lesions confirmed by histopathology. *An Bras Dermatol.* 2011; 86: 74-79.
11. Zaballos P, Ara M, Puig S, Malvey J. Dermoscopy of molluscum contagiosum: a useful tool for clinical diagnosis in adulthood. *J Eur Acad Dermatol Venereol.* 2006; 20: 482-483.
12. Morales A, Puig S, Malvey J, Zaballos P. Dermoscopy of molluscum contagiosum. *Arch Dermatol.* 2005; 141: 1644.
13. Scope A, Benvenuto-Andrade C, Gill M, Ardigo M, Gonzalez S, Marghoob AA. Reflectance confocal microscopy of molluscum contagiosum. *Arch Dermatol.* 2008; 144: 134.

Cite this article

Megalla M, Bronsnick T, Noor O, Rao B (2014) Dermoscopic, Confocal Microscopic, and Histologic Characteristics of an Atypical Presentation of Molluscum Contagiosum. *Ann Clin Pathol* 2(5): 1038.