

## Case Report

# A Case of Pancytopenia and Reticulocytopenia with Multiple Granulomas on Bone Trephine Biopsy

Ayesha Majeed Memon<sup>1</sup> and Muhammad Usman Shaikh<sup>2\*</sup><sup>1</sup>Department of Pathology and Laboratory Medicine, Aga Khan University Hospital, Pakistan<sup>2</sup>Consultant Hematologist, Aga Khan University Hospital, Pakistan

## BREIF HISTORY

55 Years female presented with the history of fever, weakness and weight loss for two months. Examination reveals pallor, rest of examination is unremarkable. Base line CBC shows pancytopenia and reticulocytopenia. Bone marrow done for workup.

Peripheral Blood Counts:

HB: 8.2 G/DL

HCT: 25.0 %

MCV: 72.5 FL

MCH: 23.8 PG

WBC'S: 3.8 x 10E9/L

ANC: 3.1 x 10E9/L

PLATELETS: 129 x 10E9/L

CORRECTED RETICULOCYTE COUNT: 0.8%

Her peripheral blood film showed anisocytosis, hypochromia, microcytosis, poikilocytosis and elliptical cells. Bone marrow aspirate was hypocellular specimen. Bone trephine biopsy showed trilineage haematopoiesis along with multiple well defined large areas of non-caseating granulomas exhibiting lymphohistiocytic collection along with plasma cells. Many epithelioid cells were visible along with few giant cells. ZN stain was applied but was negative for AFB.

Considering the history of fever and granulomatous inflammation, Tuberculosis was top among Differential diagnosis unfortunately patient was lost to follow up because of financial constrains.

## DISCUSSION

Bone marrow examination plays pivotal role in the diagnosing haematological as well as non-haematological disorders [1], hence making it one of the important investigations for the workup

### \*Corresponding author

Muhammad Usman Shaikh, Department of Pathology and Laboratory Medicine, Aga Khan University Hospital, Consultant Hematologist, Section of Haematology, Karachi, Pakistan, Email: usman.shaikh@aku.edu

Submitted: 15 March 2016

Accepted: 18 April 2016

Published: 20 April 2016

ISSN: 2373-9282

Copyright

© 2016 Shaikh et al.

OPEN ACCESS

of pyrexia of unknown origin (PUO) [2]. One of the prominent finding could be presence of granulomas while examining bone trephine biopsy specimen. Granulomas are found in around 2% of trephine biopsies [3]. They are reported to be associated with various infections, connective tissue disorders, lymphomas or metastatic carcinomas [4]. Bone marrow granulomas were first ever diagnosed by Pease in the year 1956. In some cases of bone marrow granulomas, causative reason may be hidden [5]. Unfortunately in our patient's blood and bone marrow cultures could not be done as patient was lost to follow up.

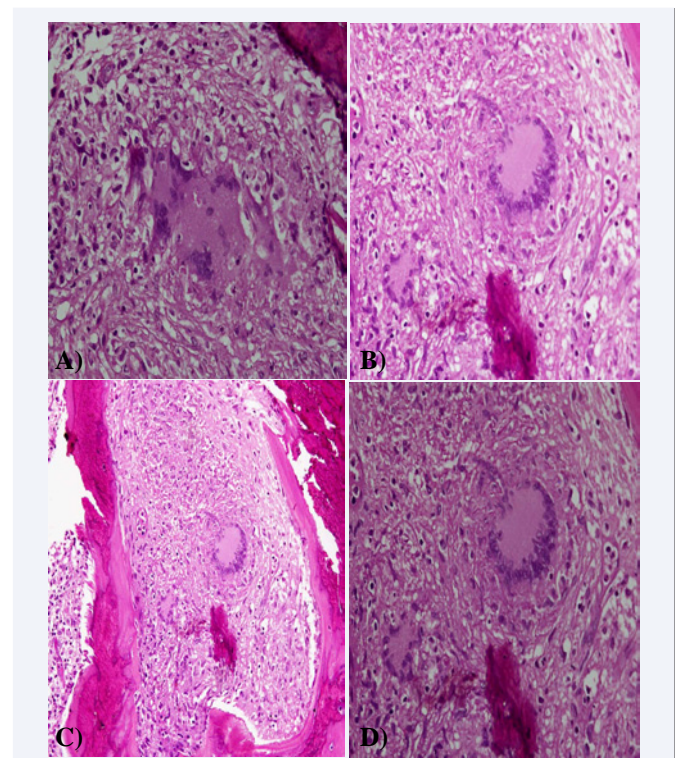


Figure 1

## REFERENCES

1. Toi PCh, Varghese RG, Rai R. Comparative evaluation of simultaneous bone marrow aspiration and bone marrow biopsy: an institutional experience. *Indian J Hematol Blood Transfus.* 2010; 26: 41-44.
2. Laing RBS. Fever and Pyrexia of Unknown Origin. *Medicine.* 2001; 29: 24-26.
3. Vilalta-Castel E, Valdés-Sanchez MD, Guerra-Vales JM, Teno-Esteban C, Garzón A, López JI, et al. Significance of granulomas in bone marrow: a study of 40 cases. *Eur J Haematol.* 1988; 41: 12-16.
4. Bodem CR, Hamory BH, Taylor HM, Kleopfer L. Granulomatous bone marrow disease. A review of the literature and clinicopathologic analysis of 58 cases. *Medicine (Baltimore).* 1983; 62: 372-383.
5. Pease GL. Granulomatous lesions in bone marrow. *Blood.* 1956; 11: 720-734.

### Cite this article

Memon AM, Shaikh MU (2016) A Case of Pancytopenia and Reticulocytopenia with Multiple Granulomas on Bone Trepine Biopsy. *Ann Clin Pathol* 4(3): 1073.