

## Research Article

# Inter-Observator Variability and the Value of Histological Examination in the Classification of Ampullary Carcinomas

L TahiriElousrouti<sup>1\*</sup>, FZ Erreggad<sup>1</sup>, G Atsame<sup>1</sup>, B Efared<sup>1</sup> and L Chbani<sup>2</sup>

<sup>1</sup>Department of Pathology, Hospital University Hassan II, Morocco

<sup>2</sup>Biomedical research and translational laboratory, University Sidi Mohammed Ben Abdellah, Morocco

## \*Corresponding author

Layla Tahiri Elousrouti, Department of pathology, Hospital University Hassan II, Fes, Morocco, Tel: 00212662101728; Email: laylatahiri.elous@gmail.com

Submitted: 18 April 2016

Accepted: 12 May 2016

Published: 13 May 2016

ISSN: 2373-9282

Copyright

© 2016 Elousrouti et al.

OPEN ACCESS

## Keywords

- Ampulla of Vater
- Carcinoma
- Inter-Observator variability
- Histological examination

## Abstract

The ampullary carcinomas represent 7% of carcinoma arising in pancreatobiliary region. Adenocarcinoma is the dominant histological type, observed in 90% of cases. The determination of the intestinal or pancreatobiliary origin have a double interests; prognostic and therapeutic. The aim of this study is to evaluate the value of histological examination in determining the origin of ampullary carcinomas.

We reviewed 35 cases of ampullarytumors, collected in the Department of Pathology of Hassan II university Hospital of Fez (Morocco) over a period of 2 years. Two pathologists reviewed, independently, all the cases, without clinical or radiological information. They were based on histological criteria defined in the WHO classification of digestive tumours. The Kappa coefficient is used to assess agreement.

Our study showed a medium reproducibility of histological examination in the diagnosis of ampullary carcinomas, with good agreement for the intestinal type. The distinction between these histological subtypes is required given its prognostic and therapeutic implications. The standard histological examination allows in most cases the determination of intestinal or biliopancreatic origin, based on architectural criteria and cyto-nuclear. Using immune histochemical supplements prove necessary in the loss morphological criteria or discordant cases overlap.

## INTRODUCTION

The ampulla of Vater is a vital structure traversed by important ducts and surrounded by the pancreas and the duodenum. The ampullary carcinomas account for 7% of Carrefour pancreatobiliary carcinomas [1]. Adenocarcinoma is the dominant histological type, observed in 90% of cases. The determination of the intestinal or pancreatobiliary origin have a double interests; prognostic and therapeutic [2]. Carcinomas of the pancreatobiliary subtype are found to be more aggressive than that of the intestinal subtype, since the 5-year survival is 48% for pancreatobiliary origin against 73% for intestinal origin. Similarly, for chemotherapy response, same authors have suggested that patients with pancreatobiliary-type carcinomas may benefit from gemcitabine therapy, and those with intestinal-

type tumours may benefit from a 5-fluorouracil (5-FU)-based regimen [3].

## MATERIAL AND METHODS

## Clinical Data and Tumor Specimen Acquisition

This study was restricted to 35 patients with ampullary carcinoma collected in the Department of Pathology of Hassan II University Hospital of Fez (Morocco) over a period of 2 years. Ampullary carcinomas included in our study were identified from the pathology and surgery databases.

Data on clinical variables, including sex and age were gathered retrospectively from patients' reports. All specimens underwent gross anatomical examination according to the procedure described by Rosai, including evaluation of all anatomic structures

in surgical resection (pancreatic duct, ampulla of Vater, common bile duct, and pancreatic head) [4].

**Histology**

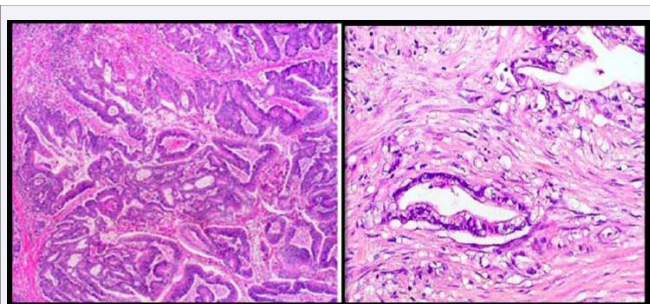
All specimens were fixed in 10 % buffered formaldehyde and embedded in paraffin. The samples were sectioned at 5 µm and stained with hematoxylin and eosin. Histological diagnosis was re-examined by 2 independent pathologists (P1 and P2), without clinical or radiological information. All tumours were classified histologically according to the criteria published in WHO classification of digestive tumours [5] (Figure 1, Table 1) So, intestinal subtype carcinoma was defined as a tumour morphologically similar to colorectal carcinoma, it characterized from well-formed tubular to elongate glands, complex cribriform areas, and solid nests, composed of columnar cells with hyperchromatic and pseudostratified nuclei. So-called “dirty” necrosis was used as a feature supportive of intestinal subtype. Pancreaticobiliary subtype carcinomas resembled to conventional pancreatic ductal adenocarcinoma and was defined as mostly consisting of simple or branching glands and small solid nests composed of cuboidal to low columnar cells and more rounded nuclei arranged in a single layer, often surrounded by desmoplastic stroma. Tumours with mixed pattern were classified according to their predominant component into the pancreaticobiliary-type or intestinal-type group. Carcinomas that contained >50% extracellular, nonluminal, mucin were categorized as mucinous subtype. While those with a solid pattern or infiltrating single cells lacking any intestinal or pancreaticobiliary morphology were classified as poorly differentiated carcinomas.

**Statistical Analysis**

Kappa statistics were used to assess the overall agreement and individual category agreement for histologic typing. A k value more than 0.8 was considered to indicate excellent agreement, a value between 0.6 and 0.8 was considered to indicate good agreement, a value between 0.4 and 0.6 was considered to indicate medium agreement, and a value between 0.2 and 0.4 was considered to indicate poor agreement (Table 2).

P-value of <0.05 was considered statistically significant.

The results of histology were compared with radiological data to evaluate the value of the histological examination.



**Figure 1** On left an intestinal-type ampullary adenocarcinoma. On right, a pancreaticobiliary- type ampullary adenocarcinoma.

**Table 1:** Histological criteria defined in the WHO Book for diagnosis of ampullary carcinoma.

Histological subtype	Morphological criteria
Intestinal	Well- formed tubular, elongate glands, complex cribriform areas, and solid nests. Columnar cells with hyperchromatic and pseudostratified nuclei. “Dirty” necrosis.
Pancreatobiliary	Simple or branching glands, small solid nests, papillary and micro-papillary architectures could also occur. Cuboidal to low columnar cells and more rounded nuclei arranged in a single layer. Desmoplastic stroma.
Poorly differentiated	Solid pattern or infiltrating single cells lacking any intestinal or pancreaticobiliary morphology.
Mucinous	Carcinomas that contained >50% extracellular, nonluminal, mucin.

**Table 2:** Signification of Kappa coefficient.

Kappa Coefficient	Signification
0,8-1	Excellent
0,6-0,8	Good
0,4-0,6	Medium
0,2-0,4	Poor
0-0,2	Negligible
<0	Bad

**RESULTS**

**Demographics characteristics**

35 cases of ampullary carcinomas were reviewed by two pathologists. The cases were distributed between 61% women and 39% men. The average age is 58 years (33-86 years).

**Histological subtypes**

Pathologist 1 (P1) confirmed the intestinal subtype carcinomas in 30 (83%) cases and pancreaticobiliary subtype carcinomas in 5 (17%) cases. Pathologist 2 (P2) confirmed the intestinal subtype carcinomas in 15 (42%) cases, pancreaticobiliary subtype carcinomas in 14 (40%) cases, and poorly differentiated carcinomas in 6 (18%) cases. In radiology, the intestinal subtype carcinoma was suspected in 25 (71%) cases and the pancreaticobiliary subtype carcinoma was suspected in 10 (29%) (Figure 2).

**Interobserver agreement of histologic classification**

When results of the independent review were compared, agreement of HES typing was achieved in 21 of 35 cases (60%). These included 16 (46%) for intestinal subtype, and only 5 (14%) pancreaticobiliary subtype. Fourteen of the 35 case (40%) were discordant (Table 3, Figure 2).

The agreement between the two pathologists in the diagnosis

of ampullary carcinomas is medium ( $K = 0.425$ ) and between the pathologist 2 and radiology data is good ( $K = 0.684$ ) (Table 4).

**DISCUSSION**

The ampullary region is a transition zone between a biliopancreatic epithelium and intestinal epithelium. This explains the histological variation in ampullary adenocarcinomas: intestinal, pancreatobiliary, poorly differentiated and mucinous. The distinction between these histological subtypes is required given its prognostic and therapeutic implications [1].

Carcinomas of the ampulla of Vater represent 0.5% of gastrointestinal carcinomas and 7% of carcinomas arising in

the region of the head of the pancreas [2]. Although uncommon, ampullary adenocarcinoma accounts for 90% of ampullary epithelial neoplasms, and its incidence has been increasing since 1973 [2,7].

Histologically, these tumors can resemble either intestinal-type carcinomas of the duodenum or pancreatobiliary-type carcinomas of the pancreas and bile duct, or they can be poorly differentiated, precluding further histologic categorization. The current classification of ampullary carcinomas relies on this distinction and also includes uncommon subtypes such as mucinous adenocarcinoma [4,5].

A definite diagnosis of ampullary carcinomas can still be worn with current diagnostic tools. The diagnosis relies on radiological and histological confrontation. Histologically, there is not at present a “gold standard” to confirm intestinal or biliopancreatic origin. In fact this diagnosis is founded on architectural and cytonuclear criteria that can orient towards to any particular origin. The best histological signs were defined in the WHO classification of digestive tumours [5] and were re evaluated in our series. The intestinal subtype is formed tubular to elongate glands, complex cribriform areas, and solid nests composed of columnar cells with hyperchromatic and pseudostratified nuclei. So called “dirty” necrosis was used as a feature supportive of intestinal subtype. The pancreatobiliary subtype resemble to conventional pancreatic ductal adenocarcinoma and was defined as mostly consisting of simple or branching glands and small solid nests composed of cuboidal to low columnar cells and more rounded nuclei arranged in a single layer, often surrounded by desmoplastic stroma [5,6].

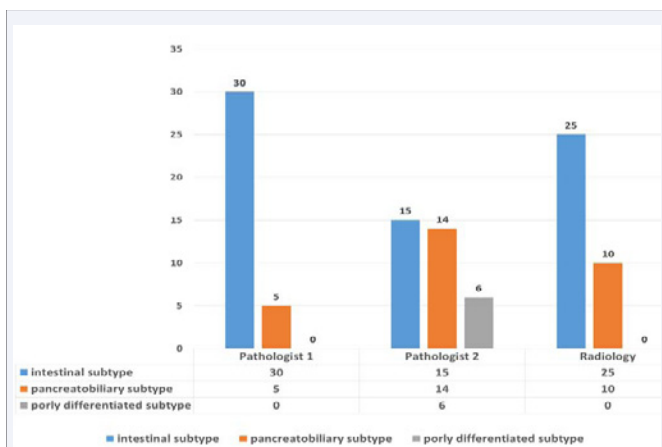
Using systematic HES review, this study achieved a major observation. The histologic typing of ampullary carcinomas into intestinal, pancreatobiliary, mixed, mucinous, and poorly differentiated subtypes using the current definitions is feasible, with an overall concordance rate of 60% among two pathologists.

Similar to previous retrospective studies, we found that the majority (21/35) of ampullary carcinomas fulfilled the morphologic criteria for either intestinal or pancreatobiliary subtypes [1,3,7]. However, our interobserver variability study demonstrated that the agreement among observers even on these two major subtypes was “medium,” with a k value of 0.42 (Table 5). Among the less common histologic subtypes, although excellent agreement among observers was obtained for poorly differentiated tumours. These findings highlight the difficulties in differentiating ampullary carcinomas of pancreatobiliary subtype from that of intestinal subtype. The difficulties reflect the fact that the morphology of these 2 subtypes can overlap: some nuclear pseudo stratification can occur in pancreatobiliary subtypes, as can luminal necrosis; intestinal subtype can have more simple glands; both subtypes can have some solid nests or even a frank micropapillary pattern. It should be further noted that the relatively medium reproducibility in this study may reflect a high level of experience with classifying ampullary carcinomas among the study authors.

In most studies [6-8] carcinomas of the pancreatobiliary subtype are found to be more aggressive than that of the intestinal subtype (5-yr disease survival rate of 48% vs. 73%10).

**Table 3:** Results of histological review and the comparison with radiology.

Pathologist 1(P1)	Pathologist 2 (P2)	imagery	Total
intestinal	intestinal	intestinal	16
Pancreatobiliary	Pancreatobiliary	Pancreatobiliary	5
Pancreatobiliary	intestinal	Pancreatobiliary	1
intestinal	intestinal	Pancreatobiliary	1
intestinal	Pancreatobiliary	intestinal	3
intestinal	Pancreatobiliary	Pancreatobiliary	3
intestinal	Poorly differentiated	intestinal	6



**Figure 2** Results of histological review and the comparison with radiology.

**Tables 4:** The agreement between the two pathologists and radiology.

	P1/P2	P2/imagery	P1/imagery
Kappa Coefficient	0,425	0,371	0,684
signification	Medium	Poor	Good
P	0,01	0,001	<0,0001

**Table 5:** Comparison of agreement in different studies.

	Daphne [1]	Our study
Agreement interobserver	77%	60%
Kappa	0,57= good	0,42= Medium

In other studies [5,9], however, such an association has not been observed or not proven to be statistically significant. Similarly, for chemotherapy response, small retrospective studies have suggested that patients with pancreatobiliary-type carcinomas may benefit from gemcitabine therapy, and those with intestinal-type tumors may benefit from a 5-fluorouracil (5-FU)-based regimen.

For these reasons, immunohistochemistry support for the morphologic classification of ampullary carcinomas is highly desirable, especially for pathologists without extensive experience in this arena.

## CONCLUSION

Our study showed a medium reproducibility of histological examination in the diagnosis of ampullary carcinomas, with good agreement for the intestinal type. The distinction between these histological subtypes is required given its prognostic and therapeutic implications. The standard histological examination allows in most cases the determination of intestinal or biliopancreatic origin, based on architectural criteria and cyto-nuclear. Using immunohistochemical supplements prove necessary in the loss morphological criteria or discordant cases overlap.

## REFERENCES

1. Ang DC, Shia J, Tang LH, Katabi N, Klimstra DS. The utility of immunohistochemistry in subtyping adenocarcinoma of the ampulla of vater. *Am J Surg Pathol*. 2014; 38: 1371-1379.
2. Albores-Saavedra J, Schwartz AM, Batich K, Henson DE. Cancers of the ampulla of vater: demographics, morphology, and survival based on 5,625 cases from the SEER program. *J Surg Oncol*. 2009; 100: 598-605.
3. Florence Le Pessot, Marie-Laure Ranty, Marie-France Hellot, Françoise Lemoine, Paul Ténrière, Jacques Testart, et al. Expression immunohistochimique des cytokératines 7 et 20 dans les carcinomes ampullaires. *Ann Pathol* 2004; 24: 312-318.
4. Albores-Saavedra J, Hensen DE, Klimstra DS. Tumors of gallbladder, extrahepatic bile ducts, and ampulla of vater. In: Rosai J, Sobin L, eds. *Atlas of Tumor Pathology, Fourth Series, Fascicle*. Washington, DC: Armed Registry of Pathology; 2014.
5. WHO Classification of Tumours Pathology and Genetics of the Digestive System. Lyon: IARC; 2010: 203-218.
6. Westgaard A, Tafjord S, Farstad IN. Pancreatobiliary versus intestinal histologic type of differentiation is an independent prognostic factor in resected periampullary adenocarcinoma. *BMC cancer*. 2008; 8:170.
7. Morini S, Perrone G, Borzomati D, Vincenzi B, Rabitti C, Righi D, et al. Carcinoma of the ampulla of Vater: morphological and immunophenotypical classification predicts overall survival. *Pancreas*. 2013; 42: 60-66.
8. Kim WS, Choi DW, Choi SH, Heo JS, You DD, Lee HG. Clinical significance of pathologic subtype in curatively resected ampulla of vater cancer. *J Surg Oncol*. 2012; 105: 266-272.
9. Roh YH, Kim YH, Lee HW, et al. The clinicopathologic and immunohistochemical characteristics of ampulla of Vater carcinoma: the intestinal type is associated with a better prognosis. *Hepatogastroenterology*. 2007; 54:1641-1644.

### Cite this article

Elousrouti LT, Erreggad FZ, Atsame G, Efared B, Chbani L (2016) Inter-Observator Variability and the Value of Histological Examination in the Classification of Ampullary Carcinomas. *Ann Clin Pathol* 4(4): 1079.