

Review Article

Ocular Hydatid Cyst

Shreya Thatte^{1*} and Sharvil Thatte²¹Department of Ophthalmology, Sri Aurobindo Medical College and PG Institute, India²Final MBBS Student, Seth GS Medical College, India**Abstract**

Hydatid disease is a common parasitic infestation in many parts of the world with involvement of any organ inside the human body. Ocular hydatid cyst is a relatively rare entity. It may remain asymptomatic and can cause sight threatening symptoms with increase in size. Therefore, early diagnosis with the help of radio-imaging can be helpful to dictate the proper line of medical or surgical management in these patients.

INTRODUCTION

Parasitic infestation in humans is a common entity. It can involve any organ of the human body. The parasitic infections are varied and include protozoa, nematodes, cestodes, trematodes and ectoparasites.

Hydatid disease is one of the common parasitic infestations by a tapeworm of the genus *Echinococcus* in many parts of the world. It is endemic in the Middle East as well as other parts of the world, including India, Africa, South America, New Zealand, Australia, Turkey and Southern Europe [1-4]. The incidence of intra-orbital hydatid disease is extremely low out of all cases of hydatid cysts. Hydatid cysts are most commonly seen in the liver (60–70%) and lungs (20%). The orbital involvement represents < 1% of all cases of hydatid disease, a relatively rare entity [5,6]. Though it represents less than 0.3% - 1% of all intra-orbital lesions, however, the percentage is quite high in some endemic regions of the world [7-9].

Hydatid disease can damage the eye in different ways. It can do direct damage by the infectious pathogen or indirect damage by toxic products, damage by immune response generated by the infection or ectopic parasitism. The etiopathogenesis, size and site of hydatid cysts dictate symptoms in orbital involvement, which can range from asymptomatic to simple headache to sight threatening complications. Therefore, it is very important to know manifestations, clinical features, early diagnosis and management of this inflammatory condition.

Life cycle

Ocular hydatid disease is caused by cestode larvae of the genus *Echinococcus*. The commonest form affecting humans is *E. granulosus*. Their life cycle involves only two hosts, one definitive and the other intermediate. Humans act as an accidental intermediate host and sheep and cattle represent intermediate hosts whereas dogs are the definitive hosts as they eat the flesh of infected sheep. Excreta of infected sheep and cattle may contain large numbers of eggs, and humans can become infected by close contact with dogs or handling or consuming contaminated food. Once eggs enter the human body, hydatid cysts are formed by

***Corresponding author**

Shreya Thatte, Department of Ophthalmology, Sri Aurobindo Medical College and PG Institute, Chaitanya 17, Yeshwant Colony, Indore, MP, India, Tel: 919302104864; Email: shreyathatte@gmail.com

Submitted: 31 May 2016

Accepted: 09 June 2016

Published: 110 June 2016

ISSN: 2373-9282

Copyright

© 2016 Thatte et al.

OPEN ACCESS**Keywords**

- Parasitic infections
- Ocular hydatid cyst
- Radio-imaging
- Sight threatening symptoms

lodgement of embryo of *Echinococcus granulosus* at different sites.

Depending on the involvement of organs, it can be primary or secondary, primary when only orbit is affected and secondary when it is part of a disseminated disease with multiple organ affection [10,11].

Symptoms

Primary hydatid cysts rarely appear isolated in the orbital cavity without involvement of other organs. In the orbit, most common site is superolateral and superomedial angles of the orbit. Totally Inferior or superior cysts are uncommon. In the early period, the patient is asymptomatic and many hydatid cysts remain asymptomatic, even into advanced stage.

The degree of symptoms is determined by parasite load, site and size of the cysts. Symptoms due to pressure usually take a long time to manifest. Most symptomatic cysts are larger than 5 cm in diameter. Patient commonly presents with painless nodular growth in lid, fornix (Figure 1), or proptosis (Figure 2) for months, associated with mild periorbital pain and later on mechanical restriction of ocular movements (Figure 3). It can present as defective vision, recurrent inflammation, chemosis, exposure keratitis, headache or other clinical features related to marked proptosis [12].

Diagnostic investigations

Preoperative definitive clinical diagnosis is not easy as, in majority of cases, there are no symptoms, except those due to pressure, and thus simulate a slow growing neoplasm. Pre-operative diagnosis is important in order to plan surgical strategy to avoid complications of rupture during surgery resulting into severe allergic and anaphylactic reactions, seeding and dissemination of parasite causing recurrence of disease. The diagnostic investigations include, serological tests, orbital ultrasound, CT and MRI. Many serological tests can be used in

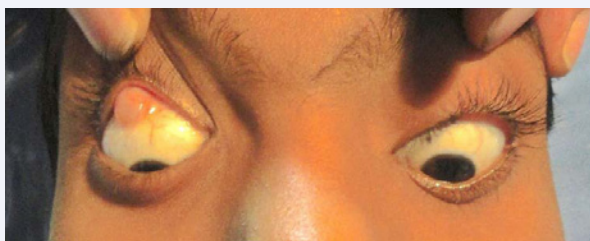

Figure 1 Hydatid cyst in superior fornix.

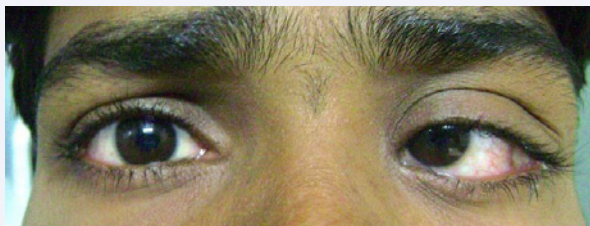

Figure 2 Hydatid cyst causing proptosis.

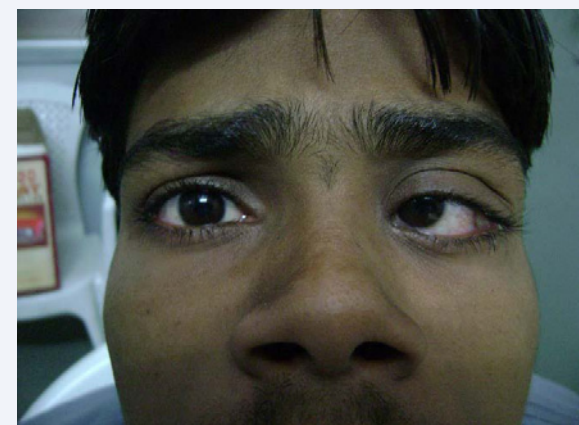


Figure 3 Restriction of lateral movements.

diagnosis of Echinococcosis, but in orbital hydatid cyst they usually give negative results. Cassoni's intradermal test, counter immune-electrophoresis, double diffusion test and indirect hemagglutination test are used for diagnosis. The sensitivity of Cassoni's test is 96% in liver, 90% in lung, and only 77% in orbital involvement. This is due to the encysted parasite in the orbit. Unreliability of these tests makes the radiological examination more important for pre-operative diagnosis [13].

The various radiological investigations including ultrasound, CT scan and MRI in correlation with MRI Spectroscopy help to confirm the correct diagnosis. On radiological investigations, orbital hydatid cysts usually appear as a well-defined, thin-walled, oval shape lesions with fine peripheral rim enhancement of their fibrous capsule after contrast medium administration [14,15].

On ultrasound, diagnostic 'Double Layer Sign' of the cyst wall is seen in some cases. 'Spoke wheel pattern' and 'Waterlily Sign' are classically described in literature.

On CT scan, these cysts may appear as well defined, uni-locular or multi-locular large cysts, with or without globe displacement. Contrast enhanced CT scan shows mildly enhancing cystic lesion having fluid attenuation of 3 - 30 HU with few calcifications, multiple septae and globe deformity, if present (Figure 4).

MRI shows well defined lesion, T1 and T2 FLAIR hypo-intense and T2 hyper-intense lesion, characteristic of cystic lesion [16].

MRI Spectroscopy is a new tool for confirmatory diagnosis of the hydatid cyst and it can be performed in cases of dilemma.

Proton MR Spectroscopy shows markedly elevated pyruvate, succinate, acetate, alanine peaks [17,18], lipid-lactate peak and also myoinositol elevation [19]. These are metabolic end products arising from microorganisms. Succinate peak is nonspecific and can occur in hydatid disease, neurocysticercosis, and abscesses [20]. Pyruvate peak is more specific and has been mentioned as an *in vivo* marker of hydatid infestation [18-21]. Acetate and succinate peaks are seen in both parasitic cysts and bacterial abscesses. Abscesses show higher acetate:succinate ratio, while succinate:acetate ratio is higher in hydatid and neurocysticercosis [17,19]. Creatine peak is seen in neurocysticercosis and its absence in hydatid [22]. On fertility assessment of hydatid cyst *ex vivo* by MR spectroscopy, presence of malate and fumarate in addition to other resonances was seen in fertile cysts [17]. Unusual appearance of the cyst on MRI which can be attributed to the layering of hydatid sand [16,23-25].

The final diagnosis is made by demonstration of scolices in the fluid and histological appearance of the cyst wall after the surgical removal of cyst. Histological examination (Figure 5) is the only confirmatory feature. It shows scolices in center along with refractile hooklets within the scolices, surrounded by eosinophilic acellular laminated membrane bordered by paucicellular germinal epithelium [13].

The differential diagnosis of such ocular cysts includes abscess, orbital hematoma, lymphangioma, lacrimal cysts or dermoid cysts. Abscess can be suspected if constitutional symptoms like fever, headache is present. Only peripheral enhancement rules out other lesions like hemangioma, lymphangioma and malignant tumors which have their own unique enhancement patterns. Dermoid cysts show fatty and calcified components within simultaneously [16].

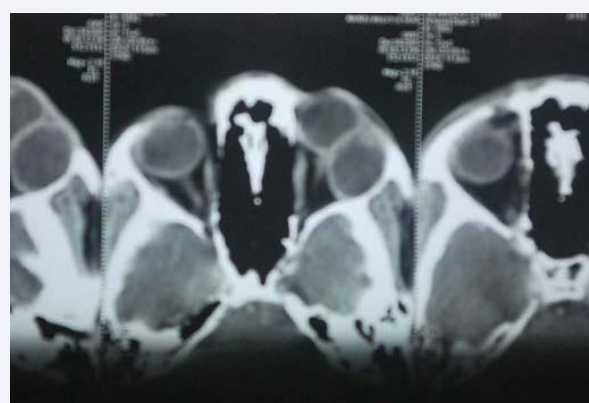


Figure 4 CT of Left eye shows large cyst behind eye ball.

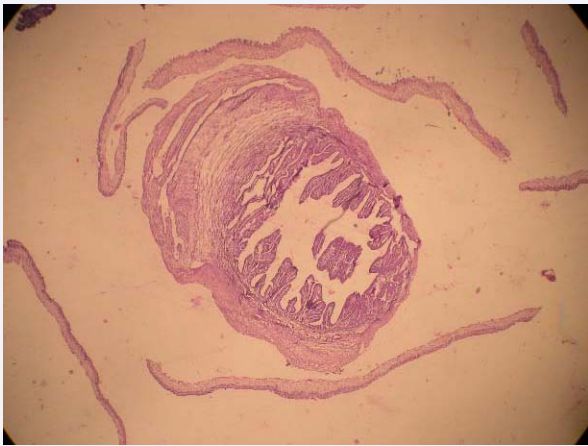

Figure 5 Histopathology showing scolix in the center.

Treatment

Hydatid disease can be treated medically and or surgically. Medical therapy is mostly with antihelminthic mebendazole or albendazole which is the gold standard and found to be useful in the prevention of recurrence specially when cyst ruptures during excision and contents contaminate the surgical site [26]. Antihelminthic therapy may cause an increased inflammation around the lesions, therefore corticosteroids are used to subside induced inflammation. Albendazole treatment is useful, especially if begun 14–28 days before surgery and is used as an adjunctive therapy to surgery [27-29].

Surgical excision may be required for isolated ocular lesions when they are growing and causing symptoms and visual loss.

Surgical methods

Surgical treatment can be of two types, simple aspiration or total excision. Aspiration is done, where the contents of the cyst are evacuated through a large caliber needle with closed suction followed by injection of 10 to 50 ml of 10% formalin into the cyst and re-aspiration after 5 minutes. Dissection and removal of cyst and fibrotic pseudo-capsule is done and the cavity is again irrigated with more formalin and obliterated with sutures where possible [33].

Total surgical excision is the definitive treatment. An understanding of the microanatomy of the orbit and a proper surgical approach are very important in preventing intra and post-op surgical complications. To avoid the possibility of the cyst rupturing during excision and risk of spreading infection, blunt dissection of the cyst is done along with orbital fat over the cyst wall keeping hypertonic saline-soaked cotton between cyst and dissector [30-35].

Per-operative instillation of various scolicial solutions have been mentioned in the literature, but the safe solutions are 15% hypertonic saline, 30% hydrogen peroxide, 0.5% cetrimide, 0.5% silver nitrate or 95% ethanol. Scolicial solution is instilled before opening the cavity to kill the daughter cysts and thus prevents anaphylactic reactions and further spread or seeding of cyst. If cyst accidentally ruptured, in situ irrigation with hypertonic saline should be performed. It is better to cover

the area surrounding the cyst and exposed optic tissue with hypertonic saline soaked cotton before beginning the dissection and cyst removal [13].

Cyst in the fornix can be removed with simple total excision (Figure 6a, 6b) but orbital cysts required complex surgical methods. There are two main orbital surgical approaches. First is the transcranial extension where it is essential to expose the optic nerve and also for lesions located superiorly to the optic nerve. The second is the lateral orbital approach (Figure 7a-7b). It is the most commonly used procedure to treat intra-orbital lesions located in the lateral compartment of the orbit. After excision of cyst, surgical area is irrigated with hypertonic saline [36].

Usually mild inflammation may occur post-operatively, in case of significant spillage of cyst contents into the operative field. It may lead to excessive postoperative inflammation and even recurrence. To prevent recurrence, antihelminthic drugs such as albendazole and mebendazole have been advocated postoperatively, along with systemic steroids [37,38].

The orbital hydatid cysts are slow growing and may remain asymptomatic, but large cysts can cause symptoms due to pressure

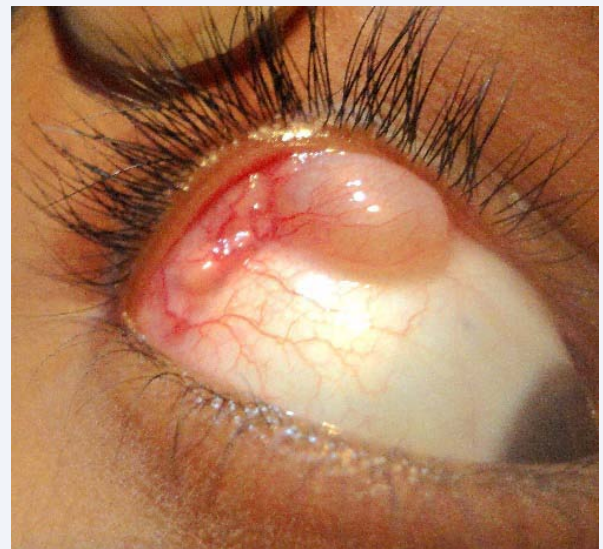

Figure 6a Hydatid cyst close up.

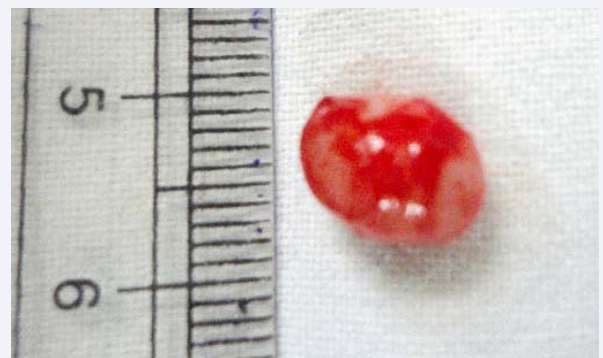

Figure 6b Total excision of cyst.

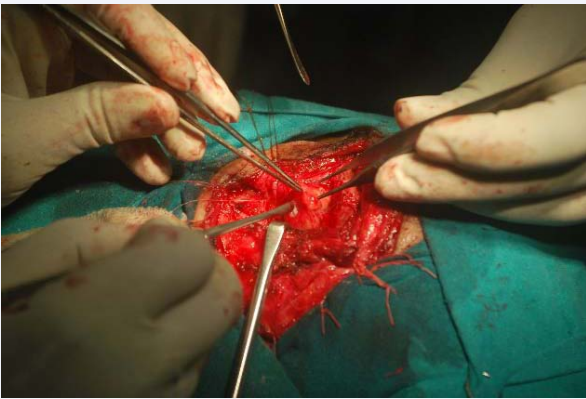


Figure 7a Lateral orbitotomy showing large cyst.

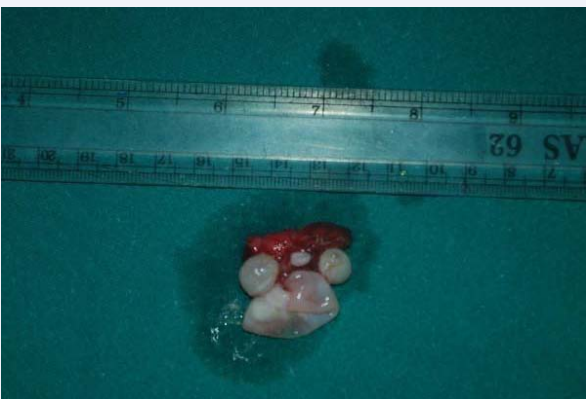


Figure 7b Multi loculated cyst.

effects. Depending on the location, it can lead to proptosis and even vision loss. Therefore, early diagnosis of orbital hydatid cyst and its prompt medical or surgical management is recommended for excellent results. The most important complication in surgical treatment is rupture of the cyst during excision, which can cause a relapse. However, complete removal of the cyst without rupture is not easy to achieve. This requires careful non traumatic dissection of cyst along with use of scolicedal solutions pre-, intra- and post-operatively.

REFERENCES

1. Altinors N, Bavbek M, Caner HH, Erdoan B. Central nervous system hydatidosis in Turkey: A cooperative study and literature survey analysis of 458 cases. *J Neurosurg.* 2000; 93: 1-8.
2. Ergün R, Okten AI, Yüksel M, Gül B, Evliyaoğlu C, Ergüngör F, et al. Orbital hydatid cysts: report of four cases. *Neurosurg Rev.* 1997; 20: 33-37.
3. Benazzou S, Arkha Y, Derraz S, Ouahabi EA, Khamlichi EA. Orbital hydatid cyst: review of 10 cases. *J Craniomaxillofac Surg.* 2010; 38: 274-278.
4. Cooney RM, Flanagan KP, Zehyle E. Review of surgical management of cystic hydatid disease in a resource limited setting: Turkana, Kenya. *Eur J Gastroenterol Hepatol.* 2004; 16: 1233-1236.
5. Copley IB, Fripp PJ, Erasmus AM, Otto DD. Unusual presentations of cerebral hydatid disease in children. *Br J Neurosurg.* 1992; 6: 203-210.
6. Karakas HM, Tokoğlu F, Kacar M, Boyacigil S. Retrobulbar hydatid cyst: assessment of two cases. *Australas Radiol.* 1997; 41: 179-180.
7. Shah A, Kirtane MV, D'Souza CE. "Hydatid Cyst of the Orbit (A Case Report)." *Journal of Postgraduate Medicine.* 1998; 34: 43-44.
8. Talib H. Orbital hydatid disease in Iraq. *Br J Surg.* 1972; 59: 391-394.
9. Morales GA, Croxatto JO, Crovetto L, Ebner R. Hydatid cysts of the orbit. A review of 35 cases. *Ophthalmology.* 1988; 95: 1027-1032.
10. Staindl O, Kenkel C. "Throat, Nose and Ear Medicine." *NHO Host Network Operator HNO Harvard News Office HNO Helvetica Narrow Oblique.* 1985; 404-408.
11. Betharia SM, Pushker N, Sharma V, Avinash M, Kashyap S. Disseminated hydatid disease involving orbit, spleen, lung and liver. *Ophthalmologica.* 2002; 216: 300-304.
12. Gökçek C, Bayar N, Buharai Z. Total removal of an unruptured orbital hydatid cyst. *Can J Ophthalmol.* 2001; 36: 218-220.
13. Mathad VU, Singh H, Singh D, Butte MV, Kaushik M. Large primary intraorbital hydatid cyst in elderly. *Asian J Neurosurg.* 2013; 8: 163.
14. Betharia SM, Sharma V, Pushker N. Ultrasound findings in orbital hydatid cysts. *Am J Ophthalmol.* 2003; 135: 568-570.
15. Aksoy FG, Tanrikulu S, Kosar U. Inferiorly located retrobulbar hydatid cyst: CT and MRI features. *Comput Med Imaging Graph.* 2001; 25: 535-540.
16. Taori K, Disawal A, Rathod J, Hatgaonkar A, Dhakate S, Bakare V, et al. Role of MRI Imaging and MR Spectroscopy in the Diagnosis of Ocular Hydatid Cyst: Case Report. *Open J Med Imaging.* 2013; 3: 7-11.
17. Garg M, Gupta RK. *MR Spectroscopy in Intracranial Infection.* Clinical MR Neuroimaging. Cambridge University Press. Cambridge; 2005; 380-406.
18. Sreedhar M. Disseminated Hydatid Disease: A Case Report with MR Spectroscopic Correlation. *Indian Journal of Radiology and Imaging.* 2006; 16: 771-774.
19. Chand K, Kanodia AK, Manpreet G, Neeraj A. *In vivo* proton magnetic resonance spectroscopy in a known case of intracranial hydatid cyst. *Neurol India.* 2005; 53: 337-338.
20. Jay Kumar PN, Srikanth SG, Chandrasekhar HS, Kovoor JM, Shankar SK, Anandh B. Pyruvate: An in Vivo Marker of Cestodal Infection in Human Brain on Proton MR Spectroscopy. *Journal of Magnetic Resonance Imaging.* 2003; 18: 675-680.
21. Kohli A, Gupta RK, Poptani H, Roy R. *In vivo* proton magnetic resonance spectroscopy in a case of intracranial hydatid cyst. *Neurology.* 1995; 45: 562-564.
22. Garg M, Chawla S, Prasad KN, Roy R, Sikora SS, Kumar R, et al. Differentiation of hydatid cyst from cysticercus cyst by proton MR spectroscopy. *NMR Biomed.* 2002; 15: 320-326.
23. Rumboldt Z, Jednacak H, Talan-Hranilović J, Rumboldt T, Kalousek M. Unusual appearance of a cisternal hydatid cyst. *AJNR Am J Neuroradiol.* 2003; 24: 112-114.
24. Vashisht S, Berry M. *Imaging of the orbit.* Diagnostic Radiology and Imaging Jaypee Brothers. 1997; 1: 885-889.
25. Günalp I, Gündüz K. Cystic lesions of the orbit. *Int Ophthalmol.* 1996; 20: 273-277.
26. Akhan O, Bilgiç S, Akata D, Kiratli H, Ozmen MN. Percutaneous treatment of an orbital hydatid cyst: a new therapeutic approach. *Am J Ophthalmol.* 1998; 125: 877-879.
27. Altinörs N, Bavbek M, Caner HH, Erdogan B. Central nervous system hydatidosis in Turkey: a cooperative study and literature survey

- analysis of 458 cases. *J Neurosurg.* 2000; 93: 1-8.
28. Cooney RM, Flanagan KP, Zehyle E. Review of surgical management of cystic hydatid disease in a resource limited setting: Turkana, Kenya. *Eur J Gastroenterol Hepatol.* 2004; 16: 1233-1236.
29. Jimenez-Mejias ME, Alarcon-Cruz JC, Marquez-Rivas FJ, Palamino-Nicas J, Montero JM, Pachon J. Orbital hydatid cyst: Treatment and prevention of recurrences with albendazole plus praziquantel. *J Infect.* 2000; 41: 105-107.
30. Farioli B, Esposito V, Santoro A, Iannetti G, Giuffre R, Cantare G. Transmaxillophenoidal approach to tumors invading the medial compartments of the cavernous sinus. *J Neurosurg.* 1995; 82: 63-69.
31. Rabadán A, Conesa H. Transmaxillary-transnasal approach to the anterior clivus: a microsurgical anatomical model. *Neurosurgery.* 1992; 30: 473-481.
32. Handous AB. Proptosis caused by hydatid disease. *Br J Ophthalmol.* 1951; 35: 607-613.
33. Akhan O, Bilgiç S, Akata D, Kiratli H, Ozmen MN. Percutaneous treatment of an orbital hydatid cyst: a new therapeutic approach. *Am J Ophthalmol.* 1998; 125: 877-879.
34. Baghdassarian SA, Zakharia H. Report of three cases of hydatid cyst of the orbit. *Am J Ophthalmol.* 1971; 71: 1081-1084.
35. Talib H. Orbital hydatid disease in Iraq. *Br J Surg.* 1972; 59: 391-394.
36. Aksoy FG, Tanrikulu S, Kosar U. Inferiorly located retrobulbar hydatid cyst: CT and MRI features. *Comput Med Imaging Graph.* 2001; 25: 535-540.
37. Nahri GE. A simplified technique for removal of orbital hydatid cysts. *Br J Ophthalmol.* 1991; 75: 743-745.
38. Jimenénez-Mejías ME, Alarcón-Cruz JC, Márquez-Rivas FJ, Palomino-Nicás J, Montero JM, Pachón J. Orbital hydatid cyst: treatment and prevention of recurrences with albendazole plus praziquantel. *J Infect.* 2000; 41: 105-107.

Cite this article

Thatte S, Thatte S (2016) Ocular Hydatid Cyst. *Ann Clin Pathol* 4(5): 1081.