

Case Report

The Course of Serous Macular Detachment in Active Toxoplasmic Retinochoroiditis

Yasemin Özdamar Erol and Pinar Çakar Özdal*

Department of Retinal and Uveal Diseases, Ulucanlar Eye Research Hospital, Turkey

*Corresponding author

Pinar Çakar Özdal, Ulucanlar Eye Research Hospital, Ulucanlar cad. No: 59 Altındağ, 06100, Ankara, Turkey, Tel: 90-312-312-62-61; Fax: 90-312-312-48-27; Email: pinarozdal@hotmail.com

Submitted: 07 September 2016

Accepted: 03 November 2016

Published: 05 November 2016

ISSN: 2373-9282

Copyright

© 2016 Özdal et al.

OPEN ACCESS

Abstract

Serous macular detachment is a rare complication of active toxoplasmic retinochoroiditis involving the posterior pole and may be responsible for decreased visual acuity. It can be easily detected by using optic coherence tomography. SMD has a good visual prognosis with antibiotic and corticosteroid combination therapy. In this study, we reported the clinical course and OCT findings of SMD in two cases with active toxoplasmic retinochoroiditis.

ABBREVIATIONS

OT: Ocular Toxoplasmosis; SMD: Serous Macular Detachment; TRC: Toxoplasmic Retinochoroiditis; OCT: Optic Coherence Tomography.

INTRODUCTION

Ocular toxoplasmosis is one of the most frequent causes of posterior uveitis worldwide. The typical presentation of OT is unilateral focal necrotizing retinochoroiditis usually at the border of a pre-existing pigmented retinochoroidal scar and overlying vitritis [1,2]. SMD can rarely occur in eyes with active TRC involving the posterior pole of the retina and it can be a potential cause of decreased visual acuity. OCT imaging facilitates showing and monitoring the serous exudation of the macula. Due to extensive use of OCT imaging, few cases of TRC associated SMD have been reported in recent years [3-6].

In this study, we reported the clinical course and OCT findings of SMD in two cases with active TRC.

CASE 1

A 17-year old woman presented to our clinic with the complaint of blurred vision in the right eye. The patient's history was normal. Her visual acuity was hand motion in the right eye and 20/20 in the left eye. Biomicroscopic examination and intraocular pressures were normal in both eyes. Fundus examination of the right eye showed active retinochoroiditis located under the super temporal retinal vessels. There was a greyish-black chorioretinal scar adjacent to active retinochoroiditis, and a clinically visible large SMD area was observed (Figure 1). Fundoscopy of the left eye was normal. Laboratory investigations revealed negative antitoxoplasma Ig M and positive IgG. Ophthalmologic findings suggested the diagnosis of active TRC. OCT imaging confirmed and showed the details of SMD in the right eye. There were multiple hyperreflective dots in the subretinal fluid and hyperreflective

debris and/or strands were observed on the outer retina or in the subretinal space (Figure 2). The patient was treated with combined antibiotic regimen; azithromycin 1000 mg on the first day and 500 mg per day for 3 weeks and sulfamethoxazole 800 mg/trimethprim 160 mg twice daily for 6-8 weeks. Two days after the antibiotics regimen, oral corticosteroids 0.5-1 mg/kg were initiated and tapered over 4 weeks. On the 10th day of the treatment, SMD disappeared on OCT imaging, her visual acuity was 20/200 in the right eye and active TRC gradually decreased (Figure 3-4). After 6 weeks' treatment, visual acuity was 20/40, there was no subretinal fluid in OCT of the macula and atrophic retinochoroidal scar developed in the region of active TRC (Figure 5-6).

CASE 2

A 39-year old woman presented with painless blurred vision

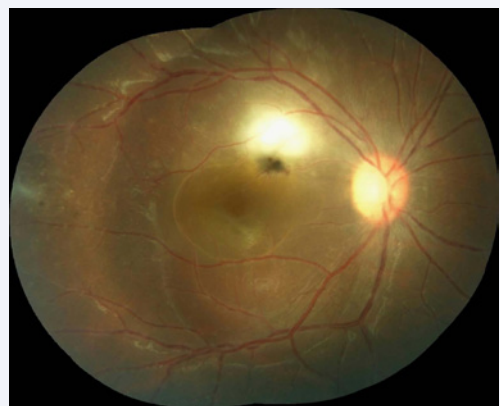

Figure 1 A color photograph shows a greyish-black chorioretinal scar adjacent to active retinochoroiditis and clinically visible large SMD in the right eye.

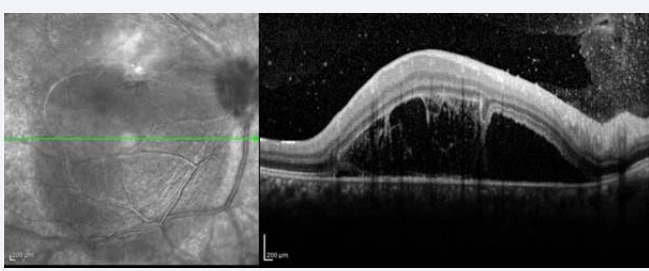


Figure 2 OCT demonstrates SMD, multiple hyperreflective dots in the subretinal fluid and hyperreflective debris/strands on the outer retina or in the subretinal space in the right eye.

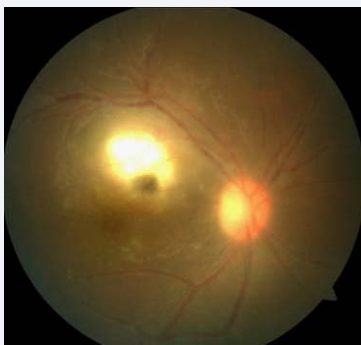


Figure 3 A color fundus photograph of the right eye shows decreased active TRC on the 10th day of the treatment.

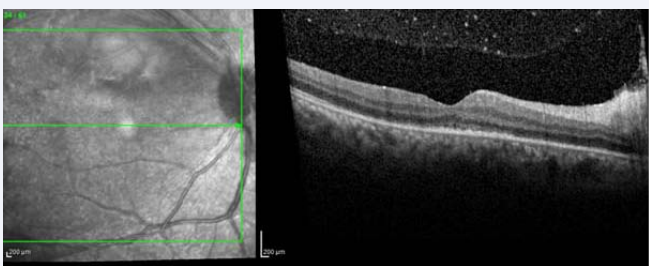


Figure 4 OCT imaging of the right eye shows disappeared subretinal fluid on the 10th day of the treatment.

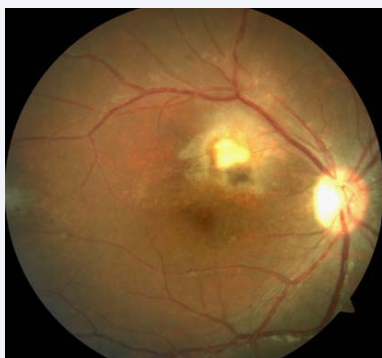

Figure 5 Fundus photography of the right eye shows atrophic retinochoroidal scar developing in the region of active TRC after 6 week's treatment.

in the right eye. Her visual acuity was hand motion in the right eye and 20/20 in the left eye. Biomicroscopic examination and intraocular pressures were unremarkable in both eyes. The patient's history was normal. On fundus examination of the right eye, a very small, greyish-white lesion at the nasal region adjacent to the optic disc, a large pigmented retinochoroidal scar at the region of inferotemporal retinal vessels and a SMD were observed (Figure 7). Fundoscopy of the left eye was normal. Anti-toxoplasma antibody analysis revealed positive IgG and negative IgM titers. Ophthalmologic findings were compatible with active TRC. OCT imaging of the right eye showed SMD, multiple hyperreflective dots in the subretinal fluid and hyperreflective debris/strands on the outer retina or in the subretinal space as in Case 1 (Figure 8 A and B). The patient was treated with the combined treatment regimen given to Case 1. On the 8th day of the treatment, SMD disappeared on OCT imaging, the visual acuity increased to 20/60 and active TRC became more evident (Figure 9-10). After 6 weeks' treatment, visual acuity was 20/20, there was no subretinal fluid on OCT of the macula and atrophic retinochoroidal scar developed in the region of active TRC (Figure 11-12).

CONCLUSION

Serous macular detachment is a rare complication of active toxoplasmic retinochoroiditis and it can usually occur in eyes with macular involvement. Several pathogenic mechanisms of SMD have been proposed including breakdown of the blood-retinal barrier or transient retinal pigment epithelium dysfunction or choroidal ischemia [6].

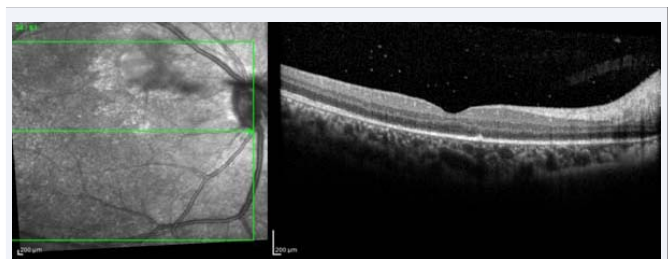


Figure 6 OCT imaging of the right eye shows no submacular fluid after 6 week's treatment.

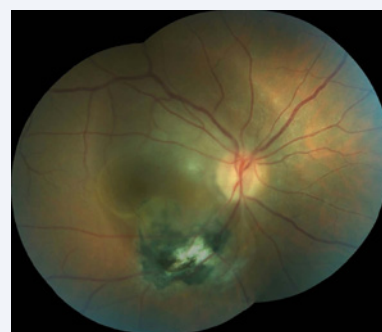

Figure 7 A color fundus photograph shows a small greyish-white lesion at the nasal region adjacent to the optic disc, a large pigmented retinochoroidal scar at the region of inferotemporal retinal vessels and a SMD in the right eye of second case.

Optic coherence tomography imaging is the most helpful imaging method to assess the subretinal fluid. There has been a recent increase in the number of reported cases of SMD in eyes with active TRC thanks to the more frequent use of OCT imaging [3-6]. Khairallah et al., found serous retinal detachment in 14 of 60 eyes (23.3%) with active TRC. Active TRC with serous retinal detachment was located in the posterior pole in 10 eyes and in

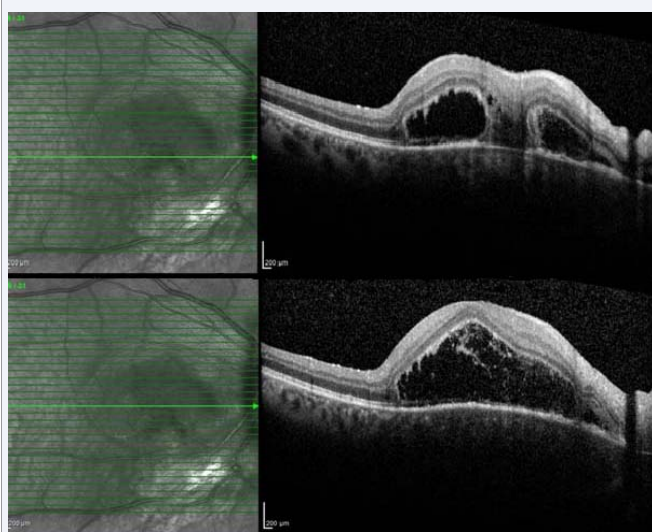


Figure 8 A- B: OCT imaging of the right eye shows SMD , multiple hyperreflective dots in the subretinal fluid and hyperreflective debris and/or strands on the outer retina or in the subretinal space.

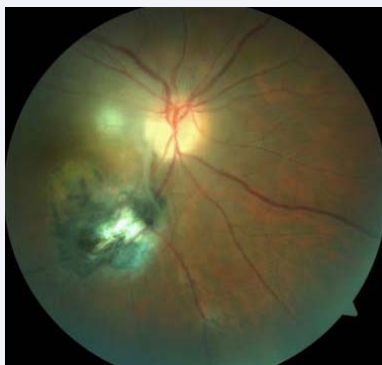

Figure 9 On the 8th day of the treatment, A color fundus photograph shows evident active TRC.

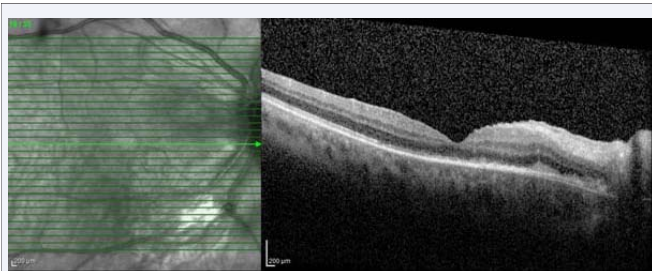


Figure 10 OCT imaging shows no subretinal fluid on the 8th day of the treatment in the right eye.

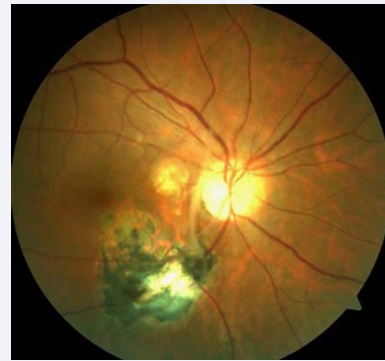


Figure 11 A color fundus photograph shows atrophic retinochoroidal scar developing in the region of active TRC after 6 weeks' treatment.

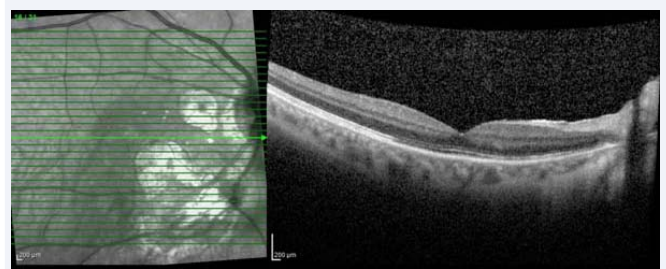


Figure 12 OCT imaging shows no subretinal fluid in the right eye after 6 weeks' treatment.

the midperiphery in 4 eyes. In their study, subfoveal fluid was detected in 9 eyes. They reported retinal reattachment and improvement in visual acuity over a period of 2-6 weeks. All patients were treated with a combination of pyrimethamine (100 mg on the first day, then 50 mg daily), azithromycin (500 mg on the first day, then 250 mg daily), and prednisone for 4-6 weeks in their study [3]. Diniz et al., observed macular detachment in 5 of 10 eyes (50%) with active TRC and all lesions were located in the posterior pole in their study. They suggested that the presence of subretinal fluid had an indirect correlation with the distance of active TRC from the fovea, which was not statistically significant. They reported complete resolution in 80% of the cases after 6 weeks of treatment. Only one patient had residual fluid at the follow up; they explained that the fluid might be associated with the proximity of the lesion to the macula and discrete vitreo-foveal traction. Patients were treated with oral sulfamethoxazole 800 mg/trimethprim 160 mg for 6 weeks and prednisone 0.5 mg/kg/day, tapered over 4 weeks [4]. In another study, Orefice et al., reported subretinal fluid accumulation adjacent to the active lesion in 5 of 24 eyes (20.8%) by using spectral OCT. However, authors did not describe the location of active TRC in the retina. Also, they did not supply information about their treatment regimen [5]. Interestingly, in Goldenberg et al., study evaluating OCT findings in active and scarred toxoplasmosis lesions, subretinal fluid was not observed in 19 eyes with active TRC [6].

There are various antibiotic regimens and treatment modalities in the management of active TRC in clinical practice. Each regimen has different effects and/or side-effects [7]. In addition, oral corticosteroids have been added for specific

indications including; severe vitreous inflammatory reaction, decreased vision and proximity of the lesions to the fovea or optic disc, and for large lesions [8]. In clinical practice, we prefer azithromycin and sulfamethoxazole /trimethoprim combination in the treatment of OT [9]. As shown in abovementioned studies, several antibiotic regimens have been used for the treatment of OT associated SMD. Following a treatment period of 4-6 weeks, SMD has been shown to have a good prognosis including macular reattachment and improvement in visual acuity.

In this study, our patients had both SMD and active TRC of the posterior pole not involving the fovea. The combined antibiotic regimen was used to treat OT for 6-8 weeks; 2 days after the antibiotics regimen, oral corticosteroids 0.5-1 mg/kg were initiated and then stopped before the antibiotics. This combination therapy accelerated regression of serous subretinal fluid and OCT performed one week after the treatment showed that SMD disappeared completely. Periocular or intravitreal corticosteroids injections should be avoided to treat this submacular fluid. It is well known that fulminant ocular toxoplasmosis may occur as a consequence of corticosteroids injections without concomitant antibiotic treatment [10]. Also, fulminant toxoplasmic retinochoroiditis due to intravitreal triamcinolone injection despite simultaneous systemic anti-toxoplasmic therapy has been reported [11].

Optic coherence tomography enables identification of inflammatory changes in vitreous, retina and choroid. Hyper reflective dots and debris demonstrate active phases of inflammation in eyes with uveitis [12,13]. To the best of our knowledge, this is the first report to show massive hyperreflective dots and debris in the subretinal space or the outer retina in OCT images of eyes with OT associated SMD. This finding may point out severe inflammatory reaction, and disappear with combination therapy.

In summary, serous macular detachment is a rare complication of acute TRC and may account for potential visual loss in patients with TRC sparing the fovea. OCT is recommended in eyes with acute TRC for screening of SMD and monitoring the treatment. SMD has a favorable visual prognosis with antibiotic and corticosteroids combination therapy and local corticosteroids injections should be avoided.

REFERENCES

- Maenz M, Schlüter D, Liesenfeld O, Schares G, Gross U, Pleyer U. Ocular toxoplasmosis past, present and new aspects of an old disease. *Prog Retin Eye Res.* 2014; 39: 77-106.
- Delair E, Latkany P, Noble AG, Rabiah P, McLeod R, Brézina A. Clinical manifestations of ocular toxoplasmosis. *Ocul Immunol Inflamm.* 2011; 19: 91-102.
- Khairallah M, Kahloun R, Ben Yahia S, Jelliti B. Clinical, tomographic, and angiographic findings in patients with acute toxoplasmic retinochoroiditis and associated serous retinal detachment. *Ocul Immunol Inflamm.* 2011; 19: 307-310.
- Diniz B, Regatieri C, Andrade R, Maia A. Evaluation of spectral domain and time domain optical coherence tomography findings in toxoplasmic retinochoroiditis. *Clin Ophthalmol.* 2011; 5: 645-650.
- Oréfice JL, Costa RA, Scott IU, Calucci D, Oréfice F; Grupo Mineiro de Pesquisa em Doenças Oculares Inflamatórias (MINAS). Spectral optical coherence tomography findings in patients with ocular toxoplasmosis and active satellite lesions (MINAS Report 1). *Acta Ophthalmol.* 2013; 91: 41-47.
- Goldenberg D, Goldstein M, Loewenstein A, Habet-Wilner Z. Vitreal, retinal, and choroidal findings in active and scarred toxoplasmosis lesions: a prospective study by spectral-domain optical coherence tomography. *Graefes Arch Clin Exp Ophthalmol.* 2013; 251: 2037-2045.
- Jasper S, Vedula SS, John SS, Horo S, Sepah YJ, Nguyen QD. Corticosteroids as adjuvant therapy for ocular toxoplasmosis. *Cochrane Database Syst Rev.* 2013; 30.
- Reich M, Mackensen F. Ocular toxoplasmosis: background and evidence for an antibiotic prophylaxis. *Curr Opin Ophthalmol.* 2015; 26: 498-505.
- Yazıcı A, Özdal P, Taşkıntuna I, Kavuncu S, Köklü G. Trimethoprim/Sulfamethoxazole and azithromycin combination therapy for ocular toxoplasmosis. *Ocul Immunol Inflamm.* 2009; 17: 289-291.
- Oray M, Ozdal PC, Cebeci Z, Kir N, Tugal-Tutkun I. Fulminant ocular toxoplasmosis: The hazards of corticosteroid monotherapy. *Ocul Immunol Inflamm.* 2015; 8: 1-10.
- Backhouse O, Bhan KJ, Bishop F. Intravitreal triamcinolone acetonide as an adjunct in the treatment of severe ocular toxoplasmosis. *Eye (Lond).* 2008; 22: 1200-1201.
- Onal S, Tugal-Tutkun I, Neri P, Herbort C. Optical coherence tomography imaging in uveitis. *Int Ophthalmol.* 2014; 34: 401-435.
- Saito M, Barbazetto IA, Spaide RF. Intravitreal cellular infiltrate imaged as punctate spots by spectral-domain optical coherence tomography in eyes with posterior segment inflammatory disease. *Retina.* 2013; 33: 559-565.

Cite this article

Erol YÖ, Özdal PÇ (2016) The Course of Serous Macular Detachment in Active Toxoplasmic Retinochoroiditis. *Ann Clin Pathol* 4(8): 1096.