

Case Report

Ruptured Hydatid Cyst of Liver and Huge Pulmonary Hydatid cyst: Presented as Acute Abdomen with Severe Anaphylaxis Shock: A Rare Presentation

Manouchehr Aghajanzadeh*, Mohammad RasoulHerfatkar, FarzadGhotbi, Goharshriea, Bahareh Mohtasham, and Omid Mosafaiee

Department of Internal Medicine, Guilan University of Medical Sciences, Iran

*Corresponding author

Manouchehr Aghajanzadeh, Inflammatory Lung Disease Research Center, Department of Internal Medicine, Razi Hospital, School of Medicine, Guilan University of Medical Sciences, Rasht, Iran, Tel: 989111311711; Fax:98-13-33542460; Email: maghajanzadeh2003@yahoo.com

Submitted: 21 February 2018

Accepted: 13 March 2018

Published: 14 March 2018

ISSN: 2373-9282

Copyright

© 2018 Aghajanzadeh et al.

OPEN ACCESS

Keywords

• Echinococcosis; Peritoneum; Abdomen, Acute; Anaphylaxis

Abstract

Hydatid disease can involve various organs of the body and may develop in any organ member But most often in the liver (77%-50%) and lungs (35%-18%), and sometimes in other organs. Liver and hepatic hydatid cysts occur in 25% of cases in 4%. The clinical signs and symptoms of hydatid cyst depend on the locations that are involved (deep or superficial, right or left lobe), size, adjacent organs, and complications such as infection or cyst rupture. Rupture of the cyst may occur after trauma or spontaneously due to suddenly increased intracystic pressure. When a hydatid cyst is broken down in the peritoneum, catastrophic complications such as abdominal pain, chewing gum, anaphylaxis, and sudden death may occur. We have a 40-year-old woman with anaphylactic shock, Such as severe abdominal pain, tachycardia, hypotension and massive erythema, and rapidly intubating and then severely care unit for resuscitation. With the primary suspicion of peritonitis, open laparotomy was performed. During the surgery, hydatid cyst elements were observed within different parts of the abdomen. One ruptured cyst was seen in the posterior of the right lobe of liver which invades to the diaphragm. The cyst cavity was irrigated with saline, pericystectomy and Capi tonnage. The abdominal cavity was washed twice with providing 10% iodine solution at 10-minute intervals. One huge cyst was also detected in the upper lobe of right lung on postoperative chest radiography. one week later patient underwent thoracotomy for lung cyst. Patient discharged with good conditions. Conclusion: The rupture of a hydatid cyst into the abdominal cavity is rare and anaphylaxis shock is extremely rare. This condition missed with acute abdomen in endemic areas, especially in young patients and must be in the differential diagnosis of the acute abdomen.

INTRODUCTION

Hydatid disease is a serious health and infection problem in endemic countries such as Iran. It is a parasitic infection caused by the larval stage of *Echinococcus granulosus* [1,2]. Humans are accidental infected and do not have any role to the normal life cycle of this microorganism [2,3]. Humans are infected by ingesting egg from vegetable, soil or water which contaminated by the feces of dogs [1,3,4]. Hydatid cysts may develop in any body organ but occur most frequently in the liver (50%-77%) and lungs (18%-35%), and occasionally in other organs [1,2,5,6,3]. Concomitant liver and pulmonary hydatid cysts occur in 4% 25% of patients [1]. In some time Hydatid cyst is a chronic disease with late presentation and often is asymptomatic. It may be found during routine clinical examination and serologic, radiographic, or ultrasonographic screening [5,7,9]. The clinical signs and symptoms of hydatid cysts depend on locations in the involvement of organs (deep or superficial, right or left lobe), size, adjacent organs, and complications such as infection or cyst rupture. A cyst may rupture into the biliary systems, into the hollow organ, through the diaphragm into the pleural cavity or pulmonary parenchyma, or directly in the peritoneal cavity [4,5,6,8,10]. Rupture of the cyst may occur after trauma or

spontaneously due to suddenly increased intracystic pressure. Pressure [4,6,9]. A hydatid cyst rupturing into the peritoneal cavity may cause complications including abdominal pain, urticaria, anaphylaxis, and sudden death [7-9] Therefore, hydatid cyst rupture requires both emergency surgery and careful postoperative care. In this report, we present the case of a patient who had hydatid cyst of liver and pulmonary that ruptured into the peritoneal cavity spontaneously without any trauma

CASE REPORT

A 42-year-old woman was transferred to our hospital's emergency department from locally hospital emergency service with the complaint of abdominal pain accompanied by severe abdominal pain, vomiting, and dyspnea. In The patient history, an abdominal Pain was seen which not associated with trauma or GI tract disorder. Three days before admission, she had an abdominal ultrasonography which revealed the intra abdominal accumulation of fluid with a cystic lesion in the segments 7 of the liver, pain occurs suddenly and located in the through all of the abdomens. At that time he was conscious, only complaining of severe abdominal pain. The only physical finding was tenderness and guarding in all quadrants of the abdomen. On the three

hours of hospitalization, the patient developed of anaphylactic shocks, such as severe abdominal pain, tachycardia, hypotension, and widespread erythema, of the abdomen and was subsequently transferred to the intensive care unit for resuscitation; he was rapidly intubated. His blood pressure decreased to 80/50 mmHg, heart rate was 135 beats min, respiratory rate 25 bpm. Resuscitation was started with Rapid fluid loading with crystalloid and colloid by via central venous catheter, epinephrine (8mcg), methyl prednisolone (600mg) and dopamine infusion (6µg/kg/min). The situation progressively improved with continuing fluid loading, administering epinephrine and hydrocortison. The patient underwent emergency laparotomy with a diagnosis of peritonitis. Invasive monitoring with continuous central venous and arterial blood pressure measurements was used. At surgery, elements of the cyst and greenish fluid were seen in the peritoneal cavity and a ruptured hydatid cyst in segments 7 of the liver (Figure 1). The ruptured cyst was invaded the diaphragm, during resection of priciest, diaphragm was ruptured, after insertion of chest-tube in the right pleural space. diaphragm was repaired with 1 victory stitches. Pericystectomy was performed, a Foley catheter put in Remme-Nant Caity of cyst the abdominal cavity was washed twice with providing-iodine 10% of solution at 10-minute intervals, the patient transferred to the intensive care unit. He was extubated 24 hours later after the surgery. Two days after surgery, she discharged from intensive care unit. Albendazole started day two (800mg/daily). Postoperative, Brain, thorax and abdominal computed tomography (CT) were performed and Brain was normal. The abdominal CT examination show remnant cavity of evacuated cyst situated in the sub capsular area of the posterior lobes of right hepatic (Figure 2). The thoracic CT examination shows huge intact hydatid cysts in the upper lobe of the right lung (Figure 3). Ten days later the cyst of the lung was operated with antero-lateral thoracotomy, aspiration, evacuation, pericystectomy, and cartonnage for the obliteration of remnant cavity (Figure 4) she discharged on day 10 post-thoracotomy with good conditions. In follow-up she was perfect.

DISCUSSION

Hydatid disease is a serious health and infection problem in endemic countries such as Iran [1,2]. It is caused by the larval stage of *Echinococcus granulosus* [1,2]. Concomitant liver and pulmonary hydatid cysts occur in 4% to 25% of patients with echinococcosis [1]. Complications occur in 5% to 40% patients with liver hydatid cysts and include, cyst rupture into the biliary tree, compression of biliary duct, cyst infection, allergy, anaphylactic reactions and intraperitoneal rupture, arupture in the pleural cavity and pulmonary parenchymal [7-9]. The rupture of a liver hydatid cyst into the peritoneal cavity ranges is from 1% to 16% [2,5,8,10]. Rupture may result from trauma or may occur spontaneously [3,5,6,9]. The risk factors predisposing to rupture include young age, cyst diameter >10 cm, and superficial cyst location, large cyst diameter, which increases the internal cyst pressure and superficial location of the cyst are prone to rupture, even with minor trauma [4,5,6,8,10]. Occasionally the clinical signs and symptoms of intraperitoneal rupture of hydatid cyst are not severe, but hydatid fluid or bile can cause peritoneal irritations and peritonitis, as occurred in our patient. Peritoneal signs and symptoms can be more severe if bile leakage occurs

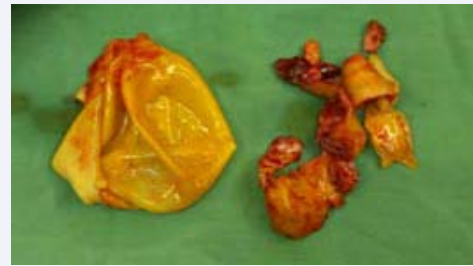


Figure 1 Show elements of hydatid cyst in the peritoneal cavity.

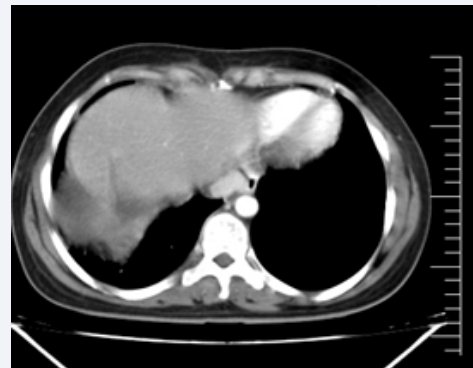


Figure 2 Postoperative CT-scan of abdomen show remnant cavity of cyst after evacuation.

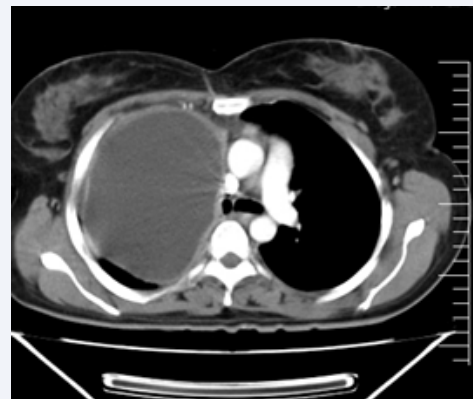

Figure 3 Postoperative CT-scan of chest show huge hydatid cyst of right lung.

or the cyst is infected. [3,4,7]. An allergic reaction can occur as Urticaria and macular eruptions on the skin Allergic reaction may be fatal, the patient may develop anaphylaxis and life-threatening anaphylactic shock [3,4,5,9]. The Anaphylactic reactions or shock may occur more severely in 1% to 12.5% of patients [3,5,9,10], as our case which present with severe anaphylactic shock. In our practice, we had four patient with spleen cyst [2] and liver cysts [2] with anaphylactoid reactions as urticaria, peripheral edema, and dyspnea. Timely appropriate medical intervention and surgery prevented the death of patients with anaphylaxis reactions [3,5,9]. Therefore, immediate medical treatment for allergic reactions is advised [3,6,9,10]. In our previous cases we used hydrocortison,

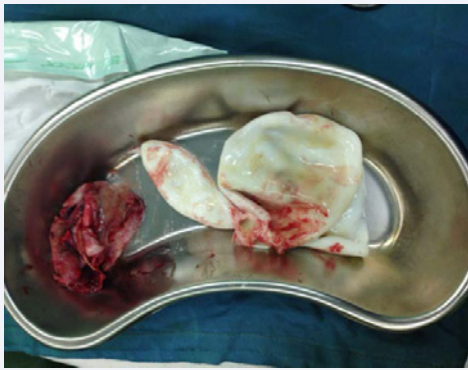


Figure 4 Show laminated membrane of cyst after evacuation.

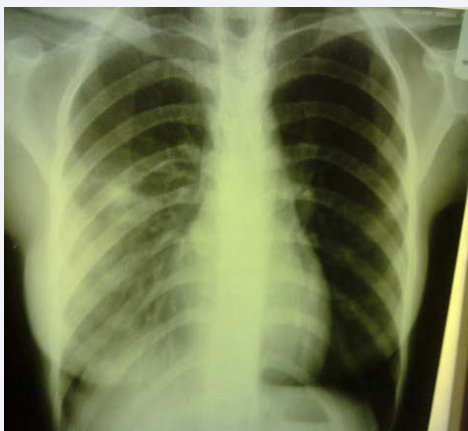

Figure 5 Postoperative CXR.

promethazine, epinephren, intravenous colloid, crystalloid fluid and early surgery, all four case responded to this medications. Surgery is the first choice for complicated cysts [4,7,8,9]. The surgical management of a patient with a ruptured hydatid cyst is more complex than an intact cyst [2,3,7,8]. In ruptured cyst Scolices, protoscoleces and others element of cyst spill into the abdomen cavity. The surgeon must explore abdominal cavity carefully for thesource of the ruptured cyst [2,3,5,8,10]. The main goals of surgery are to eliminate local disease, cyst elements in abdominal cavity, prevent complications and recurrence risk [3,4,6,9] After intervention for a ruptured cyst of involved organ and removal of all cystic contents from abdominal cavity, irrigate of peritoneal cavity with sufficient sporicidal agents{ cetrimide-chlorhexidine, povidone-iodine (10%), silver nitrate (0.5%), hypertonic saline solution (3%-30%) and chlorhexidine (0.4%) is important}. [3,5,9] .we used povidone-iodine (10%) in our patients. However, patients with traumatic or spontaneous

cyst rupture after stabilization of patients emergency surgery is mandatory because. Therefore, medical treatment may be started as early as possible to reduce the risk of recurrence after surgery and continued for 1 to 6 months, Albendazole (10-15 mg/kg/d) [3,6-9]. We use Albendazole (10 mg/kg/d) for three months in our case. Meticulous postoperative follow-up requires for ruptured hydatid cyst. A CT scan may show recurrence. [3,7,8,10] we use yearly CT in our cases.

CONCLUSION

The rupture of a hydatid cyst into the abdominal cavity is rare and anaphylaxis shock is extremely rare. This complication is a challenge for the emergency team and surgeon. This condition missed with acute abdomen in endemic areas, especially in young patients and must be in the differential diagnosis of the acute abdomen. The most important treatment for intraperitoneal rupture of hydatid cysts is emergency surgery and medical treatment should be started postoperatively as soon as possible.

REFERENCES

1. Aghajanzadeh M, Safarpour F, Amani H, Alavi A. One-Stage Procedure for Lung and Liver Hydatid Cysts. *Asian Cardiovasc Thorac Ann.* 2008; 16: 392-395.
2. Hessam Ghassemof, Reza Jafarzadeh Esfehiani. Hydatid Disease Presented as Acute Abdomen, an Interesting Incidental Finding: A Case Report: *Arch Clin Infect Dis.* 2015; 10:
3. Dirican A, Yilmaz M, Unal B, Tatli F, Piskin T, Kayaalp C. Ruptured hydatid cysts into the peritoneum: a case series. *Eur J Trauma Emerg Surg.* 2010; 36: 375-379.
4. Gulalp B, Koseoglu Z, Toprak N, Satar S, Sebe A, Gokel Y, et al. Ruptured hydatid cyst following minimal trauma and few signs on presentation. *Neth J Med.* 2007; 65: 117-118.
5. Akcan A, Akyildiz H, Artis T, Ozturk A, Deneme MA, Ok E, et al. Peritoneal perforation of liver hydatid cysts: clinical presentation, predisposing factors, and surgical outcome. *World J Surg.* 2007; 31: 1284-1291
6. Kurt N, Oncel M, Gulmez S, Ozkan Z, Uzun H. Spontaneous and traumatic intra-peritoneal perforations of hepatic hydatid cysts: a case series. *J Gastrointest Surg.* 2003; 7: 635-641.
7. Dirican A, Unal B, Ozgor D, Piskin T, Aydin C, Sumer F, et al. Perforated hepatic hydatid cyst into the peritoneum with mild symptoms. *Case Rep Gastroenterol.* 2008; 2: 439-443.
8. Velitchkov NG, Losanoff JE, Kjossev KT, Mironov MB. Life-threatening traumatic rupture of a liver hydatid cyst. *Eur J Emerg Med.* 2001; 8: 225-228.
9. Doganay Z, Guven H, Aygun D, Altintop L, Yerliyurt M, Deniz T. Blunt abdominal trauma with unexpected anaphylactic shock due to rupture of hepatic hydatid cysts. *Grand Rounds.* 2002; 2: 17-20.
10. Derici H, Tansug T, Reyhan E, Bozdog AD, Nazli O. Acute intraperitoneal rupture of hydatid cysts. *World J Surg.* 2006; 30: 1879-1883.

Cite this article

Aghajanzadeh M, Herfatkar MR, Ghotbi F, Goharshrieha, Mohtasham B, et al. (2018) Ruptured Hydatid Cyst of Liver and Huge Pulmonary Hydatid cyst: Presented as Acute Abdomen with Severe Anaphylaxis Shock: A Rare Presentation. *Ann Clin Pathol* 6(1): 1131.