

Case Report

Hajdu-Cheney Syndrome Presenting with Extensive Lung Disease with Alveolar Cholesterol Granulomas

Jupin Chacko^{1,2*} and Javed Akhter²¹Advocate Children's Hospital, USA²Clinical Professor of Pediatrics at Rosalind Franklin University of Medicine and Science, USA

*Corresponding author

Jupin Chacko, 4440 95th St. Oak Lawn, IL, USA 60453, Tel: (847) 284-0661; Email: jupin.chacko@my.rfums.org

Submitted: 19 May 2018

Accepted: 30 May 2018

Published: 06 June 2018

ISSN: 2373-9282

Copyright

© 2018 Chacko et al.

OPEN ACCESS

Keywords

- Hajdu-Cheney syndrome
- Acroosteolysis
- NOTCH2

Abstract

Hajdu-Cheney Syndrome is an extremely rare connective tissue disorder with less than 100 reported cases worldwide. The syndrome is known for acroosteolysis of the hands and feet, short stature, developmental defects of bones, teeth and joints, among numerous other findings. This case report presents the first documented instance of lung involvement being the primary presenting feature in this syndrome.

INTRODUCTION

Hajdu-Cheney syndrome is a rare connective tissue disease with less than 100 reported cases. It was first described by Hajdu in 1948 in a 37 year old accountant and then further reported by Cheney in 1965. It is characterized by acroosteolysis of the hands and feet, severe osteoporosis, short stature, developmental defects of bones, teeth and joints causing distinctive craniofacial and skull changes including micrognathia and Wormian bones, platybasia, hydrocephalus, and basilar invagination, cardiovascular defects such as patent ductus arteriosus, atrial and ventricular septal defects, mitral and aortic valve abnormalities, developmental delay and polycystic kidneys [1]. There are additional findings, of which the most characteristic include transverse bands of acroosteolysis of the phalanges of both hands and feet, osteoporosis, and deformities of the skull, mandible, spine and other bones [2].

It is inherited in an autosomal dominant fashion but sporadic cases have been reported. The syndrome is associated with mutations in exon 34, the terminal exon of NOTCH2 upstream from the PEST domain. The PEST domain is responsible for the ubiquitination and degradation of NOTCH2 in the proteasome. Since the PEST domain is downstream, mutations in exon 34 of NOTCH2 lead to a truncated and stable NOTCH2 protein with increased NOTCH2 signaling activity. Notch receptors are proteins that determine cell fate and play a role in skeletal development and homeostasis [1]. Notch signaling additionally plays a role in the differentiation and function of osteoblasts and osteoclasts [2]. Mutations and dysregulation can therefore lead to skeletal developmental disorders [1].

Acroosteolysis of the distal phalanges of the hands and feet

and wide cranial sutures, specifically the lambdoid suture with multiple Wormian bones are radiologically specific for this syndrome [3]. These radiologic findings can make the diagnosis possible before clinical signs develop [4].

Treatment of this syndrome is mainly symptomatic. Bone antiresorptives and anabolic agents have been used to treat the osteoporosis but there is no clear evidence that either is beneficial [1]. However, there was a case report published in 2016 that did show benefit from antiresorptive therapy with denosumab that improved bone mineral density but not acroosteolysis [5]. The pathogenesis of the disease is not completely understood and there is currently no cure or proven treatment to stop the osteolytic process [4].

CASE PRESENTATION

A 5-year-old boy was born at 39 weeks via an uncomplicated pregnancy and delivery. At 5.5 weeks of life he began to develop watery secretory diarrhea. A biopsy showed features suggestive of autoimmune enteritis and Immune dysregulation, polyendocrinopathy enteropathy X-linked (IPEX) syndrome was entertained. However, gene testing and immunology testing ruled out the diagnosis of IPEX.

At 6 months of age, the patient developed pneumonia. He was seen by his pediatrician and treated empirically. No organism was identified. Parents reported that a chest X-ray done at an earlier age at an outside hospital had an infiltrate. Upon review, this X-ray done at around 5 weeks of age revealed alveolar opacities with patchy distribution in both lungs.

He continued to have frequent episodes of upper respiratory infections and episodes of bronchitis. He would get sick more

often than his sibling. The patient's pediatrician diagnosed bronchiolitis/bronchitis at one year of age and he was managed as an outpatient. At 2 years old he had RSV bronchiolitis. Symptoms were mild and he was managed as an outpatient. No hypoxemia was noted during the illness.

In 2014, the patient had low grade chest symptoms constantly. At the end of 2014, the patient's parents started to notice changes in his fingers and toes that led to a return visit. At the visit, he was noted to have severe clubbing (Figure 3) and a noisy chest without crackles or wheezing. He also appeared to have lost muscle tone.

An extensive workup was undertaken to rule out Cystic Fibrosis, antibody deficiency syndromes, leaky SCID and recurrent pulmonary aspiration. All were negative. An open lung biopsy was done that revealed patchy lung disease with multiple areas of intra-alveolar cholesterol granulomas associated with interstitial chronic inflammation located mainly in the subpleural regions of the biopsy (Figures 1 and 2). There was no significant fibrosis or bronchiolitis obliterans.

He was treated with steroids without response and repeat chest X-ray showed worsening findings. In spite of extensive lung disease, the patient's oxygen saturations remained in the high 90s on room air. Other than lung pathology, digital clubbing and poor muscle tone, there were no other organ systems involved. He was referred to St. Louis Children's Hospital for possible lung transplantation evaluation.

Whole exome sequencing was obtained and the study revealed pathogenic, de novo, heterozygous NOTCH2 variant (c.6659C>G/p.S2220X) associated with Hajdu-Cheney syndrome. He also has inherited pathogenic SERPINA1 variant from his father, SERPINA1 variant of uncertain significance inherited from his mother and SERPINA3 variant of unknown significance inherited from his mother. The specific NOTCH2 variant seen in this patient has not been previously reported but is believed to cause loss of normal protein function through protein truncation

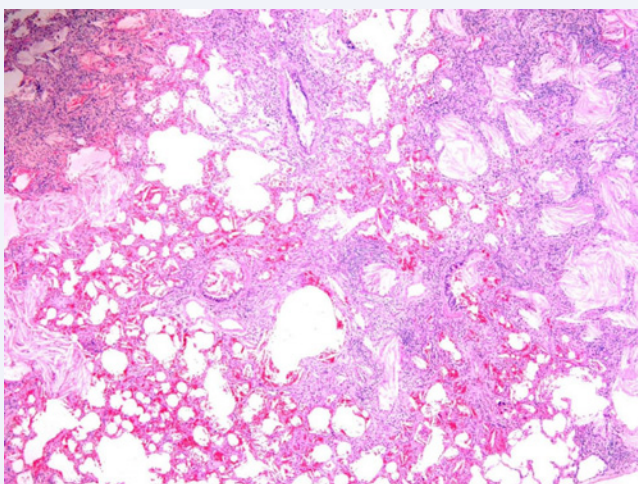


Figure 1 Low power photomicrograph of lung biopsy showing patchy alveolar filling and interstitial inflammation (hematoxylin and eosin stain, 40x original magnification).

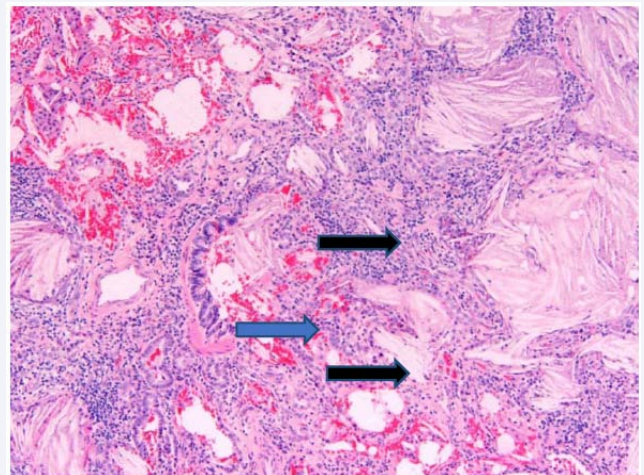


Figure 2A Intermediate power (2A) and high power (2B) photomicrographs of lung biopsy showing intraalveolar mucin accumulation with cholesterol clefts (black arrows) and chronic interstitial inflammation (blue arrows) including lymphocytes and eosinophils (red arrow) (hematoxylin and eosin stain, 2A: 100x and 2B: 200x original magnification).

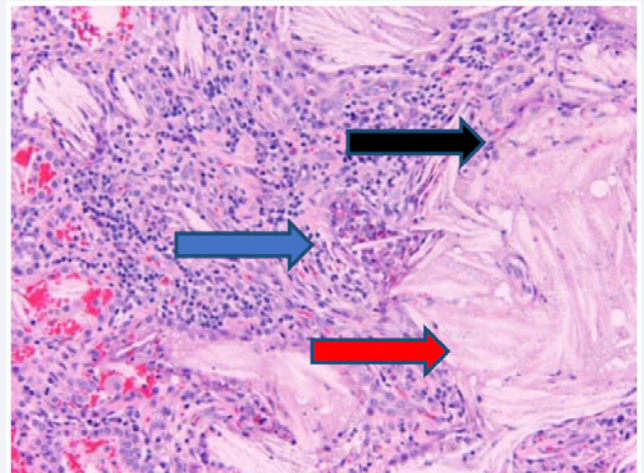


Figure 2B Digital clubbing of patient's right hand.

and be associated with the diagnosis of Hajdu-Cheney syndrome. SERPINA1 encodes alpha-1-antitrypsin and SERPINA3 encodes alpha-1-antichymotrypsin and are less likely to be related to his pulmonary findings.

The patient's physical findings had changed and his phenotype had become consistent with Hajdu-Cheney syndrome. Of note, the patient did develop back pain in 2016 and had X-rays and a DEXA scan done that year that revealed collapse of multiple vertebrae and the presence of Wormian bones.

DISCUSSION

This is the first reported patient to be identified with Hajdu-Cheney syndrome with lung disease as the presenting finding. He is also the first patient in the literature where the lung pathology has been extensively documented by imaging, including CT

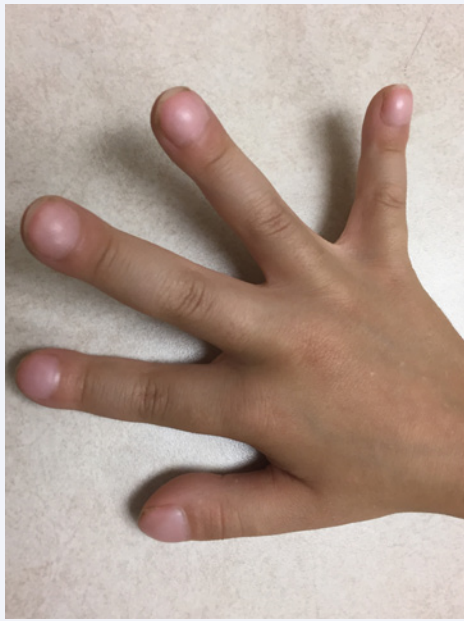

Figure 3 Digital clubbing of patient's right hand.

chest, and an open lung biopsy. Previous descriptions of lung involvement in this syndrome are limited to mention of symptoms. The patient had extensive lung disease before he exhibited any of the typical features of the syndrome including acroosteolysis or bone deformities. The findings in the boy's fingers appear to have been thickening of the bones in both hands and feet giving the erroneous impression of clubbing.

The oral steroids were discontinued and he is now on hydroxychloroquine. His lung disease appears to be responding to this medication.

Based on this patient's findings, there is need to look at lung involvement in other patients with Hajdu-Cheney syndrome to further determine the frequency, severity and type of lung involvement associated with this disease.

ACKNOWLEDGEMENTS

We would like to thank Dr. Aliya Husain (Professor of Pathology and Residency Program Director at the University of Chicago) for her help regarding the pathology slides and interpretations she was kind enough to provide.

REFERENCES

1. Canalis, E, and Zanotti, S. Hajdu-Cheney Syndrome: A Review. *Orphanet Journal of Rare Diseases* 9.1. 2014.
2. Palav, S, Vernekar, J, Pereira, S, and Desai, A. Hajdu-Cheney Syndrome: A case report with review of literature. *Journal of Radiology Case Reports*. 2014; 8: 8-9.
3. Marik, I, Kuklik, M, Zemkova, D, and Kozlowski, K. Hajdu-Cheney syndrome: Report of a family and a short literature review. *Australasian Radiology*. 2006; 50: 534-538.
4. Vingerhoedt, E, Bailleul-Forestier, I, Fellus, P, Schoenaers, J, Frijns, J-P, and Carels, C. Syndrome of Hajdu-Cheney: Three Case Reports of Orofacial Interest. *The Cleft Palate-Craniofacial Journal*. 2010; 47: 45-653.
5. Giovanni A, Maurizio R, Davide G. Hajdu Cheney Syndrome; Report of a Novel NOTCH2 Mutation and Treatment with Denosumab. *Bone*. 2016; 92: 150-156.

Cite this article

Chacko J, Akhter J (2018) Hajdu-Cheney Syndrome Presenting with Extensive Lung Disease with Alveolar Cholesterol Granulomas. *Ann Clin Pathol* 6(3): 1140.