

Short Communication

Expression of Membrane Type-Matrix Metalloproteinases in Common Epithelial Malignant Tumors of the Ovary

Testuri M¹, Daghero H¹, Rey G², Acosta G³, Bernachin J³, and Marco M^{1*}¹Departamento de Bioquímica Clínica, Universidad de la República, Uruguay²Clínica Ginecológica B, Hospital de Clínicas, Uruguay³Laboratorio de Anatomía Patológica, Uruguay

*Corresponding author

Marta Marco, Area de Biología Tumoral-Departamento de Bioquímica Clínica, Facultad de Química, Av. Gral. Flores 2124, Universidad de la República Montevideo, Uruguay CP 11800, Tel: 59829290608; Fax: 59829241906; Email: mmarco@fq.edu.uy

Submitted: 02 May 2018

Accepted: 30 May 2018

Published: 08 June 2018

ISSN: 2373-9282

Copyright

© 2018 Testuri et al.

OPEN ACCESS

Keywords

- Immunohistochemistry
- MT-matrix metalloproteinases
- Extracellular matrix
- Ovarian cancer

Abstract

Ovarian cancer is one of the most malignant genital cancers, with a high mortality rate. Despite decades of research, the survival rate of ovarian cancer patients is largely unchanged, and there is a pressing need for identifying novel therapeutic targets.

Many researchers have suggested that soluble matrix metalloproteinases (MMPs) have remarkably high expression in ovarian cancer tissues, and they are considered to be related to the occurrence, development, invasion and metastasis of ovarian cancer. Moreover, some studies have discovered that the unbalance between MMPs and tissue inhibitor of metalloproteinases (TIMPs) are associated with the malignant phenotype of tumors. In spite of this, there is a lack of information about the expression of membrane type –MMPs (without taking into account MT1-MMP) in ovarian cancer.

This report shows (using immunohistochemistry) an increase in the expression of MT3- and MT5-MMPs especially in the most aggressive histological types (comparing with normal and benign tumors), which could suggest a possible biological role in the development of this pathology.

ABBREVIATIONS

ECM: Extracellular Matrix; GPI: Glycosylphosphatidylinositol; MT-MMP: Membrane Type-Matrix Metalloproteinase; TIMP: Tissue Inhibitor of Metalloproteinase; TM: Transmembrane

INTRODUCTION

Epithelial Ovarian Cancer (EOC) is ranked as the seventh most common cancer in women, and is the deadliest of gynecologic cancers due to the asymptomatic profile in early stages and insensitive diagnostic methods [1,2] being its etiology still uncertain.

So, EOC is frequently diagnosed in final stages when massive ASCITES is all together and peritoneal spreading has already occurred, making difficult to thoroughly remove the tumor mass by surgery and being an stage that is usually unresponsive to classical treatments but only to aggressive treatment methods [3]. At these late stages of cancer development here is a poor prognosis and the survival rate is low at 30% [1,4]. Therefore, in order to timely and effectively diagnose and treat ovarian cancer, as well as to improve the prognosis and survival rate of patients,

it is essential to identify ovarian cancer-specific tumor markers with high sensitivity [5-8].

EOC consists of a heterogeneous entity with distinct histopathological subtypes, being the more common serous, mucinous and endometrioid carcinomas; while the less common subtypes include clear cell, transitional, squamous, mixed, and undifferentiated subtypes [9].

MMPs are zinc-dependent endopeptidases that collectively have the potential to hydrolyze all protein components of the ECM. In addition, MMPs cleave a wide range of cellular and secreted proteins known to play key roles in a variety of physiological functions and pathological conditions as cancer. In humans, the MMP family includes 24 members on the base of structural organization and substrate specificity and is further divided in two major subgroups: secreted and membrane-anchored proteinases (referred to as MT-MMPs). The distinction is made upon the absence or presence of membrane anchoring domains.

To control their proteolytic activity, all MMPs are synthesized as latent pro-enzymes (referred to as pro-MMPs). Activation, the

acquisition of catalytic activity, is achieved by various proteinases or reactive oxygen species that disrupt the interaction between the active site zinc atom in the catalytic domain and a conserved cysteine within the pro-domain. Exposure of the zinc atom results in the autolytic cleavage of the pro-domain, a process known as the “cysteine switch” [11]. Once activated, MMPs catalytic activity is controlled in part by TIMPs, which act as specific proteinase inhibitors. Based on the structure of membrane anchoring domain and orientation, the MT-MMP subfamily comprises four type I TM proteases, two GPI-anchored proteinases, and one type II TM proteinase (Figure 1). The type I TM proteases include: MT1- (MMP14), MT2- (MMP15), MT3- (MMP16), and MT5- (MMP24) MMP and GPI anchored MT-MMPs include MT4- (MMP17), and MT6- (MMP25) MMP. MMP23 is the only known type II TM protein. Here we will focus on the type I MT-MMPs and GPI-anchored MT-MMPs and thus refer to them herein as MT-MMPs [10], (Figure 1)

Matrix metalloproteinases (MMPs) are frequently expressed in ovarian cancer, and play an important role in the metastatic process. MMPs mediate degradation of the basement membrane as a crucial step in epithelial transformation, ovarian tumorigenesis and intraperitoneal metastasis. Various preclinical and clinical studies have demonstrated that MMPs might provide a suitable therapeutic target [12-16].

Evidence has been reported supporting the strong association between different members of the soluble MMPs family members and the occurrence, development, and metastasis of ovarian cancer [17]. MMP14, also known as membrane-type 1 MMP (MT1-MMP), plays an important role in the invasion and metastasis of a variety of cancers by activation of proMMP-2 and ECM degradation [18]. Higher expression of MMP14 is associated with lower progression and better prognosis of ovarian carcinoma [19]. Moreover, patients with double expression of MMP14 and CD44 have a poor prognosis [15]. However, no other component of the MT-MMP family has been reported to be expressed and/or play a role in this pathology.

So, the aim of the present study is to detect the expression and possible distribution of MT (1-6) MMPs in normal and different histopathological subtypes of human ovarian cancer by immunohistochemistry.

MATERIALS AND METHODS

Patients and tissue specimens

Patients with diagnosis of Para Uterine Tumor (PUT) were recruited from the Hospital de Clínicas (Montevideo, Uruguay) in the period 2008-2016 (n = 180). Samples were obtained from: 1) Tumor directly and 2) Tumor with adjacent tissue. During surgery, a 4x2x2 mm fragment of a cystic area and another fragment of a solid area, if any, will be taken fresh. Also a fragment of a normal sector of the ovary, if recognized.

A macroscopic study was performed according to the protocol of the American Pathologists College (CAP-2010). Part of the samples will be taken, average between 10 to 35 fragments of the tumor and fixed in buffered formalin. They were included in paraffin and cuts will be made with semiautomatic microtome between 4 to 6 microns. They were stained with Hematoxylin-

Eosin (H&E), PAS, PAS-Alcian Blue and Masson's Trichrome. The latest WHO Ovarian Tumor Classification was used. (2002). An experienced pathologist reviewed all H&E-stained slides of the paraffin-embedded tissue so to designate appropriate sites. Formalin-fixed and paraffin-embedded sections were removed from the selected sites and arranged into single slides.

The records of patients were reviewed in the context of clinicopathological and follow-up work. The EOC stage was classified according to the latest criteria of the International Federation of Gynecology and Obstetrics (FIGO) [20].

None of the patients received preoperative chemotherapy or radiation therapy.

Prior to this, informed consent was obtained from each patient and as well this study was approved by the Research Ethics Committee of the Medical University.

Immunohistochemistry

Sections were deparaffinized in xylene, and dehydrated with graded ethanol. Antigen retrieval was done by heating each section in a pressure cooker for 30 min in citrate buffer (pH 6.0). After cooling for 20 min at room temperature (RT) and washing three times for 5 min with distilled water and then phosphate-buffered saline (PBS), sections were immersed in 3% hydrogen peroxide in methanol for 30 min at room temperature to suppress endogenous peroxidase activity. Sections were then washed again in PBS. To block non-specific binding sites slides were incubated with 2.5% normal horse serum for 20 minutes at room temperature. After this, they were incubated overnight at 4°C with different primary antibodies diluted in PBS.

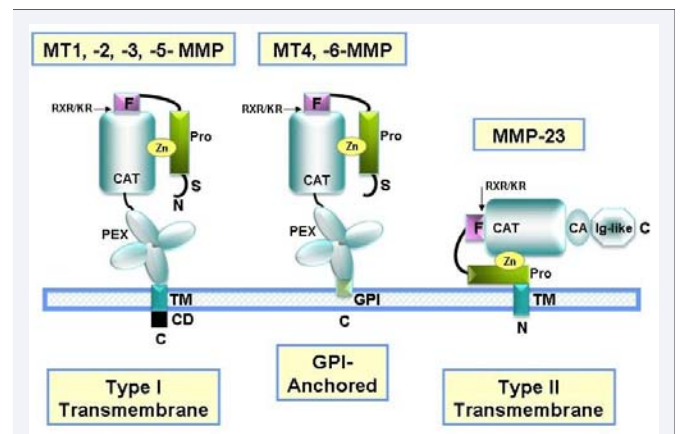


Figure 1 Domain structure of membrane-anchored MMPs. Most MMPs contain a propeptide domain (Pro), a catalytic domain (CAT), a linker (hinge- region) and a PEX domain. All the membrane-anchored MMPs have a basic RX (K/R) R motif at the C-terminal end of their prodomains. This motif can be cleaved inside the cells by furin-like proteinases. Four of the six MT-MMPs are anchored to the cell membranes through a type I transmembrane (TM) domain and the other two through a glycosylphosphatidylinositol (GPI) moiety. The seventh membrane-anchored MMP, MMP-23, has an N-terminal type II transmembrane (TM) domain. The two minimal domain MMPs and MMP-23 lack the PEX domain, and, in the latter enzyme, this domain is replaced by a C-terminal cysteine array (Ca) and an immunoglobulin-like (Ig) domain.

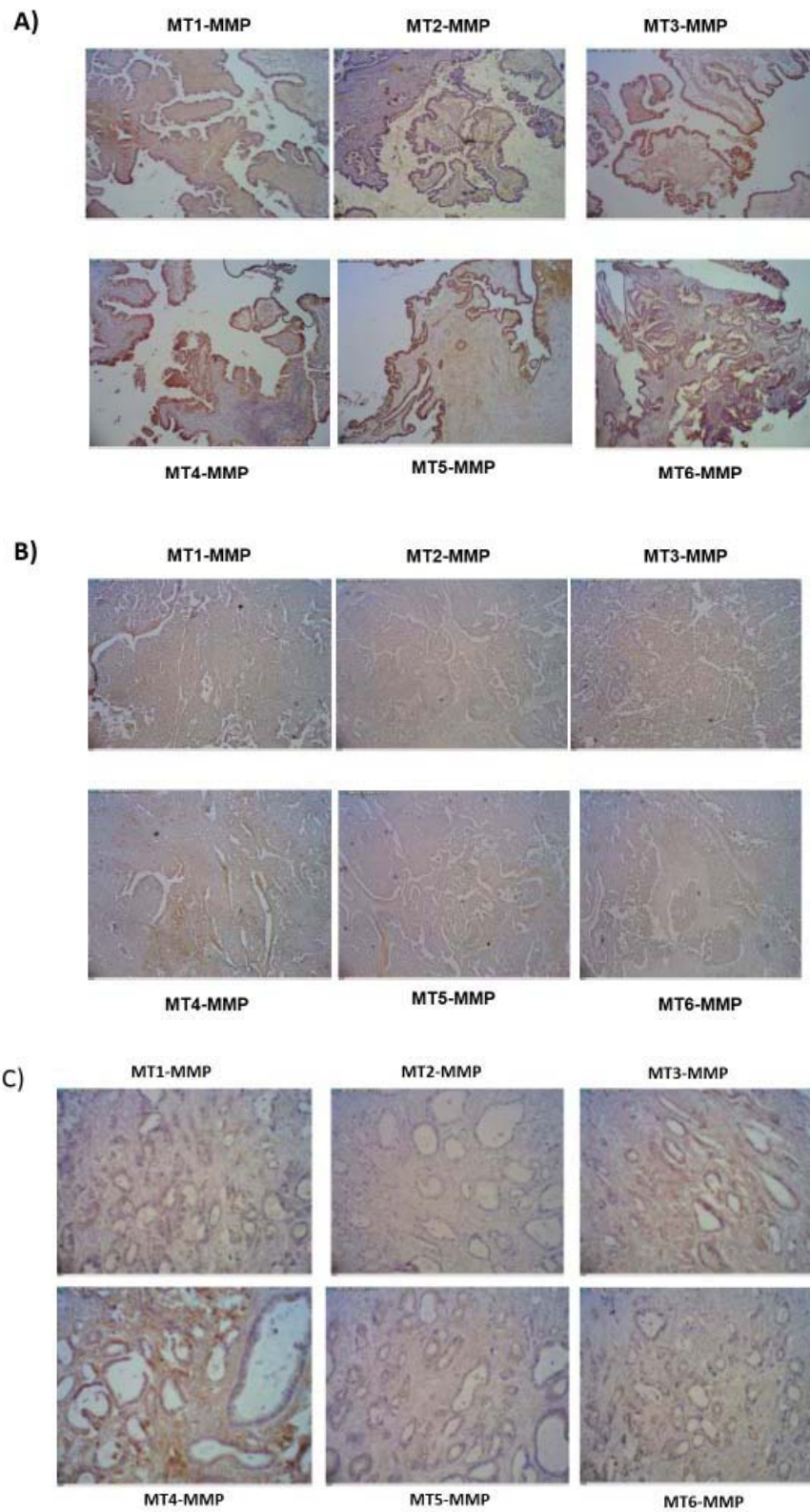


Figure 2 Immunohistochemistry for MT (1-6)-MMPs in primary human ovarian cancers tissues. (x10) A) Serous high differentiated (low grade (LG)), B) Serous Poor differentiated (solid, high grade (HG)) and C) Mucinous EOC.

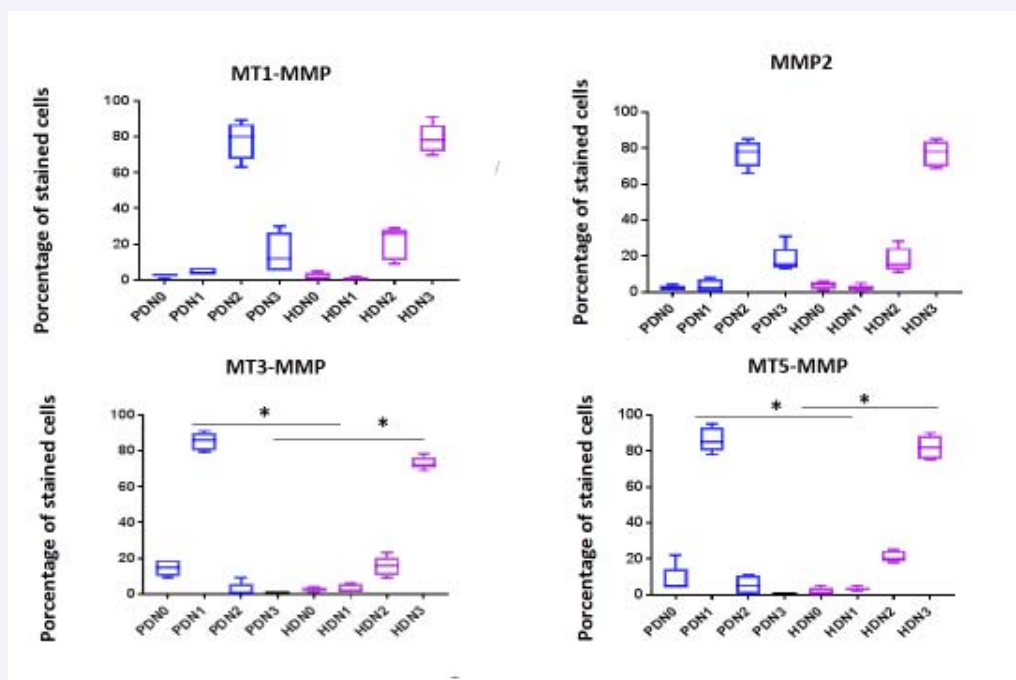


Figure 3 Distribution of positive intensity by IHQ for MT-MMPs in different stages of serous ovarian cancer. Expression as percentage of stained cells per score for MT1-MMP, MT3-MMP, MT5-MMP and MMP2 in high differentiated (HD) and poor differentiated (PD) serous EOC. Statistical evaluation was performed using the free Prisma-Graph Pad software with Anova of one tail and Scheffe as post-hoc. $P < 0.05$ was considered as statistically significant.

Clinicopathological qualities		n %
Age	<55	41 (53%)
	≥55	27 (47%)
Localisation	Right	22 (28%)
	Left	17 (22%)
	Bilateral	39 (50%)
Tumour size	≤10cm	54 (69%)
	>10 cm	24 (31%)
Histologic type	epithelial type	
	Serous adenocarcinoma	46 (59%)
	Mucinous adenocarcinoma	24 (31%)
	others	
	Granulosa tumor	6 (8%)
Mesenchymal tumor	2 (2%)	
Tumour grade	Well differentiated (HD)	18 (39%)
	Poor differentiated (PD)	28 (61%)
Tumour stage (FIGO) Serous carcinoma	Borderline	8 (17%)
	Early stage (IA-IIIC)	10 (22%)
	Advanced stage (IIIA-IV)	28 (61%)
Tumour stage (FIGO) Mucinous carcinoma	Borderline	6 (27%)
	Early stage (IA-IIIC)	14 (55%)
	Advanced stage (IIIA-IV)	4 (18%)

Table 1: Demographic, clinic and histopathologic features of the patients.

Slides were washed three times in PBS (each wash for 5 min). Sections were then incubated with ImmPRESS™ reagent (anti-rabbit (or mice) Ig [peroxidase] polymer) for 30 min at RT. After three additional washes, peroxidase activity was developed with diaminobenzidine at RT. Staining was done using prepared reagent (1 drop ImmPACT™ DAB Chromogen concentrate in 1 ml Imm PACT™ DAB Diluent, according to manufacturer’s instructions) and then counterstained with Meyer’s Hematoxylin for 10 seconds. Subsequently, samples were dehydrated through an alcohol gradient, and samples were sealed onto slides with cover slips.

Digital photomicrographs were captured using an optical microscope (Zeiss Axioplan 2; Zeiss, Gottingen, Germany) equipped with a software-controlled digital camera (Axiovision; Zeiss). Irrelevant rabbit or mice IgG (20 µg/ml) was used as isotype negative control (Santa Cruz Biotechnology, Santa Cruz, CA). In negative control experiments primary antibody was omitted, and a positive and negative control tissue was prepared for each antibody.

The immunohistochemistry technique was standardized for each of the antibodies to be studied (MT1-MT6-MMP, CA125, MMP-9 and -2) versus the suggested positive controls according with datasheets.

The commercial antibodies tested were: **Abcam** (USA) Rabbit polyclonal MMP16 (MT3-MMP) Cat.: ab 73877, Rabbit polyclonal MMP17 (MT4-MMP) Cat.: ab 39028, Rabbit polyclonal MMP24 (MT5-MMP) Cat.: ab 135564 and Mouse monoclonal CA125 (MUC16) (X325) Cat.: ab 10033. **Santa Cruz** (USA) Rabbit polyclonal IgG MMP14 (MT1-MMP) (H72) Cat.: sc-30074, mouse

monoclonal IgG₁ MMP15 (MT2-MMP)(YZ12)Cat.: sc-80213, mouse monoclonal IgG₁ MMP25 (MT6-MMP) (MM0029-2B5) Cat.: sc-101453, mouse monoclonal IgG₁ MMP2 (4D3)Cat.: sc-53630, and mouse monoclonal IgG₁ MMP9 (7-11C)Cat.: sc-13520.

For immunohistochemical analysis, all the tumor areas were examined at low magnification (x10). For each antibody in the epithelial cells, at x20 magnification. The percentage of stained tumor cells, and at high magnification (x40), the intensity of tumor cells were determined semi quantitatively and subjectively.

Evaluation of immunoreactivity and histological appearance for all cases were examined and scored by two authors concurrently. The intensity of cytoplasmic and membrane immunostaining of tumor cells was scored on a scale of (0) absent (no staining), weak (1+), moderate (2+) to strong (3+) (strongest intensity), and the percentage of tumor cells (over 100 cells) with cytoplasmic or membranous staining at each intensity was estimated for each sample.

Statistical analysis

Statistical evaluation was performed using the free Prisma-Graph Pad software with Anova of one tail and Scheffe as post-hoc. $P < 0.05$ was considered as statistically significant.

RESULTS AND DISCUSSION

A total of 186 samples were collected with clinical PUT diagnosis of ovarian tumor during the period described. 52% (n =96) were benign ovarian tumors, 42% (n=78) primitive ovarian cancer (POC), 3% (n=6) primary from another origin with ovarian metastasis and 3% (n=6) peritoneal carcinomatosis (data confirmed by deferred pathological anatomy in paraffin). Of the POC total cases: 90% (n=70) were found to be of the epithelial type (66% (n=46) serous and 34% (n=24) mucinous) and 8% (n=6) were non-epithelial (cords) while 2% (n=2) of cases were mesenchymal

In demographic records, the patients' age, tumour's location, diameter, type, grade and stage of the patients with POC were evaluated (Table 1). The median tumour diameter was 9.55 cm (range, 2.5 -25 cm). No statistical correlation was detected in the comparison between age and stage, tumour diameter, histological type either in benign or malignant tumors.

In the benign tumor group, the patients' median age was 48 years (range 20-79): 56% women were premenopausal. In the borderline tumor group, the median age of patients was 32 years (range 18-70) and 52% women were pre-menopausal. In the malignant tumor group, the median age of patients was 55 years (range 40-85) and 25% were pre-menopausal.

All the tumors were reviewed to confirm histological diagnosis. Histological typing followed the FIGO recommendations [21]. Borderline ovarian tumors were defined by serous or mucinous tumors, with proliferating activity of the epithelial cells and nuclear abnormalities, but with no infiltrative destructive growth.

Regarding EOC distribution according to the FIGO stage at the time of diagnosis, it was found that serous tumors were distributed in 17% (n=8) borderline, 22% (n=10) stage FIGO I and II and 61% (n=28) stage III and IV while mucinous tumors

were 27% (n=6) borderline, 55% (n=14) stages I and II and 18% (n=4) stages III and IV. All these data coincide with those reported in bibliography.

The results obtained so far show that in serous primitive EOC cases positive signal was found in the tumor area in 100% for CA125 and 83% for MMP2 mean while MMP9 was negative (in cell tumors) in the 100% of cases studied (Table 2). Normal ovaries (n= 50) were also tested not finding positive significant signal for the three markers in any case.

Regarding the expression of MT-MMPs, unlike normal and benign pathologies in ovaries (where it was not detected specific expression) it was found that MT1-MMP (83%), MT3-MMP (74%) and MT5-MMP (83%) were highly expressed in serous carcinomas, meanwhile MT2-MMP (24%), MT4-MMP (43%) and MT6-MMP (17%) where less and erratic expressed for the same panel of study. Interestingly, MT6-MMP for its part begins to express itself in early FIGO stages (Table 2).

Regarding the primary cases of the mucinous type same results were obtained for CA125, MMP-9 y-2, MT3- and MT5-MMP than with respect to serous. However MT2- and MT3-MMP were erratic. MT1- and MT4-MMP were expressed to the extent that the pathology was more advanced. (not shown).

It should be noted that in the case of the mucinous borderline tumors analyzed, MT1- and MT2-MMP showed no expression in either case, while MT3- and MT5-MMP they showed positivity in 100% of the cases. CA125, MMP-9 and -2 showed the same results as for the mucinous ones described above. (not shown)

As for the primitive ovarian OC of the granulosa cell type, they showed a totally different expression owing to their not epithelial origin. The negative signal for the MT-MMPs tested, demonstrates behavior and evolution totally different from the previous ones (not shown). The expression of CA125, MMP9 and -2 was erratic. The results for the mesenchymal OC show in 100% of the cases positivity of mild to MT1- MT4- and MT5-MMP; which is also a different expression to the one shown by the serous and mucinous since these originate from the mesenchyme and not of the epithelium. More cases should be tested for mesenchymal and granulosa OC to conclude a significant expression about MT-MMPs.

In spite of the results above described, the presence of a positive signal was not identical in each of the EOC case. In Figure 2 it was represented the differences between a high differentiated (HD) (low grade) serous tumor (strong signal for MT1-, MT3- and MT5-MMP) and a poor differentiated (PD) (high grade) serous tumor (weak and diffuse signal) mean while a moderate differentiated mucinous tumor presents a positive weak mark for all the markers tested. So, a score of intensity was done to show expression differences in serous tumors (Figure 3). We can conclude that MT1-MMP is highly expressed either in early as in late stages (HD and PD) of ovarian serous carcinomas with a moderate/high level (presenting the same result for MMP2) (Figure 3).

This correlation agree with the literature since MMP2 is cleaved and activated by MT1-MMP and reported to perform different functions at many steps of the progression of the disease.

FIGO Stage	CA 125	MMP9	MMP 2	MT1 MMP	MT2 MMP	MT3 MMP	MT4 MMP	MT5 MMP	MT6 MMP
Border N=8	8 (100%)	0 (0%)	8 (100%)	8 (100%)	8 (100%)	8 (100%)	5 (67%)	8 (100%)	3 (33%)
I y II N=10	10 (100%)	0 (0%)	10 (100%)	7 (70%)	0 (0%)	10 (100%)	5 (50%)	7 (70%)	5 (50%)
III y IV N=28	28 (100%)	0 (0%)	20 (72%)	23 (82%)	3 (9%)	16 (55%)	10 (36%)	23 (82%)	0 (0%)
Total positive cases over N=46	(100%)	(0%)	(83%)	(83%)	(24%)	(74%)	(43%)	(83%)	17%

Table 2: Expression of MT-MMPs in serous ovarian cancer by Immunohistochemistry.

By the other hand MT3- and MT5- MMP are highly expressed with strong intensity in high differentiated cases (HD) being weak in poor differentiated (PD) ovarian cancers.

In short, it is important to highlight the over expression of MT1-, MT3 – and MT5- specially in serous EOCs, which correspond to a more aggressive ovarian pathology, taking into account the maintenance of the strong signal for MT1-MMP (and MMP2) not having statistical difference between HD and PD cases, and the decrease of the MT3- and MT5-MMP expression as far the pathology advance, being weak in mucinous cases which are less aggressive. Also noteworthy is the difference in the expression of the MT-MMPs according to the origin of the tumor. They appear positive in tumors of epithelial origin, mild positivity in those of mesenchymal origin and are not expressed in those of the sexual cords and stroma.

In summary, several lines of evidence indicate that soluble MMPs are frequently expressed in ovarian cancer having a key role in metastasis and also are described as potential prognostic markers. In spite of this, very few information is available about expression of MT-MMPs in this pathology. By virtue of their presence on the surface of the cell, all of the MT-MMPs are thought to participate in pericellular proteolysis to promote cell growth and migration which are hallmarks for cancer metastasis as to play a key role in the vascular changes or vasculogenic mimicry associated with ovarian tumor formation and growth[22]. But indeed only MT1-MMP by activating MMP2 was demonstrated to participate in these biological functions. It is known that neither MT3-MMP nor MT5-MMP are able to activate it [23,24]

Additionally, emerging evidence suggests that MMPs may have non-proteolytic actions working through the hemopexin domain [25].

So, our results show for the first time over expression in EOC of MT3- and MT5-MMPs (besides MT1-MMP which was reported). More work should be done (including the expression of their specific inhibitors TIMP-2, TIMP-3, and TIMP-4) to know the possible biological function for these MT-MMPs and the role they could be playing in the development of ovarian cancer and their possible use as a therapeutic targets to complement conventional anticancer strategies.

ACKNOWLEDGMENTS

This work was supported in part by funds from CSIC proyecto I+D 817 - Universidad de la República (to M.Marco), and ANII initiation to research program (to M. Testuri).

The authors wish to thank also to the personal of Clínica Ginecotológica B (Hospital de Clínicas), Departamento de Anatomía Patológica (Hospital de Clínicas) and EUTM tecnicatura en anatomíapatológica (I. Sanson y S. Ravaglio).

REFERENCES

1. Siegel RL, Miller KD, Jemal A. Cancer Statistics. CA Cancer J Clin. 2017; 67: 7-30.
2. Manchanda R, Halaska MJ, Piek JM, Grabowski JP, Haidopoulos D, Zapardiel I, et al. The Need for More Workshops in Laparoscopic Surgery and Surgical Anatomy for European Gynaecological Oncology Trainees: A Survey by the European Network of Young Gynaecological Oncologists. Int J Gynecol Cancer. 2013; 23: 1127-1132.
3. Vlad C, Kubelac P, Alexandru I, Achimas-Cadariu P. The Role of Primary Debulking in Advanced Ovarian Cancer Patients. J BUON. 2016; 21: 1320.
4. Ferlay J, Soerjomataram I, Dikshit R, Eser S, Mathers C, Rebelo M, et al. Cancer Incidence and Mortality Worldwide: Sources, Methods and Major Patterns in GLOBOCAN 2012. Int J Cancer. 2015; 136: E359-E386.
5. Buys SS, Partridge E, Black A, Johnson CC, Lamerato L, Isaacs C, et al. Effect of Screening on Ovarian Cancer Mortality: The Prostate, Lung, Colorectal and Ovarian (PLCO) Cancer Screening Randomized Controlled Trial. JAMA. 2011; 305: 2295-2303.
6. Irimie A, Achimas-Cadariu P, Burz C, Puscas E. Multiple Primary Malignancies--Epidemiological Analysis at a Single Tertiary Institution. J Gastrointest Liver Dis. 2010; 19: 69-73.
7. Meinhold-Heerlein I, Fotopoulou C, Harter P, Kurzeder C, Mustea A, Wimberger P, et al. The New WHO Classification of Ovarian, Fallopian Tube, and Primary Peritoneal Cancer and its Clinical Implications. Arch Gynecol Obstet. 2016; 293: 695-700.
8. Yeung TL, Leung CS, Yip KP, Au Yeung CL, Wong ST, Mok SC. Cellular and Molecular Processes in Ovarian Cancer Metastasis. A Review in the Theme: Cell and Molecular Processes in Cancer Metastasis. Am J Physiol Cell Physiol. 2015; 309: 444-456.
9. Hennessy BT, Coleman RL, Markman M. Ovarian cancer. Lancet. 2009; 374: 1371-1382.
10. Marco M, Fortin C, Fulop T. Membrane-Type Matrix Metalloproteinases:

- Key Mediators of Leukocyte Function. *J Leukoc Biol.* 2013; 94: 237-246.
11. Van Wart HE, Birkedal-Hansen H. The Cysteine Switch: A Principle of Regulation of Metalloproteinase Activity with Potential Applicability to the Entire Matrix Metalloproteinase Gene Family. *Proc Natl Acad Sci U S A.* 1990; 87: 5578-5582.
 12. Escalona RM, Chan E, Kannourakis G, Findlay JK, Ahmed N. The Many Facets of Metzincins and their Endogenous Inhibitors: Perspectives on Ovarian Cancer Progression. *Int J Mol Sci.* 2018; 19: 450.
 13. Zhang Y, Chen Q. Relationship Between Matrix Metalloproteinases and the Occurrence and Development of Ovarian Cancer. *Braz J Med Biol Res.* 2017; 50: 6104.
 14. Brun JL, Cortez A, Lesieur B, Uzan S, Rouzier R, Daraï E. Expression of MMP-2, -7, -9, MT1-MMP and TIMP-1 and -2 has no Prognostic Relevance in Patients with Advanced Epithelial Ovarian Cancer. *Oncol Rep.* 2012; 27: 1049-1057.
 15. Vos MC, Hollemans E, Ezendam N, Feijen H, Boll D, Pijlman B, et al. MMP-14 and CD44 in Epithelial-to-Mesenchymal Transition (EMT) in Ovarian Cancer. *J Ovarian Res.* 2016; 9: 53.
 16. Brun JL, Cortez A, Commo F, Uzan S, Rouzier R, Daraï E. Serous and Mucinous Ovarian Tumors Express Different Profiles of MMP-2, -7, -9, MT1-MMP, and TIMP-1 and -2. *Int J Oncol.* 2008; 33: 1239-1246.
 17. Rasool M, Malik A, Basit Ashraf MA, Parveen G, Iqbal S, Ali I, et al. Evaluation of Matrix Metalloproteinases, Cytokines and their Potential Role in the Development of Ovarian Cancer. *PLoS One* 2016; 11.
 18. Shiomi T, Okada Y. MT1-MMP and MMP-7 in Invasion and Metastasis of Human Cancers. *Cancer Metastasis Rev.* 2003; 22: 145-152.
 19. Trudel D, Desmeules P, Turcotte S, Plante M, Grégoire J, Renaud MC, et al. Visual and Automated Assessment of Matrix Metalloproteinase-14 Tissue Expression for the Evaluation of Ovarian Cancer Prognosis. *Mod Pathol.* 2014; 27: 1394-1404.
 20. Pecorelli S. Revised FIGO Staging for Carcinoma of the Vulva, Cervix and Endometrium. *Int J Gynaecol Obstet.* 2009; 105: 103-104.
 21. Benedet JL, Bender H, Jones H 3rd, Ngan HY, Pecorelli S. FIGO Staging Classifications and Clinical Practice Guidelines in the Management of Gynecologic Cancers. FIGO Committee on Gynecologic Oncology. *Int J Gynecol Obstet.* 2000; 70: 209-262.
 22. Al-Alem L, Curry TE Jr. Ovarian Cancer: Involvement of the Matrix Metalloproteinases. *Reproduction.* 2015; 150: 55-64.
 23. Zucker S, Drews M, Conner C, Foda HD, DeClerck YA, Langley KE, et al. Tissue Inhibitor of Metalloproteinase-2 (TIMP-2) Binds to the Catalytic Domain of the Cell Surface Receptor, Membrane Type 1-Matrix Metalloproteinase 1 (MT1-MMP). *J Biol Chem.* 1998; 273: 1216-1222.
 24. Miyamori H, Hasegawa K, Kim KR, Sato H. Expression of Metastasis-Associated Mts1 Gene is Coinduced with Membrane Type-1 Matrix Metalloproteinase (MT1-MMP) During Oncogenic Transformation and Tubular Formation of Madin Darby Canine Kidney (MDCK) Epithelial Cells. *Clin Exp Metastasis.* 2000; 18: 51-56.
 25. Correia AL, Mori H, Chen EI, Schmitt FC, Bissell MJ. The Hemopexin Domain of MMP3 is Responsible for Mammary Epithelial Invasion and Morphogenesis Through Extracellular Interaction with HSP90 β . *Genes Dev.* 2013; 27: 805-817.

Cite this article

Testuri M, Daghero H, Rey G, Acosta G, Bernachin J, et al. (2018) Expression of Membrane Type- Matrix Metalloproteinases in Common Epithelial Malignant Tumors of the Ovary. *Ann Clin Pathol* 6(4): 1142.