

## Case Report

# Boerhaave's Syndrome Unusual Presentation in a 4 Month Old Infant, a Case Report and Review of Literature

Rao KS\*, Kalpana Malla, Abhishek Singh, Shanker poudel, Ganesh BK, Sudhir Adhikari, Tewari PK, Vishal Sharma

Department of Pediatrics, Radiology, Otolaryngology, Manipal College of Medical Sciences, Nepal

**\*Corresponding author**

Rao KS, Department of Pediatrics, Radiology, Otolaryngology, Manipal College of Medical Sciences, Nepal, Email: drksrao29@hotmail.com

Submitted: 05 September 2014

Accepted: 10 February 2015

Published: 12 February 2015

## Copyright

© 2015 Rao et al.

## OPEN ACCESS

## Keywords

- Boerhaave's syndrome
- Pneumo mediastinum
- Subcutaneous emphysema

**Abstract**

Boerhaave's syndrome is associated with spontaneous rupture of lower end of esophagus after a bout of vomiting, leading to chest pain and sub cutaneous emphysema, pneumomediastinum and leakage of fluids in to the base of the lungs. Boerhaave's syndrome is rare in paediatric practice. Only 28 cases were reported in children till date. The youngest child reported to have boerhaave's syndrome was a six month old Hispanic male infant who was undergoing chemo therapy for leukaemia and developed respiratory distress after a bout of vomiting. He was found to have precordial and mediastinal emphysema with evidence of lower end esophageal perforation. We now report a case of a four month old infant who was suffering from acute gastroenteritis and after a bout of vomiting has developed mediastinal emphysema ( both pre and retro cardiac region) and subcutaneous emphysema over the chest wall extending to the neck and both sides of the face with evidence of a rent in the lower end of oesophagus suggestive of Boerhaave's syndrome . He was treated conservatively without resorting to surgery.

**INTRODUCTION**

Boerhaave's syndrome is associated with spontaneous rupture of lower end of oesophagus leading to surgical emphysema and pneumo mediastinum. It was first described by Dr Herman Boerhaave a Dutch physician in 1724. His patient was a 50 year old grand Admiral of the Netherlands, Baron Jan Van wassenaer, who died in 1723 eighteen hours after attempting self induced vomiting following a sumptuous large meal. He complained of pain abdomen and right sided chest pain. The post-mortem revealed tear in the posterolateral aspect of esophagus 5cm above the diaphragm with mediastinal emphysema and food in the left pleural space [1]. About three hundred cases were reported in adults worldwide [2] and 127 cases were documented by Bladder Groen et al in 1986, out of them 114 were diagnosed antemortem and others were diagnosed at autopsy. Boerhaave's syndrome accounted for 15% of all cases of traumatic rupture or perforation of esophagus [3]. In the years between 1947 to 1980 the mortality in cases with Boerhaave's syndrome was 50%. After 1980 the mortality came down to 31% [3,4] with the advent of improved facilities for early diagnosis, surgical repair and improved intensive care [4]. It was found to be rare in pediatric practice [5]. Only 28 cases were reported in literature and out of

them only two cases were treated conservatively without under taking surgical repair [6,7]. Boerhaave's syndrome was earlier reported in a six month old Hispanic infant [8]. We are now reporting Boerhaave's syndrome in a 4month old male infant who was managed conservatively.

**CASE PRESENTATION**

A 4 month old male infant was brought to the emergency clinic of Manipal Teaching Hospital with the complaints of rapidly increasing swelling of the chest wall and gradually extending to the neck and face resulting in dyspnoea. The mother gave the history of bluish discoloration of the lips and coldness of the limb and frequent loose motions and vomiting. She complained that the swelling of the chest wall, neck and both sides of the face started after a bout of vomiting one hour prior to admission. Clinical examination revealed that the infant was severely dehydrated, dyspnoeic, mildly cyanosed with peripheries cold and clammy (suggestive of peripheral collapse) with rapidly increasing surgical emphysema over the chest wall extending to the neck, sub mandibular region and both sides of the face. Sub cutaneous emphysema was confirmed by eliciting the crepitus. Percussion note of the chest was resonant. Auscultatory findings

revealed decreased air entry with the evidence of pericardial rub suggestive of associated pneumo mediastinum with right basal crepitations. The emergency X-Ray chest [Figure1] confirmed Sub cutaneous emphysema extending from chest wall to the neck, submandibular region, facial planes of the neck and face, with pneumo mediastinum involving retrosternal, pre and retro cardiac regions.. Respiratory rate was 70 per min and heart rate 170/min,pulse was thready and feeble. Blood pressure was 50/30 mm of Hg. IV line was secured and bolus of N/2 saline in 5% dextrose at 30ml/kg started. The infant was propped up on pillow and at the highest point of gaseous distension of the neck a scalp vein needle connected to the underwater seal drain was inserted as an emergency measure to relieve the gaseous tension. The air from the sub cutaneous space was continuously flowing through the drain. Blood samples were sent for ABG analysis, Haematocrit, complete blood picture, RFT, and peripheral smear study. The haematocrit value was 50%, Hb 12.3gm/dl, peripheral smear revealed polymorphonuclear leucocytosis, blood urea 141 mg/dl,creatinine3.3mg/dl, serum sodium 162mEq/L, Potassium4mEq/L. The infant was on continuous drain of the emphysema under water seal and the air bubbles were observed to escape for about18hrs, later the rate of air bubbles under water seal decreased. The infant was treated as a case of hypernatraemic dehydration with pre renal failure, and he responded to the treatment well. He was treated with ceftriaxone, cloxacillin and IV metronidazole and parenteral nutrition. Respiratory distress decreased. Possibility of barotrauma of esophagous was suspected and oesophagoscopy was undertaken and a small rent was seen on the right side of lower thoracic part of oesophagous. Nasogastric tube was passed and continuous aspiration of gastric content carried out. The infant was maintained on IV fluids and NG aspiration for five days from the time of admission, and was started on NG feeds of expressed breast milk on the 6th day. Infant accepted feeds well. By tenth day he recovered completely and repeat oesophagoscopy was carried out and no rent could be seen. He was started on small 5ml feeds. No respiratory distress was noticed. The quantity of feed was gradually increased to 15ml per feed with no evidence of respiratory distress noticed and was permitted to suckle on the breast on the 14th day. Barium swallow did not reveal any rent in the esophagus. He was reviewed in the well baby clinic and found to thrive well.

## DISCUSSION

Herman Boerhaave a Dutch physician first described the spontaneous rupture of esophagus in 1724 and it was found to occur after forceful emesis or after auto emesis practiced by using emetic drugs in the earlier days [1], and has to be distinguished from Mallory – Weiss syndrome associated with haematemesis with incomplete rupture or laceration of esophagus. In Boerhaave's syndrome the esophagus undergoes barotrauma when increased intra gastric pressure is transmitted against closed glottis.[1] The most commonest site of perforation is the postero lateral part of the distal esophagus[1,4]. In newborn infant the perforation is usually on the right, probably because the left side of esophagus is adjacent to Aorta [5]. In the present case the rent was found on the right side of the distal esophagus.

The diagnosis of Boerhaave's syndrome is often found to be

difficult because of symptoms can masquerade many conditions like gastric ulcer, perforation, pancreatitis, myocardial infarction and pneumo thorax [9]. The clinical presentation described in literature by Mackler's triad of symptoms of vomiting, chest pain, and sub cutaneous emphysema associated with clinical and radiological findings of pneumothorax and hydro pneumothorax [10]. It may be associated with cardiovascular collapse and shock which was observed in our case. It was very difficult to decide whether the peripheral circulatory failure and cyanosis was because of the acute gastroenteritis with severe dehydration or as resultant of Boerhaave's syndrome. Presence of complex symptoms is usual and reliance on "classical presentation" is misleading [5]. It may be associated with excruciating pain chest radiating to substernal area, epigastrium or back [10], and can be mistaken for Myocardial infarction. Walker et al and Mitchel et al in their reports suggested pain is a constant complaint [5,11]. Our patient presented to the hospital with acute gastro enteritis with severe dehydration and shock. So much so it could not be detected whether he had pain or not. Progressive swelling over the chest extending to neck and both sides of face has been seen 1 hour after the last bout of vomiting in the present case. The swelling on clinical examination revealed crepitus, as if treading on ice confirmed sub cutaneous emphysema and its presence varies from 28 to 66%[5,11].The infant had pneumo mediastinum with pre and retrocardiac emphysema with evidence crackling sounds on auscultation suggestive of "Hamman's crunch", initially mistaken for pericardial rub. This is found positive in 20% of cases reported [5,12]. Because of lack of specific signs, the diagnosis is either missed or delayed [12]. The incidence of diagnostic error could be as high as 50% [13].

## IMAGING STUDIES

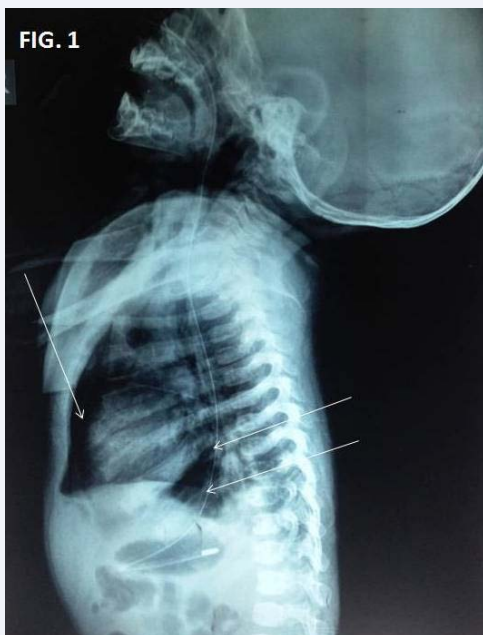Failure to obtain chest X-Ray when Boerhaave's syndrome presents as acute abdomen may result in missing the most common findings of subcutaneous emphysema, pneumo thorax, Pneumomediastinum and pleural effusion[10]. Once esophageal perforation is suspected radiological examination is the most valuable modality and simple erect film of the chest yields most of the information [14] as is in our case. Twelve % of the patients can have normal findings [15]. The most common findings like pleural effusion and pneumo thorax were reported in Boerhaave's syndrome whose incidence was reported to be 91 and 80% respectively [16,17]. Pneumo thorax is usually associated with pleural effusion unilateral or bilateral. Sub cutaneous emphysema is seen in 66% of patients [16]. Mediastinal air should be looked for in all cases as it is easily missed if it is retrocardiac [16]. Widening of mediastinum is seen and so called 'V' sign of Naclerio [18] is another subtle finding for diagnosis of Boerhaave's syndrome. In our patient radiological examination has presented with characteristic diagnostic features like subcutaneous emphysema in front of the chest extending in to the neck, sub mandibular region and both sides of the face, pneumo mediastinum with pre and retro cardiac presence of air demonstrating "V" sign of Naclerio. Minimal spillage was seen in seen in the right lower chest. Lateral view taken with naso gastric tube in situ demonstrated the retro cardiac air depicting 'V' sign of Naclerio (Figure 1,2). Esophagoscopy revealed rent in the distal thoracic esophagus on the right side which confirmed the diagnosis, Barium meal

follow through could not be carried out as the baby's condition was precarious though the contrast esophagoscopy's sensitivity was 70 to 75% [19]. Review of literature revealed X-Ray with gastrograffin may be false positive in 20% of cases [10,20] and Barium if it leaks might result in acute inflammatory reaction. The baby's condition was precarious and could not be subjected to the above investigations including CT scan. Though the diagnosis has become easy with advent of Computer Tomography studies. It is quoted in one of the studies that a convincing history, suggestive clinical findings, demonstration of peri esophageal air tracks and pneumo mediastinum ( by CT scan) are sufficient to diagnose Boerhaave's syndrome [12,16].

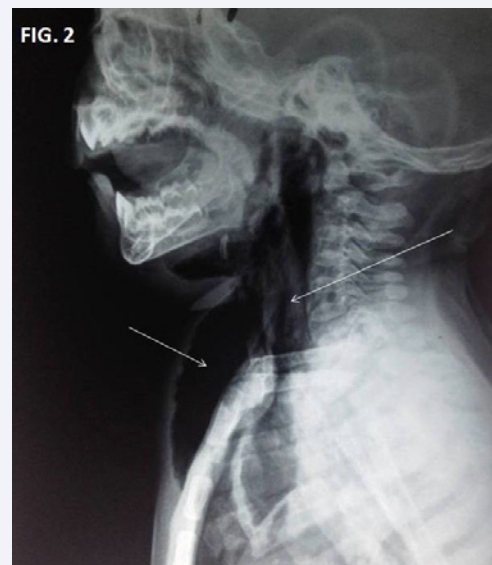### MORBIDITY AND MORTALITY

Boerhaave's syndrome remained a pathologic curiosity for long being a post-mortem diagnosis and the condition was always found to be fatal. Frink et al in 1940 has successfully drained the pleural space occupied by contaminated food particles. The first successful closure of the esophageal perforation was carried out by Barret in 1947 more than 200 years after the original description by Dr Herman Boerhaave in 1724 [21,22]. More than 300 cases were cited in literature worldwide by Kish et al in 1980 [3]. In 1986 Bladergroen et al described 127 cases of which 114 cases were diagnosed ante mortem [4]. Most of the series reported substantial mortality and morbidity [12]. Patient who underwent surgical treatment within 12hrs or more of appearance of symptoms is associated with 36% of reported mortality, while a delay of 24 hrs resulted in mortality rate of 64% [10].

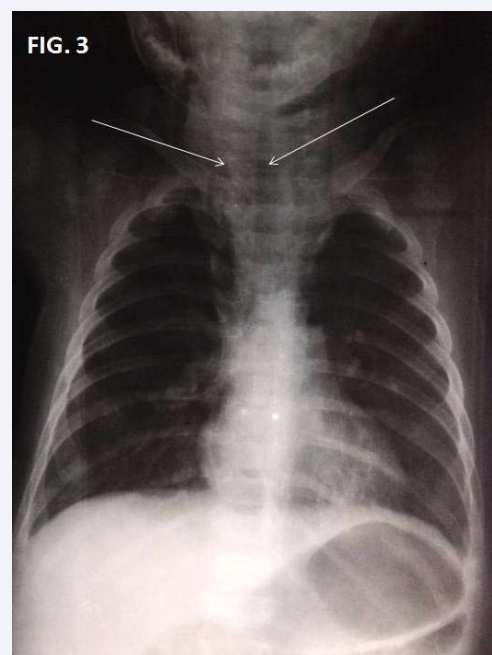
Boerhaave's syndrome is rare in children [6]. Till date only 28 cases were reported in literature. In a similar case as ours Antonio et al confirmed the rent in the esophagus and diagnosis can be established only by esophagoscopy [6,23].



**Figure 1** Shows Precardial and Retrocardial Emphysema ( Pneumo-Mediastinum) with 'V' sign of Naclerio.



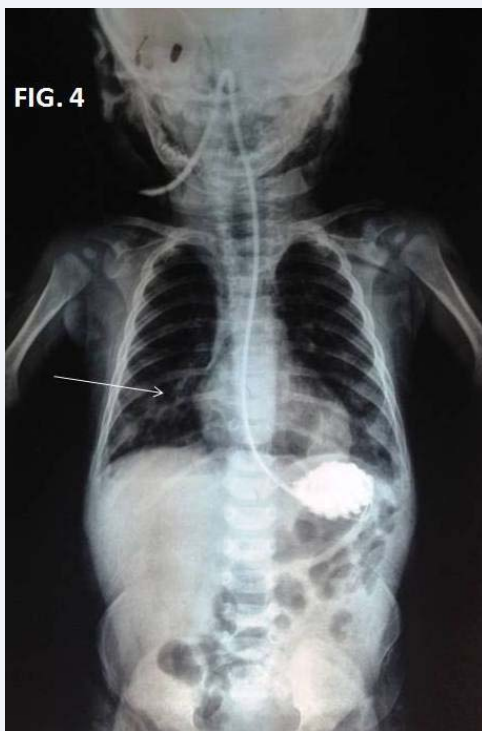**Figure 2** Shows Subcutaneous and Paratracheal Emphysema.



**Figure 3** Shows Tracheal and Paratracheal shadows.

### MANAGEMENT AND TREATMENT

Barret described the first successful surgical repair of the esophageal tear in 1947. Prior to it Boerhaave's syndrome had virtually 100% mortality [21]. De Schippe et al on a review of published literature recommended endoscopic treatment of Boerhaave's syndrome in certain cases [4]. The author has determined the survival rates of conservative, Surgical and endoscopic treatment for Boerhaave's syndrome as 75%, 81% and 100% respectively. They insisted once condition is diagnosed within 48hrs the patient should be treated by endoscopy. When the patient has reported after 48 hrs, surgical treatment was



**Figure 4** Shows Gastrografin study with right sided homogenous opacities suggestive of right side spillage.

preferred especially not complicated with sepsis. The patients selected for conservative treatment are those with small perforations [12]. contamination confined to mediastinum and late recognition ( more than 24hrs) of an esophageal perforation, as the surgical mortality at 24hrs becomes equals to that of conservative approach [10].The principles of conservative treatment consisted of a) Nil oral regimen) Continuous Naso gastric suction c)Pleural drainage, d)Broad spectrum antibiotic usage, e) Feeding enterostomy or total parental nutrition [10]. Our patient was too small and in a precarious state, and it took us 36 hrs to resuscitate him from acute renal failure, and shock. Contamination was minimal, and he was managed conservatively. In addition a continuous drainage of emphysema was carried out with under water seal drain which helped in reducing the respiratory embarrassment.

Lucendo et al reported that they came across only two published cases of esophageal perforations in children which were managed conservatively [7]. The youngest case reported earlier was 6 month old Hispanic boy who had Acute Lymphoblastic leukemia on chemotherapy and developed Boerhaave's syndrome and was managed surgically [8].Our patient was 4 month old who presented to us with acute gastroenteritis with severe hypernatraemic dehydration with peripheral circulatory failure and collapse with surgical emphysema involving the front of the chest extending on to the neck, submandibular region with pnemomediastinum. After 24 hrs the rent in the esophagus was confirmed by esophagoscopy. . The clinical and radiological findings were classical and confirmed the diagnosis of Boerhaave'S syndrome. He was successfully treated by conservative management and recovered uneventfully.

## CONCLUSIONS

The case report is that of a 4month old infant, the youngest patient to have diagnosed as a case of Boerhaave's syndrome in literature who has been managed conservatively. He is the 28 th case of boerhaave's syndrome reported till date in literature worldwide and third case managed conservatively. Early detection of the respiratory embarrassment due to surgical emphysema and pneumo thorax can be managed conservatively by use of underwater seal drainage.

## REFERENCES

1. Boerhaave H. Atrocis nee descripti prius morbi historica secundem medicine artis leges conscripta Lungd Bat Boutes-taeniana Leyeden1724 (English translation: Bull Med Library Assoc1955;43: 217.
2. Kish GF, Katske FA. A case of recurrent Boerhaave's syndrome. W V Med J. 1980; 76: 27-30.
3. Bladergroen MR, Lowe JE, Postlethwait RW. Diagnosis and recommended management of esophageal perforation and rupture. Ann Thorac Surg. 1986; 42: 235-239.
4. de Schipper JP, Pull ter Gunne AF, Oostvogel HJ, van Laarhoven CJ. Spontaneous rupture of the oesophagus: Boerhaave's syndrome in 2008. Literature review and treatment algorithm. Dig Surg. 2009; 26: 1-6.
5. Walker WS, Cameron EW, Walbaum PR. Diagnosis and management of spontaneous transmural rupture of the oesophagus (Boerhaave's syndrome). Br J Surg. 1985; 72: 204-207.
6. Antonis JH, Poeze M, Van Heurn LW. Boerhaave's syndrome in children: a case report and review of the literature. J Pediatr Surg. 2006; 41: 1620-1623.
7. Lucendo AJ, Frigal-Ruiz AB, Rodríguez B. Boerhaave's syndrome as the primary manifestation of adult eosinophilic esophagitis. Two case reports and a review of the literature. Dis Esophagus. 2011; 24: E11-15.
8. Ram Sooke C. Boerhaave's syndrome: A pediatric case. J Clin Gastroenterol. 2001; 33: 77-80.
9. Toelen C, Hendrickx L, Van Hee R. Laparoscopic treatment of Boerhaave's syndrome: a case report and review of the literature. Acta Chir Belg. 2007; 107: 402-404.
10. Janjua KJ. Boerhaave's syndrome. Postgrad Med J. 1997; 73: 265-270.
11. Michel L, Grillo HC, Malt RA. Operative and nonoperative management of esophageal perforations. Ann Surg. 1981; 194: 57-63.
12. Curci JJ, Horman MJ. Boerhaave's syndrome: The importance of early diagnosis and treatment. Ann Surg. 1976; 183: 401-408.
13. Keighley MR, Girdwood RW, Ionescu MI, Wooler GH. Spontaneous rupture of the oesophagus. Avoidance of postoperative morbidity. Br J Surg. 1972; 59: 649-652.
14. Phillips LG Jr, Cunningham J. Esophageal perforation. Radiol Clin North Am. 1984; 22: 607-613.
15. Han SY, McElvein RB, Aldrete JS, Tishler JM. Perforation of the esophagus: correlation of site and cause with plain film findings. AJR Am J Roentgenol. 1985; 145: 537-540.
16. Priviteri CA, Gay BB Jr. Spontaneous rupture of the esophagus, with report of five cases. Radiology. 1951; 57: 48-57.
17. Watts D. Complications of vomiting. The Boerhaave and the Mallory-Weiss syndromes. West J Med. 1974; 121: 50-54.

18. NACLERIO EA. The V sign in the diagnosis of spontaneous rupture of the esophagus (an early roentgen clue). *Am J Surg.* 1957; 93: 291-298.
19. Ghanem N, Altehoefer C, Springer O, Furtwangler A, Kotter E, Schaefer O, et al. Radiological findings in Boerhaave's syndrome. *Emerg Radiol.* 2003; 10: 8-13.
20. Roy PK, Othman MD. Boerhaave syndrome. 2006.
21. Barrett NR. Spontaneous perforation of the oesophagus; review of the literature and report of three new cases. *Thorax.* 1946; 1: 48-70.
22. Backer CL, LoCicero J 3rd, Hartz RS, Donaldson JS, Shields T. Computed tomography in patients with esophageal perforation. *Chest.* 1990; 98: 1078-1080.
23. Chikkappa MG, Morrison C, Lowe A, Gorman S, Antrum R, Gokhale J. Paediatric Boerhaave's syndrome: a case report and review of the literature. *Cases J.* 2009; 2: 8302.

#### Cite this article

Rao KS, Malla K, Singh A, Poudel S, Ganesh BK, et al. (2015) Boerhaave's Syndrome Unusual Presentation in a 4 Month Old Infant, a Case Report and Review of Literature. *Ann Pediatr Child Health* 3(2): 1053.