

## Case Report

# Familial Hemophagocytic Lymphohistiocytosis Type 5 Due To Novel STXBP2 Gene Mutation: A Case Report

Deepshikha\*, Prabhas Prasun Giri, Apurba Ghosh

Department of Pediatrics, Institute of child health, Kolkata, India

## \*Corresponding author

Deepshikha, Ladies Hostel, Institute of Child Health, 11, Dr. Bireswari Guha Street, Kolkata-700017, India, Tel: 89816-06919; Email Id: drdeepshikhamishra@gmail.com

Submitted: 29 June 2015

Accepted: 01 August 2015

Published: 03 August 2015

## Copyright

© 2015 Deepshikha et al.

## OPEN ACCESS

## Keywords

- Familial HLH
- Hemophagocytes
- Hepatosplenomegaly
- Cytopenia

## Abstract

Familial Hemophagocytic lymphohistiocytosis (FHL) is a fatal autosomal recessive hyperinflammatory syndrome characterized by fever, hepatosplenomegaly, cytopenia, hyperferritinemia and widespread hemophagocytosis in the reticuloendothelial tissues. Diagnosis of FHL can be confirmed by the presence of typical clinical and laboratory features along with presence of a specific genetic mutation. Mutation in STXBP2 encoding syntaxin binding protein 2 (Munc 18 -2) is the newest described mutation that gives rise to FHL5. Here we present a case of FHL 5 with typical clinical and laboratory features of FHL and came out to be positive for homozygous missense variation in exon 3 of the STXBP2 gene (chr19:7703978; G>T).

## ABBREVIATIONS

FHL: Familial Hemophagocytic Lymphohistiocytosis; FHL5: Familial Hemophagocytic Lymphohistiocytosis type 5; HLH: Hemophagocytic Lymphohistiocytosis; HSCT: Hematopoietic Stem Cell Transplant

## INTRODUCTION

Hemophagocytic lymphohistiocytosis (HLH) is a life threatening clinical syndrome that occurs as a consequence of a severe, uncontrolled hyperinflammatory reaction, which can be either primary (genetic) or secondary (acquired). Secondary HLH may follow infections, autoimmune diseases (macrophage activation syndrome) or lymphoproliferative disorders, while primary HLH may be familial (FHL) or associated with primary immunodeficiency such as Chédiak-Higashi syndrome, Griscelli syndrome, Hermanski-Pudlak syndrome type 2 or X-linked lymphoproliferative syndrome [1]. Familial HLH can present at any age, and may follow an infectious trigger, like secondary HLH [2,3]. Five types of FHL with 4 known genetic defect have been identified, caused by mutation in various genes that result in impaired functioning of Natural Killer cells and cytotoxic T lymphocytes [4]. Common genetic mutations associated with FHL are mutations in gene PRF-1 (FHL2), UNC13D (FHL3), STX11 (FHL4) and STXBP2 (FHL5). Among them, FHL5 is the rarest variety, caused by mutation in the gene for Syntaxin binding protein 2 (STXBP2) or UNC18B gene. Our patient, a 1month old male baby presented with characteristic clinical and laboratory

features of HLH and was found to be positive for the novel STXBP2 gene mutation.

## CASE PRESENTATION

A 1 month 10 day old, male baby, born of a non-consanguineous marriage, in a Hindu, Indian family, had an uneventful neonatal period and 1<sup>st</sup> month of life. He developed fever with loose stools at the age of 1 month 10 days and was admitted in a hospital the next day as he refused to feed and became lethargic. There, he was diagnosed as sepsis, and started on IV antibiotics. Even after 5 days of antibiotics, the baby's condition kept deteriorating, so, he was referred to us. On admission, the baby was febrile, with a toxic look, had hepatosplenomegaly, and a distended abdomen. Routine blood tests revealed a total WBC count of 7,700/mm<sup>3</sup> (20% neutrophils, 77% lymphocytes), haemoglobin 7.9 g/dl and platelet count 80,000/mm<sup>3</sup>. CRP was 34 mg/L (normal<6) and ESR 14mm/1<sup>st</sup> hour. Chest X Ray findings were within normal limits. Urine microscopy was normal, including no viral inclusion bodies or fungal components, and culture was negative. Stool microscopy showed 10-15 pus cells, and few RBC. The baby was started on broad spectrum combination antibiotics along with other supportive measures, and HLH panel of investigations were sent with a strong clinical suspicion. Reports showed serum ferritin level of 18,960 ng/ml, LDH 590 U/L, Triglycerides 634 mg/dl and Fibrinogen 0.9 g/L. Bone marrow aspiration was done and IV Dexamethasone (10 mg/m<sup>2</sup>/day) and Intravenous Immunoglobulin (2gram/kg) was started. The baby improved clinically in the next 2 days, was able to breast feed. CSF study

showed 20 cells, all lymphocytes, normal sugar and protein, and no growth in culture. Bone marrow cytology revealed dyserythropoiesis with presence of Hemophagocytes. Serological testing for Cytomegalovirus, Herpes Simplex virus, Rubella and Toxoplasma were done to rule out congenital infection, and were reported negative. Epstein Barr virus serology was also negative. We continued treatment with dexamethasone. Ferritin level came down to 3,360 ng/ml after 4 days. But the baby again became lethargic, developed abdominal distension with few petechial spots, and continuation of the loose, mucoid stools. Blood counts were similar but ferritin level increased to 16000 ng/ml. Oral Cyclosporin A was started as the patient was not responding to steroid alone. Patient's condition still deteriorated. Multiple petechial spots developed all over the body with further cytopenia. Blood component transfusions were given. A single dose of Etoposide (150mg/m<sup>2</sup>) was given. Despite all of our efforts, the baby suffered from pulmonary haemorrhage, went into refractory shock, and succumbed to death.

Since there was a high possibility of this HLH to be primary, and immunodeficiency disorders were ruled out as the baby had normal coloured hair, and no oculocutaneous albinism, our provisional diagnosis was Familial HLH triggered by an unknown infection. Blood samples of the baby were sent for genetic mutation analysis for FHL. An unreported homozygous missense variation in exon 3 of the *STXBP2* gene (**chr19:7703978; G>T**) that results in the amino acid substitution of Valine for Glycine at codon 54 was detected by targeted sequencing analysis, which is responsible for FHL5. Both the parents were then tested, and found to be heterozygous for the same mutation (Figure 1,2). Functional assays for natural killer (NK) cell activity could not be performed for the long shipping time. The parents were called up again and genetic counselling was done. They were advised to go for a prenatal diagnosis by a Chorionic villous sampling and mutation analysis in the next pregnancy.

## DISCUSSION

HLH is not actually a disease, but a clinical syndrome characterized by hyperinflammation. In infants and very young children, HLH is predominantly due to immune defects caused by mutation in genes responsible for cytotoxic function of NK cells and cytotoxic T lymphocytes, and known as Familial Hemophagocytic Lymphohistiocytosis (FHL) which has an overall incidence of 1/50000 live births [5]. The usual presentation is an infant with fever, cytopenias, and hepatosplenomegaly, not responding to conventional treatment of sepsis. The clinical and laboratory criteria for diagnosis of HLH are useful in the initial stages. Five out of eight of these should be present for a positive diagnosis: fever, splenomegaly, cytopenia, hypertriglyceridemia or hypofibrinogenemia, hyperferritinemia, increased soluble CD25, absent NK cell function and demonstration of Hemophagocytes [6]. But the detection of a known gene mutation causing FHL is confirmatory in itself, although it takes time. The index case showed presence of five out of eight criteria, and also had a homozygous gene mutation in *STXBP2*, so we reached to the diagnosis of FHL5.

*TXBP2* encodes for Syntaxin-binding protein-2 or Munc18-2 protein, involved in the regulation of vesicle transport to the plasma membrane. Syntaxin 11, the FHL-4 related protein, is

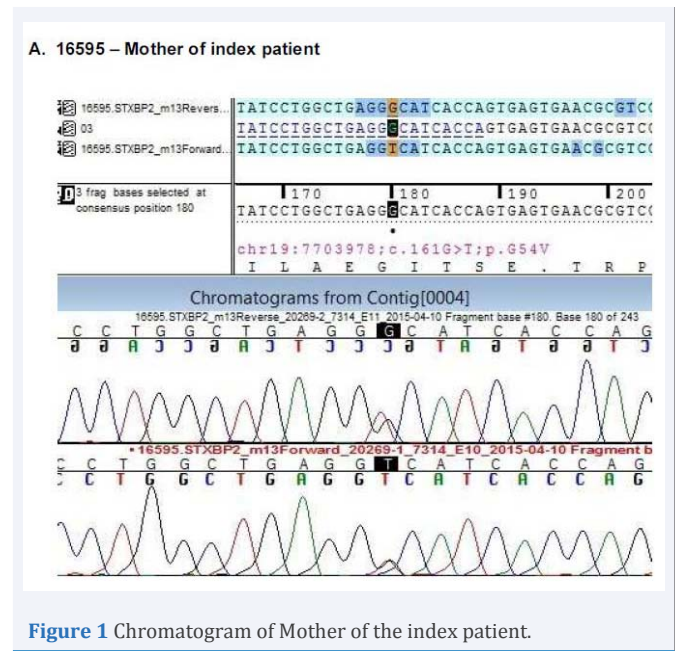


Figure 1 Chromatogram of Mother of the index patient.

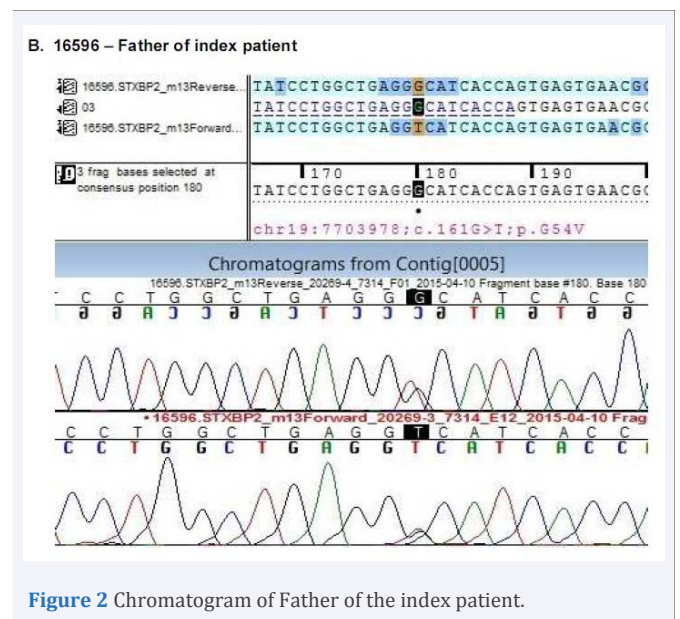


Figure 2 Chromatogram of Father of the index patient.

an interaction partner of *STXBP2*. It is required at a late step of the secretory pathway for the release of cytotoxic granules by binding to Syntaxin 11. This interaction is eliminated by the missense mutations found in patients with FHL-5, which leads to decreased stability of both proteins [4].

Zur Stadt *et al.* reported nine different mutations in the *STXBP2* gene in 12 patients from Turkey, Saudi Arabia, and Central Europe. Patients homozygous for missense mutations or a 3-bp deletion had early-onset disease, diagnosed before 1 year of age [7]. Cetica, *et al.* reported four patients with *STXBP2* mutations, from Italy, England, Kuwait and Pakistan [8]. Meeths, *et al.* reported 11 patients from Pakistan, Denmark, Netherlands, Norway and Russia and found that *STXBP2* mutation is associated with a spectrum of atypical clinical symptoms other than those typically associated with HLH (colitis and chronic diarrhoea,

sensorineural hearing loss, bleeding outside acute HLH episodes and hypogammaglobulinemia) [9]. Our proband had diarrhoea that started with the disease onset and continued till the last day of his life. The first reported case of FHL5 from India was by Jain et al from CMC Vellore in 2011 [10]. Our patient had a novel mutation for STXBP2 gene and parents were heterozygous for that mutation.

Like other FHL, FHL 5 also carries a very poor prognosis and survival is impossible without Hematopoietic Stem Cell Transplantation (HSCT). Patients are to be brought in remission with combined Chemotherapy (HLH 2004 protocol) and then proceed for HSCT as soon as possible [6]. Early genetic testing is helpful in confirming FHL for early transplant, in testing of at risk relatives, carrier testing, genetic counselling and prenatal testing for future at risk pregnancies.

## ACKNOWLEDGEMENT

We thank the scientists at Medgenome Labs Pvt LTd who contributed by performing the genetic analysis.

## REFERENCES

1. Janka GE. Familial and acquired hemophagocytic lymphohistiocytosis. *Annu Rev Med.* 2012; 63: 233-246.
2. Rohr J, Beutel K, Maul-Pavicic A, Vraetz T, Thiel J, Warnatz K. Atypical familial hemophagocytic lymphohistiocytosis due to mutations in UNC13D and STXBP2 overlaps with primary immunodeficiency diseases. *Haematologica.* 2010; 95: 2080-2087.
3. Zhang K, Jordan MB, Marsh RA, Johnson JA, Kissell D, Meller J. Hypomorphic mutations in PRF, MUNC13-4, and STXBP2 are associated with adult-onset familial HLH. *Blood.* 2011; 118: 5794-5798.
4. Cetica V, Pende D, Griffiths GM, Aricò M. Molecular basis of familial hemophagocytic lymphohistiocytosis. *Haematologica.* 2010; 95: 538-541.
5. Henter JI, Aricò M, Elinder G, Imashuku S, Janka G. Familial hemophagocytic lymphohistiocytosis. Primary hemophagocytic lymphohistiocytosis. *Hematol Oncol Clin North Am.* 1998; 12: 417-433.
6. Henter JI, Horne A, Aricò M, Egeler RM, Filipovich AH, Imashuku S. HLH-2004: Diagnostic and therapeutic guidelines for hemophagocytic lymphohistiocytosis. *Pediatr Blood Cancer.* 2007; 48: 124-131.
7. zur Stadt U, Rohr J, Seifert W, Koch F, Grieve S, Pagel J. Familial hemophagocytic lymphohistiocytosis type 5 (FHL-5) is caused by mutations in Munc18-2 and impaired binding to syntaxin 11. *Am J Hum Genet.* 2009; 85: 482-492.
8. Cetica V, Santoro A, Gilmour KC, Sieni E, Beutel K, Pende D. STXBP2 mutations in children with familial haemophagocytic lymphohistiocytosis type 5. *J Med Genet.* 2010; 47: 595-600.
9. Meeths M, Entesarian M, Al-Herz W, Chiang SC, Wood SM, Al-Ateeqi W. Spectrum of clinical presentations in familial hemophagocytic lymphohistiocytosis type 5 patients with mutations in STXBP2. *Blood.* 2010; 116: 2635-2643.
10. Rakhi Jain, Mammen Puliyeel, Prabhakar D Moses, Elena Sieni. Novel STXBP2 Mutation Causing Familial Hemophagocytic Lymphohistiocytosis. *Indian Pediatr.* 2012; 49: 488-490.

### Cite this article

Deepshikha, Giri PP, Ghosh A (2015) Familial Hemophagocytic Lymphohistiocytosis Type 5 Due To Novel STXBP2 Gene Mutation: A Case Report. *Ann Pediatr Child Health* 3(6): 1073.