

## Case Series

# Primary Solitary and Multiple Intracranial Cyst Hydatid Disease: Report of Four Cases

Solmaz Celebi<sup>1\*</sup>, Sefika Elmas Bozdemir<sup>1</sup>, Mustafa Hacimustafaoglu<sup>1</sup>, and Ozgur Taskapilioglu<sup>2</sup>

<sup>1</sup>Department of Pediatrics, Division of Pediatric Infectious Diseases, Uludag University, Turkey

<sup>2</sup>Department of Neurosurgery, Uludag University, Turkey

**\*Corresponding author**

Solmaz Celebi, Department of Pediatrics, Uludag University, Division of Pediatric Infectious Diseases, Gorukle, Bursa, Turkey, 16059, Turkey, Tel: 90-224-2950425; Fax: 90-224-4428749; Email: solmaz@uludag.edu.tr

Submitted: 10 June 2016

Accepted: 06 July 2016

Published: 12 July 2016

**Copyright**

© 2016 Celebi et al.

**OPEN ACCESS****Keywords**

- Echinococcosis
- Hydatidcyst
- Intracranial
- Children

**Abstract**

Intracranial hydatid disease is rare, with reported incidence of 1-2% of all cases with hydatid disease and most of these cases present in childhood. In this report, we describe four children with primary hydatid disease of the brain. All four patients were diagnosed with cranial Magnetic Resonance Imaging and in direct hemagglutination test for *Echinococcus granulosus*. Of these four children, three had cysts in cerebral localization and one in cerebellar localization. Two children had multiple and one of them had recurrent cerebral hydatid disease. All patients received albendazole treatment. While three patients did well after surgical excision, a ventriculo peritoneal shunt was placed in one. Also, this child was operated for duramater defect. This report shows that primary hydatid disease of brain is still a difficult problem despite all advances in diagnostic methods and surgical techniques.

**ABBREVIATIONS**

MRI: Magnetic Resonance Imaging

**INTRODUCTION**

Hydatid disease is caused by *Echinococcus granulosus* during the larval stage of the tape worms. The incidence of intracranial hydatid disease is 1-2% of all cases with hydatid disease in all ages. However 50-75% of cases involving the central nervous system occurs in the pediatric age group [1]. Cerebral hydatid cysts are usually solitary and may be uni locular or multi locular. Multiple cerebral cysts are rare and usually occur as a result of surgical or traumatic rupture, but spontaneous rupture is also possible [2,3]. Multiple cysts resulting from the rupture of a primary cyst are acepholeceles, they are in fertile and have no broad capsule. However, very rarely a multiple larval intake may cause primary multiple cerebral hydatid cysts [3,4]. Hydatid cysts may not cause focal neurological signs until they are very large. Secondary to mass effect, the first clinical sign is usually intra cranial hypertension [5].

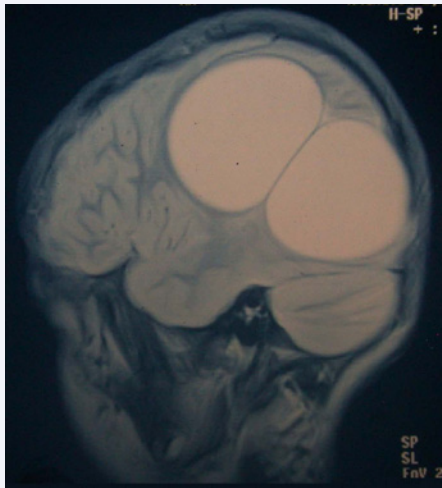In this report, we describe four children with primary intracranial hydatid cysts drawing attention to rare and different features of intracranial hydatid disease. The clinical symptoms, medical treatment and surgical interventions of these four children were discussed with in the literature.

**CASE PRESENTATION****Case 1**

A 7-year-old boy was admitted to our emergency department with strabismus, headache and vomiting lasting for 3 months. On physical examination esotropia of both eyes and papiledema were detected. The examination of chest radiograph, complete blood count, urine analysis, and blood biochemistry revealed no abnormality. Cranial MRI revealed a large multiloculated intracranial hydatid cyst with dimensions of 5.5 x 5.5 x 5 cm in left parieto-occipital region (Figure 1). Investigations for other organ involvement (abdominal ultra sonography, chest radiography and echocardiography) were performed but no other focus was found. Indirect hemagglutination test for *E. granulosus* was positive with 1/ 256 titer. Albendazole treatment of 10 mg/kg twice daily was started. Upon surgical exploration, the cyst was totally extracted without rupture. Histo pathologic examination of the specimen revealed a hydatid cyst with protoscolecocytes. Albendazole treatment continued for 6 months till indirect hemagglutination test for *E. granulosus* become 1/32 in titer. Three years after surgery, he remained well and free of disease.

**Case 2**

A 14-year-old boy was admitted to our emergency department in a state of deep stupor. He was suffering from headache, malaise



**Figure 1** T1-weighted image of a multi lobulated hydatid cyst in the left frontotemporal region.

and intellectual deterioration lasting for 15 days. The day before hospitalization he had three seizures lasting for about 5 minutes each. He had a history of surgical intervention for an intracranial hydatid cyst two years ago. Albendazole treatment was not given after first operation. On physical examination there was an operation scar on the left frontotemporoparietal area. He could hardly be awakened, without cooperation and orientation. He had bilateral papilledema. The examination of complete blood count, urine analysis, and chest radiograph and blood biochemistry revealed no abnormality. Indirect hemagglutination test for *E. granulosus* was positive with 1/64 titer. Cranial CT imaging demonstrated multiple cystic lesions the biggest of which was 6 x 7 x 7 cm in diameter in the left frontotemporoparietal region (Figure 2). Albendazole treatment of 10 mg/kg twice daily was started. Extensive screening for another cyst elsewhere in the body revealed negative results. Chest radiography, echocardiography and abdominal ultra sonography were all normal. A left frontotemporoparietal craniotomy and total excision of six cysts without rupture was done. Histopathologic examination confirmed the surgical specimens were hydatid cysts with scoleces. The postoperative course was uneventful, and the patient showed marked recovery in his neurological status. Postoperative CT confirmed complete excision of the cysts. He got albendazole treatment for three months after operation. Two years after surgery, he remained well and free of disease.

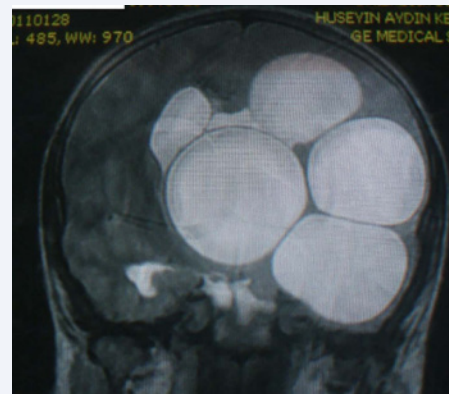
### Case 3

A 15-year-old boy presented to our pediatric outpatient clinic with the history of headache and vomiting of two days duration. He was complaining from headache for a year with augmentation on the last 2 months. On neurological examination he had right temporal hemianopsia and right hemiparesis. Chest radiograph, complete blood count, urine analysis, and blood biochemistry were all normal. Cranial MRI demonstrated multiple cystic lesion of 8x9x9cm on the right parieto-occipital region which extended to the convexity causing shift effect on midline structures (Figure 3). Indirect hemagglutination test for *E. granulosus* was positive with 1/2048 titer. Investigations for other organ

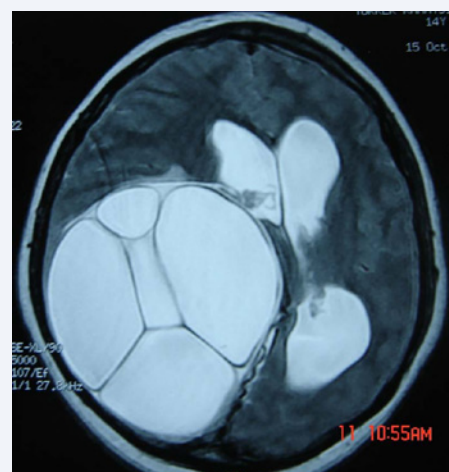
involvement (abdominal ultrasonography, chest radiography and echocardiography) were performed and no other focus was found. Albendazole treatment of 10 mg/kg twice daily was started. Upon surgical intervention 10 cysts were extirpated without rupture. An external ventricular drainage catheter was placed on the second day after operation and a ventriculo peritoneal shunt was placed on the fifteenth day. Histopathologic examination confirmed the surgical specimens were hydatid cysts with scoleces. Albendazole treatment was given in a dosage of 10 mg/kg twice daily for 6 months. He was hospitalized two times for meningitis in the following year. Further diagnostic evaluations revealed defect in front oba sale part of dura mater and he went under surgical repairment. In the two-year follow-up period, no neurological deficits or sequel observed and follow-up radiological exams showed no evidence of hydatid disease.

### Case 4

A 7-year-old boy was admitted to our pediatric emergency department with headache, intermittent vomiting and gait disturbances lasting for 3 weeks. Neurologic examination revealed bilateral papiledema, positive cerebellar signs on the left and cerebellar ataxia. The examination of chest radiograph,



**Figure 2** Cranial CT image of multiple hydatid cysts in frontotemporoparietal region.



**Figure 3** T2-weighted image of multiple hydatid cysts in right parieto-occipital region.

complete blood count, urine analysis, and blood biochemistry revealed no abnormality. Cranial MRI revealed a midline cerebellar cystic lesion of 4 x 4 cm, which was hypointense on T1-weighted images and hyper intense on T2-weighted images without contrast enhancement (Figure 4). The lesion was compressing the fourth ventricle causing dilation of the third and lateral ventricles. Laboratory studies including complete blood count, urine analysis and blood biochemistry revealed no abnormality. Extensive examination including chest radiography, echocardiography and abdominal ultrasonography for another hydatid cyts were all normal. Indirect hemagglutination test for *E. granulosus* was positive with 1/256 titer. Albendazole treatment of 10 mg/kg twice daily was started. Although the cyst capsule was ruptured during operation, total removal was achieved. Postoperative MRI confirmed complete excision of the cyst. He has been on albendazole medication for 3 months after operation. Three years after surgery, he remained well and free of disease.

## DISCUSSION

In hydatid disease, the only pathogenic species for humans are *E. granulosus*. Humans become infected by ingesting tapeworm eggs passed from an infected carnivore; especially dogs; which most frequently happens when individual handle or have a contact with infected carnivores or inadvertently ingest food or drink which is contaminated with fecal material containing tapeworm eggs [6]. The history of direct contact with dogs was found in patients 2 and 4. However, because Turkey is an endemic region, all the children in our series may have been infected by eating ingested food. Intracranial hydatid disease is considered a childhood disease. Fifty percent to 75 percent of intracranial hydatid cysts are seen in children. Izci et al. [7], reported a series of 17 patients with intracranial hydatid cysts and 13 (65%) of these patients were children. Cerebral hydatid cysts are often supratentorially localized in the distribution of the terminal branches of the middle cerebral artery, usually temporo-parieto-occipitally [8]. In our series, three patients had cysts in the distribution of middle cerebral artery; one in left parieto-occipital region, one in right parieto-occipital region and one in left fronto-temporo-parietal region.

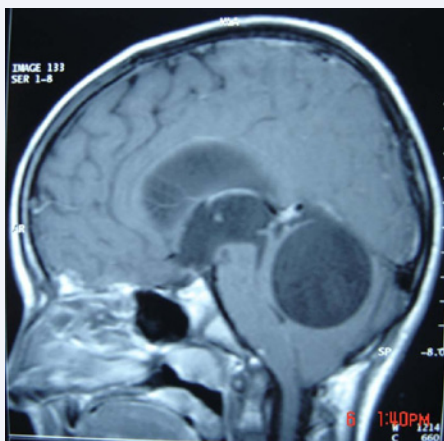


Figure 4 T1-weighted image of the cerebellar hydatid cyst.

Intracranial hydatid cysts may also be classified as primary or secondary. The primary cysts are formed as a result of direct infestation of the larvae in the brain without demonstrable involvement of other organs. In primary multiple cysts, each cyst has a separate pericyst with brood capsule protoscoleces and these originate from multiple larvae affecting brain after crossing the gastrointestinal tract, liver, lungs and right side of heart without affecting them. The primary cysts are fertile as they contain protoscoleces and brood capsules, hence rupture of primary cyst can result in recurrence. The secondary multiple cysts results from spontaneous, traumatic or surgical rupture of the primary intracranial hydatid cyst and they lack brood capsule and protoscoleces. The secondary intracranial hydatid cysts are therefore, infertile and the resultant risk of recurrence after their rupture is negligible. Primary multiple cysts are uncommon and isolated case reports of primary multiple hydatid cysts have appeared in the literature [1,9]. Lunardi et al. [10], found 2 cases in their series of 12 cases. In our series, two patients had multiple intracranial hydatid cysts. One of these patients had 10 primary cysts in right parietooccipital region. The other child had a history of operation for a solitary intracranial hydatid cyst without rupture two years before being operated in our pediatric neurosurgery department. In the second operation 6 hydatid cysts, the biggest of which was 6 x 7 x 7 cm in diameter were removed from the left frontotemporoparietal region. Because the histopathological evaluation of these cysts removed in the second operation revealed protoscoleces, and the surgical data of the first operation did not mention about rupture, we consider this patient has experienced recurrent intracranial hydatid disease due to multiple tape worm eggs intake.

The patients with intracranial hydatid cysts usually present with focal neurological deficit and features of raised intracranial pressure; the latter may be due to the large size or due to interference with pathway of cerebrospinal fluid flow. In our series, all four patients had symptoms and signs of increased intracranial pressure. All our patients are suffered from headache and vomiting. Three patients had bilateral papiledema, one of them had seizures. One patient had right temporal hemianopsia and right hemiparesis.

Radiological evaluations of hydatid cysts by cranial CT scan and MR images reveal solitary, homogeneous, spherical and large parenchymal cysts with well-defined borders, without perifocal edema and environmental contrast enhancement. The density of the cyst fluid is the same as that of cerebrospinal fluid [3]. In our cases, three patients were evaluated with cranial MRI and one patient with cranial CT before operation. Both techniques were helpful in the diagnosis.

The treatment of hydatid cyst is surgical and the aim of surgery is to excise the cyst in total without rupture to prevent recurrence and anaphylactic reaction. Only a few reports are available mentioning the efficacy of drug therapy alone. Isolated case reports showed complete disappearance of multiple intracranial hydatid cysts with Albendazole therapy in a daily dose of 10 mg/kg, taken three times a day for four months [11]. Preoperative and postoperative albendazole treatment may be considered to sterilize the cyst, decrease the chance of anaphylaxis, decrease the tension in the cyst wall (thus reducing the spillage during surgery), and reduce the recurrence rate [11]. In our cases, all

patients were operated and total surgical removal was possible. Albendazole treatment was started to all our patients before the operation and continued for at least 3 months after operation. The cyst capsule was ruptured in one patient.

In conclusion, infection with *E. granulosus* should be included in the differential diagnosis for unspecific neurologic symptoms such as progressive headache, especially in pediatric patients where hydatid disease is endemic. The most important issue in cases with intracranial hydatid cysts is whether hydatidosis will develop in the primary sites. These patients should be followed, paying close attention to this possibility.

## REFERENCES

1. Yaka U, Aras Y, Aydoseli A, Akcakaya MO, Sencer A, Imer M, et al. Primary Multiple Cerebral Hydatid Disease: Still Symptomatic Despite Pathologically Confirmed Death of the Cyst. *Turkish Neurosurg*. 2013; 23: 505-508.
2. Sahin-Akyar G. Computed tomography and magnetic resonance imaging findings in cerebral hydatid disease. *Radiography*. 2002; 8: 251-258.
3. Topal U, Parlak M, Kılıc E, Sivri Z, Sadikoglu MY, Tuncel E. CT and MRI findings in cerebral hydatid disease. *Eur Radiol*. 1995; 5: 244-247.
4. Baysefer A, Erdoğan E, Gönül E, Kayali H, Timurkaynak E, Seber N. Primary multiple hydatid cysts: Case report with CT and MRI study. *Minim Invasive Neurosurg*. 1998; 41: 35-37.
5. Sierra J, Oviedo J, Berthier M, Leiguardo R. Growth rate of secondary hydatid cysts of the brain. Case report. *J Neurosurg*. 1985; 62: 781-782.
6. Turgut M. Intracranial hydatidosis in Turkey: its clinical presentation, diagnostic studies, surgical management and outcome. A review of 276 cases. *Neurosurg Rev*. 2001; 24: 200-208.
7. Izci Y, Tüzün Y, Seçer HI, Gönül E. Cerebral hydatid cysts: technique and pit falls of surgical management. *Neurosurg Focus*. 2008; 24: E15.
8. Ciurea AV, Fountas KN, Coman TC, Machinis TG, Kapsalaki EZ, Fezouludis NI, et al. Long-term surgical outcome in patients with intracranial hydatid cyst. *Acta Neurochir (Wien)*. 2006; 148: 421-426.
9. Senapati SB, Parida DK, Pattajoshi AS, Gouda AK, Patnaik A. Primary hydatid cyst of brain: Two cases report. *Asian J Neurosurg*. 2015; 10: 175-176.
10. Lunardi P, Missori P, Di-Lorenzo N, Fortuna A. Cerebral hydatidosis in childhood: a retrospective survey with emphasis on long term follows up. *J Neurosurg*. 1991; 29: 517-518.
11. Altas M, Aras M, Serarslan Y, Davran R, Evirgen O, Yilmaz N. A medically treated multiple cerebral hydatid cyst disease. *J Neurosurg Sci*. 2010; 54: 79-82.

### Cite this article

Celebi S, Bozdemir SE, Hacimustafaoglu M, Taskapilioglu O (2016) Primary Solitary and Multiple Intracranial Cyst Hydatid Disease: Report of Four Cases. *Ann Pediatr Child Health* 4(3): 1105.