

Case Report

Post Tuberculous Kyphosis

Oheneba Boachie-Adjei*, Rufai M. Mahmud, and Kwadwo Yankey

FOCOS Orthopaedic Hospital, Ghana

*Corresponding author

Oheneba Boachie-Adjei, FOCOS Orthopaedic Hospital, Pantang-Accra, Ghana, Tel: 233 243 383 051; E-mail:

boachiecalendar@gmail.com

Submitted: 16 February 2017

Accepted: 12 July 2017

Published: 13 July 2017

ISSN: 2373-9312

Copyright

© 2017 Boachie-Adjei et al.

OPEN ACCESS

Keywords

- Post TB Kyphosis
- Halo gravity traction
- Vertebral column resection
- Spinal fusion

Abstract

Introduction: Tuberculosis of the spine and its sequelae constitute a major burden on healthcare systems in the developing world and requires meticulous attention to detail, the appropriate surgical skill and good perioperative support systems to optimize surgical outcomes

Objectives: To highlight the peculiar challenges associated with managing complex spine deformities arising from post TB infection in the developing world.

Methodology: A comprehensive review of three pediatric patients with severe post TB kyphosis treated with Posterior vertebral column resection (VCR), fusion and instrumentation. Posterior VCR involves complete resection of a vertebra undertaken from a posterior approach. In the thoracic spine it involves a costo transversectomy, careful dissection of lateral and anterior margins of vertebral body, resection of body of vertebra while providing support for the spinal cord with rods placed across it in pedicle screws. This is followed by laminectomy. The opposing cartilaginous endplates of the vertebral bodies above and below resected vertebra is excised. A structural graft is then placed anterior to the spinal cord. A description of the presentation and treatment protocol was outlined.

Results: The kyphotic deformities were first subjected to Halo gravity traction in an attempt to decrease the deformity while improving the nutritional status in one severely malnourished patient. A post-operative infection occurred in one patient requiring revision surgery. A second patient had persistent psoas abscess which required a second operation with anterior drainage, debridement and fusion. All three patients have had excellent recovery with fusion two years post op.

Conclusion: Post TB kyphosis is a common sequela of Tuberculosis of the spine which can lead to paralysis. Surgical intervention requires a complex resection and fusion which can be successfully achieved in the properly selected patient.

ABBREVIATIONS

BMI: Body Mass Index; MRI: Magnetic Resonance Imaging; VCR: Vertebral Column Resection; ESR: Erythrocyte Sedimentation Rate; FVC: Forced Vital Capacity; MEP: Motor Evoked Potentials; TB: Tuberculosis; PSF: Posterior Spinal Fusion; PJK: Proximal Junctional Kyphosis

INTRODUCTION

Over 30 million people worldwide suffer from overt tuberculosis and more than two million have the spinal involvement. About 90% of cases occur in the developing world with sub-Saharan Africa accounting for a large portion of the disease burden [1]. There is also an increasing number of cases due to malnutrition and the resurgence of HIV infections [2].

The goals of management of spinal TB are to eradicate the infection, to prevent or relieve neural compression, to prevent, or correct spinal deformities, and to achieve unrestricted mobilization and normalization of patients' daily activities [3]. The advent of anti-tuberculosis medication has helped to great success in treating the tuberculosis infections and attention has

now turned to the management of the residual or progressive spinal deformity.

Aside being the main cause of kyphosis in the developing world, spinal tuberculosis is the most common cause of paralysis apart from trauma, and about 15% of patients treated conservatively develop kyphotic deformities [4-6]. Severe kyphosis is a major cosmetic and psychological disturbance in a growing child and can result in secondary cardio-respiratory problems and late-onset paraplegia [5]. Correction of an established deformity is both difficult and hazardous with a high rate of complications, even in experienced hands.⁷ Prevention of deformity must therefore be a priority in the treatment of spinal tuberculosis [3].

We present three (3) case examples and describe their clinical presentation, preoperative treatment regimen, surgical correction and postoperative outcomes.

CASE PRESENTATION 1

SD is a nineteen year old Sierra Leonean male, weighing 35kg with a BMI of 19kg/m² who presented with 11 year history of painful progressive back deformity. He had no weakness or

numbness in the limbs and no intermittent claudication. He had good bladder and bowel function. There was also no history of cough or contact with a chronic cough patient. He had no difficulty in breathing. He has had 8 months course of anti-tuberculosis medication during the course of the illness. On examination he had a significant mid thoracic gibbus (Figure 1A) (Sharp angular kyphosis), which was non tender to palpation and the deformity was rigid on supine hyperextension maneuver. He had a normal gross motor and sensory exam in all the limbs.

Standing Antero-posterior and Lateral full length radiographs showed a rigid 170 degree thoracic kyphosis. (Figure 1B, C). MRI scan showed the typical post infection destructive changes of the apical 4 vertebral with thinning of the spinal cord at the apex of the gibbus deformity. Pulmonary function tests were within normal limits.

Surgery consisted of decompressive laminectomy of the apex, posterior spinal Fusion (PSF) of T5-L3 and posterior vertebral column resection (VCR) of T9-T11, with segmental instrumentation. A titanium mesh sheet was placed over the exposed neural elements to protect the cord during wound closure. There were no neuro-monitoring changes throughout the procedure. He had an uneventful post-operative course until post op day 11, when he was noticed to have proximal junctional kyphosis. Consequently, he had a revision surgery with proximal extension of the spinal fusion to T2. His neurological status post op was normal. One month after surgery, he was noticed to have a non-tender fluctuant swelling over the wound with hyperemia, with no associated fever, chills or vomiting. He had normal white

cell count and an elevated ESR of 66mm/HR. Due to the persistent fluid collection an incision and drainage procedure was done and the resulting aspirate was culture negative. His wounds healed well thereafter.

At discharge he was neurologically intact with x-rays showing intact instrumentation (Figure 1E-F). He was fully functional at 2 years post-operation. His incision had healed (Figure 1G, 1H) and had no focal neurological deficit with the exception of hyper-reflexia in both quadriceps and a few beats of clonus on the left. He had intact sensation. Radiograph shows a localized thoracic kyphosis T8-L2 of 76 degrees, a global kyphosis (T2-T12) of 78 degrees and lordosis 62 degree. The instrumentation was intact and the fusion mass was consolidating well on the oblique x-rays. The response from the Scoliosis Research Society Outcomes Questionnaire (SRS-22) showed satisfactory scores in function, pain, self-esteem and satisfaction domains with a mean score of 3.18. Patient has done well in terms of overall functional activities. He has gone back to school. He has no bowel nor bladder problems..

CASE PRESENTATION 2

16 year old male with a BMI of 18.9kg/m² who presented with a progressive back deformity. On assessment, he was neurologically intact and pulmonary function test showed an FVC of 66%. Lateral radiographs show a localized kyphosis (T5-T10) of 99° and a T12-S1 Lordosis of 75° (Figure 2C). CTscan of the spine showed collapsed T7/T8/T9 vertebrae at apex of kyphosis. MRI showed draping of the cord over the apex of the kyphosis. Patient had posterior vertebral column resection of T8/ T9 +

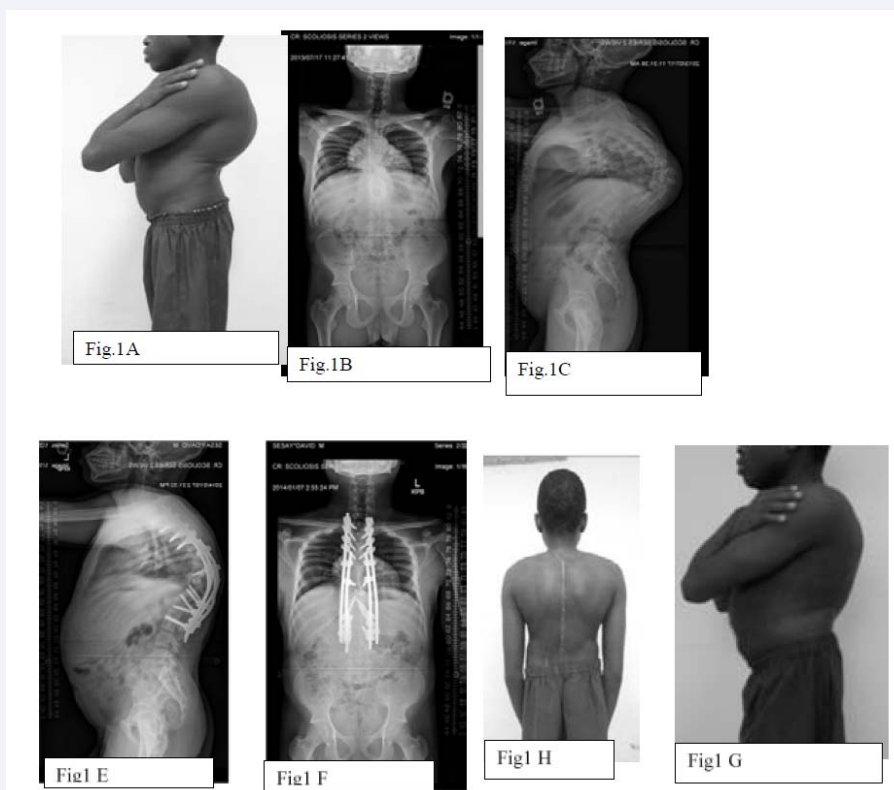


Figure 1 A nineteen year old male, with Post TB Kyphosis of 170 degrees managed by decompressive laminectomy, vertebral column resection, cage insertion and fusion.

PSF T2 -L1 with Titanium screws and cobalt chrome rods . A Harm's cage packed with local autologous bone graft was placed anteriorly at the level of the vertebral column resection. (Figure 2F). The estimated blood loss was 600ml. There was a transient decrease in the MEPs during the vertebral column resection but this improved to baseline by the end of the surgery. The patient did well post operatively. His Kyphosis T5-T10 measured 30 , 32 and 34 degrees at 6weeks, one year and two years respectively.

CASE PRESENTATION 3

KD is a 14year old Ghanaian female, with a height of 135cm and weight of 28kg and BMI of 15.4kg/m² who presented with 10yr history of painless back deformity. She had received anti TB medications in the past but did not complete the full course. She had no neurologic deficit. Radiologically, she had a severe thoracolumbar kyphosis at T7-L3 which measured 148 degrees (Figures 3 A, B, C, D).

She had an elevated ESR of 90mm/HR and a strongly positive mantoux reaction for which she was re- commenced on anti-tuberculosis (DOTs) treatment. Due to the magnitude of her deformity and malnourished status, she was put into a halo gravity traction according to our unit protocol-of 20%, 30%, 40% and maximum 50% of body weight at weeks one through weeks six respectively to optimize her CT showed organized psoas masses and multilevel vertebral destruction (Figure 3 C, D).The localized kyphosis improved to 102 degrees after 6 months of traction. Her weight and BMI improved to 41kg and 17.1kg/m² respectively. Surgery consisted of a two staged procedure 3 months apart. The first stage involved posterior spinal fusion of T6-Pelvis, S2 alar iliac screws. The second stage, done three months was an anterior vertebral column debridement corpectomy L1-L4 with an interbody fusion and mesh cage. Local bone graft and graft from the rib was used. During the procedure, copious cheesy

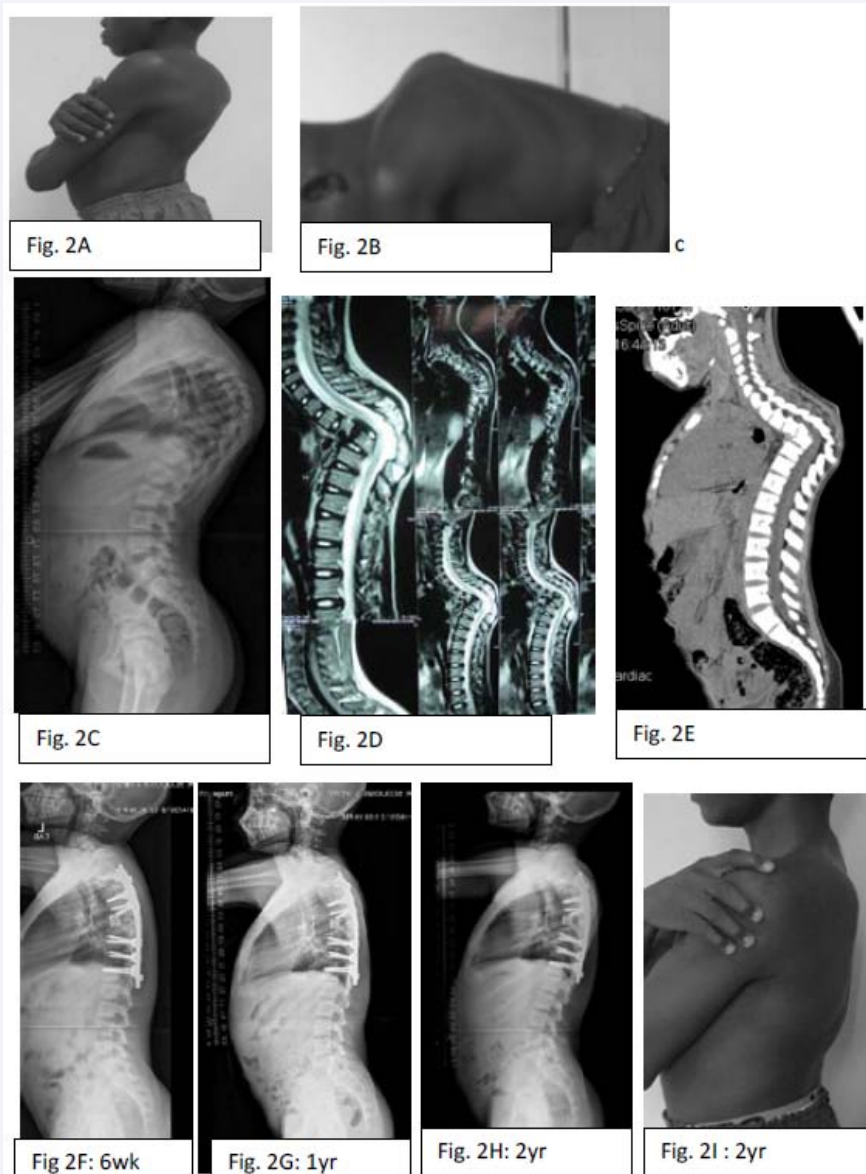


Figure 2 16yr old with 99 degrees thoracic kyphosis, treated with T8/T9 VCR and Harm's cage placement.

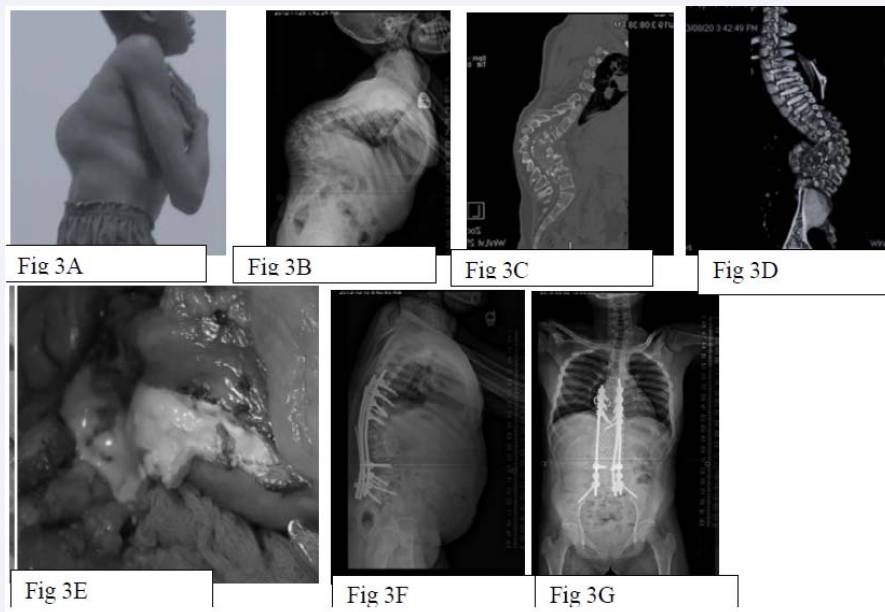


Figure 3 14yr old with post TB thoraco-lumbar kyphosis treated anti -TB medications, Halo gravity traction, VCR, corpectomy and anterior titanium cage placement.

material was evacuated from the psoas between L1-L4 which was cultured and acid -fast bacilli (AFB) were negative (Figure 3F)

Spinal cord monitoring was stable from baseline throughout the procedure. A chest tube was placed after the anterior procedure and removed on the 3rd day post op. Post op course was un-eventful. She was discharged home to continue anti-Tuberculosis treatment and to be reviewed in 6 weeks. She had an uneventful post-operative recovery. On examination 8 weeks post-op, she had a localized kyphosis of 26 degrees (Figure 3 F-G) which has remained same at the 2 year post-op.

DISCUSSION

Kyphosis or angular deformity in the sagittal plane is the most common outcome after TB infection and is directly proportional to, the diminution in the height of the disc space and destruction of the vertebral bodies. If the disease occurred early in childhood as seen in Case 1 the destruction of the intervertebral disc, vertebral bodies, and the growth plates results in slowing of their growth potential. This probably explains the relative stunting of the growth of the index patient who had severe thoracic kyphosis. The deformity occurs mostly in the thoracic spine.

Tuli believed that once a deformity exceeds 45 degrees, the posterior spinal muscles are at a mechanical disadvantage to maintain normal spinal alignment [7]. In the thoracic spine there is a natural kyphosis and gravity perpetuates the deformity culminating into respiratory embarrassment and costo-pelvic impingement if not addressed timely. Extension of abscess of bone fragments can cause spinal cord impingement and eventual paralysis [8]. Similarly, Guri reported that destruction of thoracic vertebrae by TB results in posterior displacement of the center of motion, subluxation at the level of the facets, and increased weight borne by the anterior part of the vertebral body, all resulting in aggravation of kyphosis if present [9].

Surgical treatment for patients with progressive thoracic kyphosis is therefore not only aimed at correcting the cosmetic disfigurement but also to avoiding respiratory compromise and deterioration in neurologic function. In severe deformities the vertebral column is shortened anteriorly and spinal cord abuts the apex of the kyphosis. Thus it is desirable to shorten the vertebral column posteriorly while lengthening the anterior column to allow the cord to adjust to a physiologic vertebral column and alignment.

Posterior Vertebral column resection is an effective procedure to correct angular kyphotic deformities. This is a complex and risky procedure even in expert hands [10], but the availability of intra-operative neuro-monitoring which allows live, real time continuous monitoring of the spinal cord helps in conducting the VCR procedure relatively safely [11].

Rajasekaran et al., in their study concluded that tuberculosis in the lumbar region behaves differently from TB in other areas of the spine [12]. A capacious spinal canal with floating nerve roots usually is relatively tolerant to compression by an abscess or by granulation tissue, which may develop slowly. Normal lordosis helps block the tendency of anterior disease to cause kyphosis, so extensive destruction of a vertebral body is required before kyphosis occurs. Thus, cosmetic deformity is less common in this region of the spine compared to the thoracic spine. This is consistent with the finding of localised lumbar kyphosis of 40 degrees in patient #2 though this does not rule out the possibility of progressive increase in kyphotic deformity with eventual neurologic deficit. Rajasekaran observed continued progression of deformity during the quiescent phase until growth was complete in 40% of patients while 43% had spontaneous improvement while 17% showed no change [10].

Tuli was of the opinion that if patients developed 60° or more kyphosis at dorsal or dorso -lumbar spine they were

likely to develop late onset paraplegia. Now, with increased life expectancy, these patients are likely to live longer and a localized kyphosis of 50°–60° may be disabling due to biomechanical stresses on proximal and distal segments of spine even though late onset paraplegia may not develop [5].

Halo gravity traction for kyphosis has not gained as much popularity as it is for scoliosis. It is always feared that excessive longitudinal traction may cause the spine to suffer undue attenuation at the apex and hence a neural injury. At FOCOS hospital, we have utilized Halo gravity traction in a carefully established protocol in dozens of patient without any neurologic sequelae. Halo Gravity Traction is started with a weight of 20% of the body weight at the first week, 30% at the second week, progressing as tolerated to 40% and a maximum of 50% by the fourth and fifth week respectively. Patients are carefully monitored and neurologic examination is performed every time the weight is increased. Patients are instructed to immediately report any unusual symptoms and regular full neurologic and pin site examination was performed.

The duration of preoperative halo traction varies depending on when curve correction plateaued based on 4 weekly x-rays Cobb angle measurements usually ranging between 4 weeks to 6 months (average of 63 days). Routine pinsite care is performed daily with povidone iodine. Antibiotics are used in cases of pin track infection, and pins were exchanged as necessary because of loosening or infection. Patient #3 was deemed a good candidate for this protocol due to the extent of her deformity and the need to optimize her nutritional status.

The patient underwent about 6 months of halo traction during which the curve reduced from 148 to 102 degrees, illustrating the value of halo traction in the management of kyphotic deformities and also making the deformity correction much easier and safer. For patients receiving anti-TB therapy, surgical decompression is recommended when there is progression of neurological deficits and worsening of condition and should not always wait for completion of anti-TB therapy [13]. Patient #3 had radiologic, laboratory and clinical features of an active disease and underwent surgery while on anti-tuberculosis therapy drugs, rest and mobilization with a suitable orthosis.

A wide variety of surgical treatments for spinal TB have been reported in the literature, including anterior or posterior surgery alone, and combined anterior and posterior surgery [14-16]. Different published series also describe the use of instrumentation systems and varied amounts and types of bone grafts. Patient # 3 thus had a 2-staged procedure, a posterior vertebral column resection with posterior fusion followed 3 months later by anterior corpectomy, interbody fusion with harm's cage filled with local bone graft. Even though VCR can correct the deformity anterior debridement, graft augmentation is indicated in patients with residual anterior disease or anterior column deficiency which can lead to failure of the posterior constructs and hence the arthrodesis.

As with most surgical correction of kyphosis a long construct is needed to avoid junctional collapsed as occurred inpatient #1. Unless the child is still growing, in which case a short segment fusion is warranted, adolescent patients should have a long fusions to avoid this complication. The cases show the value of patient selection, pre-operative optimization and surgical correction with favorable outcomes despite the risks involved.

REFERENCES

1. World Health Organization. Global tuberculosis report. 2012. 2012.
2. Bhutta ZA, Sommerfeld J, Lassi ZS, Salam RA, Das JK. Global burden, distribution, and interventions for infectious diseases of poverty. *Infect Dis Poverty*. 2014; 3: 21.
3. Karaeminogullari O, Aydinli U, Ozerdemoglu R, Ozturk C. Tuberculosis of the lumbar spine: outcomes after combined treatment of two-drug therapy and surgery. *Orthopedics*. 2007; 30.
4. Moon MS. Tuberculosis of the spine: controversies and a new challenge. *Spine*. 1997; 22: 1791-1797.
5. Tuli SM. Severe kyphotic deformity in tuberculosis of the spine. *Int Orthop*. 1995; 19: 327-331.
6. Moon MS, Kim I, Woo YK, Park YO. Conservative treatment of tuberculosis of the thoracic and lumbar spine in adults and children. *Int Orthop*. 1987; 11: 315-322.
7. Yau APMC, Hsu LCS, O'Brien JP, Hodgson AR. Tuberculosis kyphosis-correction with spinal osteotomy, halo-pelvic distraction and anterior and posterior fusion. *J Bone Joint Surg*. 1974; 56: 1419-1434.
8. Guri JP. The formation and significance of vertebral ankylosis in tuberculous spines. *J Bone Joint Surg Am*. 1947; 29: 136-148.
9. Rajasekaran S, Shanmugasundaram TK. Prediction of the angle of gibbus deformity in tuberculosis of the spine. *J Bone Joint Surg Am*. 1987; 69: 503-509.
10. Rajasekaran S. The natural history of post-tubercular kyphosis in children. *Bone Joint J*. 2001; 83: 954-962.
11. Boachie-Adjei O, Yagi M, Nemani VM, Sacramento-Dominguez C, Akoto H, Cunningham ME, et al. Incidence and risk factors for major surgical complications in patients with complex spinal deformity: a report from an SRS GOP site. *Spine Deform*. 2015; 3: 57-64.
12. Cho SK, Lenke LG, Bolon SM, Pahys JM, Cho W, Kang MM, et al. Can intraoperative spinal cord monitoring reliably help prevent paraplegia during posterior vertebral column resection surgery?. *Spine Deform*. 2015; 3: 73-81.
13. Jain AK. Treatment of tuberculosis of the spine with neurologic complications. *Clin Orthop Related Res*. 2002; 398: 75-84.
14. Zhao J, Lian XF, Hou TS, Ma H, Chen ZM. Anterior debridement and bone grafting of spinal tuberculosis with one-stage instrumentation anteriorly or posteriorly. *Int Orthop*. 2007; 31: 859-863.
15. Moon MS. Combined posterior instrumentation and anterior interbody fusion for active tuberculous kyphosis of the thoraco-lumbar spine. *Current Orthop*. 1991; 5: 177-179.
16. Jain AK, Dhammi IK, Prashad B, Sinha S, Mishra P. Simultaneous anterior decompression and posterior instrumentation of the tuberculous spine using an anterolateral extrapleural approach. *Bone Joint J*. 2008; 90: 1477-1481.

Cite this article

Boachie-Adjei O, Mahmud RM, Yankey K (2017) Post Tuberculous Kyphosis. *Ann Pediatr Child Health* 5(3): 1132.