SciMedCentral

Annals of Pediatrics & Child Health

Case Report

Noonan Syndrome: Obstacles in Making a Diagnosis

Luke Cielonko*, Dorothee Newbern, and Reeti Chawla

Department of Pediatric Endocrinology & Diabetes, Phoenix Children's Hospital, USA

***Corresponding author**

Luke Cielonko DO, Division of Pediatric Endocrinology & Diabetes, Phoenix Children's Hospital, Phoenix, Arizona, 1920 E. Cambridge Ave Suite 301 Phoenix, AZ 85006, USA, Tel: 602-933-4723; Email: lcielonko@phoenixchildrens.com

Submitted: 22 August 2020

Accepted: 31 August 2020

Published: 31 August 2020

ISSN: 2373-9312

Copyright

© 2020 Cielonko L, et al.

OPEN ACCESS

Keywords

- Noonan syndrome
- Genetic disorder
- PTPN11

Abstract

Noonan syndrome (NS), is a common congenital genetic disorder due to defects in the PTPN11 gene or genes related to Ras/mitogen-activated protein kinase signaling pathway. Common features seen in individuals with NS include characteristic facial features, congenital heart defects, short stature, and developmental delay. Its presentation, however, can be variable with lack of clear genotype-phenotype correlation thus making the diagnosis of a child with NS challenging. In this case report we describe a late diagnosis of NS in a 14 year old male who presented with a normal height, but a predicted adult height discordant with his genetic potential. Furthermore an extensive genetics evaluation as an infant with karyotype and chromosomal microarray returned normal, which likely dismissed the presence of a genetic syndrome. This case highlights the obstacles that resulted in a delay in diagnosis and provides additional considerations for providers who have a clinical suspicion for NS. Early recognition is important for prompt initiation of counseling, monitoring and therapeutic interventions for comorbidities associated with NS.

ABBREVIATIONS

NS: Noonan Syndrome; CMA: Chromosomal Microarray; MPH: Mid-parental Height; RAS/MAPK: Ras/mitogen-activated protein kinase; rGH: Recombinant Growth Hormone

INTRODUCTION

Noonan syndrome (NS), is a common congenital genetic disorder occurring in 1 in 1000-2500 live births due a defect in the PTPN11 gene or genes related to Ras/mitogen-activated protein kinase (RAS/MAPK), signaling pathway [1,2]. NS is inherited in an autosomal dominant pattern and has multi-systemic involvement with variable phenotypic expression. Common features seen in individuals with NS include: characteristic facial features (wide-spaced and prominent epicanthal folds, ptosis, or down slanting palpebral fissures), congenital heart defects (pulmonic stenosis and hypertrophic cardiomyopathy), and poor growth/short stature [3-7].

We describe a late diagnosis of NS in a 14 year old male who presented to our pediatric endocrinology clinic with a technically normal height (9th percentile, Z-score -1.34), but a predicted adult height discordant with his mid-parental height (MPH). Furthermore, an extensive genetics evaluation as an infant with karyotype and chromosomal microarray (CMA), returned normal, which likely resulted in the dismissal of the presence of a genetic syndrome. This case highlights the obstacles that resulted in a delay in diagnosis of this common congenital condition and provides additional considerations for providers who may have a clinical suspicion for NS.

CASE PRESENTATION

A 14 year old male was referred to pediatric endocrinology for parental concern that he was short relative to other family members. At his first endocrine visit, his height was 154.3 cm (9th percentile, Z-score -1.34), weight 43.1kg (14th percentile), and BMI 18.0 kg/m^2 (29th percentile). Upon review of his growth chart provided by his pediatrician, his growth velocity was appropriate at 5.4 centimeters per year (normal 4.5-7cm/year), as seen in Figure 1[8]. His calculated mid-parental height was 194.5 +/- 5 cm (99th percentile, Z-score 2.5). To evaluate for skeletal maturity, his pediatrician had obtained a bone age radiograph, which we interpreted as 13 years, 6 months while chronological age was 14 years, 2 months (SD 10.5 months). Although the bone age was mildly delayed, the result was appropriately concordant within the normal range of 2 SD. Using standards of Greulich-Pyle for bone age his predicted adult height was 168.9 +/-3.6 cm (16th percentile, Z-score -1.11), which is 25.6 cm (4 SD), below his MPH [9].

On physical examination we noted relative macrocephaly with a prominent forehead, triangular face and a short neck. His eyes were widely spaced with mild ptosis of the left eyelid. His nose, philtrum, and lips were normal in shape and size. He had a high arched palate and crowding of his teeth. He had mild restriction in the motion of his elbows and ankles. He was found to have pes planus bilaterally on foot examination. Upper to lower segment ratio was normal for age without scoliosis. He had a normal phallus with Tanner 3 pubic hair, but his testes were asymmetric (Right 6ml, Left 12ml). Cardiac examination was normal as was the remainder of his physical examination.

In review of his past history he was born term via c-section secondary to large for gestational age status after an uncomplicated pregnancy. However, immediately after birth he

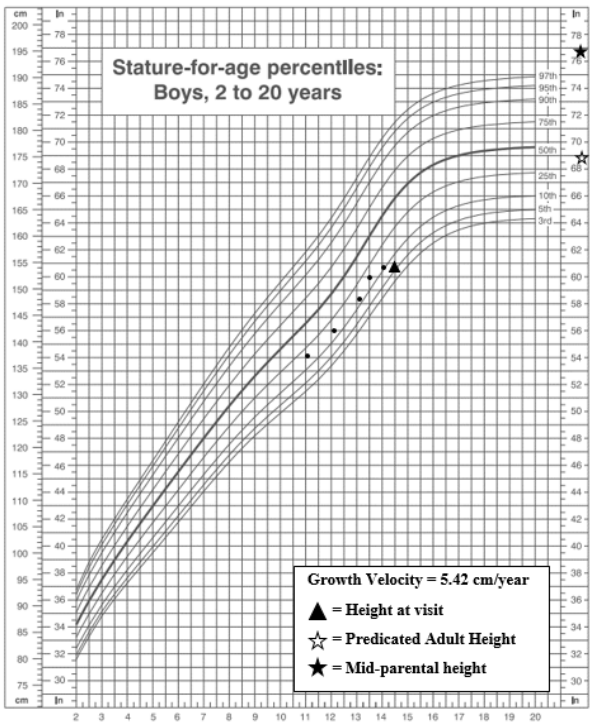

Figure 1 Linear growth pattern of Case Patient. Adapted from 2000 CDC growth charts for males ages 2 to 20 years [8].

developed respiratory distress requiring NICU hospitalization for a week. He did not have any hypoglycemia, but several congenital anomalies were noted: bilateral cryptorchidism, macrocephaly, and left eyelid ptosis. He was thus evaluated by Genetics and both a karyotype and CMA returned negative. An evaluation of craniosynostosis given his macrocephaly was negative. Around one year of age, he developed failure to thrive related to poor feeding and frequent spit-ups, so feeding therapy was initiated by pediatric gastroenterology. No specific etiology was identified, but over time feeding improved and weight stabilized at the 20th percentile. His surgical history is remarkable for a complicated bilateral orchiopexy at 2 months of age and levator resection of the left eyelid to treat his ptosis at age 2.

Biochemical evaluation of short stature was unremarkable except for a low IGF-I level of 188 ng/dL (192-599 ng/dL), Z-score -1.88 (Table 1). Testicular ultrasound obtained due to testicular asymmetry showed a severely atrophic, mildly heterogeneous right testicle (right testicular volume 0.3ml, left 11.6ml), but no testicular masses were seen. Based on his previous history, significant findings on his physical examination, and short stature relative to his MPH, genetic testing for NS was performed (Invitae Noonan Syndrome panel; San Francisco, CA). The results confirmed the diagnosis of NS with a heterozygous pathogenic variant in the PTPN11, c.923A>G (p.Asn308Ser).

DISCUSSION

NS is a genetically heterogeneous condition resulting in variable involvement and severity of different organ systems throughout life. Although most commonly due to gain of function mutations in PTPN11 gene (40-50% of affected individuals), the syndrome can be caused by mutations in other genes related to RAS/MAPK pathway (SOS1, ~10-13%; RAF1, ~5-10%; RIT1, 5%; SHOC2 <2%, KRAS, <1-2%; BRAF, <1-2%; MAP2K1, <2%; NRAS accounting for <2% of affected individuals) [1,2,4,5]. Although genetic testing is available for these mutations, 40% of cases do not have an identifiable mutation [4]. NS remains a clinical diagnosis requiring recognition of characteristic physical features and associated clinical findings (Table 2).

Our patient's early history of bilateral cryptorchidism, ptosis, and poor feeding highlight features of NS. A delay in diagnosis may have occurred due to lack of congenital heart disease and a misleading previous genetic workup. Our patient had a normal karyotype and CMA. The latter detects both large and small duplications/deletions of a section of a chromosome. CMA is not useful to identify single nucleotide variants such as insertions, deletions or base changes in DNA sequence as seen in NS [10]. Molecular genetic testing such as a multi gene panel, serial single-gene testing, or sequence analysis is required to identify pathogenic variants involved with NS.

Phenotypic outcomes of these mutations may be present with varying degrees of severity and timing of presentation that may hinder providers in making an earlier diagnosis. A scoring system has been developed to help identify individuals with NS based on various major and minor clinical findings [11]. Table 2 describes the multi-organ involvement requiring persistent surveillance. Early identification of an individual with NS is key to prevent a delay in screening for comorbidities and interventions recommended by the American Academy of Pediatrics (AAP) [4].

Table 1: Laboratory Data.

Laboratory	Result	Reference Range
IGF-1 (ng/ml) [Z-score]	188 [-1.8]	187-599 [-2.0- +2.0]
IGFBP-3 (mg/l)	4.0	3.3-10.0
WBC (k/mm^3)	9.2	4.0-10.5
Hemoglobin (g/dl)	14.9	12.5-16.1
Hematocrit (%)	42.1	36.0-47.0
Platelet count (k/mm^3)	199	130-450
Sodium (mmol/L)	141	134-147
Potassium (mmol/L)	4.0	3.6-5.3
Chloride (mmol/L)	102	95-108
Bicarbonate (mmol/L)	25	19-31
BUN (mg/dL)	15	8-25
Creatinine (mg/dL)	0.65	0.6-1.20
Glucose (mg/dL)	95	65-99
Calcium (mg/dL)	9.5	8.8-10.4
Albumin (g/dL)	4.8	3.6-5.1
AST (IU/L)	19	10-50
ALT (IU/L)	15	5-41
ESR (mm/hr)	<3	<15
TSH (mU/L)	3.78	0.3-4.0
Free T4 (ng/dL)	1.1	0.9-1.5

Table 2: Common Clinical Manifestations of NS by Organ System.

System	Clinical Manifestation
Facial Features	Infancy Wide-spaced and prominent epicanthal folds, ptosis, or down slanting palpebral fissures (95%) Low set ears (85%) and posterior hairline (55%) Webbed neck (20%) Tall forehead, large cranium Adolescence Triangular face
Endocrine	**(A/B$^{\Delta}$)** Short stature (50-70%) Delayed puberty (35% in males and 44% in females)
Cardiovascular	**(A)** Pulmonic Stenosis (50-65%) **(A)** Electrocardiogram abnormality (50%) **(A)** Hypertrophic cardiomyopathy (20-30%) **(B)** Secundum ASD (6-10%) **(B)** Other structural defects
Musculoskeletal	**(A)** Chest deformities (pectus carinatum and excavatum) **(B)** Broad thorax Spinal deformities (10-15%)
Gastrointestinal	Feeding difficulties (75%)
Renal/Genitourinary	**(A/B*)** Cryptorchidism (~77-80%) Solitary kidney, renal pelvis dilation, duplicated collecting system (10-11%)
Hematology/Oncology	Coagulation defects (30-65%) Thrombocytopenia Myeloproliferative disorder Leukemia
Lymphatic	**(A/B*)** Lymphatic dysplasia of the lungs, intestines and/or lower extremities (20%)
Ophthalmologic	Strabismus, refractive errors, amblyopia, nystagmus (95%) Anterior chamber abnormalities (ie cataracts) Fundal changes (optic disk hypoplasia, colobomas)
Neurologic, Cognitive and Behavioral	**(A/B*)** Developmental delay Language and Learning impairments (30%) Auditory deficits Difficulties with social interaction

Scoring system for NS [11]
A= Major criteria, B = Minor criteria
Definitive NS = Typical facial features plus one A or two B OR Suggestive facial features plus 2A or 3B
* Meet major criteria if all findings occur together or minor criteria if individual findings
$^{\Delta}$ Meet major criteria if height <3 percentile or minor criteria if height <10 percentile

Table 3: Formula for Calculating Mid-parental Height.

$$Girls = \frac{\left[Father's\ hieght\left(cm\ or\ in\right) + Mother's\ height\left(cm\ or\ in\right)\right] - (13\ cm\ or\ 5\ in)}{2}$$

$$Boys = \frac{\left[Father's\ hieght\left(cm\ or\ in\right) + Mother's\ height\left(cm\ or\ in\right)\right] + (13\ cm\ or\ 5\ in)}{2}$$

In our patient his predicted adult height based on bone age was significantly below his mid-parental height (4 SD), leading to a consideration of NS. Short stature is defined as a height less than two standard deviations below the mean for age and gender, however, this definition is not all encompassing to identify children with growth abnormalities. A child's height should be evaluated in the context of his or her genetic height potential, i.e. MPH (Table 3), which has a strong influence on final adult height. Comparison of a child's final projected adult height using his or her current growth curve with a calculated MPH with a predicted adult height based on bone age may help identify a pathologic growth abnormality. Most predicted adult heights should be within 10cm (4 in), or 2 SD of their mid-parental height. Without this key information our patient would not have been identified as having a growth abnormality leading to further delay in the diagnosis of NS.

Short stature and growth abnormalities are common, occurring in 50-70% of individuals with NS [6,12]. A PTPN11 defect has the greatest association with short stature in comparison to PTPN11 negative individuals (82% versus 57%) [13]. Birth weight and length are typically normal, but later throughout childhood individuals develop short stature. Growth abnormalities are most widely recognized during adolescence. This is thought to

be due to the fact that individuals with NS have been found to have a later onset of puberty (mean age 13.4 years in males and 13 years old in females) and subsequent delayed bone age of ~2 years [6,12]. Although there is some catchup growth after further pubertal progression, a majority of individuals remain short with a median height slightly below -2 SDS compared to the normal population [14]. The etiology of short stature has not been fully established, but possible mechanisms include growth hormone deficiency, neurosecretory dysfunction, and growth hormone resistance [15-17]. Individuals with a PTPN11 defect have been found to have lower insulin-like growth factor 1 levels suggesting a component of underlying growth hormone resistance [17]. In 2007 the FDA approved the use of recombinant growth hormone (rGH), for the treatment of short stature and growth abnormalities in NS regardless of growth hormone status. The use of rGH in NS has shown significant increase in growth velocity within the first year of therapy (average GV of 4.4-4.9 ± 0.2-1.7 cm/yr to 8.1-8.4 ± 0.4-1.7cm/yr) [18,19]. Previous studies have shown about a quarter of individuals with NS will not reach a normal adult height despite 4-6.4 years of rGH suggesting a spectrum of pathophysiology related to short stature in NS [20,21]. Although the efficacy of rGH for short stature in NS has not shown benefit for all NS individuals, studies agree patients who receive rGH at an earlier age and for a longer duration have the greatest outcomes [12].

CONCLUSION

NS is a common genetic congenital genetic disorder that providers may encounter. Effective monitoring and therapeutic interventions for comorbidities associated with NS is dependent upon early recognition. Calculating MPH, a diagnostic scoring system, and appropriate genetic testing should be used by providers to identify or diagnose individuals with NS who have a subtle phenotype.

REFERENCES

1. Mendez HMM, Opitz JM. Noonan syndrome: A review. Am J Med Genet. 1985; 21: 493-506.
2. Tartaglia M, Mehler EL, Goldberg R, Zampino G, Brunner HG, Kremer H, et al. Mutations in PTPN11, encoding the protein tyrosine phosphatase SHP-2, cause Noonan syndrome. Nat Genet. 2001; 29: 465-468.
3. Noonan JA. Noonan syndrome and related disorders. Progress in Pediatric Cardiology. 2005; 20: 177-185.
4. Romano AA, Allanson JE, Dahlgren J. Noonan syndrome: Clinical features, diagnosis, and management guidelines. Pediatrics. 2010; 126: 746-759.
5. Roberts AE, Allanson JE, Tartaglia M, Gelb BD. Noonan syndrome. The Lancet. 2013; 38: 333-342.
6. Sharland M, Burch M, McKenna WM, Paton MA. A clinical study of Noonan syndrome. Arch Disease in Childhood. 1992; 67: 178-183.
7. Noonan JA, Raaijmakers R, Hall B. Adult height in Noonan syndrome. Am J Med Genetics. 2003; 123A: 68-71.
8. Kuczmarski RJ, Ogden CL, Guo SS. 2000 CDC growth charts for the United States: Methods and development. Vital and Health Statistics, Series 11: Data from the National Health Survey, the National Health and Nutrition Examination Surveys, and the Hispanic Health and Nutrition Examination Survey. 2002; 11.
9. Reynolds E. Radiographic atlas of skeletal development of the hand and wrist. By W. W. Greulich and S. I. Pyle. Stanford University Press, 1950, xiii + 190 pp., ($10.00). Am J Physical Anthropol. 1950; 8: 518-520.
10. Aoki Y, Niihori T, Narumi Y, Kure S, Matsubara Y. The RAS/MAPK syndromes: Novel roles of the RAS pathway in human genetic disorders. Hum Mutat. 2008; 29: 992-1006.
11. van der Burgt I. Noonan syndrome. Orphanet J Rare Dis. 2007; 2: 4.
12. Romano AA, Dana K, Bakker B, Davis DA, Hunold JJ, Jacobs J, et al. Growth response, near-adult height, and patterns of growth and puberty in patients with Noonan syndrome treated with growth hormone. J Clin Endocrinol Metab. 2009; 94: 2338-2344.
13. Zenker M, Buheitel G, Rauch R, Koenig R, Bosse K, Kress W, et al. Genotype-phenotype correlations in Noonan syndrome. J Pediatr. 2004; 144: 368-374.
14. Ranke MB, Heidemann P, Knupfer C, Enders H, Schmaltz AA, Bierich JR. Noonan syndrome: growth and clinical manifestations in 144 cases. Eur J Pediatr. 1988; 148: 220-227.
15. Ahmed ML, Foot ABM, Edge JA, Lamkin VA, Savage MO, Dunger DB. Noonan's syndrome: Abnormalities of the growth hormone/IGF-I axis and the response to treatment with human biosynthetic growth hormone. Acta Paediatrica Scandinavica. 1991; 80: 446-450.
16. Noordam C, van der Burgt I, Sweep CGJ, Delemarre-Van De Waal HA, Sengers RCA, Otten BJ. Growth hormone (GH) secretion in children with Noonan syndrome: Frequently abnormal without consequences for growth or response to GH treatment. Clin Endocrinol. 2001; 54: 53-59.
17. Binder G, Neuer K, Ranke MB, Wittekindt NE. PTPN11 mutations are associated with mild growth hormone resistance in individuals with noonan syndrome. J Clin Endocrinol Metabolism. 2005; 90: 5377-5381.
18. Cotterill AM, McKenna WJ, Brady AF, Sharaland M, Elsawi M, Yamada M, et al. The short-term effects of growth hormone therapy on height velocity and cardiac ventricular wall thickness in children with Noonan's syndrome. J Clin Endocrinol Metabolism. 1996; 81: 2291-2297.
19. MacFarlane CE, Brown DC, Johnston LB, Patton MA, Dunger DB, Savage MO, et al. Growth Hormone Therapy and Growth in Children with Noonan's Syndrome: Results of 3 Years' Follow-Up. JCEM. 2001; 86: 1953-1956.
20. Noordam C, Peer PGM, Francois I, de Schepper J, van den Burgt I, Otten BJ. Long-term GH treatment improves adult height in children with Noonan syndrome with and without mutations in protein tyrosine phosphatase, non-receptor-type 11. Eur J Endocrinol. 2008; 159: 203-208.
21. Lee PA, Ross J, Germak JA, Gut R. Effect of 4 years of growth hormone therapy in children with Noonan syndrome in the American Norditropin Studies: Web-Enabled Research (ANSWER) Program® registry. Int J Pediatric Endocrinol. 2012; 2012: 15.

Cite this article

Cielonko L, Newbern D, Chawla R. Noonan Syndrome: Obstacles in Making a Diagnosis. Ann Pediatr Child Health 2020; 8(7): 1199.