

Annals of Pediatrics & Child Health

Special Issue on

Pediatric Gastroenterology Disorders

Edited by:

Hillel Naon, M.D.

Acting Division Head, Pediatric Gastroenterology, Hepatology and Nutrition, Children's Hospital Los Angeles, University Southern California, Keck School of Medicine, Los Angeles, USA

Case Report

CMV Colitis in a Full-Term Neonate after Surgical Repair of Imperforate Anus

Fotini Tania Mitsinikos^{1*}, Hillel Naon¹, Nick Shillingford²,
Chuan-Hao Lin¹ and Rula Harb¹

¹Division of Gastroenterology, Hepatology, and Nutrition, Children's Hospital Los Angeles, University Southern California, Keck School of Medicine, Los Angeles, USA

²Department of Pathology, Children's Hospital Los Angeles, University Southern California, Keck School of Medicine, Los Angeles, USA

*Corresponding author

Fotini Tania Mitsinikos, Division of Gastroenterology, Hepatology, and Nutrition, Children's Hospital Los Angeles, 4650 Sunset Blvd, MS #78, Los Angeles, 90027, USA, Tel: 323-361-2181; Fax: 323-361-3718; E-mail: fmitsinikos@chla.usc.edu

Submitted: 01 October 2014

Accepted: 12 January 2015

Published: 04 February 2015

Copyright

© 2015 Mitsinikos et al.

OPEN ACCESS

Keywords

- CMV
- Colitis
- Neonate
- Hematocheizia

Abstract

Background: Cytomegalovirus (CMV) is a ubiquitous virus and has significant implications in the immune suppressed. Several cases of CMV colitis have been reported in neonates, acquiring the virus in a variety of ways, through vertical transmission, breast milk, or blood transfusion.

Case Presentation: Here we report a full-term infant who developed severe cytomegalovirus colitis post-operatively after imperforate anus repair.

Conclusion: In many cases, identification of transmission of CMV is difficult and often times unidentified, even in the case presented here. Discussion of congenital CMV infection is discussed and considered unlikely.

ABBREVIATIONS

CMV: Cytomegalovirus

INTRODUCTION

Cytomegalovirus (CMV) is a ubiquitous virus and its infection has a wide spectrum of presentation dependent on age and immune competency. Particularly in the neonate, this can range from asymptomatic to symptomatic congenital disease which may

manifest as intrauterine growth retardation, jaundice, purpura, hepatosplenomegaly, microcephaly, intra cerebral calcification, and retinitis. Developmental delays may develop with age. In the immune competent host, it often presents with vague symptoms, similar to infectious mononucleosis, however in the immune compromised host, it may present as pneumonia, retinitis, or colitis [1]. Here, we describe a neonate who developed colitis in the setting of repaired imperforate anus.

CASE PRESENTATION

The patient is a newborn male infant, born to a G2P2 mother, at 39 weeks gestational age, by vacuum-assisted vaginal delivery, with variable decelerations during labor, weighing 3 kilograms at birth. The mother had received prenatal care with negative prenatal infectious screens and normal prenatal ultrasounds. At the time of delivery, APGARS were 9 and 9 at 1 and 5 minutes, respectively. Physical exam was significant for imperforate anus with pinhole opening near expected location of the anus. In the first few days of life, he was noted to be jaundiced in the setting of ABO incompatibility (mother type A+ and infant type O+) with a total bilirubin of 10.7 with a conjugated component of 0.7 at 38 hours of life and received 2 days of phototherapy. He became increasingly more lethargic with bilious emesis and found to have a metabolic acidosis. He was started on ampicillin and gentamicin and transferred to our facility for higher level care and surgical evaluation.

Upon transfer, he was tachycardic, lethargic, with a mild to moderately distended abdomen and thick, bilious, feculent material draining from the repogle tube. His physical exam was significant for few palpable loops of bowel in the abdomen and abdominal X-ray demonstrated paucity of distal gas with mild distention concerning for mid-to-proximal bowel obstruction. On day of life 4, he had an exploratory laparotomy for these findings, revealing a completely normal and viable intestine with some congested lacteals and no evidence of atresia. A limited posterior sagittal anorectoplasty was performed. After successful completion of his operation, he returned to the NICU, intubated, on pressor support and on ampicillin, gentamicin, and metronidazole.

In the immediate post-operative period, he was coagulopathic, presumably from sepsis, although no identified infection at the time, requiring multiple blood product transfusions including packed erythrocytes, platelet and cryoprecipitate. On post-operative day (POD) #4, he began having frankly bloody output from the repogle and bloody watery stools. Fecal culture, adenovirus and *Clostridium difficile* were negative. Hematology was consulted regarding his coagulopathy and recommended Vitamin K replacement given his antibiotic history as well as Factor XIII level, which was normal. Gastroenterology was consulted on POD #8 for bloody stools, however given proximity to surgery and coagulopathy, was deemed high risk for perforation and colonoscopy was deferred.

He was extubated on POD #9, however continued to have bloody stools with the passage of clots that looked to be casts, thought to be sloughed mucosa. His stool output and blood losses were significant and in the face of persistent coagulopathy requiring cryoprecipitate almost daily. On POD #17 an upper gastrointestinal series with small bowel follow through was completed that did not demonstrate obstruction, however there was bowel wall irregularities, for which enterocolitis was a consideration. Despite completion of 14 days of antibiotics, he developed a leukocytosis with significant bandemia, for which ceftriaxone, metronidazole, and vancomycin were restarted. On POD #32, suction rectal biopsy was completed by surgery that was not consistent with Hirschsprung's disease without any evidence of infection. On POD #35, a flexible sigmoidoscopy was

completed that demonstrated mild to moderate colitis in the recto-sigmoid area with focal erythema and patchy abnormal colonic mucosa. A biopsy from the rectum was obtained that showed no intestinal epithelium and consistent with CMV-associated colitis with ulceration, granulation tissue and large atypical cells with cytoplasmic and nuclear inclusions as demonstrated in (Figure 1). His urine and blood CMV PCR were positive. Further work up was negative for ophthalmologic and cranial ultrasonographic evidence of CMV. Breast milk was tested for CMV and negative. Additionally, immunodeficiency work up was completed and negative. Treatment with intravenous ganciclovir was initiated. Blood and urine CMV PCR down trended and cleared while on treatment, for which he completed eleven weeks. His liver function was never significantly compromised and his AST and ALT are 82 and 63, respectively with a total bilirubin of 0.4. His bloody stools have persisted, thought to be related to delayed re-epithelialization of the colonic mucosa, although have slowly improved over time, becoming more formed and subjectively decreased amount of visible blood. He has tolerated a slow advancement of enteral breast milk feeds, largely dictated by stool output, to aid mucosal healing, and with intravenous

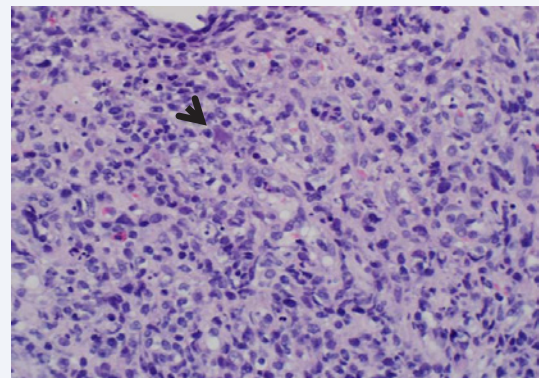


Figure 1 H&E stain. The slide shows a fragment of granulation tissue (from an ulcer) with a mixed inflammatory infiltrate. The large cell (arrow) represents an infected cell with the classic intra nuclear inclusion. Of note, the cell appears to have internalized a neutrophil (bottom half of cell). The nuclei of other cells in the field have a smudgy appearance, a common finding in CMV colitis.

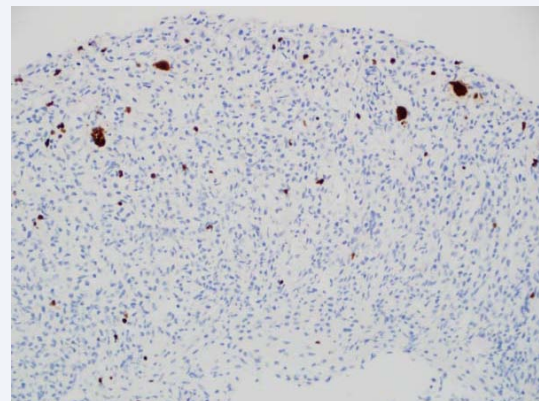


Figure 2 CMV Immunohistochemical stain for cytomegalovirus is positive in several large cells.

parenteral nutrition supplementing the remainder of his caloric needs for growth.

DISCUSSION

Cytomegalovirus infection manifestations are quite variable and dependent on both age and immune competency of the host. In most children, infections are asymptomatic, however may present as an infectious mononucleosis-like picture with prolonged fever and mild hepatitis. More invasive disease is typically found in immune compromised hosts, such as individuals with human immunodeficiency virus (HIV) or individuals receiving immunosuppressive therapy for organ transplantation, and may have a variety of presentations as well as varying degrees of severity [1].

In the neonatal period, 10% of infants born with CMV will demonstrate involvement at birth, particularly intrauterine growth retardation, jaundice, purpura, hepatosplenomegaly, microcephaly, intracerebral calcifications, and retinitis [1]. Long-term sequela includes sensorineural hearing loss, which is particularly increased in infants with symptomatic congenital infection. Infection with CMV in the neonate may be acquired in a variety of ways, namely, from in-utero transplacental passage of blood-borne virus, passage through infected maternal genital tract, post-natally through ingestion of infected breast milk, and blood transfusion [1-3]. Viral shedding from maternal pharynx or urinary tract during the first months after birth is not associated with perinatal transmission [4]. CMV gastrointestinal disease has been demonstrated in immune competent host, in neonates, older children and adolescents [2,4,5]. In most cases, infants were breast fed and presented with CMV disease 5-8 weeks after birth, particularly with fever and diarrhea, implying that transmission of the virus occurred soon after birth, as CMV incubation period is quite variable, 3-12 weeks after blood transfusion and between 1 to 4 months after tissue transplantation [1] [Figure2].

Several case reports demonstrate CMV colitis in the neonate. These case-reports demonstrate that infants were breast-fed and many of them premature and low-birth weight [4,6,7]. These premature infants are considered an immune compromised host and in the setting of breast-feeding, thought to be the enteral exposure leading to these infant's gastrointestinal manifestations. In our case, the infant was born full-term with no exposure to breast milk given history of imperforate anus and acute obstruction early on in life. There have been no case reports demonstrating CMV gastrointestinal infection with imperforate anus after repair. While there were no stigmata of symptomatic congenital infection, there was low clinical suspicion for testing of CMV prior to demonstrating this pathology on rectal biopsy.

In our case, unlike most case reports of CMV colitis in the neonate, he had early abdominal surgery and posterior sagittal anorectoplasty (PSARP). In a study in France, they studied 5 neonates, average gestational age of 34.4 weeks, who underwent various surgical interventions for various etiologies like necrotizing enterocolitis, Meckel's diverticulum resulting in volvulus and perforation, and ileal atresia and in all surgical samples demonstrated characteristic CMV nuclear inclusions,

suggesting that CMV may be involved in surgical pathology in neonates [8]. Interestingly, it is difficult to discern whether the presence of the virus or active infection and inflammation may lead to these outcomes. Specifically, they noted CMV infecting the enteric plexus, giving rise to Hirschsprung's disease. Of note, 3 of the 5 patients did not receive blood transfusion prior to detection of CMV in the surgical specimen. Blood transfusion is a known source of infection in all age groups. At our institution, CMV antibody negative blood is reserved for infants who are very low birth weight (VLBW), weighing less than or equal to 1000 grams. We universally leukoreduce for CMV safe blood, reducing white cell load by 4 logs. However, this may miss about 1.5% of CMV in a blood donor due to window period of seroconversion and sensitivity. While still a possibility, transmission through packed erythrocyte transfusions, for which this child received 4 prior to diagnosis, is possible, but unlikely. Ultimately, it is impossible to determine the source of the infant's infection, whether congenital or acquired. While blood transfusion is a possible source, it is difficult to determine whether his surgical procedure put him at risk of acquiring the infection as well. Further work up revealed no underlying immunodeficiency and patient was treated with intravenous ganciclovir which has shown effectiveness in other neonates [1,9].

REFERENCES

1. Cytomegalovirus Infection. In: Pickering Lea, ed. Red book 2012: 2012 Report of the Committee on Infectious Diseases. 29th ed 2012.
2. Berardi A, Rossi C, Fiorini V, Rivi C, Vagnarelli F, Guaraldi N, et al. Severe acquired cytomegalovirus infection in a full-term, formula-fed infant: case report. *BMC Pediatr*. 2011; 11: 52.
3. Hamprecht K, Maschmann J, Jahn G, Poets CF, Goelz R. Cytomegalovirus transmission to preterm infants during lactation. *J Clin Virol*. 2008; 41: 198-205.
4. Cheong JL, Cowan FM, Modi N. Gastrointestinal manifestations of postnatal cytomegalovirus infection in infants admitted to a neonatal intensive care unit over a five year period. *Arch Dis Child Fetal Neonatal Ed*. 2004; 89: 367-369.
5. Rafailidis PI, Mourtzoukou EG, Varbobitis IC, Falagas ME. Severe cytomegalovirus infection in apparently immunocompetent patients: a systematic review. *Virol J*. 2008; 5: 47.
6. Okulu E, Akin IM, Atasay B, Ciftçi E, Arsan S, Türmen T. Severe postnatal cytomegalovirus infection with multisystem involvement in an extremely low birth weight infant. *J Perinatol*. 2012; 32: 72-74.
7. Fischer C, Meylan P, Bickle Graz M, et al. Severe postnatally acquired cytomegalovirus infection presenting with colitis, pneumonitis and sepsis-like syndrome in an extremely low birth weight infant. *Neonatology*. 2010; 97: 339-345.
8. Bonnard A, Le Huidoux P, Carricaburu E, Farnoux C, Berrebi D, Aigrain Y, et al. Cytomegalovirus infection as a possible underlying factor in neonatal surgical conditions. *J Pediatr Surg*. 2006; 41: 1826-1829.
9. Buonomo PS, Maurizi P, Valentini P, Mastrangelo S, Lazzareschi I, Ridola V, et al. Successful treatment with oral valganciclovir in immunocompetent infant with gastrointestinal manifestations of cytomegalovirus infection. *J Perinatol*. 2006; 26: 648-649.

Cite this article

Mitsinikos TF, Naon H, Shillingford N, Lin CH, Harb R (2015) CMV Colitis in a Full-Term Neonate after Surgical Repair of Imperforate Anus. *Ann Pediatr Child Health* 3(2): 1050.