

Review Article

Chronic Lung Allograft Dysfunction After Lung Transplantation and Late Onset Non-infectious Pulmonary Complications After Hematopoietic Stem Cell Transplantation: Are they Mirror Images?

Masaaki Sato^{1,2*}¹Department of Thoracic Surgery, Kyoto University, Japan²Latner Thoracic Surgery Research Laboratories, University of Toronto, Canada

*Corresponding author

Masaaki Sato, Department of Thoracic Surgery, Kyoto University Hospital, 54Kawara-chyo, Sakyo-ku, Kyoto-city, Kyoto606-8507, Japan, Tel: +81-75-751-4975; Fax: +81-75-751-4974; Email: satomasa@kuhp.kyoto-u.ac.jp

Submitted: 27 February 2014

Accepted: 11 April 2014

Published: 07 May 2014

ISSN: 2333-6625

Copyright

© 2014 Sato

OPEN ACCESS

Keywords

- Lung transplantation
- Hematopoietic stem cell transplantation
- Chronic rejection
- Graft-versus-host disease
- Bronchiolitis obliterans

Abstract

Chronic Lung Allograft Dysfunction (CLAD) or chronic rejection after lung transplantation may exhibit a conventional obstructive form (bronchiolitis obliterans syndrome, BOS) or a restrictive form with predominant involvement of peripheral lung tissue (restrictive allograft syndrome, RAS). Late onset non-infectious pulmonary complications (LONIPCs) following hematopoietic stem cell transplantation typically appear as obstructive pulmonary dysfunction similar to BOS after lung transplantation, while peripheral lung tissue may also be predominantly involved. The classification and diagnosis of LONIPCs includes Idiopathic Pneumonia Syndrome (IPS), Bronchiolitis Obliterans Organizing Pneumonia (BOOP), and other conditions. Considering the interesting similarity of immunological backgrounds (i.e., the lung allograft is targeted by the host immune system or the native lung is targeted by the immune system of the graft progenitor hematopoietic cells), the lung injury observed in these two conditions appears to be a mirror image. In this article, similarities as well as differences between the two conditions are reviewed. Hopefully, this new approach comparing the two conditions will provide a better understanding of the biological mechanisms involved and ultimately lead to better preventive and therapeutic strategies in the future.

ABBREVIATIONS

CLAD: Chronic Lung Allograft Dysfunction; BO: Bronchiolitis Obliterans; BOS: Bronchiolitis Obliterans Syndrome; RAS: Restrictive Allograft Syndrome; LONIPCs: Late Onset Non-infectious Pulmonary Complications; HSCT: Hematopoietic Stem Cell Transplantation; IPS: Idiopathic Pneumonia Syndrome; BOOP: Bronchiolitis Obliterans Organizing Pneumonia; GVHD: Graft-Versus-Host Disease; FEV1: Forced Expiratory Volume in one second; FVC: Forced Vital Capacity; ISHLT: International Society for Heart and Lung Transplantation; NRAD: Neutrophilic Reversible Allograft Dysfunction; ARAD: Azithromycin-

Responsive Allograft Dysfunction; PPFE: Pleuroparenchymal Fibroelastosis; DAD: Diffuse Alveolar Damage; OP: Organizing Pneumonia.

INTRODUCTION

Chronic Lung Allograft Dysfunction (CLAD) remains the major limitation to long-term success of lung transplantation, affecting approximately 50–60% of lung transplant recipients within 5 years after transplantation [1]. Recipients of hematopoietic stem cell transplantation (HSCT) are susceptible to various pulmonary complications; in particular, approximately 10% of the recipients

of allogenic HSCT are affected by chronic lung complications, comprehensively called Late Onset Non-Infectious Pulmonary Complications (LONIPCs) [2].

Interestingly, in both CLAD and LONIPCs, immune-mediated injury targeting the lung is considered to play a critical role; namely, chronic rejection against the allograft lung in CLAD after lung transplantation and chronic Graft-Versus-Host Disease (GVHD) against the native lung in LONIPCs after HSCT [3,4] (Figure 1). Factors other than immune-mediated injuries may also be involved, such as infection, aspiration, ischemia-reperfusion injury after lung transplantation, and chemotherapy and radiation before HSCT (Figure 1). The common major phenotype of CLAD and LONIPCs is bronchiolitis obliterans (BO; histological diagnosis) and its clinical correlate, Bronchiolitis Obliterans Syndrome (BOS), the focus of which is small airways (terminal bronchioles). Clinically, both CLAD and LONIPCs can predominate in peripheral lung tissue, as seen in Restrictive Allograft Syndrome (RAS) after lung transplantation [5] and Bronchiolitis Obliterans Organizing Pneumonia (BOOP) and idiopathic pneumonia syndrome (IPS) after HSCT [6] (Table 1).

The purpose of the present article is to review each phenotype of non-infectious chronic pulmonary complications following lung transplantation and HSCT and to compare the similarities and differences in order to facilitate further investigation across these two fields.

CLAD after lung transplantation

CLAD, which has also been called chronic rejection, remains a major limitation to the long-term success of lung transplantation.

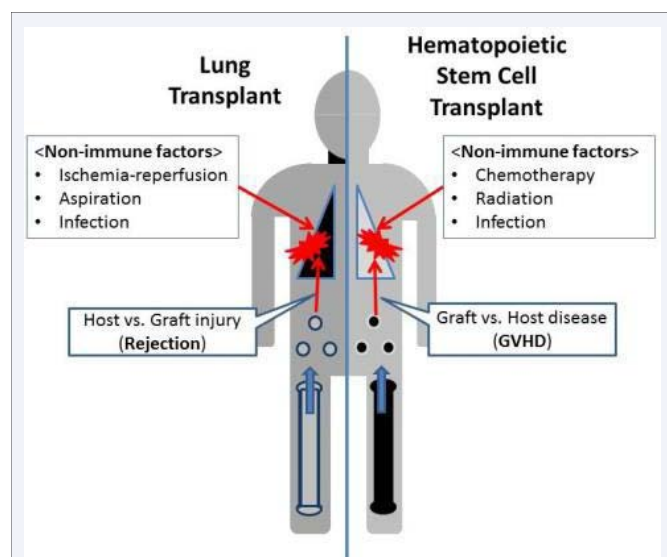


Figure 1 Similarities and differences between chronic lung allograft dysfunction after lung transplantation (CLAD) and late onset non-infectious pulmonary complications (LONIPCs): In CLAD after Lung Transplantation (left), the transplanted lung is allogenic and is a potential target of alloimmune responses (i.e., rejection) by the host immune system. In LONIPCs after hematopoietic stem cell transplantation (right), the whole body is allogenic to the transplant hematopoietic stem cell and is a potential target of alloimmune responses (i.e., graft-versus-host disease). Non-immune factors may also be involved in these processes.

Table 1: CLAD after lung transplantation and LONIPCs after HSCT.

	Obstructive dysfunction	Restrictive dysfunction
Post-lung-transplant CLAD	BOS	RAS
Post-HSCT LONIPCs	BOS	IPS, BOOP, DAD, NSIP
Anatomical compartment	Small airways	Peripheral lung tissue
Pathology (early)	Lymphocytic bronchiolitis	DAD, interstitial pneumonia
Pathology (established)	Fibrotic BO	PPFE, BOOP, interstitial fibrosis
CT findings (early)	Tree-and-bud (ARAD)	Patchy/diffuse GGO, consolidation
CT findings (established)	Hyperinflation, mosaic attenuation, bronchiectasis	Pleural/interlobular septal thickness, consolidation, interstitial fibrotic change

Abbreviations: CLAD: Chronic Lung Allograft Dysfunction; LONIPCs: Late Onset Non-Infectious Pulmonary Complications; HSCT: Hematopoietic Stem Cell Transplantation; BOS: Bronchiolitis Obliterans Syndrome, RAS: Restrictive Allograft Syndrome; IPS: Idiopathic Pneumonia Syndrome; BOOP: Bronchiolitis Obliterans Organizing Pneumonia; DAD: Diffuse Alveolar Damage; NSIP: Nonspecific Interstitial Pneumonia; BO: Bronchiolitis Obliterans; PPFE: Pleuroparenchymal Fibroelastosis; ARAD: Azithromycin-Responsive Allograft Dysfunction; GGO: Ground Glass Opacities

Approximately 50–60% of lung transplant recipients are affected by CLAD within 5 years after transplantation [1]. The high incidence of CLAD translates into a limited long-term survival of lung transplant recipients of approximately 50% for 5-year survival and 30% for 10-year survival, which are significantly worse than for survival rates for other solid organ transplantation [1].

BOS has long been the term applied to chronic rejection after lung transplantation; however, with emerging evidence that BOS is not the only form of chronic rejection or chronic allograft dysfunction [5,7,8], the term, CLAD has recently been applied. The definition of CLAD is currently under discussion in the working group of the International Society for Heart and Lung Transplantation (ISHLT) [3]. Two major forms of CLAD have been recognized: BOS and RAS. Although BOS and RAS may show a similar decline in Forced Expiratory Volume in one second (FEV1) in pulmonary function tests, BOS and RAS show distinct clinical presentations with different physiology, pathology, and radiological findings [5] (Figure 2).

BOS after lung transplantation

Pulmonary function tests in “conventional” BOS after lung transplantation show obstructive changes without restrictive components [9] represented by a decline in FEV1 and FEV1/FVC (forced vital capacity) without a decline in total lung capacity. The ISHLT has graded the severity of BOS according to the results of pulmonary function tests (Table 2) [9]. The histopathological findings of established BOS after lung transplantation include inflammation and fibrosis around and inside the lumen of small airways (terminal bronchioles); BO is a histological diagnosis representing this condition [10] (Figure 2).

Neutrophilic Reversible Allograft Dysfunction (NRAD) and

Fibrotic BOS (fBOS) are concepts proposed by the Leuven group to describe subtypes of BOS [11]. NRAD describes allograft dysfunction that is responsive to azithromycin treatment, so the currently preferred term is Azithromycin-Responsive Allograft Dysfunction (ARAD) [12]. ARAD is characterized by centrilobular changes including nodules and a tree-in-bud pattern on CT scan [13]. Airway neutrophilia has been demonstrated to be associated with lymphocytic bronchiolitis [14], which has been assumed to be a precursor lesion of BO [15]. Therefore, some cases of ARAD are considered to be associated with the clinical presentations of lymphocytic bronchiolitis.

Conversely, fBOS is not responsive to azithromycin. These patients show less inflammation in BAL findings, and the histological findings are characterized by airway fibrosis [11]. Radiographically, fBOS shows air trapping and hypertranslucency inconsistent with the conventional description of BOS. fBOS may develop in a stable patient, or eventually in a patient who developed ARAD and recovered [11].

BOS explains approximately two-thirds of all CLAD cases [5,16]. Although patient survival after the development of BOS has been believed to be generally poor, it is possible that RAS has been a significant confounder. Furthermore, the prognosis of BOS with late onset (after 2 or 3 years post-transplant) is significantly better than for RAS or BOS with earlier onset and is almost comparable with patients without CLAD [17].

RAS after lung transplantation

RAS shows restrictive physiology represented by a decline in total lung capacity less than 90% of baseline with a decline in FEV1 less than 80% of baseline [5]. The histology of established RAS is characterized by inflammation and fibrosis in peripheral lung tissue including the alveoli, pleura, and interlobular septum [5] (Table 1, Figure 1). Our recent study also revealed that established RAS shows the characteristics of Pleuroparenchymal Fibroelastosis (PPFE) [18], while the onset of RAS is strongly associated with late new-onset Diffuse Alveolar Damage (DAD) that occurs later than 3 months post-transplant [19]. Notably, the organizing phase of DAD can also be interpreted as organizing pneumonia. Importantly, the lung affected by RAS also contains BO lesions of varying degrees [5] (Figure 3).

In the early stages of RAS, central and peripheral ground glass opacities are the most prominent feature on CT, whereas in later stages bronchiectasis, traction, central and peripheral consolidation, architectural deformation, volume loss and hilus retraction are more pronounced [20]. The clinical course of RAS is characterized by a stair-step pattern of progression; RAS patients had 1–4 acute episodes that accompanied acute respiratory

Table 2: BOS classification system (2002 ISHLT).

BOS 0	BOS 0-p FEV ₁ 81–90% of baseline and/or FEF _{25–75%} ≤75% of baseline
BOS 1	FEV ₁ 66–80% of baseline
BOS 2	FEV ₁ 51–65% of baseline
BOS 3	FEV ₁ ≤50% of baseline

Abbreviations: BOS: Bronchiolitis Obliterans Syndrome; ISHLT: International Society for Heart and Lung Transplantation; FEV1: Forced Expiratory Volume in one second; FEF_{25–75%}: Forced mid-Expiratory Flow rate

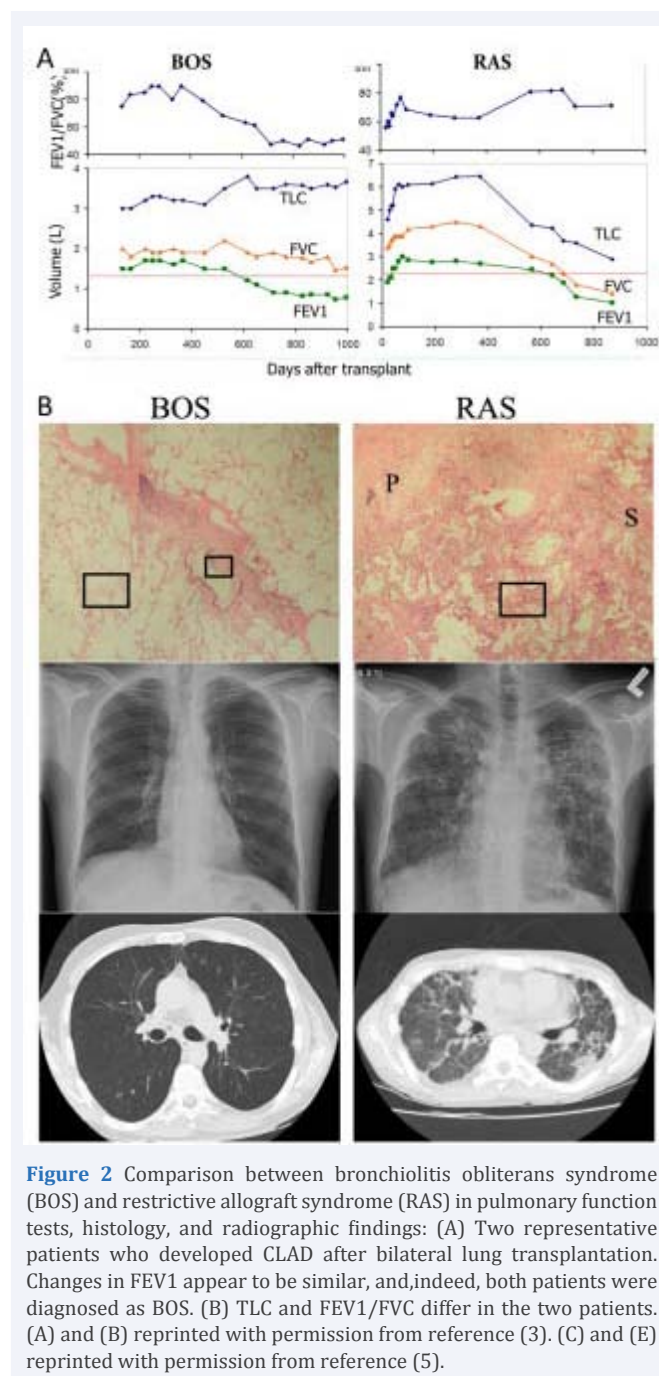


Figure 2 Comparison between bronchiolitis obliterans syndrome (BOS) and restrictive allograft syndrome (RAS) in pulmonary function tests, histology, and radiographic findings: (A) Two representative patients who developed CLAD after bilateral lung transplantation. Changes in FEV1 appear to be similar, and, indeed, both patients were diagnosed as BOS. (B) TLC and FEV1/FVC differ in the two patients. (A) and (B) reprinted with permission from reference (3). (C) and (E) reprinted with permission from reference (5).

deterioration or distress, a sudden drop in pulmonary function, evidence of DAD on biopsies, and patchy or diffuse ground-glass opacities with occasional consolidation on CT scan [21].

Importantly, RAS explains as many as 25–35% of all CLAD cases and the patient survival of RAS after CLAD onset is much worse than that of BOS, with the median survival of RAS approximately one-half to one-third that of BOS (BOS, 1421 days vs. RAS, 541 days) [5]. This significant difference has been well reproduced by the Leuven group [16]. Given that RAS shows such different clinical characteristics and is not a minor component of CLAD, the results of previous studies that did not distinguish RAS and BOS must be carefully interpreted.

RAS and its impact on CLAD after lung transplantation

BO has been considered to be a histological finding specific to chronic rejection after lung transplantation. Other miscellaneous findings in peripheral lung tissue such as DAD, organizing pneumonia, and interstitial fibrosis are generally nonspecific and therefore, little attention has been paid to these pathological processes occurring in lung allografts. Because obtaining a histological diagnosis of BO can be difficult, the clinical diagnosis of BOS was based on pulmonary function tests. However, the basic concept that BO(S) is a form of chronic rejection has not changed for many years.

The identification of RAS sheds light on the “non-specific” findings in peripheral lung tissue and it is now evident that a series of events occurring in this anatomical compartment has a significant impact on a patient’s clinical course and eventual survival. What is important to lung transplant physicians now is not whether the histological finding is specific to chronic rejection, but rather how the complete clinical picture of the patient including physiology, pathology, and radiology, fits in which CLAD phenotype.

LONIPCs after HSCT

Bone marrow transplantation and other forms of HSCT are established treatment options for patients with a number of hematological and non-hematological malignant and non-malignant conditions. After HSCT, 40–60% of recipients develop pulmonary complications, which remain major causes of morbidity and mortality. In particular, LONIPCs occur beyond 3 months after allogenic HSCT in approximately 10% of cases and are life-threatening complications [2,22]. Although the underlying mechanisms of LONIPCs remain incompletely understood, their development is considered to be associated with the presence of chronic GVHD [2,22].

The spectrum of LONIPCs is undefined, as well. Palmas et al included BO, BOOP, diffuse DAD, Lymphocytic Interstitial Pneumonia (LIP), and Non classifiable Interstitial Pneumonia (NCIP) [2]. Afessa et al included BO, BOOP, and IPS in LONIPCs [6]. According to the consensus document from the National Institutes of Health, only histologically demonstrated BO is

diagnostic or sufficient to establish the diagnosis of chronic GVHD, while BOOP may present as either acute or chronic GVHD [4]. Because BO has several specific defining characteristics, compared with the other disorders, LONIPCs were sometimes classified as BO and other conditions.

BOS after HSCT

BO is the most common late non-infectious pulmonary complication following HSCT and is characterized by the onset of new air flow obstruction. Yokoi et al reported that the early histologic changes of BO included epithelial defects of the trachea and bronchi and infiltration of inflammatory cells, and these transformed to a late phase in which airways were partially or completely obstructed [23]. Notably, BO is not truly specific to pulmonary GVHD; BO can also be drug-induced, associated with collagen diseases, or idiopathic [24]. Because BO is a histological diagnosis based on biopsy or autopsy, and the proof of BO lesions in biopsy is difficult in practical terms because of their patchy distribution, BOS has been used as a clinical surrogate for histological BO, applying the ISHLT criteria used for lung and heart-lung transplantation [25] (Table 2).

Because of the lack of defined diagnostic criteria, the reported incidence of BO(S) following allogenic HSCT varies widely from 1.7–26% [25]. In a review of 2152 allogenic HSCT recipients reported in nine studies, the average incidence of BO was 8.3% [6]. The development of BOS in both pediatric and adult populations is closely associated with the occurrence of chronic GVHD; other risk factors include the use of methotrexate and serum immunoglobulin deficiency [6].

Despite treatment with augmented immunosuppression and other therapeutic strategies that are essentially the same as those for BOS after lung transplantation (Table 2), the prognosis for patients with BOS remains generally poor. The FEV1 decline rate is widely variable in BO and rapid deterioration in FEV1 is associated with increased mortality [26]. Previous studies report a 3-year mortality rate of 65% in patients with BOS accompanying chronic GVHD [26].

Involvement of peripheral lung tissue in LONIPCs after HSCT

In contrast to BO, in which the focus of the pathological process is essentially small airways (terminal bronchioles), other forms of LONIPCs involve more peripheral lung tissue. By reviewing histological changes in 17 biopsy specimens of the lung showing GVHD in bone marrow transplant recipients, Yousem suggested that morphological changes related to pulmonary GVHD fell into four transplant-related categories: DAD, lymphocytic bronchitis/bronchiolitis with interstitial pneumonitis, BOOP, and BO [27]. However, to date, only BO is diagnostic of chronic pulmonary GVHD in the consensus document from the National Institutes of Health [4].

IPS is defined by the presence of widespread alveolar injury in the absence of lower respiratory tract infection [28], representing a heterogeneous group of conditions that result in DAD or interstitial pneumonitis [29]. The diagnostic criteria for IPS are not clearly defined and could also include other conditions involving the pulmonary interstitium such as BOOP,

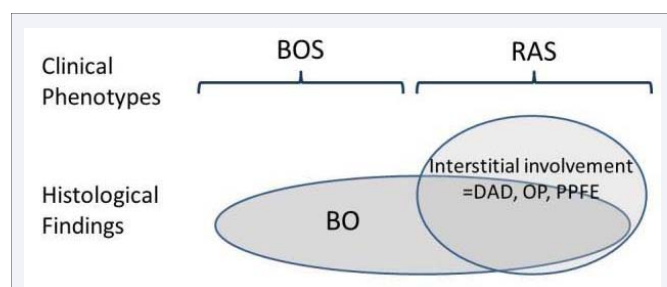


Figure 3 Relationships between clinical phenotypes of CLAD after lung transplantation and histological findings: Note that the histological diagnosis of BO is not limited to BOS but often exists in the lung affected by RAS.

Abbreviations: BOS: Bronchiolitis Obliterans Syndrome; RAS: Restrictive Allograft Syndrome; BO: Bronchiolitis Obliterans; DAD: Diffuse Alveolar Damage; OP: Organizing Pneumonia; PPFE: Pleuroparenchymal Fibroelastosis.

nonspecific interstitial pneumonia, and eosinophilic pneumonitis [30]. IPS often occurs earlier than 100 days post HSCT, and often in association with acute GVHD [31], although IPS may also occur beyond 100 days and presumably in association with chronic GVHD [6]. A review of six selected studies revealed that the overall mortality of 388 HSCT recipients with IPS was 74%, ranging between 60–86% and that the 1-year survival was less than 15% [6].

BOOP is a disorder involving bronchioles, alveolar ducts, and alveoli, the lumen of which becomes filled with granulation tissue. BOOP may present with either acute or chronic GVHD [4]. The radiologic findings in BOOP are diffuse or patchy and occasionally migratory “fluffy” consolidations, ground glass opacities, and nodules. BOOP after HSCT is usually more responsive to corticosteroids than BO and the prognosis is generally better than for BO, but potentially lower than for idiopathic BOOP [25]. In one report, 22% of post-HSCT BOOP cases progressed despite corticosteroids, with eventual respiratory failure in the majority of cases [32].

In a recent report, von der Thusen et al described four cases of pulmonary disease following allogeneic bone marrow transplantation that presented with pneumothorax and demonstrated the histopathological signs of PPFE [33], the features of which are indeed similar to those observed in RAS [18].

DISCUSSION

Comparative lessons from lung transplantation and HSCT

As discussed in the section on CLAD after lung transplantation, BO/BOS was long been believed to be the representative form of chronic rejection. Indeed, there is sufficient evidence to claim that BO is a relatively specific finding to such immune-mediated chronic lung injury. However, careful clinical and pathological examination has revealed that the apparently “non-specific” features of chronic lung injury such as DAD, Organizing Pneumonia (OP), and peripheral lung fibrosis have a significant impact on patient survival. Successful separation of the clinical phenotypes of CLAD into BOS and RAS using pulmonary function tests reflects an important pathological question with respect to the focus of inflammation and tissue remodeling in CLAD and further addresses clinicians’ critical questions regarding the clinical course and patient prognosis.

Another important finding in RAS is that BO lesions are also usually observed in the explanted lungs of these patients [5] (Figure 3), suggesting that an immune-mediated process is also involved in this phenotype of CLAD [12]. Therefore, although the “non-specific” findings in peripheral lung tissue observed in RAS have been apt to be elusive in discussions of chronic rejection after lung transplantation both clinically and experimentally, now is the time to shift the focus of investigation to include this important pattern of lung injury and remodeling.

The same could possibly be true of LONIPCs after HSCT; BO has generally been considered to be the finding specific to chronic pulmonary GVHD [4]; however, this does not necessarily mean that peripheral “non-specific” lung lesions are clinically

less important. Rather, in my impression in viewing many lung-transplant candidates with end-stage post-HSCT pulmonary complications with the diagnosis of BO/BOS, many of these patients have evident involvement of peripheral lung tissue on CT scan, and indeed these lesions play critical roles in symptoms and progression of the disease as seen in thoracic air leakage syndrome [34] (Figure 4). Furthermore, once such patients undergo lung transplantation, the pathological findings of explanted native lung tissue frequently include both BO lesions and peripheral lung fibrosis, typically a fibrous non-specific interstitial pneumonia pattern. This admixture of the pathological processes both in small airways and peripheral lung tissue resembles what is seen RAS after lung transplantation.

Currently BOOP is considered to represent chronic GVHD affecting peripheral lung tissue [4,6]; however, it is also possible that many patients with the diagnosis of BO/BOS after HSCT also have peripheral lung tissue involved and such a pathological process in peripheral lung tissue is truly important in determining patients’ prognosis. If BOOP represents chronic GVHD, the focus of investigation in chronic pulmonary GVHD should not be limited to BO and rather, should focus more on the peripheral lung pathology. Also, given the clinicopathological similarities between CLAD after lung transplantation and LONIPCs after HSCT, investigation across the two fields (both at laboratory and clinical levels) should be facilitated to better understand the interesting and important clinical phenomena occurring in the lung in association with transplantation.

CONFLICT OF INTEREST

The author declares that there are no conflicts of interest and no financial support was received for this study.

REFERENCES

1. Stehlik J, Edwards LB, Kucheryavaya AY, Benden C, Christie JD, Dipchand AI, et al. The Registry of the International Society for Heart and Lung Transplantation: 29th official adult heart transplant report--2012. *J Heart Lung Transplant*. 2012; 31: 1052-1064.
2. Palmas A, Tefferi A, Myers JL, Scott JP, Swensen SJ, Chen MG, et al. Late-onset noninfectious pulmonary complications after allogeneic bone marrow transplantation. *Br J Haematol*. 1998; 100: 680-687.
3. Sato M. Chronic lung allograft dysfunction after lung transplantation: the moving target. *Gen Thorac Cardiovasc Surg*. 2013; 61: 67-78.
4. Filipovich AH, Weisdorf D, Pavletic S, Socie G, Wingard JR, Lee SJ, et al. National Institutes of Health consensus development project on criteria for clinical trials in chronic graft-versus-host disease: I. Diagnosis and staging working group report. *Biol Blood Marrow Transplant*. 2005; 11: 945-956.
5. Sato M, Waddell TK, Wagnetz U, Roberts HC, Hwang DM, Haroon A, et al. Restrictive allograft syndrome (RAS): a novel form of chronic lung allograft dysfunction. *J Heart Lung Transplant*. 2011; 30: 735-742.
6. Afessa B, Litzow MR, Tefferi A. Bronchiolitis obliterans and other late onset non-infectious pulmonary complications in hematopoietic stem cell transplantation. *Bone Marrow Transplant*. 2001; 28: 425-434.
7. Pakhale SS, Hadjiliadis D, Howell DN, Palmer SM, Gutierrez C, Waddell TK, et al. Upper lobe fibrosis: a novel manifestation of chronic allograft dysfunction in lung transplantation. *J Heart Lung Transplant*. 2005; 24: 1260-1268.
8. Woodrow JP, Shlobin OA, Barnett SD, Burton N, Nathan SD.

- Comparison of bronchiolitis obliterans syndrome to other forms of chronic lung allograft dysfunction after lung transplantation. *J Heart Lung Transplant.* 2010; 29: 1159-1164.
9. Estenne M, Maurer JR, Boehler A, Egan JJ, Frost A, Hertz M, et al. Bronchiolitis obliterans syndrome 2001: an update of the diagnostic criteria. *J Heart Lung Transplant.* 2002; 21: 297-310.
 10. Stewart S, Fishbein MC, Snell GI, Berry GJ, Boehler A, Burke MM, et al. Revision of the 1996 working formulation for the standardization of nomenclature in the diagnosis of lung rejection. *J Heart Lung Transplant.* 2007; 26: 1229-1242.
 11. Vanaudenaerde BM, Meyts I, Vos R, Geudens N, De Wever W, Verbeken EK, et al. A dichotomy in bronchiolitis obliterans syndrome after lung transplantation revealed by azithromycin therapy. *Eur Respir J.* 2008; 32: 832-843.
 12. Verleden GM, Raghu G, Meyer KC, Glanville AR, Corris P. A new classification system for chronic lung allograft dysfunction. *J Heart Lung Transplant.* 2014; 33: 127-133.
 13. de Jong PA, Vos R, Verleden GM, Vanaudenaerde BM, Verschakelen JA. Thin-section computed tomography findings before and after azithromycin treatment of neutrophilic reversible lung allograft dysfunction. *Eur Radiol.* 2011; 21: 2466-2474.
 14. Glanville AR, Aboyoun CL, Havryk A, Plit M, Rainer S, Malouf MA. Severity of lymphocytic bronchiolitis predicts long-term outcome after lung transplantation. *Am J Respir Crit Care Med.* 2008; 177: 1033-1040.
 15. Yousem SA. Lymphocytic bronchitis/bronchiolitis in lung allograft recipients. *Am J Surg Pathol.* 1993; 17: 491-496.
 16. Verleden GM, Vos R, Verleden SE, De Wever W, De Vleeschauer SI, Willems-Widyastuti A, et al. Survival determinants in lung transplant patients with chronic allograft dysfunction. *Transplantation.* 2011; 92: 703-708.
 17. Sato M, Ohmori-Matsuda K, Saito T, Matsuda Y, Hwang DM, Waddell TK, Singer LG. Time-dependent changes in the risk of death in pure bronchiolitis obliterans syndrome (BOS). *J Heart Lung Transplant.* 2013; 32: 484-491.
 18. Ofek E, Sato M, Saito T, Wagnetz U, Roberts HC, Chaparro C, et al. Restrictive allograft syndrome post lung transplantation is characterized by pleuroparenchymalfibroelastosis. *Mod Pathol.* 2013; 26: 350-356.
 19. Sato M, Hwang DM, Ohmori-Matsuda K, Chaparro C, Waddell TK, Singer LG, et al. Revisiting the pathologic finding of diffuse alveolar damage after lung transplantation. *J Heart Lung Transplant.* 2012; 31: 354-363.
 20. Verleden SE, de Jong PA, Ruttens D, Vandermeulen E, van Raemdonck DE, Verschakelen J, et al. Functional and computed tomographic evolution and survival of restrictive allograft syndrome after lung transplantation. *J Heart Lung Transplant.* 2014; 33: 270-277.
 21. Sato M, Hwang DM, Waddell TK, Singer LG, Keshavjee S. Progression pattern of restrictive allograft syndrome after lung transplantation. *J Heart Lung Transplant.* 2013; 32: 23-30.
 22. Sakaida E, Nakaseko C, Harima A, Yokota A, Cho R, Saito Y, et al. Late-onset noninfectious pulmonary complications after allogeneic stem cell transplantation are significantly associated with chronic graft-versus-host disease and with the graft-versus-leukemia effect. *Blood.* 2003; 102: 4236-4242.
 23. Yokoi T, Hirabayashi N, Ito M, Uno Y, Tsuzuki T, Yatabe Y, et al. Broncho-bronchiolitis obliterans as a complication of bone marrow transplantation: a clinicopathological study of eight autopsy cases. Nagoya BMT Group. *Virchows Arch.* 1997; 431: 275-282.
 24. Ryu JH, Myers JL, Swensen SJ. Bronchiolar disorders. *Am J Respir Crit Care Med.* 2003; 168: 1277-1292.
 25. Yoshihara S, Yanik G, Cooke KR, Mineishi S. Bronchiolitis obliterans syndrome (BOS), bronchiolitis obliterans organizing pneumonia (BOOP), and other late-onset noninfectious pulmonary complications following allogeneic hematopoietic stem cell transplantation. *Biol Blood Marrow Transplant.* 2007; 13: 749-759.
 26. Clark JG, Crawford SW, Madtes DK, Sullivan KM. Obstructive lung disease after allogeneic marrow transplantation. Clinical presentation and course. *Ann Intern Med.* 1989; 111: 368-376.
 27. Yousem SA. The histological spectrum of pulmonary graft-versus-host disease in bone marrow transplant recipients. *Hum Pathol.* 1995; 26: 668-675.
 28. Clark JG, Hansen JA, Hertz MI, Parkman R, Jensen L, Peavy HH. NHLBI workshop summary. Idiopathic pneumonia syndrome after bone marrow transplantation. *Am Rev Respir Dis.* 1993; 147: 1601-1606.
 29. Kantrow SP, Hackman RC, Boeckh M, Myerson D, Crawford SW. Idiopathic pneumonia syndrome: changing spectrum of lung injury after marrow transplantation. *Transplantation.* 1997; 63: 1079-1086.
 30. Panoskaltzis-Mortari A, Griese M, Madtes DK, Belperio JA, Haddad IY, Folz RJ, et al. An official American Thoracic Society research statement: noninfectious lung injury after hematopoietic stem cell transplantation: idiopathic pneumonia syndrome. *Am J Respir Crit Care Med.* 2011; 183: 1262-1279.
 31. Cooke KR, Yanik G. Acute lung injury after allogeneic stem cell transplantation: is the lung a target of acute graft-versus-host disease? *Bone Marrow Transplant.* 2004; 34: 753-765.
 32. Freudenberger TD, Madtes DK, Curtis JR, Cummings P, Storer BE, Hackman RC. Association between acute and chronic graft-versus-host disease and bronchiolitis obliterans organizing pneumonia in recipients of hematopoietic stem cell transplants. *Blood.* 2003; 102: 3822-3828.
 33. von der Thüsen JH, Hansell DM, Tominaga M, Veys PA, Ashworth MT, Owens CM, et al. Pleuroparenchymal fibroelastosis in patients with pulmonary disease secondary to bone marrow transplantation. *Mod Pathol.* 2011; 24: 1633-1639.
 34. Vogel M, Brodoefel H, Bethge W, Faul C, Hartmann J, Schimmel H, et al. Spontaneous thoracic air-leakage syndrome in patients following allogeneic hematopoietic stem cell transplantation: causes, CT-follow up and patient outcome. *Eur J Radiol.* 2006; 60: 392-397.

Cite this article

Sato M (2014) Chronic Lung Allograft Dysfunction After Lung Transplantation and Late Onset Non-infectious Pulmonary Complications After Hematopoietic Stem Cell Transplantation: Are they Mirror Images? *Clin Res Pulmonol* 2(1): 1014.