SciMedCentral

Clinical Research in Pulmonology

Case Report

Thoraco-Abdominal Hydatidosis by Contiguous Dissemination: A Case Report

El Khattabi W[1,2], Nahidi M[1,2]*, Arfaoui H[1,2], Cherkaoui R[1,2], Jabri H[1,2], and Afif MH[1,2]

[1]Department of Pneumology, 20 August 1953, Morocco

[2]Faculty of Medicine and Pharmacy of Casablanca, University Hassan II Casablanca, Morocco

*Corresponding author

Nahidi M, Department of Pneumology, 20 August 1953, Casablanca, Morocco, Tel: 00212766730961

Submitted: 28 November 2022

Accepted: 22 December 2022

Published: 26 December 2022

ISSN: 2333-6625

Copyright

© 2022 El Khattabi W, et al.

OPEN ACCESS

Keywords

- Thoraco-Abdominal Hydatidosis; Parasitic infection; Contiguous dissemination; Albendazole

Abstract

Background: Hydatidosis is a parasitic infection that is still frequent in the world, especially in the Mediterranean area and in breeding regions such as Morocco. The management of complicated hydatid cysts remains delicate, especially in the case of intrapleural rupture, with a high risk of intraoperative swarming and of local, regional and distant recurrence, which modifies the prognosis. This case of dissemination by contiguity is one of the rarest presentations.

Case presentation: This is a case report of a 29-year-old Moroccan patient, operated 8 years before for a left pulmonary hydatid cyst ruptured in the pleura and bronchi without immediate postoperative complications who presented with respiratory symptomatology revealing an almost exclusive left thoracoabdominal hydatidosis with diaphragmatic involvement The diagnosis was retained on several clinical, biological and radiological grounds. The almost exclusive left involvement pleads for a dissemination by contiguity entering the case of a diffuse hydatidosis whose treatment is medical. The evolution is marked few months later by the death of the patient by respiratory distress.

Conclusion: Contiguous dissemination of the pulmonary hydatid cyst is a rare but possible situation which requires careful peroperatory manipulation of the hydatid cyst content, the adoption of surgical methods with the lowest risk of recurrence and complications, and an adjuvant medical treatment with albendazole. Patients education on the importance of adherence to treatment and follow-up is fundamental.

INTRODUCTION

Hydatidosis is a cosmopolitan anthropozoonosis due to the larval form of a parasite of the cestode family called Echinococcus granulosus. It is a parasitic infection that remains frequent in the world, mainly in the Mediterranean area and in the breeding regions of some countries such as America, New Zealand, and Australia. Morocco is one of the countries most affected by this pathology [1,2].

The lung is the second most frequent location, i.e. 30% to 40%, after the liver, which accounts for 50 to 60%. However, in 10% of cases the parasite can migrate to any other tissue of the body [3].

The majority of cysts are single, but diffuse forms are possible and exceptional with a high risk of mechanical and infectious complications.

The treatment of pulmonary hydatid cysts is essentially surgical. However, there is a risk of local, regional and distant dissemination.

We report a case of thoracoabdominal hydatidosis by contiguous dissemination.

OBSERVATION

The patient is 29 years old. He is a truck driver, living in a rural environment with cattle and dogs in his surroundings.

He is a chronic smoker weaned eight years ago at 10 packs/year. He underwent surgery in 2014 for a left pyothorax on a ruptured pulmonary hydatid cyst in the pleura which was treated by evacuation of both pyothorax and pulmonary hydatid cyst with pleural decortication. The postoperative course was simple at 3 months and then the patient was lost to follow-up. Moreover, he had no other associated comorbidities.

The patient consulted 8 years after his surgery for a symptomatology dating back 20 days. He reported a left chest pain with heaviness, dyspnea at rest, a dry cough followed by an episode of hydatid vomiting on the day of his consultation (Figure 1). He also reported dysphonia, with feverish sensations, chills, and a decline in general condition.

Respiratory physical examination revealed a fluid effusion syndrome. The rest of the physical examination was normal.

The frontal chest radiograph performed on admission showed multiple rounded opacities giving the appearance of a unilateral balloon release (Figure 2).

The thoracic-abdominal-pelvic CT scan confirmed the presence of multiple contiguous cystic lesions of intra-parenchymal, circumferential pleural, and left mediastinal location, making an imprint on the elements of the mediastinum,

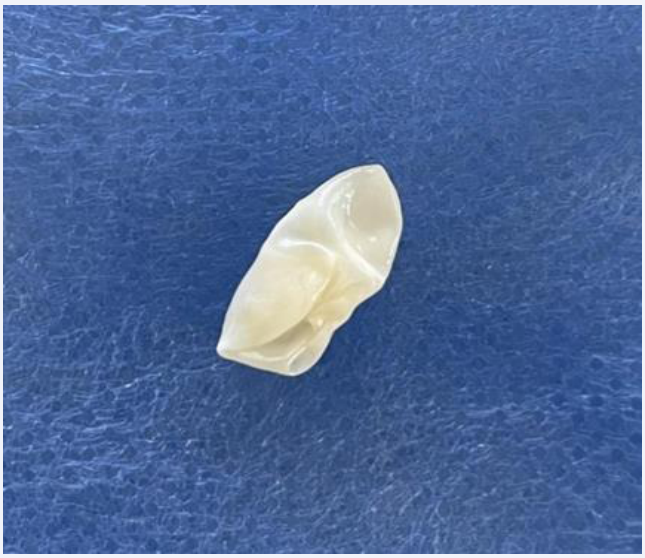

Figure 1 Hydatid membrane released by the patient while coughing.

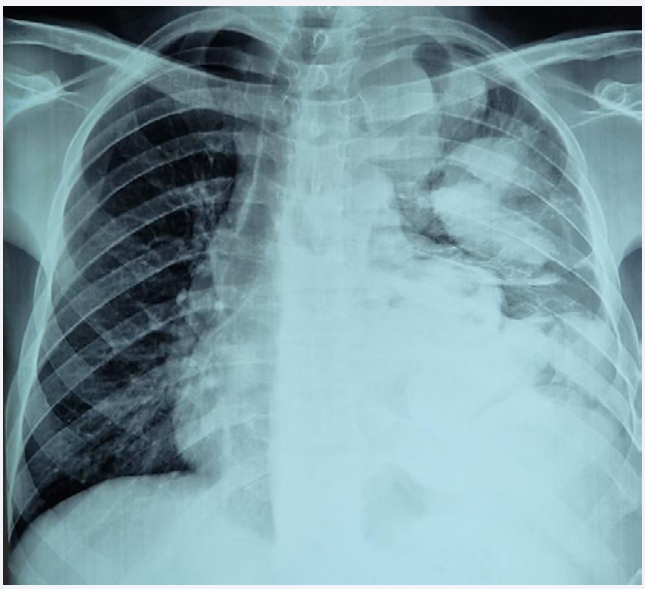

Figure 2 AP chest X-ray: Multiple dense heterogeneous rounded opacities occupying the left hemithorax and describing the appearance of a left balloon release.

including the heart and the aortic arch, which they repressed. They are associated with diaphragmatic involvement. These cystic formations continue into the abdomen in contact with the spleen with a cystic lesion of the sixth segment of the liver classified as Gharbi IV, then reach the back cavity of the epiplonia exerting a mass effect on the pancreas and the splenic artery, and reach the left retroperitoneal space (Figure 3,4).

Spinal cord MRI revealed a cystic foraminal lesion at the level of D11 and D12 confirmation with no detectable intraductal extension (Figure 5). And the cerebral CT was normal.

The blood tests showed a strongly positive hydatid serology by HAI and Western Blot. The rest of the biological workup, including CBC, liver and kidney function tests, as well as lipasemia, was normal.

Flexible bronchoscopy showed extrinsic compression at the entrance of the left main bronchus with diffuse inflammation of the entire bronchial tree, without visible hydatid membranes or other visible abnormalities.

Trans-thoracic echocardiography shows that the cardiac chambers are crushed by the mediastinal cystic component without intra-cavity masses or cysts (Figure 6).

In total, it is a diffuse thoraco-abdominal echinococcosis by contiguous dissemination given the predominance of left involvement intra-abdominal. The treatment in this case remains medical treatment represented by albendazole at a rate of 800mg/day. Unfortunately, the evolution was marked 3 months later by the death of the patient in respiratory distress.

DISCUSSION

The pulmonary hydatid cyst represents 90% of intra thoracic hydatidosis. It may be complicated by superinfection, compression of adjacent organs, fissure, intra-bronchial and intra-pleural rupture. Intrapleural rupture is less common and accounts for only 1.5 to 6% of complications [4-6]. However it stills a rare event that modifies the prognosis of this pathology given the risk of anaphylactic shock and respiratory distress. This risk is increased in case of acute rupture of the KHP. It manifests as pleurisy, pneumothorax or hydropneumothorax [1,5].

In our case, the patient had in 2014 an intrapleural and intrabronchial rupture of a left pulmonary hydatid cyst. The latter was confirmed by the hydatid vomit described by the patient during the interrogation and repeated on the day of his consultation. The diagnosis of pulmonary hydatidosis is based on several arguments, starting with the interrogation, the cornerstone of the diagnostic suspicion, the imaging, mainly represented by the thoracic CT scan and the thoracic ultrasound, as well as the biological examinations, including the hydatid serology, which allows to confirm the diagnosis, and the follow-up.

The treatment of pulmonary hydatid cysts is surgical in the absence of any contraindication and in the absence of generalized echinococcosis. The aim of surgical treatment is the removal of the germinal membrane without causing intraoperative contamination, avoiding the maintenance of any residual intra-pulmonary cystic formation and preserving the respiratory functional capital [7-9].

The surgical management requires a preoperative preparation made of a preoperative check-up in search of a possible contraindication to surgery, a respiratory physiotherapy essentially in complicated KHP [10], an antibiotic therapy in case of suppurated KHP or in case of an associated pneumopathy by superinfection. Pleural drainage is indicated in case of intrapleural rupture.

The most commonly used approach is the posterolateral thoracotomy through the 5th intercostal space. However, other approaches have been described in the literature, in particular axillary or lateral thoracotomy without muscle section,

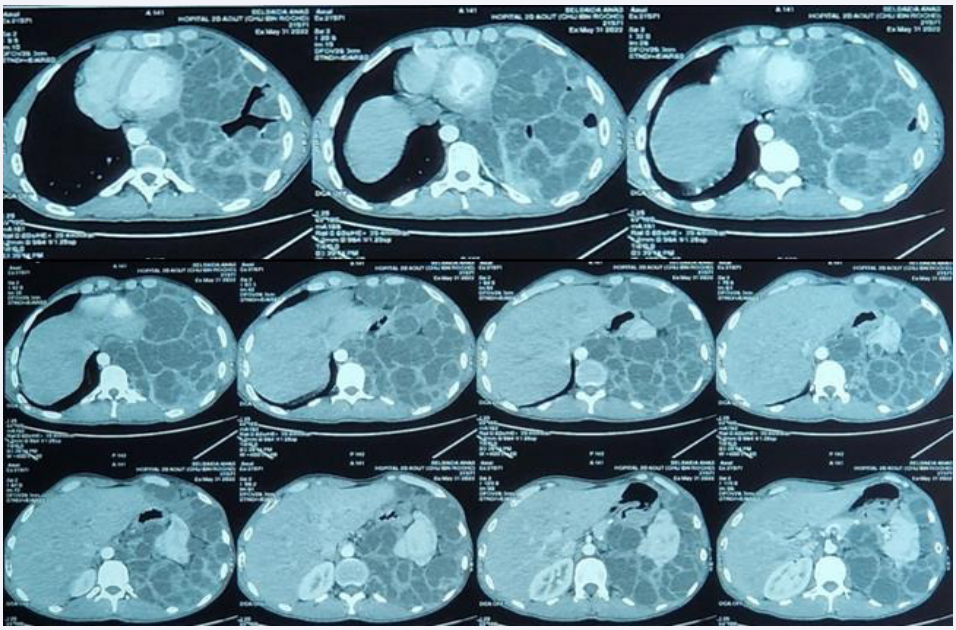

Figure 3 Thoraco-abdominal-pelvic CT: Multiple contiguous cysts of intraparenchymal, pleural, left mediastinal and left intraabdominal location with diaphragmatic involvement.

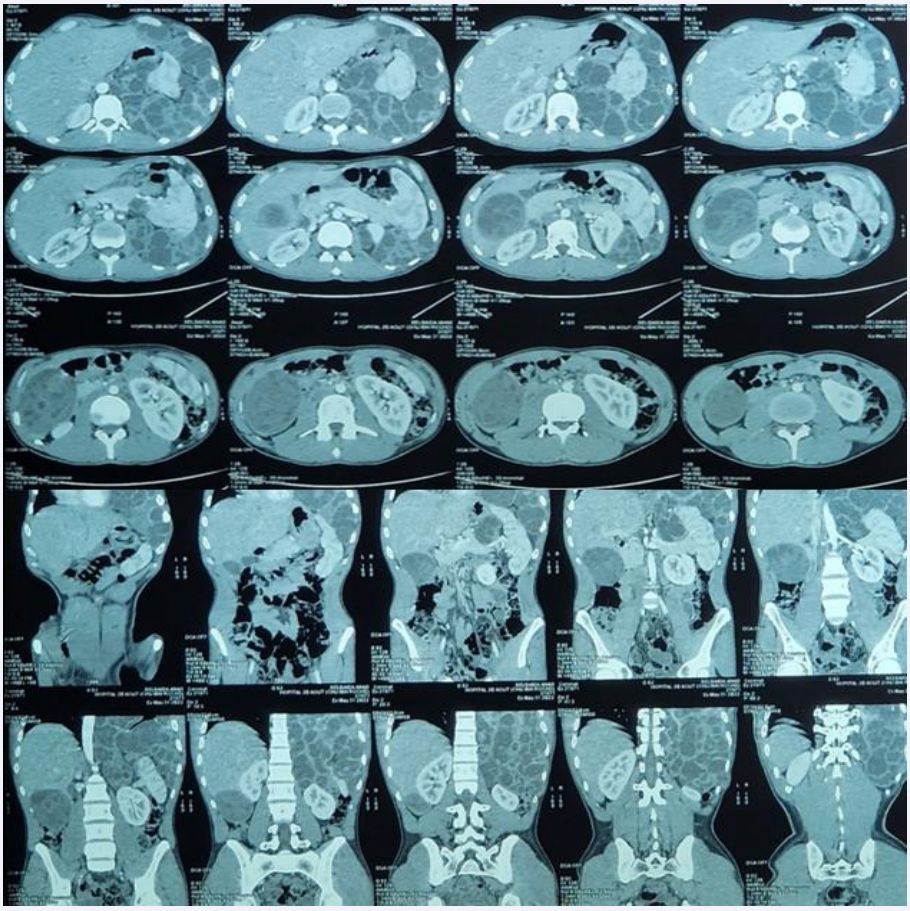

Figure 4 Thoraco-abdominal-pelvic CT: Multiple intra-abdominal cysts in contact with the spleen with a cystic lesion of segment six of the liver classified Gharbi IV, with many cysts at the level of the posterior cavity of the omentums that exert a mass effect on the pancreas and the splenic artery, with cysts in the left retroperitoneal space.

sternotomy in case of associated cardiac localization or in case of bilateral hydatid cysts of the upper lobes, as well as combined approaches including thoraco-laparotomy in case of associated intra-abdominal involvement [11].

Several surgical methods are described, some are conservative others are radical. Conservative treatment is based on cystectomy by different techniques including the Ugon technique and the Barrett technique by aspiration of the cyst contents and removal of the hydatid membrane [12].

In case of complicated pulmonary hydatid cysts with reworked and thickened pericysts pericystectomy is also indicated [13].

The residual cavity is a major problem on which the postoperative course will depend, which explains the interest in treating the residual cavity by blinding the bronchial fistulas with or without capitonnage. However, capitonnage seems to have a positive impact on the quality of the post-operative course.

Radical treatment by, usually partial pulmonary resection (lobectomy, segmental resection), is indicated in cases of pulmonary hydatid cysts with extensive suppuration, in cases of giant hydatid cysts, in the presence of multiple bronchial fistulas, and in cases of destruction of the pulmonary parenchyma [14,15].

New methods have been introduced recently, including treatment by video-assisted thoracic surgery (VATS), which allows simple postoperative procedures and shortens the duration of hospitalization.

Regardless of the surgical method adopted, the risk of surgical dissemination by contiguity is increased in the absence of protection of the operating field. It avoids the spread of the infectious agent and considerably reduces the risk of anaphylactic shock. It requires a scolicide solution such as hydrogen peroxide or 20% hypertonic sodium chloride, or even cetyl trimethylammonium bromide. It is based on 3 major principles [16]:

- Caution when handling the pulmonary hydatid cyst;
- Isolation of the pleura and the rest of the sites with fields impregnated with a scolicide solution;
- Neutralization of the cyst by puncture-aspiration followed by meticulous cleaning of the residual cavity with scolicide solution.

However, the use of scolicide solution is controversial. According to certain authors, it's responsible of many complications including hydro-electrolytic disorders and pulmonary oedema [17,18].

Although various surgical techniques are described in the literature, the management of ruptured pulmonary hydatid cysts, particularly in the pleura, remains delicate. The most adopted technique stills cystectomy with or without capitonnage, or partial pulmonary resection in case of destruction of the pulmonary parenchyma, with pleural decortication and pleurectomy.

The postoperative course is often simple, but there is a risk

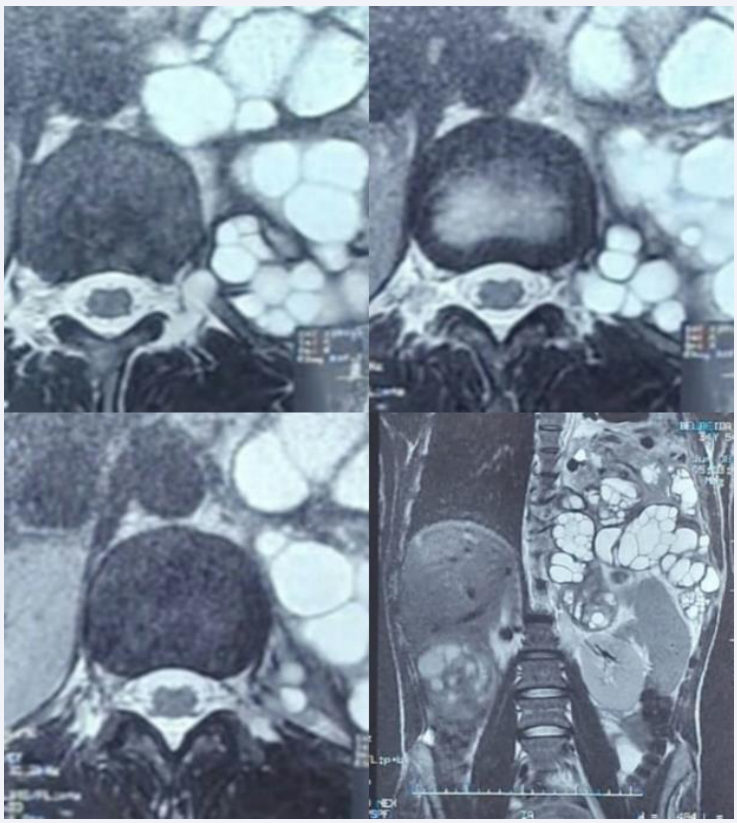

Figure 5 Spinal MRI: Cystic lesion of the conjugate foramina of D11 and D12 vertebral bodies without intra canal extension.

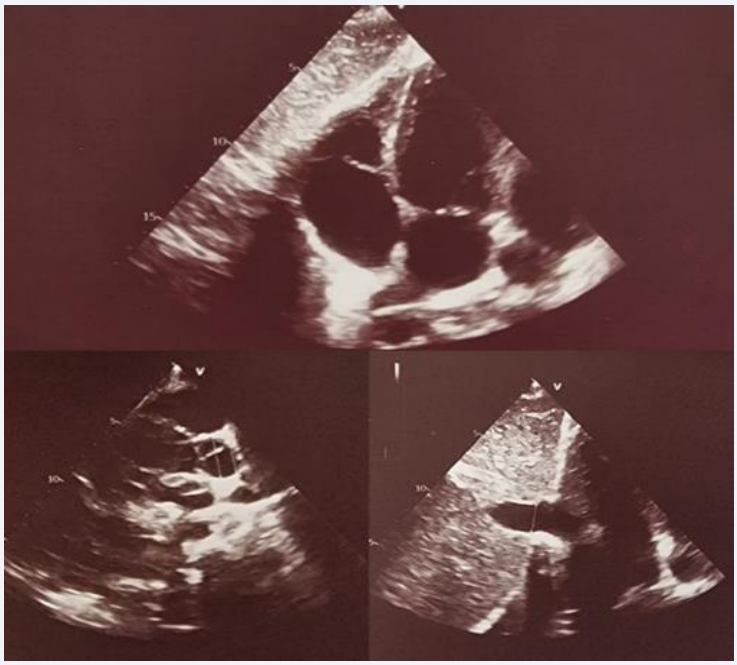

Figure 6 Trans-thoracic echocardiography: Cardiac chambers crushed by the mediastinal cystic component without visible intracavitary lesions.

of medium and long-term post-surgical complications that do not exceed 10% [12].

The most common complications are bronchial congestion, pneumonia, atelectasis, aspergillosis or neoplastic grafting on a persistent residual cavity, bronchiectasis, bronchial fistula, parietal suppuration, hemothorax, pyopneumothorax, pachypleuritis, and recurrence.

Recurrence of hydatid cyst is not exceptional and can reach up to 22% in 5 years [19]. The frequency of recurrence varies according to the series.

Recurrence of hydatid cysts can be local at the surgical site, regional or distant. The main causes of recurrence seem to be microscopic swarming of the parasite during surgery, inability to eliminate all cysts, especially the most inaccessible ones, incomplete pericystectomy and maintenance of a residual cystic during surgery.

The therapeutic efficacy cannot be judged in the short term as recurrence may occur several years later. There are two types of recurrence. Early recurrence occurs within 18 months postoperatively, while late recurrence requires an interval of 3 years at least.

It is agreed that adjuvant antiparasitic treatment should be maintained for a period of 6 months with close clinical, radiological and biological follow-up for a period of 4 years at least. It is also recommended to avoid intraoperative spillage of hydatid cyst material, by surgical field protection and total removal of the hydatid cyst. Inactivation by puncture, aspiration, injection, re-aspiration (PAIR), antiparasitic chemotherapy, seem to be modern methods to reduce the rate of recurrence and intraoperative dissemination [19].

In our case, although we do not have a detailed operative report, the patient was treated by puncture-evacuation of the hydatid cyst, evacuation of the pyothorax with pleural decortication. However, the predominance of lesions on the side of the initial attack and at the surgical site is in favor of a local recurrence complicated by contiguous spread to the mediastinum and then to the abdomen homolaterally while crossing the diaphragm. This could be due to intraoperative parasite dissemination, and the absence of postoperative follow-up, the lack of education about the risk of recurrence and the importance of medium and long term follow-up.

CONCLUSION

Through our case, we underline that the pulmonary hydatid cyst requires an early diagnosis and a well conducted surgical management in order to avoid the risk of postoperative complications. Recurrence of pulmonary hydatid cysts is not exceptional and can be responsable for a generalized echinococcosis with an unfortunate prognosis.

Dissemination by contiguity is more likely when the involvement is strictly homolateral to the initial surgical site. It may be due to several intraoperative and postoperative factors, which explains the interest in adopting surgical techniques that are less likely to cause complications, the use of surgical field protection, the maintenance of adjuvant antiparasitic treatment for at least 6 months, and armed follow-up in the short, medium and long term.

REFERENCES

1. El Khattabi W, Aichane A, Riah A, Jabri H, Afif H, Bouayad Z. Analyse de la sémiologie radioclinique du kyste hydatique pulmonaire. Revue de Pneumologie Clinique. 2012; 68: 329-337.
2. Amro L, Fadili SE, Serhane H, Sajiai H, Batahar SA. Hydatidose multiple

à localisation inhabituelle, pancréatique et pelvienne : à propos d'un cas. Pan African Med J. 2017.

3. Diallo S, Toloba Y, Dao S, Sidibe Y, Sissoko BF, Gomez P, et al. HYDATIDOSE MULTIPLE A PROPOS D'UNE OBSERVATION AU MALI .Mali Médical. 2005.

4. Kuzucu A, Ulutas H, Reha Celik M, Yekeler E. Hydatid cysts of the lung: lesion size in relation to clinical presentation and therapeutic approach. Surg Today. 2013; 44: 131-136.

5. Bouchikh M, Achir A, Maidi M, Ouchen F, Fenane H, Benosman A. La rupture intrapleurale des kystes hydatiques pulmonaires. Revue de Pneumologie Clinique. 2014; 70: 203-207.

6. Racil H, Ben Amar J, El Filali Moulay R, Ridene I, Cheikrouhou S, Zarrouk M, et al. Kystes hydatiques compliqués du poumon. Revue Des Maladies Respiratoires. 2009; 26: 727-734.

7. Solak H, Ceran S, Ozpinar C, Yeniterzi M, Yuksek T, Sunam GS, et al. Lung hydatid cyst rupture and its surgery. Indian J Med Sci. 1994; 48: 155-157.

8. Anshuman Darbari, Raja Lahiri, Mayank Mishra, Ajay Kumar, Sandeep Gautam, Navin Kumar. Management of Pulmonary Hydatid Cyst with Pleural Complications: A Case Series. Eur Med J. 2021.

9. Deus fombellida et coll. Aspects chirurgicaux de l'hydatidose pulmonaire infantile à propos d'une série de 107 cas Ann.Chir.Chir Thorac Cardio-Vasc. 1982; 36: 701-711

10. Ben Jemaa M, Marrakchi C, Maaloul I, Mezghanni S, Khemakhem B, Ben Arab N, et al. Traitement médical du kyste hydatique : évaluation de l'albendazole chez 3 patients (22 kystes)Medical treatment of hydatid cysts: activity of albendazole in three patients (22 cysts) Médecine et Maladies Infectieuses. 2002; 32: 514-518.

11. Barrett NR, Thomas D. Pulmonary hydatid disease. Br J Surg. 1952; 40: 22-44.

12. Rifki-Jai S, Belmahi A. Le traitement chirurgical du kyste hydatique du poumon. Maghreb Med. 2001; 21: 192-195.

13. OZCELIK C, INCI.I ET COLL. Surgical treatment of pulmonary hydatid cysts (92 patients) J Chir. 1994; 29: 392-395.

14. BISSON A, LEROY M. Traitement chirurgical des KHP. EMC (Paris France) techniques chir Thorax. 1995; 42: 8.

15. QIAN ZX. Thoracic hydatid cysts: a report of 842 cases treated over a thirty year period Ann Thorac Surg. 1988; 46: 342-346.

16. Jougon J, Delcambre F, Velly JF. Voies d'abord chirurgicales antérieures du thorax Encyclopédie Médico-Chirurgicale. 2004; 42-210.

17. SAINT FLORENT Hydatidose pulmonaire. Rev.Pneumol.Clin. 1989; 45: 47-48.

18. Manouchehr Aghajanzadeh, Ehsan Hajipour Jafroudi, Ali Alavi Foumani, Alireza Jafarnejad, Azita Tangestaninejad, Yousha Pourahmadi, et al. Postoperative recurrence of cystic hydatidosis: Management and outcome Int J Life Sci. 2022; 10: 101-108.

19. LETAIEF.R ET COLL. Le KHP chez l'enfant à propos d'une série de 162 cas traités chirurgicalement Tunisie Méd. 1990; 68: 167-171.