

## Short Communication

# Intracranial Tumors in Neurofibromatosis Type 2: A Review of Magnetic Resonance Findings

Swetha Pedavally<sup>1</sup> and Matthew Folorunso Omojola<sup>2</sup><sup>1</sup>Department of Neurology, University of Nebraska Medical Center, USA<sup>2</sup>Department of Radiology, University of Nebraska Medical Center, USA

## Corresponding author

Swetha Pedavally, Department of Neurology, University of Nebraska Medical Center, Omaha, NE, 68198, Email: Swetha.pedavally@unmc.edu

Submitted: 15 January 2014

Accepted: 18 February 2014

Published: 28 February 2014

ISSN: 2333-7095

## Copyright

© 2014 Swetha et al.

OPEN ACCESS

## Keywords

- Neurofibromatosis
- Meningioma
- Schwannoma
- Tumor

## Abstract

**Objective:** Our main aim is to present an index case of an 11-year-old female with NF 2 who has intra cranial bilateral vestibular schwannomas, bilateral trigeminal schwannomas, bilateral facial schwannoma, and intra ventricular meningioma and to demonstrate the longitudinal growth of the tumors over time. We also review the literature regarding intracranial masses and their pattern in NF2.

**Background:** Defining intracranial features of NF 2 is bilateral vestibular schwannomas which are present in 90 to 95% of NF 2. Schwannomas involving other cranial nerves are seen only in 24 to 51% of NF 2. Our literature search did not yield any cases of both bilateral vestibular schwannomas and bilateral trigeminal schwannomas together in the same patient.

**Design:** This is a thorough review of a case of NF 2 presenting the history, physical examination and intra cranial magnetic resonance imaging findings with particular attention to longitudinal growth of the tumors.

**Results:** Bilateral vestibular schwannomas, bilateral trigeminal schwannomas and intra ventricular meningioma were noted to grow exponentially over a period of 7 years from tiny lesions to large lobulated masses in the IAC and CP angles, Meckel caves and within the right lateral ventricle respectively with surrounding brain parenchymal mass effect. We review other intracranial masses in NF 2 though not present in our patient.

**Conclusions:** Bilateral vestibular schwannomas are the hallmark of NF 2. Bilateral trigeminal schwannomas can also be seen in a few patients along with other intracranial tumors. However presence of bilateral vestibular and trigeminal schwannomas in the same patient has not been previously described.

## ABBREVIATIONS

NF 2: Neurofibromatosis type 2; MRI: Magnetic Resonance Imaging; NF: Neurofibromatosis; T1WI: T1 Weighted Image; T2WI: T2 Weighted Image

## INTRODUCTION

Neurofibromatosis type 2 is a rare disorder, which results from mutations in the NF2 tumor suppressor gene located on chromosome 22q12 [1]. This is the same chromosomal abnormality found in spontaneous spinal schwannomas. The incidence of NF2 is reported around 1 in 33,000 to 40,000 [2,3]. Both the genders are equally affected [4]. It usually manifests in the second decade of life. Bilateral vestibulo-

cochlear schwannomas are the most common tumor associated with NF2 and around 10% of patients with bilateral vestibular schwannomas have NF2. Affected individuals can develop schwannomas in other spinal, peripheral and cranial nerves. Other nervous system tumors associated with this disorder include meningiomas, ependymomas, astrocytomas, gliomas and rarely neurofibromas. In this article we present an index case of NF 2 with bilateral vestibular and trigeminal schwannomas and intraventricular meningioma and aim mainly to focus on magnetic resonance imaging pattern and growth of intracranial neoplasms in this disease.

## MATERIALS AND METHODS

This is an 11-year-old Caucasian right handed female who

presented to our institution to establish care for her NF type 2 diagnosed at an outside facility. She has a history of mild headaches. Physical examination showed hypo-pigmented skin lesions over right shoulder and back of her legs. She is scoliotic and has normal hearing.

Audiometric exam showed normal bilateral hearing. Brain MRI imaging showed bilateral homogeneously contrast enhancing masses in the internal auditory canals with bilateral meatal protrusions consistent with bilateral vestibular schwannomas that grew over time from a volume of 202.42 mm<sup>3</sup> (Right), 45.38 mm<sup>3</sup> (left) in 2005 to volume of 2284.63mm<sup>3</sup> (Right) and 2219.14 mm<sup>3</sup> (Left) in 2013 (Figures 1 A and B). The average growth rate of these vestibular schwannomas per year is 260.277 mm<sup>3</sup> on the right and 271.72 mm<sup>3</sup> on the left. Her MRI in 2013 also showed a foramen ovale schwannoma, which was not present in 2005. It measured about 107.70 mm<sup>3</sup>. The average growth rate of this schwannoma per year is 13.46 mm<sup>3</sup>.

There were also bilateral trigeminal contrast enhancing masses which also grew substantially over a period of years from 48.26 mm<sup>3</sup> (Right) 42.21 mm<sup>3</sup> (Left) in 2005 to 611.5 mm<sup>3</sup> (Right) and 389.61 mm<sup>3</sup> (Left) in 2013 (Figure 2 A and B). The average growth rate of these trigeminal schwannomas per year is 70.40 mm<sup>3</sup> on the right and 43.42 mm<sup>3</sup> on the left.

A growing right lateral ventricular avidly contrast enhancing mass with perilesional parenchymal edema was eventually removed and proved to be an intraventricular meningioma (Figure 4A). This intraventricular meningioma also grew substantially from a volume of 1479.55 mm<sup>3</sup> in 2005 to 12800.95 mm<sup>3</sup> in 2009 (Figure 3A and B). The average growth rate of this tumor per year is estimated to be 2830.35 mm<sup>3</sup>.

The imaging findings of bilateral vestibular and trigeminal schwannomas, intra ventricular meningioma supports the diagnosis of NF 2 in the settings of NF 2 family history and other associated non tumoral intracranial findings and peripheral neural tumor. The most recent MR images in this patient also shows right side geniculate ganglion tumor presumably schwannoma (Figure 5).

## RESULTS AND DISCUSSION

Clinical presentations of NF 2 depend on the type and anatomical location of the intracranial lesions. According to a large reported case series of 63 patients by Parry DM et al and 83 patients by Fisher LM et al 90 to 95% of patients had bilateral vestibular schwannomas, 24 to 51% had schwannomas involving other cranial nerves commonly the trigeminal nerves (CN V), 45 to 58% had intracranial meningiomas, 63 to 90% had spinal tumors of which 55 to 90% were extra medullary and 18-53% were intra medullary [5,6].

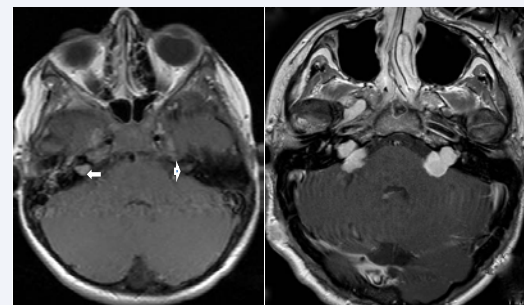
Often the first clinical sign in NF2 is a sudden hearing loss due to the development of bilateral or unilateral vestibular schwannomas. Other symptoms are deafness, tinnitus, dizziness and imbalance. Sometimes it can present as Bell's palsy from mononeuropathy affecting the facial nerve, which does not fully recover. Some children present with a polio like illness with wasting of muscle groups in a lower limb, which again does not fully recover. Meningiomas which are avidly contrast enhancing iso-intense extra axial masses produce clinical symptoms related

to their size and anatomical location like headaches and seizures. Presence of CSF space obstruction may produce hydrocephalus with evidence of raised intracranial pressure. Ependymomas in NF 2 are usually spinal intramedullary lesions. They could be intraventricular or parenchymal in location. They are usually complex heterogeneous contrast enhancing masses.

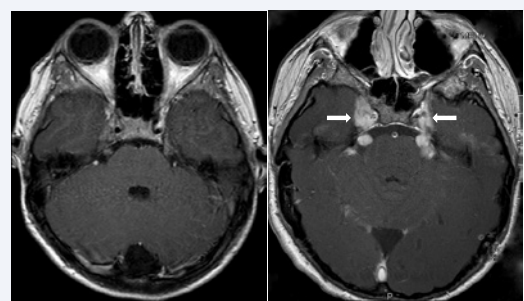
Diagnosis: NF type 2 can be diagnosed when the mutation in the NF 2 gene is identified or when the Manchester clinical criteria [7] is fulfilled (Table 1). The Manchester clinical criteria are more sensitive than previous diagnostic models, while maintaining a high level of specificity [8].

**Table 1:** Manchester criteria for clinical diagnosis of NF 2. (Adapted from ref 7).

	Additional findings needed for diagnosis
Bilateral vestibular schwannomas	None
Family history	Unilateral vestibular schwannoma or two NF 2 associated lesions (meningioma, glioma, neurofibroma, Schwannoma or cataract).
Unilateral vestibular schwannoma	Two NF 2 associated lesions associated with the disorder (meningioma, glioma, neurofibroma, schwannomas, or cataract)
Multiple meningiomas	Unilateral vestibular schwannoma or two other NF 2 associated lesions (glioma, neurofibroma, schwannomas or cataract)



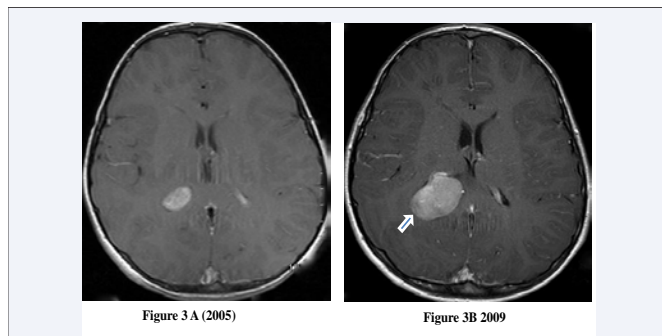
**Figure 1** Axial post contrast MR T1WI showing bilateral avidly contrast enhancing intracanalicular masses protruding into the meatus bilaterally consistent with bilateral vestibular schwannomas (arrows). A right foramen ovale schwannoma is also present in figure 1B (vertical arrow).



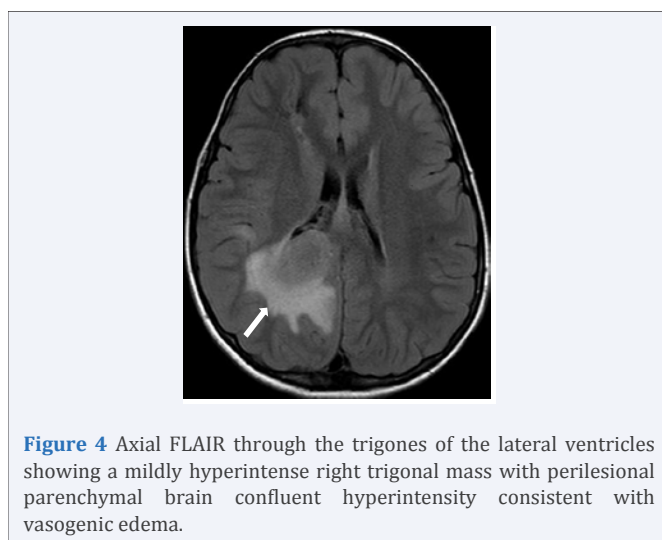
**Figure 2** Axial post contrast MR T1WI through the level of the trigeminal nerves showing bilateral almost symmetrical lobulated thickening of the bilateral trigeminal nerves consistent with bilateral trigeminal schwannomas.

Brain MRI with gadolinium is the gold standard test in terms of diagnostic precision for evaluation of the intracranial tumors. Vestibular schwannomas vividly enhance and are best seen by high-resolution contrast enhanced T1 weighted MRI as in figure 1. Vestibular schwannomas are isointense to hypointense on T1 weighted images and hyperintense on T2 weighted images. Another common finding on MRI is schwannomas of other cranial nerves most commonly of the 3<sup>rd</sup>, 5<sup>th</sup> and 7<sup>th</sup> cranial nerves. T2 weighted or Fluid Attenuated Inversion Recovery (FLAIR) MRI sequences are helpful to demonstrate peritumoral edema and cysts.

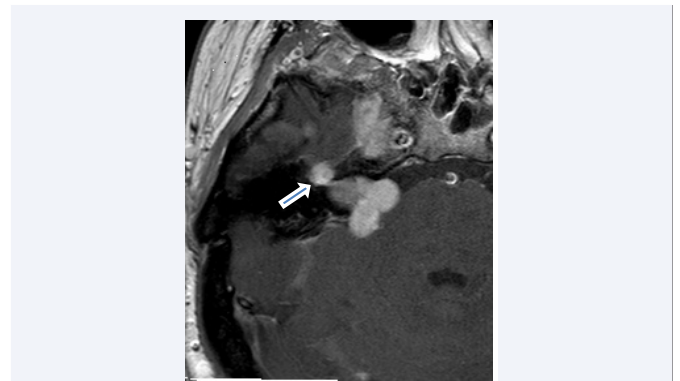
NF2 associated meningiomas are WHO I tumors. However, higher grade meningiomas have been found in resected symptomatic meningiomas. They can easily be detected on MRI as extra axial isointense masses on spin echo sequences with homogeneously avid contrast enhancement on post contrast T1WI. The isointensity on all sequences makes meningioma difficult to detect without contrast administration if they are small. Intracranial ependymomas are also seen in NF2. They are usually low grade tumors and are mainly in the infratentorial region arising from the floor of the 4th ventricle in 60% of the cases seen mainly in children. In the remaining 40% of cases they are supratentorially located. Ependymomas are heterogeneous isointense to hypointense on T1 weighted MRI images and hyperintense on T2WI. Blood or calcification presents as blooming



**Figure 3** Axial post contrast MR T1WI showing right lateral ventricular hyperintense mass.



**Figure 4** Axial FLAIR through the trigones of the lateral ventricles showing a mildly hyperintense right trigonal mass with perilesional brain confluent hyperintensity consistent with vasogenic edema.



**Figure 5** Axial post contrast MR T1WI in 2013 showing right geniculate ganglion tumor presumably schwannoma.

on GRE. Ependymomas show heterogeneous enhancement with contrast. The pattern of growth in these tumors has been described as linear, exponential and salutatory. The rapid growth of the tumors in our case fits more with the exponential growth pattern.

**Management:** Due to the diverse presentations based on the location and type of tumor, management of NF type 2 is by a multidisciplinary approach. It consists of observation, surgery or radiotherapy. Because many of the tumors do not grow for a prolonged period of time and many new tumors arise during the life time of these patients, "wait and watch" approach is a reasonable option initially with only symptomatic tumors treated. This was the treatment option in this patient hence we are able to measure the rate of growth of the tumors. Complete surgical resection is the curative option for vestibular schwannoma as the size and growth rate do not predict hearing status. Overall surgical results for preservation of hearing and facial nerves in NF type 2 even for small tumors have generally been much poorer than is reported. Stereotactic radiotherapy is an option to consider in smaller tumors (generally less than 2.5 cm) or a documented growth in elderly patients. Auditory brainstem implants can offer partial auditory rehabilitation to patients who are deaf. Most intracranial meningiomas are safely and fully resectable except those originating from the optic nerve sheath and skull base, which might be associated with neurological morbidity due to their anatomical location [9]. Symptomatic ependymomas are also removed as appropriate.

## CONCLUSION

Bilateral vestibular schwannomas are common in NF 2 patients, bilateral trigeminal schwannomas can also be seen in a few patients along with other intra cranial tumors. However presence of bilateral vestibular and trigeminal schwannomas in the same patient has not been previously described.

## REFERENCES

1. Wippold FJ, Lubner M, Perrin RJ et al. Neuropathology for the neuroradiologist: Antoni A and Antoni B tissue patterns. *AJNR Am J Neuroradiol.* 2007; 28: 1633-1638.
2. Evans DG, Huson SM, Donnai D, Neary W, Blair V, Teare D, et al. A genetic study of type 2 neurofibromatosis in the United Kingdom.

1. Prevalence, mutation rate, fitness, and confirmation of maternal transmission effect on severity. *J Med Genet.* 1992; 29: 841-846.
3. Mautner VF, Tatagiba M, Lindenau M, Fünsterer C, Pulst SM, Baser ME, et al. Spinal tumors in patients with neurofibromatosis type 2: MR imaging study of frequency, multiplicity, and variety. *AJR Am J Roentgenol.* 1995; 165: 951-955.
4. Baser ME, Evans DG. Lack of sex-ratio distortion in neurofibromatosis 2. *Am J Med Genet.* 2000; 95: 292.
5. Parry DM, Eldridge R, Kaiser-Kupfer MI, Bouzas EA, Pikus A, Patronas N. Neurofibromatosis 2 (NF2): clinical characteristics of 63 affected individuals and clinical evidence for heterogeneity. *Am J Med Genet.* 1994; 52: 450-461.
6. Fisher LM, Doherty JK, Lev MH, Slattery WH 3rd. Distribution of nonvestibular cranial nerve schwannomas in neurofibromatosis 2. *Otol Neurotol.* 2007; 28: 1083-1090.
7. Evans DG, Baser ME, O'Reilly B, Rowe J, Gleeson M, Saeed S, et al. Management of the patient and family with neurofibromatosis 2: a consensus conference statement. *Br J Neurosurg.* 2005; 19: 5-12.
8. Baser ME, Friedman JM, Wallace AJ, Ramsden RT, Joe H, Evans DG. Evaluation of clinical diagnostic criteria for neurofibromatosis 2. *Neurology.* 2002; 59: 1759-1765.
9. Couldwell WT, Fukushima T, Giannotta SL, Weiss MH. Petroclival meningiomas: surgical experience in 109 cases. *J Neurosurg.* 1996; 84: 20-28.

**Cite this article**

Swetha P, Omojola MF (2014) Intracranial Tumors in Neurofibromatosis Type 2: A Review of Magnetic Resonance Findings. *J Radiol Radiat Ther* 2(1): 1026.