

Short Communication

Intensity-Modulated vs. Conformal Radiotherapy after Prostate Seed Implant Brachytherapy Regarding Summed Rectal Dose

Ryuji Nakamura^{1*}, Koyo Kikuchi¹, Satoshi Yamaguchi¹, Hisao Kakuhara¹, Jun Sugawara², Hirobumi Oikawa¹, and Hisanori Ariga¹

¹Department of Radiology, Iwate Medical University, Japan

²Department of Radiology, Iwate Prefectural Chubu Hospital, Japan

***Corresponding author**

Ryuji Nakamura, Department of Radiology, Iwate Medical University, 020-8505 Morioka, Japan, Tel: 81-19-651-5111;

Fax: 81-19-651-0702; Email: makamur@iwate-med.ac.jp

Submitted: 08 December 2016

Accepted: 21 June 2017

Published: 23 June 2017

ISSN: 2333-7095

Copyright

© 2017 Nakamura et al.

OPEN ACCESS**Keywords**

- Prostate cancer
- Brachytherapy
- Rectal bleeding
- Dose-volume histogram

Abstract

Purpose: To disclose effectiveness of substitution of conformal radiotherapy (CRT) with intensity-modulated radiotherapy (IMRT) in combined with ¹²⁵I permanent seed brachytherapy (BT) in reducing a rectal dose-volume parameter recently proven to be correlated with late rectal bleeding after the combined radiotherapy.

Materials/Methods: A CT image set obtained a month after BT was used for CRT and tentative IMRT planning as well as dosimetry of BT (post plan). Physical dose of each DICOM-RT was converted to biologically effective dose under α/β of 3(Gy₃) for three dimensional summation of rectal volume exposed to 150 Gy₃ (rV₁₅₀₍₃₎). Alteration of the value along BT, BT combined with CRT (BT+CRT), and BT combined with IMRT (BT+IMRT) was traced individually, and the mean value were statistically compared between the modalities.

Results: The elevation rate of rV₁₅₀₍₃₎ from BT to BT+CRT is proportional to their rV₁₅₀₍₃₎ of BT. All rV₁₅₀₍₃₎ was decreased from BT+CRT to BT+IMRT except 3 cases with smaller rV₁₅₀₍₃₎ at BT+CRT. The mean rV₁₅₀₍₃₎ values of BT, BT+CRT, and BT+IMRT were 0.06 ± 0.09 cc, 1.41 ± 0.88 , and 1.18 ± 0.75 cc, respectively, showing significant differences between all values.

Conclusions: The substitution of CRT with IMRT in conjunction with seed implant brachytherapy reduces the rectal dose predisposing bleeding. Avoiding rectal exposure to high doses during BT is important even in BT+IMRT.

ABBREVIATION

IMRT: Intensity-Modulated Radiotherapy; CRT: Conformal Radiotherapy; BT: Brachytherapy; OPC: Organ-confined Prostate Cancer; EBRT: External Beam Radiotherapy; DVH: Dose-volume Histogram; DICOM-RT: Digital Imaging and Communication in Medicine in Radiotherapy; RTP: Radiotherapy Treatment Planning; CTV: Clinical Target Volume; PTV: Planning Target Volume; BED: Biologically Effective Dose

INTRODUCTION

A combination of seed implant brachytherapy (BT) and external beam radiotherapy (EBRT) has become a standard option for intermediate- or high-risk organ-confined prostate cancer (OCP) [1,2] with favorable outcomes in biochemical control rates [3,4]. However, the combined radiotherapy has been associated with an increased probability of rectal morbidities compared to either modality alone [5,6]. To avoid toxicity, three-dimensional conformal radiotherapy (CRT) has been replaced by

intensity-modulated radiotherapy (IMRT) as the EBRT portion of the combined radiotherapy. However, the substitution showed relatively limited effects in the reduction of rectal bleeding rate: from 15% to 9% [7] or 11% to 7% [8]. Rectal dose-volume histogram (DVH) indices in treatment planning system (TPS) have been correlated with the frequency of rectal bleeding. They are rectal volumes exposed to doses from 50 to 77 Gy in EBRT for OCP [9-11], or to the prescription dose (rV₁₀₀) calculated using computed tomography (CT) images obtained 1 month after seed implant (post plan) in BT [12,13]. In the combined radiotherapy, a rectal dose delivered by BT is superimposed to a summed dose during subsequent EBRT, which has been shown to substantially determine the probability of rectal bleeding. We preliminarily examined the efficacy of substituting CRT with IMRT in decreasing the rectal dose presumed to be predisposing bleeding.

MATERIALS AND METHODS**DICOM-RT sets**

Between June 2006 and April 2011, 64 OCP patients

underwent BT and CRT under a protocol approved by the institutional review board of Iwate Medical University Hospital. A CT image set obtained a month after BT was used for CRT planning as well as dosimetry of BT (post plan). The top 20 pairs of BT post plan and CRT plan were selected based on large rV_{100} values following BT treatment.

BT

^{125}I free seeds (0.28–0.335 mCi; Source Tec ^{125}I NIST99; Bard, NJ) were implanted by using a Mick applicator system (Mick Radio nuclear Instruments, New York, USA). Real-time interactive seed insertion was optimized using BT-TPS (Variseed version 7.2; Varian Medical Systems, Palo Alto, CA) to consider dose constraints of pD_{90} (the dose covering 90% of the prostate volume) >110 Gy, pV_{100} (% prostate volume exposed to 110 Gy) >95%, pV_{150} (% prostate volume exposed to 165 Gy) <60%, and rV_{100} (rectal volume exposed to 110 Gy) <1.0 cc.

BT post plan

CT (Aquillion; Toshiba, Tokyo, Japan) images with a 3-mm pitch of the pelvis, with the patient in the supine position, were acquired 30 days after BT, and were imported into the BT-TPS. In addition to the prostate, the rectum was contoured as a solid structure defined by the outer wall on all slices that showed seeds, without attempting to differentiate the inner wall or the contents. All doses were defined using the TG43 formalism from a 1-mm grid size at each seed location, determined by the seed finder module.

CRT

The CT data were also imported into another TPS (Eclipse version 8.0; Varian Medical Systems, CA) for subsequent CRT planning. The clinical target volume (CTV) included the prostate and proximal half or whole of the seminal vesicle. The planning target volume (PTV) was defined by adding a 2-cm margin to the volume surrounding the CTV, except on the rectal side where only 1 cm was added. Irradiation with 10 MV-photons was delivered from a linear accelerator (Clinac 2100C; Varian Medical Systems, CA) by using a conformal 4-field technique at a dose of 2 Gy per fraction, with 5 fractions per week; the total dose was 40 Gy. The dose delivered to the prostate and rectum was calculated with a 5-mm grid size. The rectum was contoured in the slices including the PTV.

Tentative IMRT

Using the same CT image set a tentative IMRT plan by 7 coplanar beams was devised with the dose covering 95% of the target volume set at 40 Gy. The CTV for the IMRT plan was the same as that for the CRT plan, and included a 5-mm CTV-PTV margin in all directions. The normalization was performed by application of typical dose constraints used for definitive IMRT of 78 Gy/39 fractions

Summation of BT and EBRT doses

The physical doses in the DICOM-RT of BT-post plan, CRT, and tentative IMRT were converted to BED using a previously published equation [14,15], with an α/β ratio of 3 (Gy_3). The modified DICOM-RT doses were added to the CRT-TPS, and

summation using the 'sumplan' module created actual (BT followed by CRT: BT+CRT) and tentative (BT followed by IMRT: BT+IMRT) rectal DVHs.

Study Design

The rectal volume exposed to 150 Gy_3 ($rV_{150(3)}$) in the combined radiotherapy is presumed to be the predictive variable [16]. Statistical differences in mean $rV_{150(3)}$ for BT, BT+CRT, and BT+IMRT were compared by using paired t-tests. Statistical analysis was performed using SPSS version 11.01j (SPSS Japan, Tokyo, Japan). Differences were significant if p-values were less than 0.05.

RESULTS & DISCUSSION

During BT, an average of 49.6 (range (R), 33–74) seeds was inserted per prostate, which had a mean volume of 23.7 (R, 13.8–39.5) cc. The BT post plan revealed average pD_{90} , pV_{100} , pV_{150} , and rV_{100} values of 122 (R, 88–150) Gy, 93.5 (R, 83.2–99.4%), 63.3 (R, 30.9–85.8%), and 0.40 (R, 0–2.48) cc, respectively. CRT was administered an average of 33.7 (R, 22–76) days after BT. Tentative IMRT planning satisfied entire of dose constraints, with the total dose presumed to be 40 Gy instead of 78 Gy.

The mean $rV_{150(3)}$ of BT, BT+CRT, and BT+IMRT was 0.06 ± 0.09 , 1.41 ± 0.88 , and 1.18 ± 0.75 cc, respectively. A significant difference was found between BT and BT+CRT ($p < 0.001$) and between BT+CRT and BT+IMRT ($p < 0.001$). $rV_{150(3)}$ of BT unanimously increased at BT+CRT, and then decreased at BT+IMRT except in 3 cases that showed a further increase in $rV_{150(3)}$ at BT+IMRT (Figure 1).

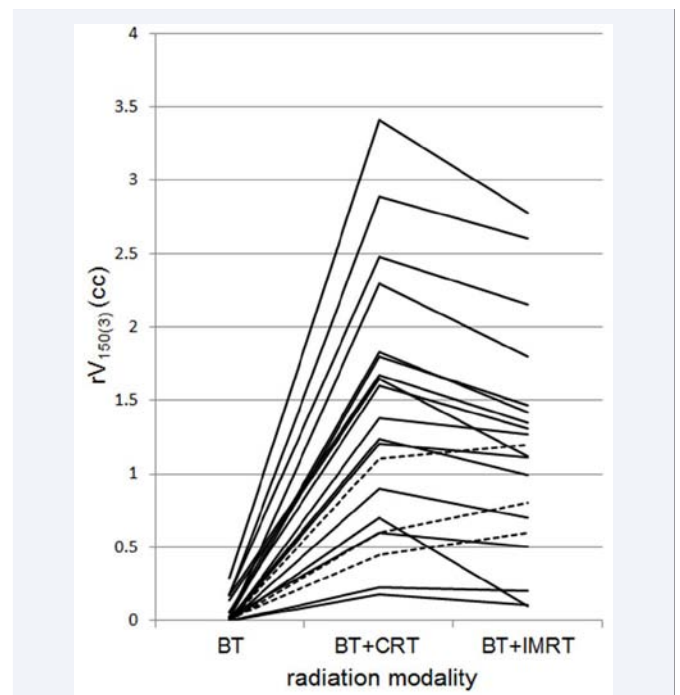


Figure 1 Legend. $rV_{150(3)}$ at BT, BT+CRT, and BT+IMRT. From BT+CRT to BT+IMRT, $rV_{150(3)}$ decreased in most cases (solid lines) except in 3 cases (dotted lines).

The elevation rate of $rV_{150(3)}$ from BT to BT+CRT in each case is proportional to their $rV_{150(3)}$ of BT as shown in Figure 1. The larger $rV_{150(3)}$ is surrounded by a broader rectal wall exposed to a sub toxic dose during BT that should be easily recruited into $rV_{150(3)}$ by CRT. This also means that $rV_{150(3)}$ of BT is located in the rectal anterior wall, which is unexceptionally irradiated during CRT. Although substitution of CRT with IMRT substantially reduces $rV_{150(3)}$, it is not enough to lessen the number of patients receiving rectal doses beyond the safe range. In order to reduce $rV_{150(3)}$ in combined radiotherapy, it is essential to maintain $rV_{150(3)}$ as small as possible in BT.

IMRT optimizes the prostate dose within the fixed rectal dose constraints in its monotherapy. Meanwhile, situations in the combined radiotherapy are different. When $rV_{150(3)}$ of BT is large, the posterior edge of the prostate should be already covered by a sufficient dose, requiring less additional doses. The reverse may also apply, with a small $rV_{150(3)}$ requiring more additional doses. Under these conditions, it is misleading to set fixed dose constraints for supplemental IMRT. Hence, we must establish a method to individually determine the dose constraints in IMRT according to the inconsistent prostate and rectal doses delivered by BT in each case.

Some limitations should be acknowledged in this study. There was a notable difference in PTV margins between CRT and IMRT treatment plans, reflected actual transition in EBRT systems within our hospital. The CRT for OPC has been performed with a generous margin in previous studies [17-18] and during this study, whereas IMRT margins are much smaller, owing to the image-guided radiotherapy system [19]. The smaller PTV margin of IMRT compared to CRT should partially account for the decrease in rectal exposure by the substitution [20]. The α/β ratio used for BED calculation in this study is another premise that should be referred because it is computed from clinical data based on changes in total is effective target dose after changes in prescribed dose per fraction disregarding differences among patients in the volumes of normal tissue irradiated [21].

CONCLUSION

The substitution of CRT with IMRT in conjunction with seed implant brachytherapy reduces the mean rectal dose predisposing bleeding. Avoiding rectal exposure to high doses during BT is important even in BT+IMRT.

REFERENCES

1. Davis BJ, Horwitz EM, Lee WR, Crook JM, Stock RG, Merrick GS, et al. American Brachytherapy Society consensus guidelines for transrectal ultrasound-guided permanent prostate brachytherapy. *Brachytherapy*. 2012; 11: 6-19.
2. Stock RG, Cesaretti JA, Hall SJ, Stone NN. Outcomes for patients with high-grade prostate cancer treated with a combination of brachytherapy, external beam radiotherapy, and hormonal therapy. *BJU Int*. 2009; 104: 1631-1636.
3. Stock RG, Ho A, Cesaretti JA, Stone NN. Changing the pattern of failure for high-risk prostate cancer patients by optimizing local control. *Int J Radiat Oncol Biol Phys*. 2006; 66: 389-394.
4. Sylvester JE, Grimm PD, Blasko JC, Millar J, Origo III PF, Skoglund S, et al. 15-year biochemical relapse free survival in clinical stage T1-T3 prostate cancer following combined external beam radiotherapy and brachytherapy; Seattle experience. *Int J Radiat Oncol Biol Phys*. 2007; 67: 57-64.
5. Sherertz T, Wallner K, Merrick G, Ford E, Sutlief S, Cavanagh W, et al. Factors predictive of rectal bleeding after 103Pd and supplemental beam radiation for prostate cancer. *Brachytherapy*. 2004; 3: 130-135.
6. Ohashi T, Yorozu A, Toya K, Saito S, Momma T, Nagata H, et al. Rectal morbidity following I-125 prostate brachytherapy in relation to dosimetry. *Jpn J Clin Oncol*. 2007; 37: 121-126.
7. Zelefsky MJ, Nedelka MA, Arican ZL, Yamada Y, Cohen GN, Shippy AM, et al. Combined brachytherapy with external beam radiotherapy for localized prostate cancer: reduced morbidity with an intraoperative brachytherapy planning technique and supplemental intensity-modulated radiation therapy. *Brachytherapy*. 2008; 7: 1-6.
8. Forsythe K, Blacksbury S, Stone N, Stock RG. J Intensity-modulated radiotherapy causes fewer side effects than three-dimensional conformal radiotherapy when used in combination with brachytherapy for the treatment of prostate cancer. *Int Radiat Oncol Biol Phys*. 2012; 83: 630-635.
9. Jackson A, Skwarchuk MW, Zelefsky MJ, Cowen DM, Venkatraman ES, et al. Late rectal bleeding after conformal radiotherapy of prostate cancer. II. Volume effects and dose-volume histograms. *Int J Radiat Oncol Biol Phys*. 2001; 49: 685-698.
10. Pederson AW, Fricano J, Correa D, Pelizzari CA, Liauw SL. Late toxicity after intensity-modulated radiation therapy for localized prostate cancer: an exploration of dose-volume histogram parameters to limit genitourinary and gastrointestinal toxicity. *Int J Radiat Oncol Biol Phys*. 2012; 82: 235-241.
11. Vargas C, Martinez A, Kestin LL, Yan D, Grills I, Brabbins DS, et al. Dose-volume analysis of predictors for chronic rectal toxicity after treatment of prostate cancer with adaptive image-guided radiotherapy. *Int J Radiat Oncol Biol Phys*. 2005; 62: 1297-1308.
12. Nakamura R, Kikuchi K, Yabuuchi T, Uwano I, Yamaguchi S, Ariga H, et al. Narrow safety range of intraoperative rectal irradiation exposure volume for avoiding bleeding after seed implant brachytherapy. *Radiat Oncol*. 2012; 7: 15.
13. Zelefsky MJ, Nedelka MA, Arican ZL, Yamada Y, Cohen GN, Shippy AM, et al. Combined brachytherapy with external beam radiotherapy for localized prostate cancer: reduced morbidity with an intraoperative brachytherapy planning technique and supplemental intensity-modulated radiation therapy. *Brachytherapy*. 2008; 7: 1-6.
14. Dale RG. The application of the linear-quadratic dose-effect equation to fractionated and protracted radiotherapy. *Br J Radiol*. 1985; 58: 515-528.
15. Jani AB, Hand CM, Lujan AE, Roeske JC, Zagaja GP, Vijayakumar S, et al. Biological effective dose for comparison and combination of external beam and low-dose rate interstitial brachytherapy prostate cancer treatment plans. *Med Dosim*. 2004; 29: 42-48.
16. Kikuchi K, Nakamura R, Tanji S, Yamaguchi S, Kakuwara H, Yabuuchi T, et al. Three-dimensional summation of rectal doses in seed implant brachytherapy combined with external beam radiotherapy for prostate cancer. *Radiat Oncol*. 2013; 107:159-164.
17. Poli ME, Parker W, Patrocínio H, Souhami L, Shenouda G, Campos LL, et al. An assessment of PTV margin definitions for patients undergoing conformal 3D external beam radiation therapy for prostate cancer based on an analysis of pretreatment daily ultrasound localizations. *Int J Radiat Oncol Biol Phys*. 2007; 67: 1430-1437.
18. Tinger A, Michalski JM, Cheng A, Low DA, Zhu R, Bosch WR, et al. A critical evaluation of the planning target volume for 3-D conformal radiotherapy of prostate cancer. *Int J Radiat Oncol Biol Phys*. 1998; 42: 213-221.

19. Liu B, Lerma FA, Patel S, Amin P, Feng Y, Yi BY, et al. Dosimetric effects of the prone and supine positions on image guided localized prostate cancer radiotherapy. *Radiother Oncol.* 2008; 88: 67-76.
20. Zaider M, Zelefsky MJ, Cohen GN, Chui CS, Yorke ED, Hunt MA, et al. The role of external beam in brachytherapy. *Future Oncol.* 2007; 3: 159-168.
21. Tucker SL, Thames HD, Michalski JM, Bosch WR, Mohan R, Winter K, et al. Estimation of α/β for late rectal toxicity based on RTOG 94-06. *Int J Radiat Oncol Biol Phys.* 2011; 81: 600-605.

Cite this article

Nakamura R, Kikuchi K, Yamaguchi S, Kakuwara H, Sugawara J, et al. (2017) Intensity-Modulated vs. Conformal Radiotherapy after Prostate Seed Implant Brachytherapy Regarding Summed Rectal Dose. *J Radiol Radiat Ther* 5(1): 1066.