

Research Article

A Comprehension Between Preoperative Diagnosis of Elastofibroma Dorsi with Magnetic Resonance Imaging(MRI) or CT-Scan of Chest with Post Resection Histopathology

Manoucheher Aghajanzadeh*, Rasool Hassanzadeh, Sima Falah Arzpeyma, Siamak Geranmayeh, and Mohammad Taghi Ashoobi

Department of Thoracic Surgery, Guilan University of Medical Sciences, Iran

***Corresponding author**

Manoucheher Aghajanzadeh, Department of Thoracic Surgery, Guilan University of Medical Sciences, Sardar Jangal Ave, Razi Hospital, Rasht, Iran, Tel: 98-13-33542460; Fax: 98-13-33542460; Email : maghajanzadeh2003@yahoo.com

Submitted: 31 October 2020

Accepted: 08 December 2020

Published: 09 December 2020

ISSN: 2333-7095

Copyright

© 2020 Aghajanzadeh M, et al.

OPEN ACCESS**Keywords**

- Fibroma
- Magnetic resonance imaging
- Computed tomography scan
- Pathology

Abstract

Background: In this study, we aimed to comparison the results of Magnetic Resonance Imaging [MRI] and Computed Tomography [CT] scan in the diagnosis of Elastofibroma Dorsi (ED) with postoperative histopathology as the gold standard diagnostic tool. Clinical characteristics of ED and radiologic features of MRI and CT scan are also discussed.

Materials & Methods: In a retrospective study, we identified all patients with ED who treated in our center between 2000 and 2019. The data including signs, symptoms and imaging's feature and surgical approaches were reviewed. The results of MRI and CT scan were compared with histopathologic findings.

Results: The records of 12 patients who were diagnosed for ED were reviewed. Four of these patients were asymptomatic and were excluded from the study. These patients presented with mass and pain. The mean age of the patients was 64 years. Five of the patients underwent MRI, two patients CT scan and one patient both imaging technique. Core needle biopsy was performed in 3 patients and incisional biopsy was performed in 2 patients. In 3 patients the mass were primarily completely resected without pre or intra operative histopathologic verification. All of the patients underwent wide resection. The postoperative histopathologic results in all of them were compatible with MRI and CT scan findings.

Conclusion: As the results of MRI and CT scan are compatible with postoperative histopathologic assessment, these tools are useful for assessments of ED especially in asymptomatic patients that can potentially avoid from unnecessary biopsy and surgery.

BACKGROUND

Elastofibromas are benign slowly growing soft tissue tumors. These tumors consist of fragmented and enlarged elastic fibers in a collagenous matrix. In 99% of the patients, ED locates between the scapula and the chest wall in the inferior tip of the subscapular region and bilateral involvement may be occur [1,2]. Elastofibromas are common in active persons, older than 50 years [1,3]. In elderly patients, this tumor can be diagnose as an incidental finding in up to 2% by CT scan [3,4]. Children can also be affected by this tumor [1]. In cases older than 55 years of age, the prevalence is up to 24% [5]. It can mimic clinical presentation of others soft tissue tumors located on the thoracic wall. Although it is usually asymptomatic, but it can be associated with mild pain on moving the scapula. Occasionally, the tumor invades the adjacent structures and becomes fixed to the underlying periosteum. Using MRI facilitates accurate diagnosis [1,5-7]. As the results of noninvasive techniques, especially MRI,

and histologic evaluations are closely correlated, so sometimes an unnecessary biopsy can be avoided by using them [5,7-9]. CT-scan shows the same changes, but is less sensitive to visualize the strands of fatty tissue in comparison with MRI [1,5,8-10]. In symptomatic patients or in whom suspicious for malignancy, complete local surgical excision is the choice treatment [4,7, 8, 11]. It can be well controlled by radical surgery [1,7,11], postoperative recurrence is uncommon [1,7,9]. Spontaneous regression without treatment has been seen in some cases [1,4,7]. In fact, because of high incidence of postoperative complications, only symptomatic patients can benefit from surgical resection [4,11]. Due to any report of malignant transformation, surgical excision is not necessary in asymptomatic lesions [1,4,7,8,11].

OBJECTIVES

In this study, we aimed to comparison the results of MRI and CT scan in the diagnosis of ED with postoperative histopathology as the gold standard diagnostic method.

MATERIALS AND METHODS

In this retrospective study, we reviewed the records of all patients with ED who treated in Razi and Arya Hospitals-Rasht-Iran between 2000 and 2019. This study was approved by the regional Committee for Clinical Research Ethics of our university. The data including signs, symptoms and imaging's features and surgical approaches were reviewed. All patients underwent MRI or CT scan imaging preoperatively. Four of asymptomatic patient excluded from this study. Core needle biopsy was performed in 3 patients and incisional biopsy was performed in 2 patients and In 3 patients the mass were primarily completely resected without pre or intraoperative histopathological verification. In all patients, complete wide resection was performed and for pathological study, tissue specimens were obtained and sent to an experienced clinical pathologist. Defects of chest wall were closed primarily. Data were collected and analyzed using SPSS version 21.

RESULTS

Of those 8 patients that were included in our study, 2 patients were men and 6 were women. The average age at the time of treatment was 64 years [52 -79 years]. Four of the patients worked as a hair dresser and were very active during the life. Two were costumer. In four of the patients, the main symptoms were swelling and snapping of the scapula, dyspnea without pain and three patients reported a long history of swelling and pain and discomfort. One patient presented with a long term history of mass with pain and difficulty in shoulder movements. Bilateral involvement was not seen in current study. MRI of the patients showed an ill-defined, relatively spherical, deeply located and extraosseous soft tissue mass [low to intermediate on all sequences: T1, T2W & STIR] within posterior chest wall in the inferior border of scapula beneath serratus anterior

muscle without any invasion to adjacent bony structures and mild enhancement during contrast administration. M.R.I findings were most compatible with tumoral mass containing fibrotic tissue [Elasto fibroma Dorsi], (Figure 1A,B,C&D), and CT scan of these patients showed a poorly defined soft tissue mass with attenuation similar to that of adjacent latissimus dorsi muscle with streaks of fat density located infrascapular / subscapular region. There was no calcification or cystic component or bone erosion. These findings are highly suggestive for elastofibroma dorsi (Figure 2). In all patients the margins of the elastofibromas were ill defined. The tumors were located in inferior angle of the scapula. Core needle biopsy revealed a fibrotic tumor without malignant features in three patients and incisional biopsy confirmed the diagnosis of (ED) in two patients. All patients underwent mass resection with posterolateral thoracotomy. These tumors attached to the thoracic wall with no invasion to ribs. The anterior portion of the tumor, located between Serratus anterior muscle and chest wall and the posterior portion was between serratus and latissimus dorsi muscles. Pleural space was not opened during resection. In five cases, the tumor was at the right side; in the rest at the left side. The tumor size ranged from 6 to 15 cm. In all patients chest wall was banded postoperatively and a Redon drain was put under muscles for prevention of seroma. Postoperative seroma occurred in three cases. Pathology revealed soft tissue lesions characterized by an irregular, ill defined fibroelastotic mass with a slightly rubbery and elastic consistence. The cut surface showed strands of white and yellow tissue due to entrapment of fatty remnants (Figure 3 A&B). The tumors were not encapsulated. Histologically, the tumors were composed of fibrous, collagens strands and plump. The elastic structures typically formed discs or globules. These fibers are detected difficultly by hematoxylin-eosine-staining. For this reason elastic stain [Orcein] was used which stained the elastic fibers dark brown to black. The lesions were dominantly

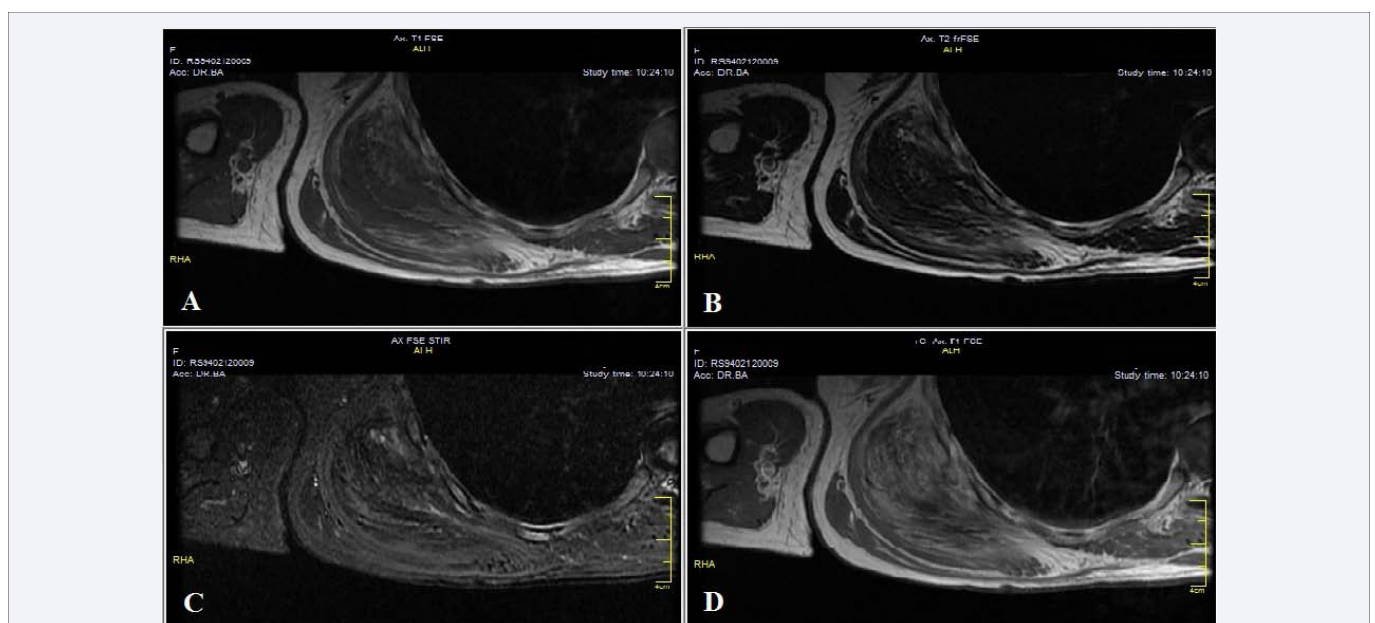


Figure 1 A,B,C&D MRI shows an ill-defined soft tissue mass with intermediate signal on T1W (A) and low signal on T2W & STIR sequences (B&C) with minimal enhancement on T1W post contrast image (D) located in right infrascapular region beneath serratus anterior muscle without bony involvement. These findings are highly suggestive for elasto fibroma dorsi.

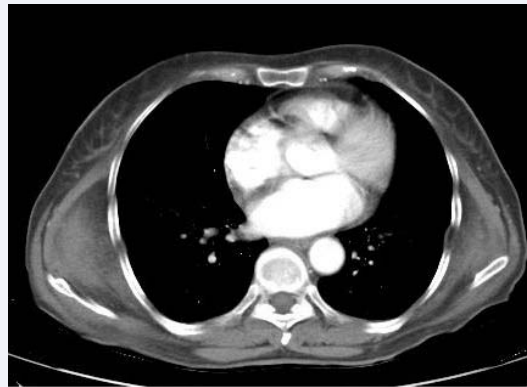

Figure 2 CT scan shows a poorly defined soft tissue mass with attenuation similar to that of adjacent muscle (latissimus dorsi) with streaks of fat density located at right subscapular region. There is no calcification or cystic component and no bone erosion. The findings are highly suggestive of elastofibroma dorsi.

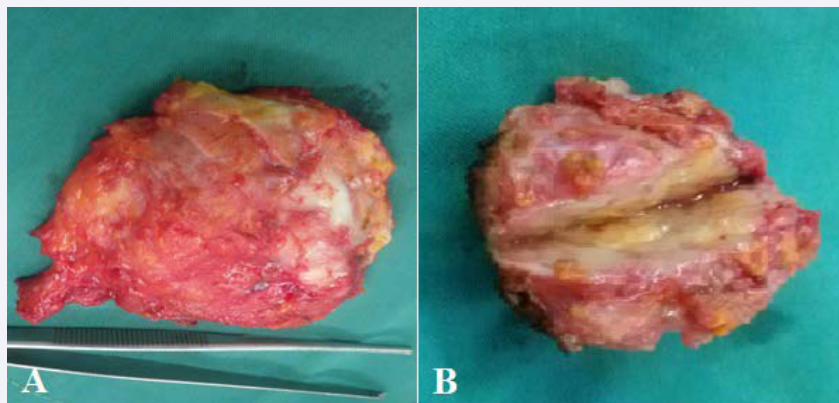


Figure 3 A; Excised mass with irregular borders. B; The cut surface shows strands of white and yellow tissue caused by the entrapment of fatty remnants.

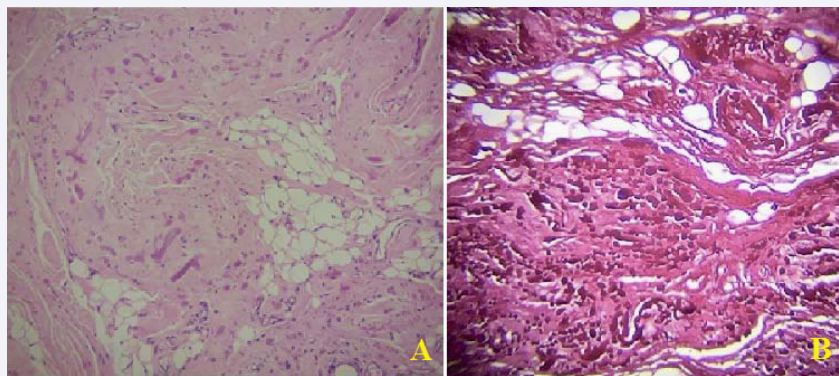


Figure 4 A: Shows hyalinized collagen with scattered fibroblasts and entrapped islands of mature fat cells (Hematoxylin-Eosine staining), B: Orcein stain highlights elastic fibers as dark, beaded cords and spherules.

hypocellular with fibrocytic and fibroblastic cells without atypical changes and mitotic activity [Figure 4 A&B]. At follow-up period [2 to 6 years], not only the patients didn't complain from decrease of function or sensation of the shoulder or the arm on the operated side but also had neither recurrence of the elastofibroma nor any difficulties caused by surgery.

DISCUSSION

The etiology of (ED) is still unclear, but repetitive micro trauma caused reactive hyperproliferation of fibroelastic tissue between scapula and chest wall are suspected [1,4,7]. Vascular insufficiency considered as a possible cause in etiology of (ED) [1,2,7]. Some studies suggested abnormal elastogenesis or

degenerating as a cause of these processes [1,2,8,9,11,12]. In a review of the literature no role for micro trauma in pathogenesis of (ED) has been considered and enough information about patients' activity are not provided [1,4,7,13]. The female gender affected more than male (since 5:4 to 13:1). Some studies suggest that micro trauma alone cannot be the major factor in the genesis of these lesions [1,4,7]. In contrast, in our study most of the cases had a history of extensive physical activity. Six patients were extensively active during their life and their job was (hairdresser=4 and costumer=2).

The clinical presentation of elastofibroma dorsi affected by location and size of the lesion. The most common symptoms are shoulder pain or snapping scapula as our patients [1,9,13]. Most of the cases can present with only mild discomfort and some cases can remain asymptomatic for a long period until the treatment time [1,4, 10,11,13]. ED is more common on the right side and in 50% of the cases bilateral involvement may be seen [1, 12]. In our study no bilateral involvement was found. In five cases the tumor was located on the right side and in the rest on the left side. In some patients, thoracic movements may disturb due to large tumor size and dyspnea can occur [1,3,4,9,11,13].

Plain radiographs do not show specific changes [1]. Ultrasonography and Color Doppler sonography may be used as diagnostic tools [1,6,14]. However MRI is the most reliable non-invasive method used in the diagnosis of (ED). The lesions mostly have a signal intensity as adjacent muscles and interspersed adipose strands produce a heterogeneous structure with longitudinal areas of higher signal intensity [1,4-6]. In all of our patients MRI findings were consistent with the above mentioned criteria. CT-scan shows the same changes, but is less sensitive to visualize the fatty strands [1,4-6,15]. But in all our patients who underwent CT-scan, findings were highly suggestive for (ED).

The advanced age, long term history of mass, typical localization, female gender or bilateral manifestations are highly suggestive for the presumptive diagnosis of (ED). In such cases and criteria with imaging findings in favor for ED, one may refrain from the biopsy. In contrast, some authors recommend that tumor material should be obtained for confirmational diagnosis and rule out other diagnosis such as sarcomas, fibroma, aggressive fibromatosis and lipoma [1,5,7,13,15]. MRI, CT scan or ultrasound and clinical findings cannot establish definite diagnosis [1,2,5,9,16,17]. Due to hypocellularity, fine needle aspiration is not recommended [2,3,7,8, 16]. For definitive diagnosis, an open biopsy or a core needle biopsy should be performed to provide a tissue specimen [1,7,8,16,18]. In five cases of our patients frozen section was performed but was not diagnostic and we don't recommend it.

Tumor excision is not necessary in asymptomatic patients and malignant transformation has never been reported. In symptomatic cases wide marginal resection is recommended [1,2,7,9,11,18].

Some authors reported high incidence of seroma postoperatively [1,4,9,11]. In our study seroma presents in three patients with large (ED) and was treated with multiple aspirations. We also used a tight bandage for operation site to prevent seroma formation.

In a review of literature only a few cases of recurrence were reported [1,2,6,7,11,13]. In this study, all of our patients were disease free at follow-up period.

CONCLUSION

In conclusion, Elastofibroma dorsi as a differential diagnosis in all soft tissue tumors located in the infrascapular area should be considered. MRI and CT-scan are preferred methods to localize and identify the lesions. As the results of MRI and CT scan are compatible with postoperative histopathologic assessment, these tools are useful for assessments of ED especially in asymptomatic patients that can be potentially avoided from unnecessary biopsy and surgery. Also radical resections in symptomatic patients can be avoided because only marginal resection is sufficient. We recommend postoperative wound drainage with a Redon drain [one week] and a tight bandage [four week] to reduce postoperative seroma.

ETHICS APPROVAL AND CONSENT TO PARTICIPATE

This study was approved by the Ethics Committee of Guilan University of Medical Sciences and is in compliance with the declaration of Helsinki; however, there was no need to taking informed consent since only leftovers from medical record were used.

REFERENCES

1. M Bartocci, C Dell'atti, E Meacci, MT congedo, N Magarelli, L Bonomo, A Leone. Clinical features, imaging findings, treatment aspects of elastofibroma dorsi and long-term outcomes after surgical resection. *Eur Rev Med Pharmacol Sci.* 2017; 21: 2061-2068.
2. Tasli F, Vardar E, Argon A, Kabat T, Deniz S, Nart A, et al. Histochemical and immunohistochemical characteristics of elastofibromas. *Pol J Pathol.* 2014; 65: 120-124.
3. Mortman KD, Hochheiser GM, Giblin EM, Manon-Matos Y, Frankel KM. Elastofibroma dorsi: clinicopathologic review of 6 cases. *Ann Thorac Surg.* 2007; 83: 1894-1897.
4. Parratt MT, Donaldson JR, Flanagan AM, Saifuddin A, Pollock RC, Skinner JA, et al. Elastofibroma dorsi: management, outcome and review of the literature. *J Bone Joint Surg Br.* 2010; 92: 262-266.
5. Malghem J, Baudrez V, Lecouvet F, Lebon C, Maldague B, Vande Berg B. Imaging study findings in elastofibroma dorsi. *Joint Bone Spine.* 2004; 71: 536-541.
6. Bilateral and atypical localized elastofibroma dorsi in a patient with shoulder and back pain: A case report. *Turk J Phys Med Rehab.* 2019; 65: 287-289.
7. Lococo F, Cesario A, Mattei F, Petrone G, Vita LM, Petracca-Ciavarella L, et al. Elastofibroma dorsi: clinicopathological analysis of 71 cases. *Thorac Cardiovasc Surg.* 2013; 61: 215-222.
8. Domanski H, Carlen B, Sloth M, Rydholm A. Elastofibroma Doris has distinct cytomorphologic features, making diagnostic, surgical biopsy unnecessary: cytomorphologic study with clinical, radiologic, and electron microscopic correlations. *Diagn Cytopathol.* 2003; 29: 327-333.
9. Koksel O, Demir Apaydin F, Ayan E, Demir M, Ozdulger A. Elastofibroma dorsi: Review of eight cases. *Surg Today.* 2010; 40: 423-427.
10. Pierce III JC, Henderson R. Hypermetabolism of elastofibroma dorsi on PET-CT. *AJR Am J Roentgenol.* 2004; 183: 35-37.

11. Nagano S, Yokouchi M, Setoyama T, Sasaki H, Shimada H, Kawamura I, et al. Elastofibroma dorsi: Surgical indications and complications of a rare soft tissue tumor. *Mol Clin Oncol*. 2014; 2: 421-424.
12. Frederik Lundgaard Hansen, Thomas Stokholm Nørtinger, Rikke Thorninger. Bilateral Elastofibroma Dorsi as Differential Diagnosis in Posterior Chest Wall Tumor: A Case Report. *Arch Clin Med Case Rep*. 2020; 4: 235-238.
13. Majo J, Gracia I, Doncel A, Valera M, Nunez A, Guix M. Elastofibroma dorsi as a cause of shoulder pain or snapping scapula. *Clin Orthop Relat Res*. 2001: 200-204.
14. Solivetti FM, Bacaro D, Di Luca Sidozzi A, Cecconi P. Elastofibroma dorsi: ultrasound pattern in three patients. *J Exp Clin Cancer Res*. 2003; 22: 565-569.
15. Maalouly, Dany Aouad, Hicham Abdel Nour, Rami Ayoubi, Joseph Wehbi, Ralph Jalbout. Elastofibroma Dorsi of the Lateral Chest Wall Deep to Serratus Anterior and Latissimus Dorsi Muscles: A Case Report. *J Ortho Dis*. 2018; 1: 3.
16. Lococo F, Cesario A, Mattei F, Petrone G, Vita LM, Petracca- Ciavarella L, et al. Elastofibroma dorsi: clinicopathological analysis of 71 cases. *Thorac Cardiovasc Surg*. 2013; 61: 215-2217.
17. Ozan E, Akincioglu E, Kaplan T, Atac GK, et al. Extraordinary presentation of elastofibroma dorsi after a thoracotomy procedure. *J Natl Med Assoc*. 2018; 110: 428-430.
18. Cota C, Solivetti F, Kovacs D, Cristiani R, Amantea A. Elastofibroma dorsi: histologic and echographic considerations. *Int J Dermatol*. 2006; 45: 1100-1103.

Cite this article

Aghajanzadeh M, Hassanzadeh R, Arzpeyma SF, Geranmayeh S, Ashoobi MT (2020) A Comprehension Between Preoperative Diagnosis of Elastofibroma Dorsi with Magnetic Resonance Imaging(MRI) or CT-Scan of Chest with Post Resection Histopathology. *J Radiol Radiat Ther* 7(1): 1089.