

Special Issue on Cancer Radiation Therapy

Edited by:

Takeo Takahashi,

Saitama Medical University, Japan

Short Communication

Carbon-ion Radiotherapy for Non-squamous Cell Head and Neck Malignancies

Takeo Takahashi^{1,2}, Jun-ichi Saitoh², Katsuyuki Shirai², Keiichiro Nishimura¹, Tatsuya Ohno² and Takashi Nakano²

¹Department of Radiation Oncology, Saitama Medical University, Japan

²Department of Radiation Oncology, Gunma University, Japan

INTRODUCTION

The head and neck region consists of subsites, including the oral cavity, pharynx, larynx, nasal sinuses, salivary glands, and orbits, and contains important organs performing functions that are directly related to the Quality of Life (QOL), such as chewing, swallowing, and phonation. It has been reported that 32% of head and neck cancers occur in the oral cavity, 24% in the larynx, 35% in the pharynx, and 9% in the nasal cavity and sinuses [1]. Histopathologically, more than 95% of head and neck cancers are squamous cell carcinomas. With the advent of an aging society, there has been an increase in the number of people affected by head and neck cancers, including oral and pharyngeal cancers. Since head and neck cancers grow in or invade organs directly related to the QOL, surgical therapy, and, in the case of squamous cell carcinoma, radiotherapy and chemoradiotherapy, play an important therapeutic role. However, non-squamous cell carcinomas, such as adenocarcinoma and adenoid cystic carcinoma, are less radiosensitive to X-rays than their squamous cell carcinomas, and malignant melanoma is radioresistant. Therefore, non-squamous cell carcinomas are less likely to be cured by conventional radiotherapy, making surgical therapy the first-line treatment. However, locally advanced head and

*Corresponding author

Takeo Takahashi, Department of Radiation Oncology, Saitama Medical Center, Saitama Medical University, 1981, Kamoda, Kawagoe, Saitama 350-8550, Japan, Tel: +81-49-228-3441; Email: taketaka@saitama-med.ac.jp

Submitted: 26 March 2014

Accepted: 30 April 2014

Published: 02 May 2014

ISSN: 2333-7095

Copyright

© 2014 Takahashi et al.

OPEN ACCESS

Keywords

- Carbon ion radiotherapy
- Head and neck cancer
- Malignant melanoma
- Intensity modulated radiotherapy
- Non squamous cell carcinoma

neck malignancies are often difficult to treat by surgery in many patients because of anatomical features.

Treatment results for non-squamous cell head and neck cancer

Radiotherapy is usually selected for patients whose squamous cell carcinomas are difficult to surgically resect due to their location and extent of local invasion, or in whom a decrease in the postoperative functional/cosmetic QOL becomes problematic. However, no sufficient local effects can be expected from conventional radiotherapy for low-radiosensitive non-squamous cell carcinomas. For resectable head and neck adenocarcinomas and adenoid cystic carcinomas, surgical treatment was generally performed [2]. Although many studies have reported the usefulness of postoperative radiotherapy, reports on the results of single-modality radiotherapy for unresectable head and neck carcinomas are limited. Mendenhall et al. reported that the 5- and 10-year local control rates of a

combination of surgery and postoperative radiotherapy for head and neck adenoid cystic carcinomas were 94 and 91%, respectively, and the postoperative radiotherapy was effective if the surgical margins were histopathologically positive [3,4]. They also reported that the 5- and 10-year local control rates of single-modality radiotherapy for adenoid cystic carcinomas were low, at 56 and 43%, respectively, and less satisfactory, at 44 and 30%, respectively, for patients with T4 carcinomas [3]. The 10-year survival rate of patients treated by a combination of surgery and postoperative radiotherapy was 65%, whereas that of those treated by single-modality radiotherapy was only 44% [3]. These reports indicate that the results of treatment of head and neck adenocarcinomas and adenoid cystic carcinomas by single-modality radiotherapy are poor [4-7].

Since malignant melanoma cells are highly radioresistant [8-10], head and neck mucosal malignant melanomas are difficult to control by conventional single-modality X-ray radiotherapy [11]. In addition, chemotherapy has not been established for these malignant melanomas [12], making extensive surgical resection the treatment of choice [13]. However, it is often difficult to perform extensive resection with reconstruction because of functional and esthetic problems in the face, head, and neck regions, and because tumors often invade the orbit and skull base. In patients with unresected melanoma, a combination of radiotherapy and anticancer drug therapy or immunotherapy is often used. However, the 5-year survival rate of patients so treated by these treatments is reportedly low, at about 20-35% [14,15]. Postoperative radiotherapy has been attempted in patients with resected mucosal malignant melanomas. Most of studies have reported that postoperative radiotherapy improves local control rates, but does not contribute to improving survival rates. Moreno et al. reported that conventional postoperative fractionated radiotherapy improved local control, but not survival [14]. Gilligan et al. reported that the 5-year local control rate of postoperative radiotherapy was 61%, but the 5-year survival rate was only 17.9% [16].

In terms of the dose distribution, intensity-modulated radiotherapy (IMRT) for head and neck cancers has recently been becoming commonly used [17]. IMRT is a highly precise radiotherapy capable of creating a favorable dose distribution for the tumor, while avoiding the adjacent organ at risk (brain, brainstem, spinal cord, eyes, and salivary glands). IMRT for head and neck cancers, such as nasopharyngeal cancer, can reduce adverse events by avoiding organ at risk and salivary glands [17]. Heidelberg University Hospital performed IMRT in patients with mucosal malignant melanoma of the nasal cavity and sinuses, using 59 Gy (54-64 Gy) at 2 Gy/fraction to the Clinical Target Volume (CTV) and 66 Gy (60-68 Gy) at 2.2 Gy/fraction to the Gross Tumor Volume (GTV), and the 3-year survival and recurrence-free survival rates were 75 and 57.1%, respectively, which were better than previously reported [18]. However, since locally advanced tumors of the nasal cavity and sinuses often border or invade the skull base, it is difficult to avoid organ at risk such as the optic nerves with IMRT or stereotactic radiotherapy. To overcome their radioresistance, it may be useful to use higher-dose per fraction radiotherapy [13,19]. It was reported that there was a correlation between the radiation dose per fraction and radiation response of malignant melanomas, and radiotherapy

at a dose of 3 Gy or more (with a BED of 118 or more) achieved good local control [20]. In a comparative clinical trial (RTOG 83-50) of radiotherapy for metastatic malignant melanoma, no significant difference in the response rate was observed between patients treated with 8 Gy \times 4 and those treated with 2.5 Gy \times 4 [21]. Although this suggests the usefulness of hypofractionated radiotherapy, the dose per fraction is so large that the risk of nerve damage is high if the tumor borders the central nervous system or optic nerves, making 3D-conformal radiotherapy inappropriate for a good dose distribution.

Proton radiotherapy is promising for locally advanced cancer. Clinical proton beam has superior dose distribution. However, it is low LET radiation that the biological effectiveness per unit of energy absorbed is very close to that of high energy X-ray [22]. Pommier reported a 3 year local control rate of 93 % was obtained by treated with proton radiotherapy of 70 Gy (BED) for adenoid cystic carcinoma with involvement of the base of skull region [23].

Carbon ion radiotherapy

Carbon-ion Radiotherapy (C-ion RT) has superior physical characteristics and high biological effectiveness, and offers the advantage of a high dose deposition within so-called "Bragg Peak". Carbon ion beams have a high Linear Energy Transfer (LET), because carbon ions decelerate rapidly in the body and release the maximum energy near the Bragg Peak [24]. C-ion RT is capable of creating a favorable dose distribution for the tumor, while avoiding the adjacent organ at risk (brain, brainstem, spinal cord, eyes, optic nerves) (Figure 1). Carbon ion beams differ from X-rays and protons in their radiobiological properties, which result from much higher ionization density (high LET) [25]. Relative biological effectiveness of carbon beam is about 2.5~3.0, and carbon ion beam is not affected by the oxygen effect [24]. Because of the lack of cellular repair, hypofractionation (the delivery of the dose in a few large fraction) has been proposed in many tumors [25]. Therefore, it is expected to exert excellent therapeutic effects against non-squamous cell carcinomas that are difficult to locally control by X-ray radiography, such as adenocarcinoma, adenoid cystic carcinoma, and melanoma.

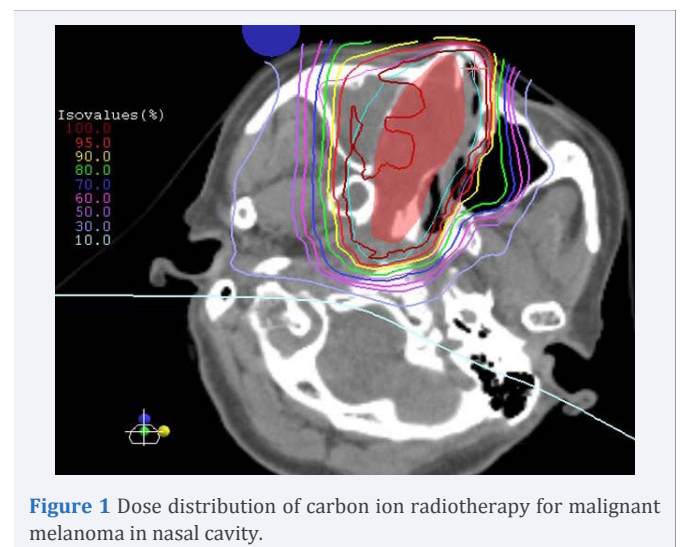


Figure 1 Dose distribution of carbon ion radiotherapy for malignant melanoma in nasal cavity.

A phase I/II clinical trials of C-ion RT for head and neck cancer was initiated in 1994 at the National Institute of Radiological Sciences (NIRS) in Japan [26,27]. Locally advanced, histological proven, and new or recurrent cancer of head and neck were treated with C-ion RT in phase I/II study [28]. The dose fraction of 72.0 GyE/ 18 fractions and 64.0 GyE/ 16 fractions showed equal clinical outcome [28]. In 2012, Mizoe reported the efficacy of C-ion RT for head neck cancer again [28]. Total dose of 64.0 GyE or 57.6 GyE/ 16 fractions were administered. The 5-year local control rate was 68 % [26]. C-ion RT for head and neck cancer showed the therapeutic effectiveness for adenoid cystic carcinoma and malignant melanoma without severe morbidity of normal tissues. Treatment results obtained so far can be summarized by stating that a favorable local control rate of as high as 80 to 90 % has been achieved in adenocarcinoma and adenoid cystic carcinoma [29]. A clinical trial at NIRS showed that the local control of mucosal malignant melanomas was excellent, but many patients with distant melanoma metastases died, with a 2-year survival rate of about 50%. Therefore, a combined carbon-ion radiotherapy-chemotherapy (DAV therapy) regimen was started, and its safety and effectiveness are being investigated [30]. The 5-year local control and 5-year survival rates with this regimen for mucosal malignant melanoma are high, at 73.9 and 62.5%, respectively, which are much higher than the 5-year survival rates of single-modality carbon-ion radiotherapy, and no adverse effect higher than grade 3 has been observed [30]. A tumor volume of 100 mL or more was a poor prognostic factor in patients undergoing carbon-ion radiotherapy [30]. If distant metastases occur early after therapy, occult distant metastatic disease may have been present. Since carbon-ion radiotherapy facilitates favorable local control, combination treatment for potential mucosal malignant melanoma is expected to improve the survival rate of patients with this disease. By using a compact prototype of the accelerator system, C-ion RT for the first patient at the Gunma University Heavy Ion Medical Center (GHMC) took place in 2010 [31]. Many clinical trials have been started at GHMC for head and neck tumor, lung cancer, hepatocellular carcinoma, recurrent rectal carcinoma, bone and soft tissue sarcoma, and prostate cancer, etc. Especially for mucosal melanoma, protocol of concurrent DAV combined with C-ion RT. C-ion RT was administered on a fractionation schedule consisting of 64.0 GyE/ 16 fractions/ 4 weeks for non-squamous head and neck cancers and mucosal malignant melanoma. Preliminary results of GHMC shows that the 1-year and 2-year local control were 92 % and 77 %, respectively for non- squamous head and neck cancers.

CONCLUSION

Because non squamous cell head and neck malignancies are radioresistant, conventional radiotherapy is not effective. On the other hand, high LET carbon ion radiotherapy has advantage for head and neck malignancies because of better dose distribution in the tumor volume and greater biological effectiveness. Carbon ion radiotherapy is promising for head and neck radioresistant tumor.

ACKNOWLEDGEMENT

This work was supported by JSPS KAKENHI Grant Number 25461925.

REFERENCES

1. Japan society for Head and Neck Cancer, Cancer Registry Committee. Report of head and neck cancer registry of japan. Clinical statistics of registered patients, 2002.
2. Brookstone MS, Huvos AG. Central salivary gland tumors of the maxilla and mandible: a clinicopathologic study of 11 cases with an analysis of the literature. *J Oral Maxillofac Surg.* 1992; 50: 229-236.
3. Mendenhall WM, Morris CG, Amdur RJ, Werning JW, Hinerman RW, Villaret DB. Radiotherapy alone or combined with surgery for adenoid cystic carcinoma of the head and neck. *Head Neck.* 2004; 26:154-162.
4. Mendenhall WM, Morris CG, Amdur RJ, Werning JW, Villaret DB. Radiotherapy alone or combined with surgery for salivary gland carcinoma. *Cancer.* 2005; 103: 2544-2450.
5. Garden AS, Weber RS, Morrison WH, Ang KK, Peters LJ. The influence of positive margins and nerve invasion in adenoid cystic carcinoma of the head and neck treated with surgery and radiation. *Int J Radiat Oncol Biol Phys.* 1995; 32: 619-626.
6. Chen AM, Bucci MK, Weinberg V, Garcia J, Quivey JM, Schechter NR, et al. Adenoid cystic carcinoma of the head and neck treated by surgery with or without postoperative radiation therapy: prognostic features of recurrence. *Int J Radiat Oncol Biol Phys.* 2006; 66: 152-159.
7. Kokemueller H, Eckardt A, Brachvogel P, Hausamen JE. Adenoid cystic carcinoma of the head and neck--a 20 years experience. *Int J Oral Maxillofac Surg.* 2004; 33: 25-31.
8. Barranco SC, Romsdahl MM, Humphrey RM. The radiation response of human malignant melanoma cells grown in vitro. *Cancer Res.* 1971; 31: 830-833.
9. Dewey DL. The radiosensitivity of melanoma cells in culture. *Br J Radiol.* 1971; 44: 816-817.
10. Doss LL, Memula N. The radioresponsiveness of melanoma. *Int J Radiat Oncol Biol Phys.* 1982; 8: 1131-1134.
11. Krengli M, Jerezek-Fossa BA, Kaanders JH, Masini L, Beldi D, Orecchia R. What is the role of radiotherapy in the treatment of mucosal melanoma of the head and neck? *Crit Rev Oncol Hematol.* 2008; 65: 121-128.
12. Chapman PB, Einhorn LH, Meyers ML, Saxman S, Destro AN, Panageas KS, et al. Phase III multicenter randomized trial of the Dartmouth regimen versus dacarbazine in patients with metastatic melanoma. *J Clin Oncol.* 1999; 17: 2745-2751.
13. Gaze MN, Kerr GR, Smyth JF. Mucosal melanomas of the head and neck: The Scottish experience. The Scottish Melanoma Group. *Clin Oncol (R Coll Radiol).* 1990; 2: 277-283.
14. Moreno MA, Roberts DB, Kupferman ME, DeMonte F, El-Naggar AK, Williams M, et al. Mucosal melanoma of the nose and paranasal sinuses, a contemporary experience from the M. D. Anderson Cancer Center. *Cancer.* 2010; 116: 2215-2223.
15. Wagner M, Morris CG, Werning JW, Mendenhall WM. Mucosal melanoma of the head and neck. *Am J Clin Oncol.* 2008; 31: 43-48.
16. Gilligan D, Slevin NJ. Radical radiotherapy for 28 cases of mucosal melanoma in the nasal cavity and sinuses. *Br J Radiol.* 1991; 64: 1147-1150.
17. Daly ME, Chen AM, Bucci MK, El-Sayed I, Xia P, Kaplan MJ, et al. Intensity-modulated radiation therapy for malignancies of the nasal cavity and paranasal sinuses. *Int J Radiat Oncol Biol Phys.* 2007; 67: 151-157.
18. Combs SE, Konkel S, Thilmann C, Debus J, Schulz-Ertner D. Local

- high-dose radiotherapy and sparing of normal tissue using intensity-modulated radiotherapy (IMRT) for mucosal melanoma of the nasal cavity and paranasal sinuses. *Strahlenther Onkol.* 2007; 183: 63-68.
19. Harwood AR, Cummings BJ. Radiotherapy for mucosal melanomas. *Int J Radiat Oncol Biol Phys.* 1982; 8: 1121-1126.
20. Wada H, Nemoto K, Ogawa Y, Hareyama M, Yoshida H, Takamura A, et al. A multi-institutional retrospective analysis of external radiotherapy for mucosal melanoma of the head and neck in Northern Japan. *Int J Radiat Oncol Biol Phys.* 2004; 59: 495-500.
21. Sause WT, Cooper JS, Rush S, Ago CT, Cosmatos D, Coughlin CT, et al. Fraction size in external beam radiation therapy in the treatment of melanoma. *Int J Radiat Oncol Biol Phys.* 1991; 20: 429-432.
22. Suit H, DeLaney T, Goldberg S, Paganetti H, Clasie B, Gerweck L, et al. Proton vs carbon ion beams in the definitive radiation treatment of cancer patients. *Radiother Oncol.* 2010; 95: 3-22.
23. Pommier P, Liebsch NJ, Deschler DG, Lin DT, McIntyre JF, Barker FG 2nd, et al. Proton beam radiation therapy for skull base adenoid cystic carcinoma. *Arch Otolaryngol Head Neck Surg.* 2006; 132: 1242-1249.
24. Takahashi T, Yoshida Y, Ando K, Kawamura H, Okamoto M, Saitoh J, et al. Singal transduction and heavy ion radiation therapy: Biological mechanisms, biological quality assurance, and new multimodality approach. *Current Signal Transduction Therapy.* 2010; 5: 237-245.
25. Goitein M. Trials and tribulations in charged particle radiotherapy. *Radiother Oncol.* 2010; 95: 23-31.
26. Mizoe JE, Hasegawa A, Jingu K, Takagi R, Bessyo H, Morikawa T, et al. Results of carbon ion radiotherapy for head and neck cancer. *Radiother Oncol.* 2012; 103: 32-37.
27. Mizoe JE, Hasegawa A, Bessho H, et al. Proceedings of NIRS-ETOILE joint symposium 2009 on carbon ion radiotherapy. *Head and neck tumors.* 2009: 32-37.
28. Mizoe JE, Tsujii H, Kamada T, Matsuoka Y, Tsuji H, Osaka Y, et al. Dose escalation study of carbon ion radiotherapy for locally advanced head-and-neck cancer. *Int J Radiat Oncol Biol Phys.* 2004; 60: 358-364.
29. Tsujii H, Mizoe J, Kamada T, Baba M, Tsuji H, Kato H, et al. Clinical Results of Carbon Ion Radiotherapy at NIRS. *J Radiat Res.* 2007; 48 Suppl A: A1-1A13.
30. Yanagi T, Mizoe JE, Hasegawa A, Takagi R, Bessho H, Onda T, et al. Mucosal malignant melanoma of the head and neck treated by carbon ion radiotherapy. *Int J Radiat Oncol Biol Phys.* 2009; 74: 15-20.
31. Ohno T, Kanai T, Yamada S, Yusa K, Tashiro M, Shimada H, et al. Carbon Ion Radiotherapy at the Gunma University Heavy Ion Medical Center: New Facility Set-up. *Cancers (Basel).* 2011; 3: 4046-4060.

Cite this article

Takahashi T, Saitoh JI, Shirai K, Nishimura K, Ohno T, et al. (2014) Carbon-ion Radiotherapy for Non-squamous Cell Head and Neck Malignancies. *J Radiol Radiat Ther* 2(2): 1046.