

Journal of Radiology & Radiation Therapy

Special Issue on Head and Neck Imaging

Edited by:

Review Article

Potential Applications of Dual Energy Computed Tomography in Dentomaxillofacial Imaging

Tanaka R* and Hayashi T

Department of Tissue Regeneration and Reconstruction, Division of Oral and Maxillofacial Radiology, Niigata University Graduate School of Medical and Dental Sciences, Japan

Abstract

Dual Energy or dual source Computed Tomography (DECT) is advantageous for clinical CT interpretation. Compared to conventional imaging, this technique enables tissue differentiation of tissues, such as kidney stones, with higher precision and has additional features such as automatic bone-, bone marrow-, and plaque removal and virtual non-contrast image generation. Moreover, DECT can potentially remove beam hardening artifacts and generate images as good as those acquired using monoenergetic high energy. This review includes studies on DECT dentomaxillofacial imaging and discusses potential applications of DECT in dentomaxillofacial imaging, focusing on monoenergetic imaging.

ABBREVIATIONS

DECT: Dual Energy Computed Tomography; CT: Computed Tomography

INTRODUCTION

Computed Tomography (CT) is an indispensable tool for diagnostic imaging of dentomaxillofacial disease, particularly conditions requiring surgical intervention. CT is used widely to provide a three-dimensional image with satisfactory spatial resolution of the bone and tooth condition; however, imaging artifacts caused by metallic dental materials critically impair the quality of diagnostic images. Because conventional CT uses a

polychromatic X-ray beam, its mean energy is shifted to a higher level when passing through an object. This beam-hardening effect can cause two types of artifacts: so-called cupping artifacts and dark-bands or streaks between dense objects. In recent years, Dual Energy Computed Tomography (DECT) has proved advantageous in clinical CT interpretation. Dual energy imaging has two advantages (1), accurate tissue differentiation and (2) image quality improvement. The technique enables differentiation of tissues with higher precision compared to conventional imaging, such as the differentiation kidney stones; additional useful features include automatic bone and plaque removal. DECT also reduces the beam-hardening and blooming artifacts, and improves image contrast (Figure 1A, 1B, 1C, Figure 2).

*Corresponding author

Ray Tanaka, Division of Oral and Maxillofacial Radiology, Department of Tissue Regeneration and Reconstruction, Niigata University Graduate School of Medical and Dental Sciences, 2-5274 Gakkocho-dori, Chuo-ward, Niigata 951-8514 Japan, Tel: +81-25-227-2916; Fax: +81-25-227-0810; E-mail: renahky@dent.niigata-u.ac.jp

Submitted: 26 January 2014

Accepted: 28 February 2014

Published: 12 March 2014

ISSN: 2333-7095

Copyright

© 2014 Tanaka et al.

OPEN ACCESS

Keywords

- Dual energy computed tomography
- Metal artifact reduction
- Monoenergetic imaging
- Dentomaxillofacial imaging

Only two studies are known at present in MEDLINE that evaluate dentomaxillofacial imaging with monoenergetic imaging after DECT [1,2]; both discuss the differentiation of metal artifacts from dental metals. Many other studies confirm that monoenergetic imaging successfully improved image quality, accuracy, and diagnostic confidence while reducing image artifacts from dense objects in other similar clinical applications [3-32]. This review discusses dentomaxillofacial imaging with DECT and its potential applications, focusing on monoenergetic imaging.

DECT systems

DECT systems are categorized into three types according to the number of X-ray tubes and detectors: dual X-ray tubes with dual detectors (Dual-source dual energy CT; the SIEMENS Dual Energy CT scanners); a single X-ray tube with a single detector

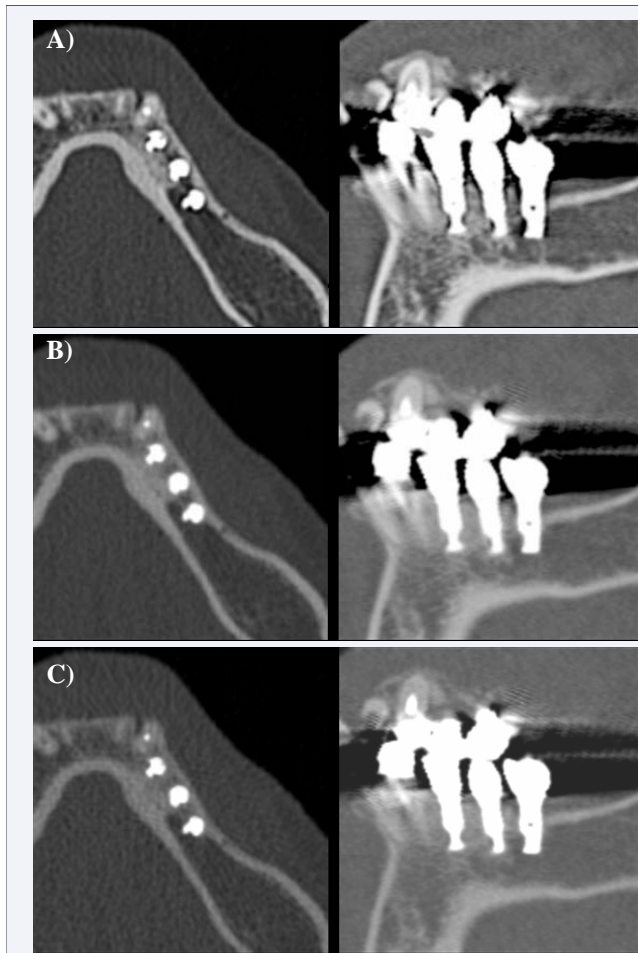


Figure 1 Three unique CT reconstructions using identical data sets.

(A) Standard 120-kV spectrum (DE120) image equivalent to conventional single-energy CT image; (B) hypothetical monoenergetic images equivalent to 100 keV (ME100) images; and (C) hypothetical monoenergetic images equivalent to 190 keV (ME190) images.

Increased reduction of dark-band-like artifacts encircling dental implants was observed in both hypothetical monoenergetic image types (ME100, ME190) compared to a standard 120-kV image (DE120).

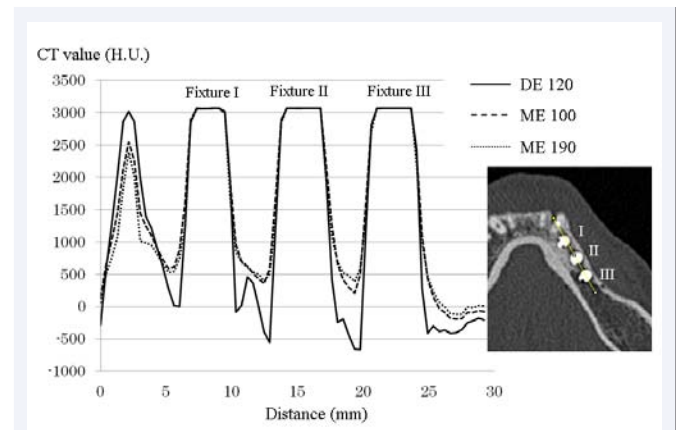


Figure 2 CT radiodensity profiles of DE120, ME100, and ME190 images.

Artifacts were reduced between the implants, illustrated in the CT radiodensity profiles of hypothetical monoenergetic images equivalent to 100 keV (ME100) images and 190 keV (ME190), compared to the standard 120-kV spectrum (DE120) profile.

(Dual-energy CT with fast kilovoltage switching; GE Healthcare Dual Energy CT scanner); and a single X-ray tube with dual detectors (Multilayered-detector dual-energy CT with Dual-Spin; PHILIPS Healthcare Dual Energy CT scanner) [33] (Table 1). The dual source DECT system used in our institute administers high and low energy X-ray beams using dual tubes mounted on a CT gantry at a mechanical offset of 95 degrees.

The GE Healthcare Dual Energy CT scanner employs a single X-ray tube and single detector equipped with new scintillator materials made of gemstone. Gemstone spectral imaging using fast kV switching enables the unit to obtain equivalent density images and monochromatic images. However, this system has limited spectral separation between high and low energy scans compared to dual-source dual energy CT. Alternatively, multilayered-detector dual-energy CT with Dual-Spin could alleviate this problem [33,34]. The technical principles and relative advantages of the three types of DECT scanners are summarized in Table 1. The technical details of available DECT units and scanning approaches are detailed in previous studies [33,34].

Hypothetical monoenergetic images

Hypothetical monoenergetic images are synthesized using dual-energy projection data [35]. During DECT, the target is simultaneously scanned with two different X-ray beams of different peak energy levels, usually 80 and 140 Kilovolt Peaks (kVp), and the X-ray attenuation of the target is measured with two different X-ray spectrums [2]. With this information, simulated monoenergetic or monochromatic images are created based on the mean absorption spectra of a discrete photon from 40 keV to 190 keV. This allows theoretical image reconstruction at high keV without increasing the actual tube voltage and, therefore, without increasing patient dose. Beam hardening artifact reduction is one of the main benefits of monoenergetic dual-energy CT [33]; further details on monoenergetic imaging are discussed in prior studies [33,35,36]. The images in the present review were acquired using

Table 1: Technical principles and advantages of DECT systems.

Scanner type	Dual-source dual energy CT		Dual-energy CT with fast kilovoltage switching	Multilayered-detector dual-energy CT with dual-spin
	64-slice	128-slice		
Hardware Description	dual tubes, dual detectors		single tube, single detector	single tube, dual detector layers
Detector configuration	2 × 32 × 0.625	2 × 64 × 0.625	64 × 0.625	2 × 32 × 0.625
FOV [cm]	26	33	50	50
Gantry rotation time for dual-energy acquisition [ms]	330	300	350	400
Advantages	Good spectral separation between high and low energy scans		Good temporal and spatial registration	Perfect temporal and spatial registration

Abbreviations: CT: Computed Tomography; FOV: Field of View.

Table 2: Summary of two dentomaxillofacial imaging studies.

Authors	Tanaka et al.	Stolzmann et al.
Purpose	To evaluate the usefulness of hypothetical monoenergetic images after DECT for assessment of the bone encircling dental implant bodies	To assess the potential of monoenergetic CT images to reduce beam hardening artifacts in comparison to standard SECT images of dental restoration on dental postmortem CT
Subjects	Monoenergetic and fused images after DECT of 24 dental implant bodies in 5 patients	Monoenergetic and standard SECT images from 30 human decedents with dental restorations
Design	Subjective assessment Statistical analysis	Objective and subjective assessment Statistical analysis
Conclusion	Monoenergetic CT images reduce dark-band-like artifacts encircling dental implant bodies and improve diagnosability of the adjacent bone condition	Monoenergetic CT reconstructions reduce beam hardening artifacts from dental restorations and improve image quality

Abbreviations: CT: Computed Tomography; SECT: Single Energy Computed Tomography; DECT: Dual Energy Computed Tomography.

a 128-slice dual source CT (SOMATOM Definition Flash, Siemens Medical Solutions, Forchheim, Germany) in dual energy mode on patients who consulted our institution. Imaging data acquired from the patients were post-processed at the workstation with the monoenergetic application of Syngo Dual Energy software version VE31 (Siemens Medical Solutions, Erlangen, Germany). The term monoenergetic is used in this context for the remainder of the article; “monoenergetic” and “monochromatic” refer to terminology in separate studies.

DECT in dentomaxillofacial imaging

Computed Tomography (CT) is currently in clinical use in dentistry. The now dominant multi-detector row CT has enabled better performance in imaging rapidity and spatial resolution. In addition, improved computer graphics and workstation performance have made imaging representation and 3D measurements easier and faster. Such technological advancement is remarkable, but metallic artifacts on CT images still remain problematic. In dentistry, these artifacts are usually caused by metallic dental fillings or crown prosthesis, and it is nearly impossible to evaluate pathology located adjacent to the metal artifact. Furthermore, a variety of metallic devices can spoil the image data, such as orthodontic metal braces, dental implants, and screws and plates used for fixation or reconstruction after fractures, orthognathic surgery, osteotomy, and mandibular dissection followed by tumor resection. Solving the problem of metal artifacts is crucial for dentistry.

Tanaka et al. [1] assessed the bone encircling dental implant bodies using axial images obtained from DECT image data scanned in dual-energy mode. They subjectively evaluated the adjacent bone focusing on (1) the degree of remaining dark-band-like artifact encircling each implant body, and (2) ability to diagnose bone condition in 3 sets of DECT images:

a fused image set equivalent to a standard 120-kV spectrum, and 2 sets of hypothetical monoenergetic images equivalent to images obtained at 100 keV and 190 keV. The results showed a statistically significant artifact reduction in hypothetical monoenergetic images and improved diagnostic utility compared to the fused image. They concluded that DECT might be promising for evaluating postoperative bone changes encircling dental implants.

Stolzmann et al. [2] investigated the application of DECT to dental post-mortem CT. They objectively and subjectively assessed the potential of monoenergetic images to reduce dental restoration beam hardening artifacts compared to standard CT images. They administered monoenergetic imaging at four energy levels, 64, 69, 88 keV, and an optimal energy level (OPTkeV), and compared the findings to those of standard single-energy CT. The results revealed that beam hardening artifacts decreased significantly as monoenergy increased, and the quality of monoenergetic CT images was superior to standard CT images. They concluded that monoenergetic CT reconstructions significantly reduced dental restoration beam hardening artifacts and improved the image quality of post-mortem dental CT.

DISCUSSION AND CONCLUSION

The study of dual-energy CT has a long history, with hundreds of studies, including clinical and theoretical studies, discussing the two primary advantages of DECT, accurate tissue differentiation and improved image quality. The present review evaluates over 32 studies investigating the clinical applications of virtual monoenergetic imaging, including ex-vivo and phantom studies, but only 2 studies specifically evaluate its utility in dental CT imaging. Both studies sought to reduce dental metallic image artifacts using monoenergetic imaging after DECT. In one study, hypothetical monoenergetic images were useful for evaluating

the postoperative bone condition encircling dental titanium implants, while the second study revealed improved image quality of post-mortem dental CT using the technique (Table 2). Clinical applications to dental implantation and post-mortem dental CT are expected to become more common. In particular, the latter application can be expanded to quickly identify corpses recovered following a disaster. These results support the ability of hypothetical monoenergetic images to improve image quality and diagnostic utility compared to conventional CT. However, the studies may be limited by the subjective assessment method employed. Qualitative and quantitative assessments were used to evaluate image quality or diagnostic interpretability resulting from the reduced metallic artifacts. Point or analog scale scoring was used for qualitative assessment, and CT numbers within a region of interest for quantitative assessment. Qualitative assessment using point or analog scale scoring is subjective because comparison to a true control to evaluate artifact reduction is absent.

Metal artifact reduction and maintenance of diagnostic utility major concerns shared among medical fields using metallic material clinically; several studies in musculoskeletal [3-8] and intracranial imaging [11] have found that virtual monoenergetic images devised from DECT displays can reduce artifacts created by implanted metal orthopedic devices or platinum coils for aneurysm coil embolization. Metallic dental implants in the dentomaxillofacial region usually compose pure titanium, and investigations using different materials may not be applicable. The relationship between different sizes, shapes, or locations of implanted devices and resulting images should be determined in future studies.

To date, research of monoenergetic dentomaxillofacial imaging is restricted to the reduction of metal artifacts. However, this imaging technique is potentially more applicable to dentomaxillofacial imaging. Deng et al. assessed the feasibility of visualizing hand and foot tendon anatomy and pathology using monoenergetic imaging [9,10], and concluded that the targeted regions were displayed more clearly using monochromatic images compared to conventional polychromatic images. Mannelli et al. [14] evaluated the measurement accuracy of calcified carotid endarterectomy specimens using the technique, and they concluded that images obtained at 80 keV provided measurements most similar to the histologic standard, suggesting that monochromatic keV images may reduce blooming artifacts caused by lesion calcification. Kulkarni et al. [31] studied the performance of DECT venography in assessing lower extremity deep venous thrombosis, and found improved intravenous contrast enhancement and higher diagnostic confidence using monochromatic DECT images. These applications of monoenergetic imaging may prove beneficial for dentomaxillofacial imaging in evaluating lesions or pathology. The dentomaxillofacial region comprises markedly high and low dense components, from air to tooth enamel, at close quarters. Given the frequency of treatment using dental materials and the very narrow and small size of targeted structures, CT is highly valued, except for metallic components. Therefore, further investigation is needed to design techniques that provide higher detectability, diagnostic utility, and measurement accuracy of dental pathology.

DECT imaging in the dentomaxillofacial field has some limitations. Although DECT has been widely used in other medical fields and has gradually become standardly equipped on CT systems, its availability in dentistry seems considerably limited. Availability highly depends on circumstances of the respective institutions. Accessibility may be further limited by the lack of a specific application for dentomaxillofacial imaging in currently available software. Notably, our study focused on assessing post-operative bone condition after dental implantation, but, in the case of preoperative bone assessment, the DECT image data and available surgical planning software for dental implantation are incompatible.

Although the literature on dentomaxillofacial DECT imaging is limited, the early results are promising. Further research of novel practical applications of DECT to dentomaxillofacial imaging is required.

REFERENCES

1. Tanaka R, Hayashi T, Ike M, Noto Y, Goto TK. Reduction of dark-band-like metal artifacts caused by dental implant bodies using hypothetical monoenergetic imaging after dual-energy computed tomography. *Oral Surg Oral Med Oral Pathol Oral Radiol.* 2013; 115: 833-838.
2. Stolzmann P, Winklhofer S, Schwendener N, Alkadhi H, Thali MJ, Ruder TD. Monoenergetic computed tomography reconstructions reduce beam hardening artifacts from dental restorations. *Forensic Sci Med Pathol.* 2013; 9: 327-332.
3. Bamberg F, Dierks A, Nikolaou K, Reiser MF, Becker CR, Johnson TR. Metal artifact reduction by dual energy computed tomography using monoenergetic extrapolation. *Eur Radiol.* 2011; 21: 1424-1429.
4. Zhou C, Zhao YE, Luo S, Shi H, Li L, Zheng L, et al. Monoenergetic imaging of dual-energy CT reduces artifacts from implanted metal orthopedic devices in patients with fractures. *Acad Radiol.* 2011; 18: 1252-1257.
5. Wang Y, Qian B, Li B, Qin G, Zhou Z, Qiu Y, et al. Metal artifacts reduction using monochromatic images from spectral CT: evaluation of pedicle screws in patients with scoliosis. *Eur J Radiol.* 2013; 82: e360-366.
6. Srinivasan A, Hoeffner E, Ibrahim M, Shah GV, LaMarca F, Mukherji SK. Utility of dual-energy CT virtual keV monochromatic series for the assessment of spinal transpedicular hardware-bone interface. *AJR Am J Roentgenol.* 2013; 201: 878-883.
7. Guggenberger R, Winklhofer S, Osterhoff G, Wanner GA, Fortunati M, Andreisek G, et al. Metallic artefact reduction with monoenergetic dual-energy CT: systematic ex vivo evaluation of posterior spinal fusion implants from various vendors and different spine levels. *Eur Radiol.* 2012; 22: 2357-2364.
8. Lee YH, Park KK, Song HT, Kim S, Suh JS. Metal artefact reduction in gemstone spectral imaging dual-energy CT with and without metal artefact reduction software. *Eur Radiol.* 2012; 22: 1331-1340.
9. Deng K, Li W, Wang JJ, Wang GL, Shi H, Zhang CQ. The pilot study of dual-energy CT gemstone spectral imaging on the image quality of hand tendons. *Clin Imaging.* 2013; 37: 930-933.
10. Deng K, Zhang CQ, Li W, Wang JJ, Wang XY, Pang T, et al. Preliminary application of high-definition CT Gemstone Spectral Imaging in hand and foot tendons. *Korean J Radiol.* 2012; 13: 743-751.
11. Shinohara Y, Sakamoto M, Iwata N, Kishimoto J, Kuya K, Fujii S, et al. Usefulness of monochromatic imaging with metal artifact reduction software for computed tomography angiography after intracranial aneurysm coil embolization. *Acta Radiol.* 2013.

12. Kamiya K, Kunimatsu A, Mori H, Sato J, Akahane M, Yamakawa T, et al. Preliminary report on virtual monochromatic spectral imaging with fast kVp switching dual energy head CT: comparable image quality to that of 120-kVp CT without increasing the radiation dose. *Jpn J Radiol.* 2013; 31: 293-298.
13. Pomerantz SR, Kamalian S, Zhang D, Gupta R, Rapalino O, Sahani DV, et al. Virtual monochromatic reconstruction of dual-energy unenhanced head CT at 65-75 keV maximizes image quality compared with conventional polychromatic CT. *Radiology.* 2013; 266: 318-325.
14. Mannelli L, Mitsumori LM, Ferguson M, Xu D, Chu B, Branch KR, et al. Changes in measured size of atherosclerotic plaque calcifications in dual-energy CT of ex vivo carotid endarterectomy specimens: effect of monochromatic keV image reconstructions. *Eur Radiol.* 2013; 23: 367-374.
15. Yuan R, Shuman WP, Earls JP, Hague CJ, Mumtaz HA, Scott-Moncrieff A, et al. Reduced iodine load at CT pulmonary angiography with dual-energy monochromatic imaging: comparison with standard CT pulmonary angiography--a prospective randomized trial. *Radiology.* 2012; 262: 290-297.
16. Delesalle MA, Pontana F, Duhamel A, Faivre JB, Flohr T, Tacelli N, et al. Spectral optimization of chest CT angiography with reduced iodine load: experience in 80 patients evaluated with dual-source, dual-energy CT. *Radiology.* 2013; 267: 256-266.
17. Apfaltrer P, Sudarski S, Schneider D, Nance JW Jr, Haubenreisser H, Fink C, et al. Value of monoenergetic low-kV dual energy CT datasets for improved image quality of CT pulmonary angiography. *Eur J Radiol.* 2014; 83: 322-328.
18. Dong J, Wang X, Jiang X, Gao L, Li F, Qiu J, et al. Low-contrast agent dose dual-energy CT monochromatic imaging in pulmonary angiography versus routine CT. *J Comput Assist Tomogr.* 2013; 37: 618-625.
19. Cheng J, Yin Y, Wu H, Zhang Q, Hua J, Hua X, et al. Optimal monochromatic energy levels in spectral CT pulmonary angiography for the evaluation of pulmonary embolism. *PLoS One.* 2013; 8: e63140.
20. Hu D, Yu T, Duan X, Peng Y, Zhai R. Determination of the optimal energy level in spectral CT imaging for displaying abdominal vessels in pediatric patients. *Eur J Radiol.* 2014; 83: 589-594.
21. Pinho DF, Kulkarni NM, Krishnaraj A, Kalva SP, Sahani DV. Initial experience with single-source dual-energy CT abdominal angiography and comparison with single-energy CT angiography: image quality, enhancement, diagnosis and radiation dose. *Eur Radiol.* 2013; 23: 351-359.
22. Zhao LQ, He W, Li JY, Chen JH, Wang KY, Tan L. Improving image quality in portal venography with spectral CT imaging. *Eur J Radiol.* 2012; 81: 1677-1681.
23. Lin XZ, Wu ZY, Tao R, Guo Y, Li JY, Zhang J, et al. Dual energy spectral CT imaging of insulinoma-Value in preoperative diagnosis compared with conventional multi-detector CT. *Eur J Radiol.* 2012; 81: 2487-2494.
24. Li X, Zhao R, Liu B, Yu Y. Gemstone spectral imaging dual-energy computed tomography: a novel technique to determine urinary stone composition. *Urology.* 2013; 81: 727-730.
25. Jung DC, Oh YT, Kim MD, Park M. Usefulness of the virtual monochromatic image in dual-energy spectral CT for decreasing renal cyst pseudoenhancement: a phantom study. *AJR Am J Roentgenol.* 2012; 199: 1316-1319.
26. Scheske JA, O'Brien JM, Earls JP, Min JK, LaBounty TM, Cury RC, et al. Coronary artery imaging with single-source rapid kilovolt peak-switching dual-energy CT. *Radiology.* 2013; 268: 702-709.
27. Okayama S, Seno A, Soeda T, Takami Y, Kawakami R, Somekawa S, et al. Optimization of energy level for coronary angiography with dual-energy and dual-source computed tomography. *Int J Cardiovasc Imaging.* 2012; 28: 901-909.
28. Fuchs TA, Stehli J, Fiechter M, Dougoud S, Gebhard C, Ghadri JR, et al. First experience with monochromatic coronary computed tomography angiography from a 64-slice CT scanner with gemstone spectral imaging (GSI). *J Cardiovasc Comput Tomogr.* 2013; 7: 25-31.
29. Okayama S, Soeda T, Takami Y, Kawakami R, Somekawa S, Uemura S, et al. The influence of effective energy on computed tomography number depends on tissue characteristics in monoenergetic cardiac imaging. *Radiol Res Pract.* 2012; 2012: 150980.
30. So A, Lee TY, Imai Y, Narayanan S, Hsieh J, Kramer J, et al. Quantitative myocardial perfusion imaging using rapid kVp switch dual-energy CT: preliminary experience. *J Cardiovasc Comput Tomogr.* 2011; 5: 430-442.
31. Kulkarni NM, Sahani DV, Desai GS, Kalva SP. Indirect computed tomography venography of the lower extremities using single-source dual-energy computed tomography: advantage of low-kiloelectron volt monochromatic images. *J Vasc Interv Radiol.* 2012; 23: 879-886.
32. Sudarski S, Apfaltrer P, W Nance J Jr, Schneider D, Meyer M, Schoenberg SO, et al. Optimization of keV-settings in abdominal and lower extremity dual-source dual-energy CT angiography determined with virtual monoenergetic imaging. *Eur J Radiol.* 2013; 82: e574-581.
33. Kraśnicki T, Podgórski P, Guziński M, Czarnecka A, Tupikowski K, Garcarek J, et al. Novel clinical applications of dual energy computed tomography. *Adv Clin Exp Med.* 2012; 21: 831-841.
34. Karçaaltıncaba M, Aktaş A. Dual-energy CT revisited with multidetector CT: review of principles and clinical applications. *Diagn Interv Radiol.* 2011; 17: 181-194.
35. Yu L, Christner JA, Leng S, Wang J, Fletcher JG, McCollough CH. Virtual monochromatic imaging in dual-source dual-energy CT: radiation dose and image quality. *Med Phys.* 2011; 38: 6371-6379.
36. Pessis E, Campagna R, Sverzut JM, Bach F, Rodallec M, Guerini H, et al. Virtual monochromatic spectral imaging with fast kilovoltage switching: reduction of metal artifacts at CT. *Radiographics.* 2013; 33: 573-583.

Cite this article

Tanaka R, Hayashi T (2014) Potential Applications of Dual Energy Computed Tomography in Dentomaxillofacial Imaging. *J Radiol Radiat Ther* 2(2): 1048.