

## Case Report

# Post-Abortal Placental Polyp Masquerading Uterine Leiomyoma: A Case Report

Samanta A\*, Majhi AK, Rakshit A, Mallick A, and Mandal K

Department of Gynaecology and Obstetrics, RG Kar Medical College and Hospital, Kolkata, India

## \*Corresponding author

Ajanta Samanta, Department of Gynaecology and Obstetrics, RG Kar Medical College and Hospital, Flat U 302, Binayak Enclave, 59 Kali Charan Ghosh Road, Kolkata, 700050, West Bengal, India, Tel: 91 9836567672; Email: drajanta@gmail.com

Submitted: 30 November 2016

Accepted: 14 February 2017

Published: 15 February 2017

## Copyright

© 2017 Samanta et al.

## OPEN ACCESS

## Keywords

- Placental polyp
- Serum  $\beta$ -human chorionic gonadotropin ( $\beta$ HCG)
- Chorionic villi
- Ultrasonography
- Histopathology

## Abstract

Placental polyp is a organized mass of retained bits of placental tissue following delivery, which is hyalinized during their prolonged retention. It is a rare entity, histologically composed of necrotic and hyalinized chorionic villi. These placental masses present within days to weeks following an abortion or delivery of a term placenta. The usual clinical presentations are abnormal uterine bleeding and small rise and detectable titers of serum  $\beta$ -human chorionic gonadotropin ( $\beta$ HCG). Here we reported a case of 25 years lady P1+1 presented with the chief complaint of intermittent vaginal bleeding since her last medical termination of pregnancy 3 months ago along with uterine enlargement. Ultrasonographic finding showed in homogenous hypoechoic intrauterine lesion with cystic degeneration suggestive of myoma. So myomectomy was planned, and during myomectomy endometrial cavity was opened and a polypoidal mass was found mostly confined to endometrial cavity. The mass was removed and uterus was repaired in layers. There was a strong suspicion of placental polyp or decidual cast on clinical examination of the mass, and for that serum  $\beta$ -human chorionic gonadotropin level was done and it was found to be slightly elevated. Hystopathologic finding came as degerated chorionic villi with necrosis and inflammation suggestive of placental polyp.

## INTRODUCTION

Placental polyp is the piece of placental tissue organized after prolonged retention following delivery or abortion, histologically composed of necrotic and hyalinized chorionic villi. It is a rare entity and its estimated incidence is around 1 in 40,000-60,000 deliveries [1]. It presents as a polypoidal mass within the uterine cavity with broad or a short pedicle. Mostly these polyps occur after therapeutic abortion and spontaneous delivery and are rare after spontaneous abortion [2]. These masses are often found within days to weeks following abortion or delivery of a term placenta. However, they rarely present after months or even years following antecedent pregnancy [3].

Trophoblastic neoplasms especially placental site trophoblastic tumor may have similar symptoms and signs, it is important to consider placental polyp in differential diagnosis in such situations. Patients usually present with symptoms like heavy bleeding or discharge per vaginum since the time of childbirth or miscarriage. Diagnosis is made by colour Doppler ultrasound [4]. Placental polyp can easily be diagnosed by hysteroscopy and managed subsequently by resection of the polyp under vision and then confirm the diagnosis by histopathology.

## CASE PRESENTATION

A 25-year-old P1+1 woman came with abnormal uterine

bleeding since her last medical termination of pregnancy 3 months ago. She had heavy menstrual bleeding along with intermenstrual bleeding with complete irregular cycle for that period. On examination she had mild pallor. On gynaecological examination, uterus was found to be smoothly enlarged and around 12 weeks size. Ultrasound examination revealed inhomogenous hypoechoic intrauterine lesion with cystic degeneration suggestive of myoma (Figure 1). So myomectomy was planned. On laparotomy, uterus was found to be smoothly enlarged, around 12 weeks size, without any detectable subserosal myoma. Myoma was assumed to be intramural, and myomectomy was planned with anterior uterine transverse incision. During myomectomy endometrial cavity was opened and a polypoidal mass was found mostly confined to endometrial cavity. The mass was 6 cm  $\times$  4 cm  $\times$  4 cm size. The mass was removed after ligating the stock, which was thick and uterus was repaired in layers. The mass was red-colored with a smooth outer surface and fragile consistency without any permeation into the myometrium (Figure 2). There was a strong suspicion of placental polyp or decidual cast on clinical examination of the mass, and for that serum  $\beta$ -human chorionic gonadotropin level was done and it was found to be slightly elevated (36 IU). Hystopathologic finding came as degerated chorionic villi with necrosis and inflammation suggestive of placental polyp (Figure 3). Final diagnosis was placental polyp according to macroscopic

and microscopic findings. Serum HCG fell rapidly to undetectable level following surgery. The patient has been well after surgery.

## DISCUSSION

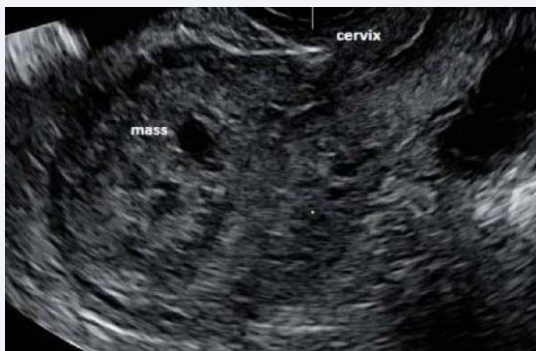Placental polyp is a piece of retained placental tissue in the uterus that has undergone neovascularization after resolution of gestation. Most commonly, placental polyp occurs after therapeutic abortion and spontaneous delivery. It is extremely rare after spontaneous abortion. Abnormal vaginal bleeding after abortion or delivery may indicate the presence of placental polyp. The villi may be necrotic, hyalinized, or partially calcified. They form a nidus for inflammation and bleeding. These pedunculated masses of villi are often found within days to weeks following

abortion or delivery of a term placenta. Rarely, they persist for months or even years after pregnancy [3]. Abnormal uterine bleeding due to placental polyp has been attributed to preserved villi, clusters of destructive villi, and isolated viable cotyledons. Ultrasound with color Doppler imaging can diagnose placental polyp with abundant blood flow [5]. Computed tomographic angiography is also useful in diagnosis and management of placental polyp with neovascularization [6]. Magnetic resonance imaging may also be used in diagnosis and follow-up of placental polyps [7]. The most clinically significant placental polyp is the hypervascular type. A hypervascular placental polyp may lead to severe hemorrhage that requires blood transfusions, interventional radiology procedures, hysteroscopic resection, and even hysterectomy to control bleeding. Evaluation of neovascularization by multimodal imaging is potentially useful in management of placental polyp in women who wish to preserve fertility.

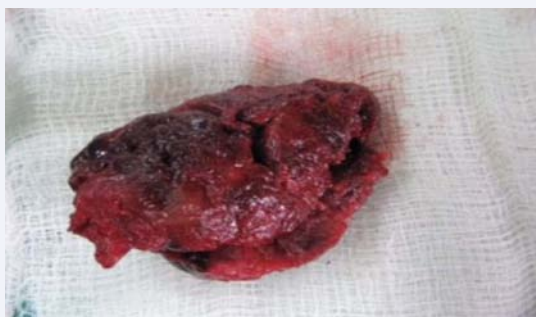Successful treatment with the use of iliac artery occlusion catheters and concomitant hysteroscopic resection has been reported [8]. Local injections of methotrexate have also been used in the treatment of placental polyp [7]. Intraoperative injection of prostaglandin F<sub>2</sub> $\alpha$  followed by hysteroscopic resection has been successful in management of these cases [9]. Our case has been treated with surgical removal after ligating the stock. Serum HCG fell to undetectable level following surgery. Although a proper preoperative diagnosis by clinical suspicion with accurate interpretation of imaging findings might have prevented laparotomy in our patient and hysteroscopic removal would be a better option. Placental polyp should be considered in any case of parous woman with unexplained abnormal uterine bleeding and slightly elevated serum HCG level. The history of the last pregnancy is sometimes very remote. This does not exclude the possibility of the presence of a placental polyp as the source of abnormal bleeding.

## REFERENCES

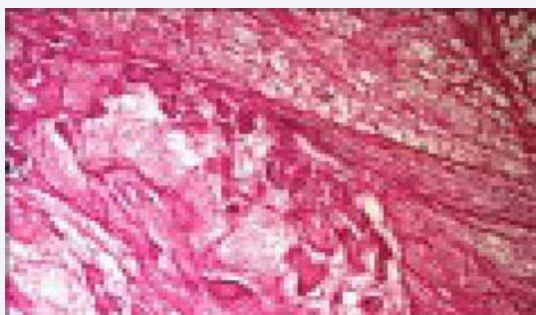
1. Watcharotone W, Leelaphatanadit C. Placental polyp: a case report. *Siriraj Med J.* 2005; 57: 391-392.
2. Kaneko M, Harima H, Okagaki R, Hosoya I, Shigemitsu S, Kasahara K, et al. [A case of placental polyp developed by immediately after spontaneous abortion]. *Nihon Sanka Fujinka Gakkai Zasshi.* 1992; 44: 255-257.
3. Mazur TM, Kurman RJ. 2nd ed. New York: Springer; *Diagnosis of Endometrial Biopsies and Curettings: A Practical Approach.* 2005; 61.
4. Polat P, Suma S, Kantarcý M, Alper F, Levent A. Color Doppler US in the evaluation of uterine vascular abnormalities. *Radiographics.* 2002; 22: 47-53.
5. Takeuchi K, Sugimoto M, Kitao K, Yoshida S, Maruo T. Pregnancy outcome of uterine arterial embolization followed by selective hysteroscopic removal of a placental polyp. *Acta Obstet Gynecol Scand.* 2007; 86: 22-25.
6. Takeda A, Koyama K, Imoto S, Mori M, Sakai K, Nakamura H, et al. Computed tomographic angiography in diagnosis and management of placental polyp with neovascularization. *Arch Gynecol Obstet.* 2010; 281: 823-828.
7. Kurachi H, Maeda T, Murakami T, Tsuda K, Sakata M, Nakamura H, et al. MRI of placental polyps. *J Comput Assist Tomogr.* 1995; 19: 444-448.



**Figure 1** Inhomogenous hypoechoic intrauterine lesion with cystic degeneration suggestive of myoma.



**Figure 2** A large red polypoid mass with smooth outer surface within endometrial cavity.



**Figure 3** Degenerated chorionic villi with necrosis and inflammation suggestive of placental polyp.

8. Marques K, Looney C, Hayslip C, Gavrilova-Jordan L. Modern management of hypervascular placental polypoid mass following spontaneous abortion: a case report and literature review. *Am J Obstet Gynecol.* 2011; 205: 9-11.
9. Maegawa M, Mitani R, Miyatani Y, Ueta S, Endo S, Senuma M, et al. A case of placental polyp treated with an intraoperative injection of prostaglandin F2a followed by hysteroscopic resection. *Reprod Med Biol.* 2012; 11: 105-108.

**Cite this article**

Samanta A, Majhi KA, Rakshit A, Mallick A, Mondal K (2017) Post-Abortal Placental Polyp Masquerading Uterine Leiomyoma: A Case Report. *Ann Reprod Med Treat* 2(1): 1009.