

## Case Report

# Preoperative Progressive Pneumoperitoneum Complementing the Surgical Treatment of a Big Scrotal Hernia with “Loss of Domain”: A Case Report

Nicola Cerasani<sup>1\*</sup>, Andreas Türler<sup>1</sup>, Markus Maria Heiss<sup>2</sup>, and Dirk Rolf Bulian<sup>2</sup>

<sup>1</sup>Department of Visceral Surgery, Johanniter Medical Center, Germany

<sup>2</sup>Department of Surgery, University of Witten / Herdecke, Germany

**\*Corresponding author**

Nicola Cerasani, Department of Visceral Surgery, Johanniter Medical Center, Johanniterstrasse 1-3, D-53113 Bonn, Germany, Tel: 49-0228-543-3542; Email: Nicola.Cerasani@johanniter-kliniken.de

Submitted: 02 February 2017

Accepted: 12 April 2017

Published: 14 April 2017

ISSN: 2379-0911

**Copyright**

© 2017 Cerasani et al.

**OPEN ACCESS****Keywords**

- Inguinal hernia
- Giant hernia
- Loss of domain
- Incisional hernia

**Abstract**

Giant inguinoscrotal hernias with loss of abdominal domain are a significant limitation of life quality in patients and represent a demanding surgical problem. A 68-year-old male patient presented with a giant right sided inguinoscrotal hernia existing for two years. Due to the “loss of domain” problem we decided, to perform a preoperatively condition of the abdominal by using a progressive pneumoperitoneum before the actual treatment of the hernia. In the scope of laparoscopy, a central venous catheter was inserted into the abdominal cavity. After placing the catheter in the right abdominal cavity first intraoperative ambient air insufflations of 2500 ml was ensued. On day seven after the beginning of the air insufflations, we performed the actual surgical treatment of the hernia according to the Lichtenstein procedure with a 20x15cm large Ultra-Pro Mesh™. The patient showed regular postoperative progress with non irritated wounds during the time. With regular bowel movements we were able to discharge the patient on the fifth postoperative day. The procedure with preoperative pneumatic dilatation of the peritoneal space allows hernia reconstruction even in giant inguinoscrotal hernias with a “loss of domain” problem.

**ABBREVIATIONS**

CT: Computed Tomography

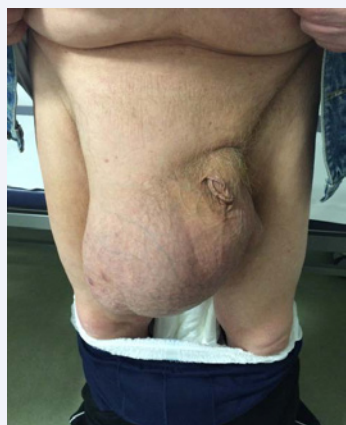**INTRODUCTION**

Big scrotal hernias are defined as inguinal hernia reaching to the middle of the femora in standing position of the patient [1]. Scrotal hernia with herniation of the small and large intestines imitate quality of life in patients and constitute a challenging surgical problem [1,2-6]. There are specific problems associated with this kind of hernias including loss of domain [7,8], such as the Patients often suffer from urine incontinence, as well as defecation disorders up to skin ulcers. In addition, the penis can get buried inside the scrotum causing urine to dribble over the vulnerable scrotal skin, which is congested to lymphatic and venous edema, causing excoriation, ulceration, and secondary infection [8].

**CASE PRESENTATION**

A 68 year old patient presented with a for 2 years existing right scrotal hernia (Figure 1). His medical history showed chronic obstructive pulmonary disease GOLD staging 1 and a chronic nicotine abuse. His quality of life was significantly reduced by the hernia, suffering from irregular stool and walking disability, by just being able to walk with a wheeled walker. The physical examination showed a huge scrotal hernia with loss of domain, reaching to knee level in upright position (Figure 1). He showed no signs of inflammation or ulceration of the scrotal skin.

A preoperative contrast-enhanced computed tomography (CT) scan showed herniation of the small intestines and colon, without any signs of passage disorder (Figure 2). Due to the loss of domain difficulty we decided to condition the abdominal wall by using a progressive pneumoperitoneum before definitive treatment of the hernia.



**Figure 1** Preoperative finding.

To control the pain during the procedure, a peridural catheter was perioperatively applied and fitted with Ropivacain™ 0, 2%. With an open approach we placed a 10 mm laparoscopic camera port in general anesthesia in the left flank. The explorative laparoscopy showed no further pathologies than the known hernia.

Under visual control a central venous catheter was placed in the left anterior axillary line below the ribs and incorporated in the abdominal cavity. After intraperitoneal positioning of the catheter on the right side of the abdominal cavity and connecting to an air filter the first intraoperative insufflations of 2500ml ambient air in the abdominal cavity ensued. Due to the preoperative applied peridural catheter a daily insufflations of 1000 to 1500 ml was possible without causing any pain. The total insufflated air was approximately 10.900 ml.

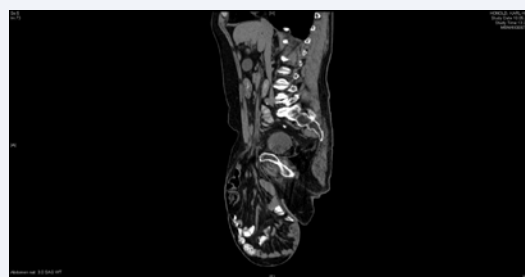
Figure (3) shows the clinical finding after 7 days of daily insufflations. The progressive dilatation can lead to serious complications such as renal insufficiency and thrombosis of the vena cava inferior. Because of this, the patient was stationary all the time. On the seventh day we performed the definitive surgical treatment of the scrotal hernia. Perioperatively a single shot antibiotics with Unacid™ 3 gr i.v. was administered. A 15 cm diagonally skin incision is placed 1 cm above the Os pubis on the right side. The externus aponeurosis was prepared and incised. On an account of the size of hernia content we first opened the hernial sac-containing caecum, ascending colon, transverse colon as well as large parts of the small intestines (Figure 4). After extensive adhesiolysis we were able to reposition the hernia content easily into the abdominal cave. We were able to remove most of the hernial sac, where as the remainder was closed with a continuous suture (PDS 3/0™). The fascia transversalis was closed whit a continuous Vicryl™ suture 3/0. Accordingly to the EHS guidelines (10) we performed a Lichtenstein procedure for surgical treatment of the hernia by placing a 20x15 cm Ultra-Pro-mesh™.

The mesh was fixed to the inguinal ligament with a continuous Prolene™ 2/0 suture and to the abdominal internal oblique muscle with single button Vicryl™ 3/0 sutures. Figure (5) shows the correct position of the mesh after performing Lichtenstein procedure. One easy flow drainage was inserted into the scrotal

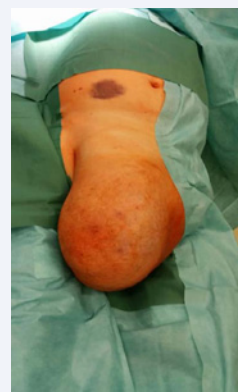sac and one Redon drainage was inserted into the subcutaneous tissue. The subcutaneous closure was accomplished with single button Vicryl™ 3/0 sutures. The cutaneous closure was performed by non-dissolving sutures. Figure (6) shows the result after finishing the operation. The patient showed regular postoperative progress with non-irritated wounds during the inpatient period. With regular bowel movements we were able to discharge the patient on the fifth postoperative day. The postoperative control after four weeks showed a good clinical result (Figure 7).

## DISCUSSION

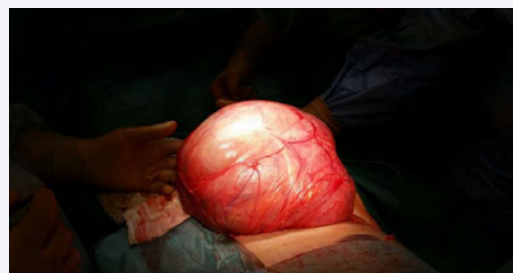Giant inguinoscrotal hernias are rare and usually the result of neglect or fear of surgical procedures and are prevalent in the rural population [8]. There are specific problems associated with this kind of hernias including loss of domain [8]. In those situations a standard reposition of big scrotal and Incisional



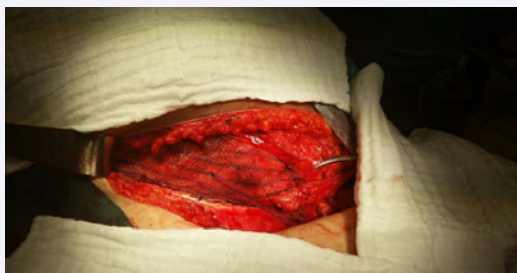**Figure 2** Preoperative CT.



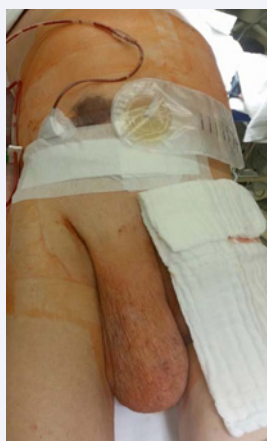**Figure 3** Clinical finding after 7 days of insufflations.



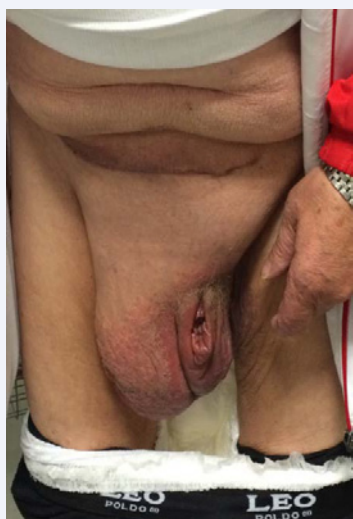**Figure 4** Intraoperative illustration of the hernial sac.



**Figure 5** Position of the mesh after Lichtenstein operation.



**Figure 6** Result at the end of the operation.



**Figure 7** Clinical status after 4 weeks.

hernia are not always possible. The sudden reposition of the hernial content into the abdominal cave, even if it is successful, can cause changes in the intra-abdominal and intra-thoracic pressure which can cause cardiac and respiratory complications up to developing an abdominal compartment syndrome [7]. Techniques were described to overcome these problems including debulking of abdominal contents or enlarging the

abdominal cavity (phrenectomy) [8]. Phrenectomy is done by creating a ventral hernia and using high density polyethylene mesh, scrotal skin flap, or component separation technique. Several musculocutaneous flaps have been used and several component separation techniques have been described [7-9]. The conditioning of the abdominal wall by using a progressive pneumoperitoneum shows an option to treat this hernia orifice [3]. Ian Goni Moreno was the first to use this technique to reposition an epigastric hernia [4,10].

The original description suggested intermittent punctures in the abdominal cave for air-insufflations. This can be avoided by placing an intraperitoneal catheter. To reduce intra-abdominal injuries and to ensure the correct position we perform a laparoscopy in our Department. The daily amount of air-insufflations was 1000 to 1500 ml. In the past pain was a limiting factor for the insufflations. This can be avoided by applying a peridural catheter.

Another limitation factor can be the kidney function which can be suppressed by the high intra-abdominal pressure, what makes daily control of the retention parameters necessary. Furthermore a compression of the vena cava can cause thrombosis, wherefore patients have to be anticoagulated. In cases of discomfort or cardiopulmonary impairment the intraperitoneal air can be surceased with the help of the intra-abdominal drainage reducing the pressure to a physiological level immediately. We have no long term outcomes which can be seen as a limitation of our study.

## CONCLUSION

The preoperative pneumatic dilatation of the peritoneal cave enables the reconstruction of the abdominal wall even in extensive difficult abdominal wall and scrotal hernia.

## ACKNOWLEDGEMENTS

Thanks to Mr. Dr Bulian and Mrs. Richards

## REFERENCES

1. Hodgkinson DJ, McIlrath DC. Scrotal reconstruction for giant inguinal hernias. *Surg Clin North Am.* 1984; 64: 307-313.
2. Hamad A, Marimuthu K, Mothe B, Hanafy M. Repair of massive inguinal hernia with loss of abdominal domain using laparoscopic component separation technique. *J Surg Case Rep.* 2013; 2013.
3. Oprea V, Matei O, Gheorghescu D, Leuca D, Buia F, Rosianu M, et al. Progressive Preoperative Pneumoperitoneum (PPP) as an Adjunct for Surgery of Hernias with Loss of Domain. *Chirurgia (Bucur).* 2014; 109: 664-669.
4. Goni Moreno IG. The rational treatment of hernias and voluminous chronic eventrations: Preparation with progressive pneumoperitoneum. In: Nyhus LM, Condon RE (eds). *Hernia* 2nd edition. Philadelphia: JB Lippincott; 1978.
5. Hodgkinson DJ, McIlrath DC. Scrotal reconstruction for giant inguinal hernias. *Surg Clin North Am.* 1984; 64: 307-313.
6. Mehendale FV, Taams KO, Kingsnorth AN. Repair of a giant inguinoscrotal hernia. *Br J Plast Surg.* 2000; 14: 305-307.
7. Kyle SM, Lovie MJ, Dowle CS. Massive inguinal hernia. *Br J Hosp Med.* 1990; 43: 383-384.

8. Karthikeyan VS, Sistla SC, Ram D, Ali SM, Rajkumar N. Giant Inguinoscrotal Hernia-Report of a Rare Case With Literature Review. *Int Surg*. 2014; 99: 560-564.
9. Serpell JW, Polglase AL, Anstee EJ. Giant inguinal hernia. *Aust N Z J Surg*. 1988; 58: 831-834.
10. Simons MP, Aufenacker T, Bay-Nielsen M, Bouillot JL, Campanelli G, Conze J, et al. European Hernia Society guidelines on the treatment of inguinal hernia in adult patients. *Hernia*. 2009; 13: 343-403.

#### Cite this article

Cerasani N, Türler A, Heiss MM, Bulian DR (2017) Preoperative Progressive Pneumoperitoneum Complementing the Surgical Treatment of a Big Scrotal Hernia with "Loss of Domain": A Case Report. *J Surg Transplant Sci* 5(1): 1049.