

## Special Issue on von Hippel Lindau Disease

Edited by:

**Hiroshi Kanno**

Professor, Department of Neurosurgery, Yokohama City University School of Medicine, Japan

### Review Article

# Current Diagnostic and Therapeutic Strategies in Treatment of CNS Hemangioblastomas in Patients with VHL

Marie T. Krüger<sup>1</sup>, Jan-Helge Klingler<sup>1</sup>, Christine Steiert<sup>1</sup>, Cordula Jilg<sup>2</sup>, Stefan Zschiedrich<sup>3</sup>, Birke Bausch<sup>4</sup>, Vera Van Velthoven<sup>1</sup> and Sven Gläser<sup>1\*</sup>

<sup>1</sup>Department of Neurosurgery, Freiburg University Medical Center, Germany

<sup>2</sup>Department of Urology, Freiburg University Medical Center, Germany

<sup>3</sup>Department of Internal Medicine, Freiburg University Medical Center, Germany

<sup>4</sup>2nd Department of Internal Medicine, Freiburg University Medical Center, Germany

### \*Corresponding author

Sven Gläser, Department of Neurosurgery, Freiburg University Medical Center, Breisacher Str. 64, D-79106, Freiburg, Germany, Tel: 49(0)761-270-50010; Fax: 49(0)761-270-50080; Email: sven.glaesker@uniklinik-freiburg.de

Submitted: 11 November 2013

Accepted: 03 January 2014

Published: 06 January 2014

### Copyright

© 2014 Gläser et al.

OPEN ACCESS

### Keywords

- Hemangioblastoma
- von Hippel-Lindau disease
- Surgical treatment
- Diagnosis; Follow-up

### Abstract

Hemangioblastomas are a rare form of benign vascular tumors of the CNS. They can occur sporadically or as component of the von Hippel-Lindau (VHL) disease - an autosomal dominant tumor syndrome. The tumors are typically located in the posterior fossa and spinal cord. Patients with associated VHL disease are usually affected at an early age and develop multiple lesions. Therefore they need a special routine for diagnosis, treatment and follow-up strategies.

In modern neurosurgery, hemangioblastomas are well resectable tumors. Symptomatic lesions should be removed. Resection should furthermore be considered for asymptomatic progressive tumors for the following reason: If a tumor has already caused neurological deficits, the chance to reverse these by surgical resection is reduced and surgical resection is usually possible with low morbidity. Preoperative embolization of large solid hemangioblastomas prevents perioperative hemorrhage but is not necessary in every case. Surgical strategies depend on many factors such as timing of diagnosis, location and progress of tumor growth and have to be discussed individually. Radiation or chemotherapy should be reserved for inoperable tumors.

The University of Freiburg serves as a reference center for VHL disease. Here we present the current diagnostic and treatment strategies of hemangioblastomas - based on our own experiences and by review of renowned literature on this topic.

### INTRODUCTION

von Hippel-Lindau (VHL) disease was named after Eugen von

Hippel, a German ophthalmologist who described “angiomatosis retinae” in 1904 and Arvid Lindau, a Swedish pathologist

who noted that these retinal lesions were associated with an increased risk of developing central nervous system (CNS) hemangioblastomas [1,2]. The term "Lindau's disease" was established by Harvey Cushing in 1928 [3].

In the distant past surgical risk was much higher than today. It was therefore not common to operate on patients who only had mild or no symptoms. Moreover, there had been no screening routines and patients had usually not been diagnosed before they developed neurological symptoms. This fact is also attributable to the lower sensitivity of former radiographic techniques leading to detection of tumors at a later stage and bigger size. Before 1986, ventriculography and angiography were the primary imaging method and was then superseded by CT [4]. Today MRI has become the gold standard for diagnosis and follow-up of hemangioblastomas.

Over time diagnostic methods, surgical skills and screening modalities have vastly improved. This review specifies the "state of the art" of diagnosis, surgical treatment and follow-up strategies of CNS hemangioblastomas in patients with VHL disease.

## CLINICAL FEATURES

Hemangioblastomas are benign CNS tumors, which are equally found in women and men. The majority of tumors (63%) are located in the cerebellum, 32% in the spinal cord and 5% supratentorially. In the spinal cord 48% are located in the thoracic segments, 36% in the cervical segments and 16% in the lumbar segments [5]. Hemangioblastomas can occur as sporadic entity (80%) or as part of VHL disease (20%) [6]. In VHL patients 39 - 65% of hemangioblastomas are located in the cerebellum

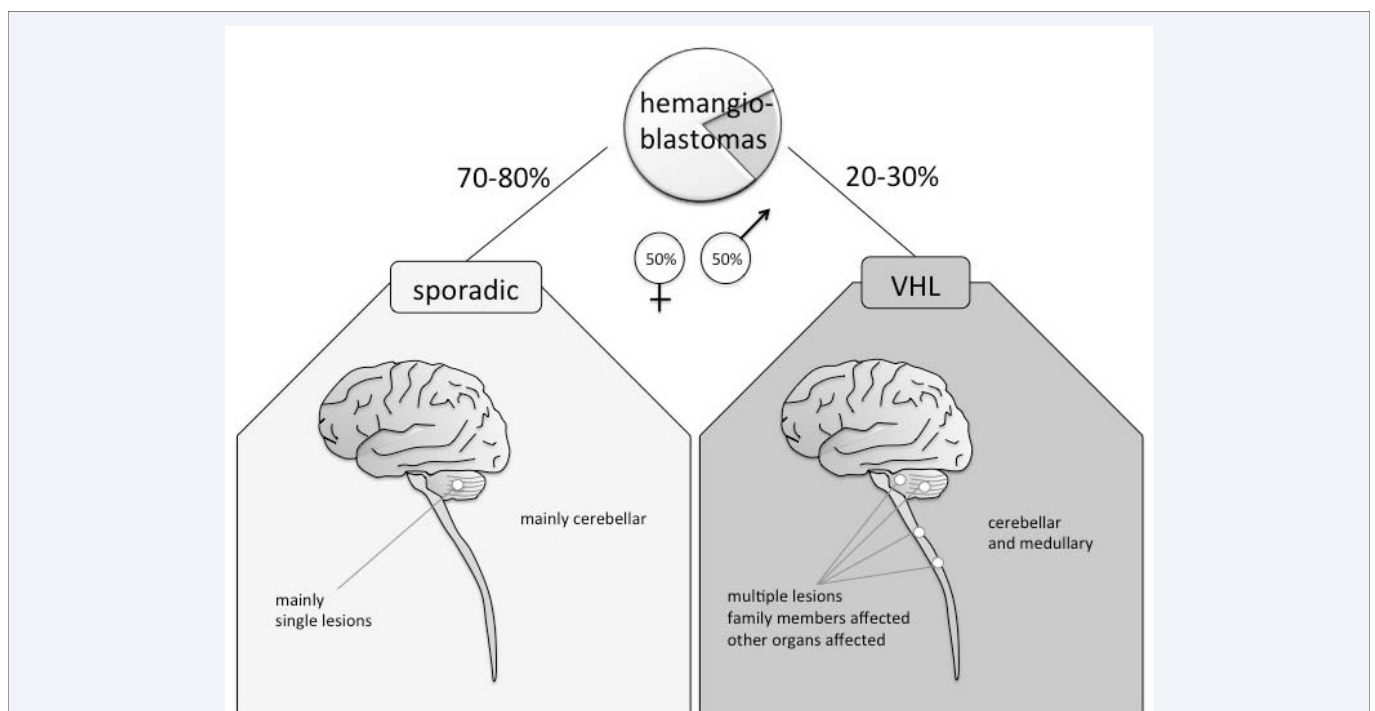
and 13 - 32% are found medullary. In non-VHL patients hemangioblastomas are usually solitary lesions, whereas VHL patients often reveal multiple hemangioblastomas at different locations [7-10] (Figure 1).

Clinical symptoms depend on size and location of hemangioblastomas. Patients with cerebellar lesions can present with headache, gait ataxia, dysmetria, diplopia and vertigo or emesis. Those with spinal lesions can present with pain, gait disturbance, hypoesthesia, weakness, hyperreflexia or incontinence. Mostly symptoms are not caused by the solid tumor itself but by the associated pseudocyst or syrinx, which can grow rapidly [5]. If located close to the ventricular system, tumors can cause cerebrospinal fluid obstructions, which may be lethal. In rare cases, hemangioblastomas present by intraparenchymal or subarachnoid hemorrhage [11]. Approximately 5% of patients develop polyglobulia, which can be cured by removing the solid tumor mass [5,12].

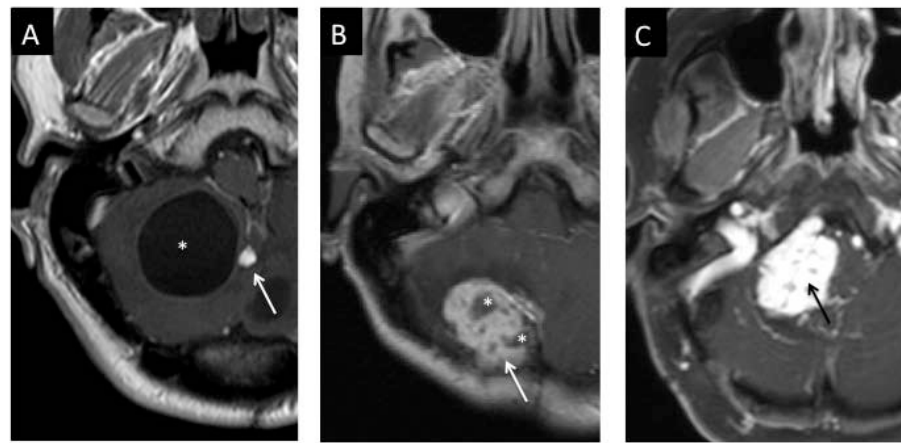
## DIAGNOSIS

### Radiographic diagnosis

**MRI:** The MRI is the gold standard for diagnosis and follow-up of hemangioblastomas. In patients with VHL disease, annual MRI screening of the complete neuroaxis (brain and spine) should be performed to identify new lesions and to monitor size of known hemangioblastomas. We perform a limited program with a triplanar T1 data set with gadolinium for the brain as well as sagittal planes for the whole spine. It is sufficient to complete the spinal data set with axial planes only at sites with identified hemangioblastomas. Generally, tumor tissue appears hypointense or isointense on T1-weighted and hyperintense



**Figure 1** Diagram showing the distribution of hemangioblastomas. Male and female are equally affected. 70-80% of hemangioblastomas are sporadic, 20-30% are associated with von Hippel-Lindau (VHL) disease. In sporadic cases most HBL are single lesions located cerebellar. When associated with VHL disease, there are mainly multiple lesions, located cerebellar and medullary. Moreover other family members and other organs are affected.



**Figure 2** Figure showing example of different hemangioblastomas. A: The classical Lindau-Tumor, a cerebellar hemangioblastoma with small solid portion (arrow) and large pseudocyst (asterix). B: Large solid cerebellar tumor mass (arrow) with intratumoral cystic formations (asterix). C: Large solid hemangioblastoma (arrow) of the cerebellopontine angle.

on native T2-weighted images. In T2-weighted images further pathologies such as syringomyelia or peritumoral edema can be identified.

In post-contrast images tumor tissue depicts as a homogenous bright contrast-enhancing mass, which clearly stands out from the surrounding tissue. Associated tumor cysts appear as adjacent hypointense lesions. Especially in the posterior fossa, hemangioblastomas appear as hypointense cystic lesions with small contrast-enhancing solid tumor parts within the cystic wall.

MRI appearance of hemangioblastomas is pathognomonic, especially in VHL patients with known tumors. Differential diagnosis includes metastatic tumors or pilocytic astrocytomas [13]. In general, hemangioblastomas can present as mainly solid tumors or as cystic tumors with only a small solid tumor mass and a large associated pseudocyst. There are also mixed types with large solid tumor masses and many cystic components (Figure 2).

**Angiography:** Hemangioblastomas appear as a bright contrast-enhancing mass in digital subtraction angiography. Having MRI available, angiography is no longer recommended as a primary diagnostic tool for hemangioblastomas. Angiography is an invasive diagnostic method implying risks such as bleeding, thrombosis or infarction. Furthermore, some VHL patients with renal cell carcinoma show impaired renal function; those are thus exposed to a higher risk of renal failure during contrast medium application during angiography. Therefore, angiography should only be performed for intended preoperative embolization in large solid hemangioblastomas.

**CT:** CT is not necessary for diagnosis or follow-up of hemangioblastomas, due to its radiation exposure and lower sensitivity compared to MRI. Routine CT should only be used if MRI is unavailable or inapplicable for example in case of cardiac pacemaker implantation. It is however indicated in emergency cases, for example in case of occlusive hydrocephalus. In CT scans with contrast medium tumor tissue is depicted as a highly contrast-enhancing mass.

## HISTOLOGY

The histology of hemangioblastomas varies strongly and is dependent on tumor size. They are mainly composed of two different constituents: “stromal” cells and “vascular” cells, of which the “stromal cells” represent the neoplastic component [14]. “Stromal cells” do not exist in normal nervous system and are believed to represent hemangioblast progenitor cells [15,16]. The “vascular cells” represent reactive angiogenesis [17]. They are predominant in small tumors  $< 8\text{mm}^3$ , whereas larger tumors  $> 8\text{mm}^3$  are mainly composed of enlarged “stromal” cells [18]. In progressed stages of the tumor, extramedullary hematopoiesis may be observed [15,16].

The diagnosis of hemangioblastomas is made histologically. Markers which are consistently positive in “stromal” cells include neuron-specific enolase, neural cell adhesion molecule (CD56) and vimentin. Positive immunoreactivity is frequently found for S-100 and only occasionally for CD 57, desmin, renin, keratin, synaptophysin, substance P, neuropeptide Y, transthyretin, and transferrin [15]. Markers commonly positive in “vascular” cells include CD 34 and CD 31.

## GENETIC ANALYSIS / VHL SCREENING

Hemangioblastomas can occur as sporadic lesions or as part of VHL disease. Patients with VHL disease need a completely different diagnostic regiment, treatment and follow-up strategies than patients with sporadic and usually single hemangioblastomas. We recommend a genetic screening for mutations of the VHL tumor suppressor gene for all patients with CNS hemangioblastomas [19].

Clinical diagnosis can be deduced from clinical features, but this is not the most reliable method [19,20]. Since diagnosis of VHL disease implies extensive consequences, genetic analysis should be applied for verification. For this purpose, genomic DNA is isolated from peripheral blood. Furthermore, the cost of the genetic analysis is cheaper than a full clinical examination program (960 to 1,070 euros without or with sequence analysis compared to 2,570 euros) [19]. The later includes: Gadolinium-

enhanced MRI of the brain, whole spine and abdomen, ophthalmological examination, fluorescein angiography of the retina and 24-hour urine catecholamine excretion to screen for other VHL manifestations such as pancreatic cysts, renal cell carcinoma, retinal and pheochromocytomas.

Genetic analysis is therefore not only indicated for patients with suspected VHL disease but also for family members of patients who harbor a VHL gene mutation.

## SURGICAL TREATMENT

### Indication

Generally, the treatment strategy of each hemangioblastoma has to be discussed individually in respect of the location of the tumor, change of tumor size or associated cyst, symptomatology and general condition of the patient.

First of all one has to differentiate between patients with sporadic hemangioblastomas and those without known VHL disease. If no VHL disease is known both symptomatic and asymptomatic hemangioblastomas should be surgically resected completely for histological analysis (Figure 3). Biopsy is not recommended due to the vascular nature of the lesion.

In patients with VHL disease the exact treatment strategies for hemangioblastomas are still a matter of debate. There is general consent that symptomatic hemangioblastomas should be treated [5,21].

Since hemangioblastomas, unlike many other benign tumors, do not grow continuously but with intermittent quiescent and

rapidly growing phases, definition of clear treatment strategies for asymptomatic tumors in patients with VHL disease are challenging.

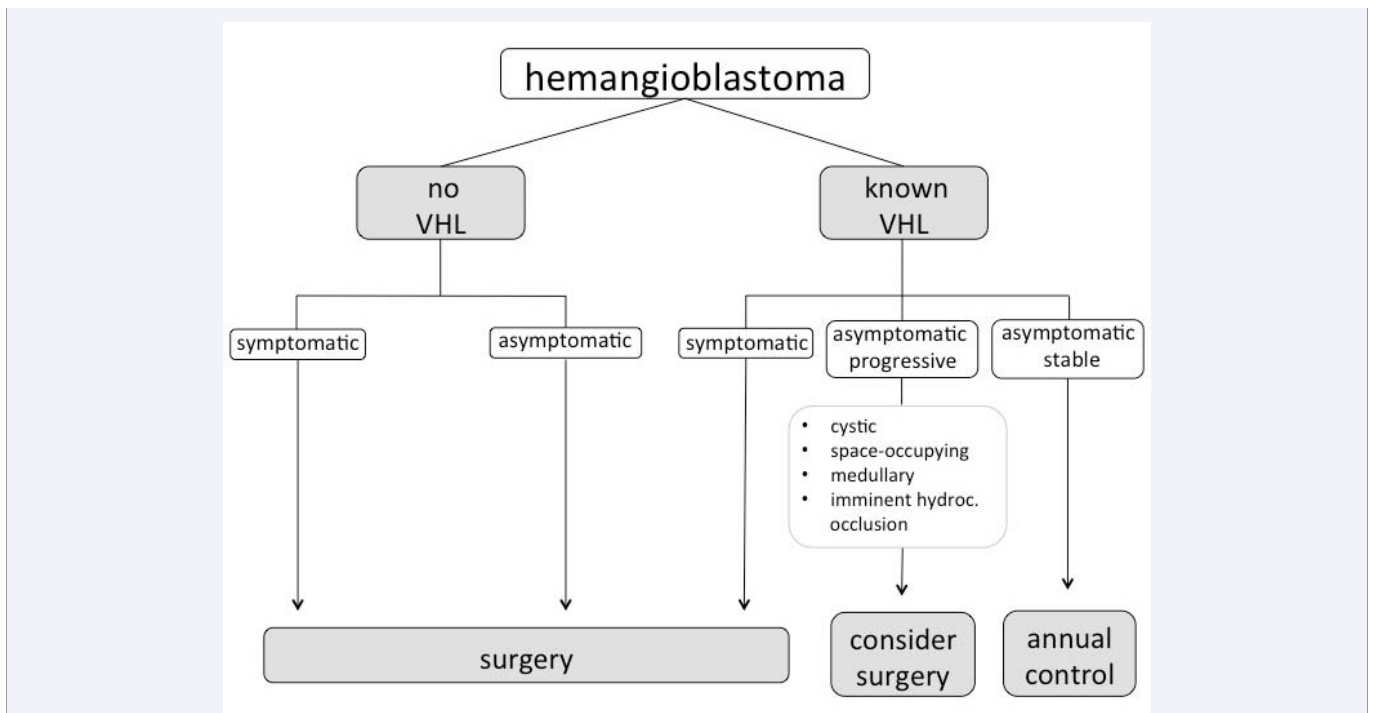
Asymptomatic tumors, which are stable in MRI screening, are recommended to be followed radiographically. Asymptomatic tumors, which are imminent to cause cerebral spinal fluid obstruction, should be treated promptly.

In asymptomatic but progressive tumors treatment strategies differ strongly in the literature. Some major centers recommend further radiographic follow-up [5], whereas others recommend early surgery [21,22], since preoperative neurological symptoms are usually not reversible and surgical resection is usually performed with low morbidity. In our center, we tend to operate hemangioblastomas at an early stage. However, this strategy has to be thought over in patients with multiple previous surgeries.

### Preoperative strategies

**Dexamethasone:** For all cerebellar and spinal hemangioblastomas we recommend a pre-treatment with dexamethasone (4 mg taken 4 times a day) for 3 days and a gradual reduction over the course of one week after the second postoperative day.

**Embolization:** Preoperative embolization can be helpful in large solid tumors to prevent perioperative hemorrhage. It is, however, associated with a number of side effects such as swelling, hemorrhage and infarction, especially in posterior fossa hemangioblastomas. Published series are still small and positive [23-25] and negative results such as swelling, hemorrhage and infarction [26-29] are reported.



**Figure 3** Diagram showing treatment strategy for hemangioblastomas. If no von Hippel-Lindau (VHL) disease is known symptomatic and asymptomatic hemangioblastomas should be surgically resected for histological analysis. If von Hippel-Lindau (VHL) disease is known symptomatic hemangioblastoma should be surgically resected. In asymptomatic but progressive hemangioblastoma surgery should be considered, especially if HBL carries a large cysts, is space-occupying, located medullary or in case of an imminent hydrocephal occlusion.



The time span between embolization and operation should not exceed three days since perifocal swelling can cause enhanced unnecessary risks.

### General surgical technique

The goal of operative treatment is always the complete resection of the solid tumor component. The cystic part may be left untreated since the fluid is solely caused by the tumor cells of the solid portion [30]. Pseudocysts would refill again in case of incomplete resection of the solid tumor. The “wall” of the pseudocyst on the contrary can be left untouched as long as there is no tumor tissue visible [31]. It consists of reactive gliosis without epithelial lining [30].

Since hemangioblastomas are highly vascular tumors, it is not recommended to cut the tumor in pieces, but as a whole without debulking or fragmentation, otherwise profound bleeding may occur. Resection has to be carried out with careful visualization, coagulation and cutting of each feeding vessel. A bloodless operating field is therefore mandatory [8,32].

Incomplete hemostasis at the end of surgery is suspicious for a tumor remnant and one has to reassure that all solid portions have been removed.

Doppler flow sonography can be useful since it is a sensitive intraoperative tool to guide the surgical approach and resection and can provide reliable intraoperative control [33].

### Cerebellar hemangioblastomas

Most hemangioblastomas or their surrounding pseudocysts are located below the surface of the cerebellum. In this case the operative approach depends on the location of the tumor in relation to the transverse sinus. Hemangioblastomas located below its level can usually be operated in prone position. Those tumors located above the sinus level on the tentorial surface of the cerebellum may better be operated in sitting position by an infratentorial, supracerebellar approach. The size of the craniotomy should be adapted to the tumor location and should be rather large since good vision is necessary due to the elevated risk of hemorrhage. Intraoperative ultrasound is also useful to verify the size and location of the tumor in relation to the craniotomy.

The solid tumor itself can be easily distinguished from the surrounding brain tissue due to its reddish or orange color and can usually be removed completely. As mentioned before, debulking of the tumor should be avoided since it can cause extensive bleeding. It is therefore necessary to consequently dissect the area between the tumor and the surrounding tissue by using low power coagulation with minimal manipulation of the surrounding brain tissue.

In many cases the pseudocyst has grown much bigger than the solid part and is causative for neurological symptoms. Upon removal of the solid part of the tumor the pseudocyst is usually opened and will regress after resection of the solid part. It may be helpful to open the pseudocyst first to gain space and facilitate resection of the tumor mass itself. The solid tumor nodule can usually be found in the cyst wall.

### Spinal hemangioblastomas

Spinal hemangioblastomas are the most common localization in patients with VHL disease. Most of these patients carry multiple lesions. Perioperative monitoring including somatosensory evoked potential and motor evoked potential for all spinal hemangioblastomas and an additional D-wave for those located in vicinity to motor tracts should be applied [8].

Most tumors are located at the dorsal root entry zone and therefore posterior to the dentate ligament. In this case a partial hemilaminectomy should be performed. Only seldom an anterior approach with corporectomy is necessary.

Next, the dura and the arachnoid have to be opened. If the tumor is not immediately visible enlarged arterialized veins can help to find it. These veins should be preserved until the end of surgery to avoid swelling and hemorrhage from the tumor. If a dorsal root is involved in the tumor it can usually be resected without causing neurological deficits. If a syrinx is associated it will usually disappear after removal of the tumor even if it is not opened during surgery [8,30].

### Peripheral nerve hemangioblastomas

Peripheral nerve hemangioblastomas are extremely rare and up to today less than 30 cases have been reported [34-46]. They are therefore often operated on in suspicion of a wrong diagnosis, such as metastasis or schwannoma. This can be a major pitfall since the high vascularization of hemangioblastomas can lead to major bleeding if the tumor is fragmented or incompletely resected [42].

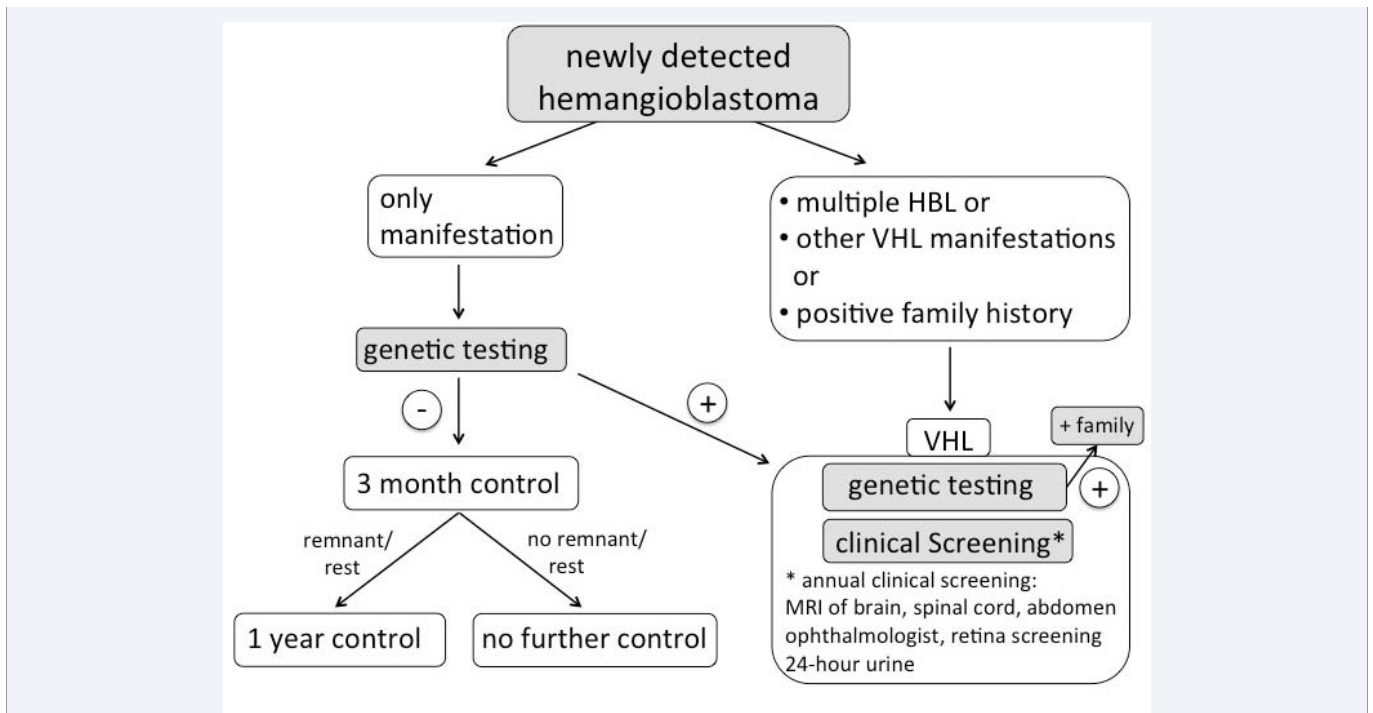
Radiographic diagnosis can be difficult especially in patients without VHL disease. The following aspects are characteristic: in MRI tumors appear as dumbbell-shaped, contrast-enhancing lesions. Tumors are usually solid and appear inhomogeneous in T2-weighted images due to their prominent foci of tubular structures. If a hemangioblastoma is suspected angiography should be considered and preoperative embolization may be performed. Intraoperatively it is mandatory for the surgeon to avoid excessive blood loss by not entering the tumor capsule until feeding vessels are coagulated. If the tumor is only partially removed it usually recurs. It is therefore mandatory to assure that the tumor has been removed completely [42].

For peripheral nerve hemangioblastomas the most important aspect is to take its diagnosis into consideration if MRI image shows suspicious aspects.

### ALTERNATIVE TREATMENTS

Radiotherapy has been proposed as a treatment alternative to microsurgical resection. Its effect, however, remains questionable [47-51] and may be considered a therapeutic option for patients who are no surgical candidates. Prophylactic radiosurgery for hemangioblastomas is generally not recommended [52]

Chemotherapy such as antiangiogenic therapy and vascular endothelial growth factor receptor inhibitors [53,54] are under investigation.



**Figure 4** Diagram showing diagnostic strategies for newly detected surgically removed hemangioblastomas manifestation. If solitary hemangioblastoma is the only manifestation a genetic testing is recommended. If testing is positive a clinical screening should be performed. If testing is negative a radiographic control after 3 months is recommended. If there is no remnant or rest no further control is necessary. If there is a remnant another radiographic control after one year should be performed. If there are multiple hemangioblastomas, other von Hippel-Lindau (VHL) manifestations or a positive family history for VHL disease an annual clinical screening and a genetic testing is recommended.

## FOLLOW UP

### Sporadic hemangioblastomas

In patients with single lesions without VHL disease a 3 months postoperative follow up by MRI with gadolinium is recommended at the site of surgery. If radiographic findings show a complete resection of the tumor no further follow up is necessary since recurrences are extremely rare. The chance to develop a new hemangioblastoma in a different region is very low, therefore another diagnostic MRI scan is not necessary.

If radiographic findings reveal an incomplete resection of hemangioblastoma, a re-operation may be considered. Alternatively, annual MRI follow-ups are recommended and resection may become necessary in case of progress (Figure 4).

In any case an earlier follow up is necessary if patients develop general or focal neurological deficits, which could be associated with the known lesion.

### VHL disease associated hemangioblastomas

Asymptomatic patients with VHL disease and known hemangioblastomas should undergo annual MRI screening of the brain and the spinal axis (Figure 4). Moreover, MRI of the abdomen is performed to screen for pancreatic cysts and renal cell carcinoma. Ophthalmological examination and fluorescein angiography of the retina are performed to screen for retinal hemangioblastomas and a 24-hour urine catecholamine excretion is performed to screen for pheochromocytomas.

In VHL patients without CNS manifestation MRI screening of the complete neuroaxis is recommended every two years [15,55].

## CONCLUSION

Hemangioblastomas are a rare form of benign highly vascularized tumors of the CNS, which frequently appears in patients with VHL disease. VHL patients are usually affected at an early age and develop multiple lesions. Therefore, they need a special routine for diagnosis, treatment and follow-up strategies. Annual MRI screening of the nervous system (brain and spine) is recommended. If hemangioblastomas grow fast or if patients develop neurological deficits a resection of these tumors should be considered to avoid further decline of neurological functions, which is not reversible by surgery. Surgeons should be aware of the highly vascular nature of these lesions. Since VHL disease also affects other organs such as retina, pancreas and kidneys, patients have to be followed closely and treated differently. Genetic analysis of patients and their relatives is advisable.

## REFERENCES

1. Von Hippel E. Über eine sehr seltene Erkrankung der Netzhaut. Von Graefe's Archiv für Ophthalmologie. 1904; 59: 83-106.
2. Lindau A. Zur Frage der Angiomatosis retinae und ihrer Hirnkomplikation. Acta Ophthalmol (Copenh). 1927: 193-226.
3. Cushing H, Bailey P. Hemangiomas of Cerebellum and Retina (Lindau's Disease): With the Report of a Case. Trans Am Ophthalmol Soc. 1928; 26: 182-202.
4. Chee CP, Bailey IC. Posterior fossa haemangioblastomas in Northern Ireland: a clinico-epidemiological study. Ulster Med J. 1986; 55: 165-171.

5. Wanebo JE, Lonser RR, Glenn GM, Oldfield EH. The natural history of hemangioblastomas of the central nervous system in patients with von Hippel-Lindau disease. *J Neurosurg.* 2003; 98: 82-94.
6. Neumann HP, Eggert HR, Weigel K, Friedburg H, Wiestler OD, Schollmeyer P. Hemangioblastomas of the central nervous system. A 10-year study with special reference to von Hippel-Lindau syndrome. *J Neurosurg.* 1989; 70: 24-30.
7. Maher ER, Yates JR, Harries R, Benjamin C, Harris R, Moore AT, et al. Clinical features and natural history of von Hippel-Lindau disease. *Q J Med.* 1990; 77: 1151-1163.
8. Gläser S, Klingler JH, Müller K, Würtenberger C, Hader C, Zentner J, et al. Essentials and pitfalls in the treatment of CNS hemangioblastomas and von Hippel-Lindau disease. *Cent Eur Neurosurg.* 2010; 71: 80-87.
9. Jagannathan J, Lonser RR, Smith R, DeVroom HL, Oldfield EH. Surgical management of cerebellar hemangioblastomas in patients with von Hippel-Lindau disease. *J Neurosurg.* 2008; 108: 210-222.
10. Kanno H, Kuratsu J, Nishikawa R, Mishima K, Natsume A, Wakabayashi T, et al. Clinical features of patients bearing central nervous system hemangioblastoma in von Hippel-Lindau disease. *Acta Neurochir (Wien).* 2013; 155: 1-7.
11. Gläser S, Van Velthoven V. Risk of hemorrhage in hemangioblastomas of the central nervous system. *Neurosurgery.* 2005; 57: 71-76.
12. Gläser S, Krüger MT, Klingler JH, Wlodarski M, Klompen J, Schatlo B, et al. Hemangioblastomas and neurogenic polyglobulia. *Neurosurgery.* 2013; 72: 930-935.
13. Gläser S, Lonser RR, Okamoto H, Li J, Jaffee H, Oldfield EH, et al. Proteomic profiling: a novel method for differential diagnosis? *Cancer Biol Ther.* 2007; 6: 343-345.
14. Vortmeyer AO, Gnarr JR, Emmert-Buck MR, Katz D, Linehan WM, Oldfield EH, et al. von Hippel-Lindau gene deletion detected in the stromal cell component of a cerebellar hemangioblastoma associated with von Hippel-Lindau disease. *Hum Pathol.* 1997; 28: 540-543.
15. Gläser S, Li J, Xia JB, Okamoto H, Zeng W, Lonser RR, et al. Hemangioblastomas share protein expression with embryonal hemangioblast progenitor cell. *Cancer Res.* 2006; 66: 4167-4172.
16. Vortmeyer AO, Frank S, Jeong SY, Yuan K, Ikejiri B, Lee YS, et al. Developmental arrest of angioblastic lineage initiates tumorigenesis in von Hippel-Lindau disease. *Cancer Res.* 2003; 63: 7051-7055.
17. Hasselblatt M, Jeibmann A, Gerss J, Behrens C, Rama B, Wassmann H, et al. Cellular and reticular variants of haemangioblastoma revisited: a clinicopathologic study of 88 cases. *Neuropathol Appl Neurobiol.* 2005; 31: 618-622.
18. Vortmeyer AO, Falke EA, Gläser S, Li J, Oldfield EH. Nervous system involvement in von Hippel-Lindau disease: pathology and mechanisms. *Acta Neuropathol.* 2013; 125: 333-350.
19. Gläser S, Bender BU, Apel TW, Natt E, van Velthoven V, Scheremet R, et al. The impact of molecular genetic analysis of the VHL gene in patients with haemangioblastomas of the central nervous system. *J Neurol Neurosurg Psychiatry.* 1999; 67: 758-762.
20. Woodward ER, Wall K, Forsyth J, Macdonald F, Maher ER. VHL mutation analysis in patients with isolated central nervous system haemangioblastoma. *Brain.* 2007; 130: 836-842.
21. Van Velthoven V, Reinacher PC, Klisch J, Neumann HP, Gläser S. Treatment of intramedullary hemangioblastomas, with special attention to von Hippel-Lindau disease. *Neurosurgery.* 2003; 53: 1306-1313.
22. Kanno H, Yamamoto I, Nishikawa R, Matsutani M, Wakabayashi T, Yoshida J, et al. Spinal cord hemangioblastomas in von Hippel-Lindau disease. *Spinal Cord.* 2009; 47: 447-452.
23. Standard SC, Ahuja A, Livingston K, Guterman LR, Hopkins LN. Endovascular embolization and surgical excision for the treatment of cerebellar and brain stem hemangioblastomas. *Surg Neurol.* 1994; 41: 405-410.
24. Tampieri D, Leblanc R, TerBrugge K. Preoperative embolization of brain and spinal hemangioblastomas. *Neurosurgery.* 1993; 33: 502-505.
25. Vázquez-Añón V, Botella C, Beltrán A, Solera M, Piquer J. Preoperative embolization of solid cervicomedullary junction hemangioblastomas: report of two cases. *Neuroradiology.* 1997; 39: 86-89.
26. Eskridge JM, McAuliffe W, Harris B, Kim DK, Scott J, Winn HR. Preoperative endovascular embolization of craniospinal hemangioblastomas. *AJNR Am J Neuroradiol.* 1996; 17: 525-531.
27. Cornelius JF, Saint-Maurice JP, Bresson D, George B, Houdart E. Hemorrhage after particle embolization of hemangioblastomas: comparison of outcomes in spinal and cerebellar lesions. *J Neurosurg.* 2007; 106: 994-998.
28. Friedrich H, Hänsel-Friedrich G, Zeumer H. Intramedullary vascular lesions in the high cervical region: transoral and dorsal surgical approach. Two case reports. *Neurosurg Rev.* 1990; 13: 65-71.
29. Krishnan KG, Schackert G. Outcomes of surgical resection of large solitary hemangioblastomas of the craniocervical junction with limitations in preoperative angiographic intervention: report of three cases. *Zentralbl Neurochir.* 2006; 67: 137-143.
30. Lonser RR, Vortmeyer AO, Butman JA, Gläser S, Finn MA, Ammerman JM, et al. Edema is a precursor to central nervous system peritumoral cyst formation. *Ann Neurol.* 2005; 58: 392-399.
31. Gläser S, Vortmeyer AO, Lonser RR, Lubensky IA, Okamoto H, Xia JB, et al. Proteomic analysis of hemangioblastoma cyst fluid. *Cancer Biol Ther.* 2006; 5: 549-553.
32. Lonser RR, Oldfield EH. Microsurgical resection of spinal cord hemangioblastomas. *Neurosurgery.* 2005; 57: 372-376.
33. Gläser S, Shah MJ, Hippchen B, Neumann HP, van Velthoven V. Doppler-sonographically guided resection of central nervous system hemangioblastomas. *Neurosurgery.* 2011; 68: 267-275.
34. Brodkey JA, Buchignani JA, O'Brien TF. Hemangioblastoma of the radial nerve: case report. *Neurosurgery.* 1995; 36: 198-200.
35. Chazono M, Shiba R, Funasaki H, Soshi S, Hattori A, Fujii K. Hemangioblastoma of the L-5 nerve root. Case illustration. *J Neurosurg.* 1999; 90: 160.
36. Chu BC, Terae S, Hida K, Furukawa M, Abe S, Miyasaka K. MR findings in spinal hemangioblastoma: correlation with symptoms and with angiographic and surgical findings. *AJNR Am J Neuroradiol.* 2001; 22: 206-217.
37. Escott EJ, Kleinschmidt-DeMasters BK, Brega K, Lillehei KO. Proximal nerve root spinal hemangioblastomas: presentation of three cases, MR appearance, and literature review. *Surg Neurol.* 2004; 61: 262-273.
38. Giannini C, Scheithauer BW, Hellbusch LC, Rasmussen AG, Fox MW, McCormick SR, et al. Peripheral nerve hemangioblastoma. *Mod Pathol.* 1998; 11: 999-1004.
39. Hermier M, Cotton F, Saint-Pierre G, Jouviet A, Ongolo-Zogo P, Fischer G, et al. Myelopathy and sciatica induced by an extradural S1 root haemangioblastoma. *Neuroradiology.* 2002; 44: 494-498.
40. McEvoy AW, Benjamin E, Powell MP. Haemangioblastoma of a cervical

- sensory nerve root in Von Hippel-Lindau syndrome. *Eur Spine J*. 2000; 9: 434-436.
41. Rohde V, Voigt K, Grote EH. Intra-extradural hemangioblastoma of the cauda equina. *Zentralbl Neurochir*. 1995; 56: 78-82.
42. Gläsker S, Berlis A, Pagenstecher A, Vougioukas VI, Van Velthoven V. Characterization of hemangioblastomas of spinal nerves. *Neurosurgery*. 2005; 56: 503-509.
43. Wu L, Yang T, Deng X, Xu Y. Intra-extradural dumbbell-shaped hemangioblastoma of the cauda equina mimicking schwannoma. *Neurol India*. 2013; 61: 338-339.
44. Mitchell A, Scheithauer BW, Wharen RE, Franck J, Chan K. Hemangioblastoma of spinal nerve: a report of six cases. *Clin Neuropathol*. 2013; 32: 91-99.
45. Nishimura Y, Hara M, Natsume A, Takemoto M, Fukuyama R, Wakabayashi T. Intra-extradural dumbbell-shaped hemangioblastoma manifesting as subarachnoid hemorrhage in the cauda equina. *Neurol Med Chir (Tokyo)*. 2012; 52: 659-665.
46. Kunihiro N, Takami T, Yamagata T, Tsuyuguchi N, Ohata K. Spinal hemangioblastoma of cauda equina origin not associated with von Hippel-Lindau syndrome--case report. *Neurol Med Chir (Tokyo)*. 2011; 51: 732-735.
47. Chang SD, Meisel JA, Hancock SL, Martin DP, McManus M, Adler JR Jr. Treatment of hemangioblastomas in von Hippel-Lindau disease with linear accelerator-based radiosurgery. *Neurosurgery*. 1998; 43: 28-34.
48. Jawahar A, Kondziolka D, Garces YI, Flickinger JC, Pollock BE, Lunsford LD. Stereotactic radiosurgery for hemangioblastomas of the brain. *Acta Neurochir (Wien)*. 2000; 142: 641-644.
49. Niemelä M, Lim YJ, Söderman M, Jääskeläinen J, Lindquist C. Gamma knife radiosurgery in 11 hemangioblastomas. *J Neurosurg*. 1996; 85: 591-596.
50. Pan L, Wang EM, Wang BJ, Zhou LF, Zhang N, Cai PW, et al. Gamma knife radiosurgery for hemangioblastomas. *Stereotact Funct Neurosurg*. 1998; 70 Suppl 1: 179-186.
51. Patrice SJ, Sneed PK, Flickinger JC, Shrieve DC, Pollock BE, Alexander E 3rd, et al. Radiosurgery for hemangioblastoma: results of a multiinstitutional experience. *Int J Radiat Oncol Biol Phys*. 1996; 35: 493-499.
52. Asthagiri AR, Mehta GU, Zach L, Li X, Butman JA, Camphausen KA, et al. Prospective evaluation of radiosurgery for hemangioblastomas in von Hippel-Lindau disease. *Neuro Oncol*. 2010; 12: 80-86.
53. Madhusudan S, Deplanque G, Braybrooke JP, Cattell E, Taylor M, Price P, et al. Antiangiogenic therapy for von Hippel-Lindau disease. *JAMA*. 2004; 291: 943-944.
54. Girmens JF, Erginay A, Massin P, Scigalla P, Gaudric A, Richard S. Treatment of von Hippel-Lindau retinal hemangioblastoma by the vascular endothelial growth factor receptor inhibitor SU5416 is more effective for associated macular edema than for hemangioblastomas. *Am J Ophthalmol*. 2003; 136: 194-196.
55. Lonser RR, Glenn GM, Walther M, Chew EY, Libutti SK, Linehan WM, et al. von Hippel-Lindau disease. *Lancet*. 2003; 361: 2059-2067.

## Cite this article

Krüger MT, Klingler JH, Steiert C, Jilg C, Zschiedrich S, et al. (2014) Current Diagnostic and Therapeutic Strategies in Treatment of CNS Hemangioblastomas in Patients with VHL. *J Transl Med Epidemiol* 2(1): 1016.