

Case Report

Primary Retroperitoneal Mucinous Cystadenoma Resected Retroperitoneoscopically

Yurdaer Kaynak^{1*}, Coskun Kaya¹, Buket Altunkara Hacıoğlu² and Murat Aynacı³

¹Department of Urology, Eskisehir State Hospital, Turkey

²Department of Pathology, Eskisehir State Hospital, Turkey

³Department of Radiology, Eskisehir State Hospital, Turkey

***Corresponding author**

Yurdaer Kaynak, Department of Urology, Eskisehir State Hospital, VışnelikMah. Erkan Sk. No: 43 Odunpazarı/ Eskişehir, Turkey, Tel: 90-4522927784; Fax: 90-0222-2376234; Email: yurdaerkaynak@hotmail.com

Submitted: 05 November 2015

Accepted: 12 January 2016

Published: 14 January 2016

ISSN: 2379-951X

Copyright

© 2016 Kaynak et al.

OPEN ACCESS

Keywords

- Laparoscopy
- Tumor
- Treatment
- Resection

Abstract

Introduction: Primary retroperitoneal tumor of mucinous type is extremely rare and has three subtypes as benign, borderline and cyst adenocarcinoma. Prompt diagnosis of the retroperitoneal tumors is important as the majority is malignant. Despite useful radiologic, laboratory and serologic investigations, a preoperative confident diagnosis is difficult. Therefore, surgical complete excision is recommended.

Case report: 34 years old woman presented to our hospital with chronic, blunt, right flank pain for one year. On physical examination, an elastic soft tumor was palpable on her right lower abdomen. Routine laboratory tests were unremarkable. There was a retroperitoneal cystic mass in the abdominal ultrasonography. Non-contrast computed tomography revealed homogeneous, retroperitoneal cystic mass without solid components and with calcifications near the lower pole of the right kidney.

Retroperitoneoscopic resection of the tumor was performed. The patient was discharged at the second postoperative day. Pathological diagnosis was primary retroperitoneal mucinous cyst adenoma (PRMC). She was free of recurrence 6 months after surgery.

Conclusion: The PRMC are rare tumors, don't diagnose easily and don't be known the etiology. When a cystic mass is determined in the retroperitoneal area; the PRMC should be taken in consideration in the differential diagnosis and may be successfully treated retroperitoneoscopically with no recurrence at the follow-up.

ABBREVIATIONS

PRMC: Primary Retroperitoneal Mucinous Cystadenoma CA: Carbohydrate Antigen CEA: Carcino-Embryonic-Antigen

INTRODUCTION

Primary retroperitoneal mucinous cystadenoma (PRMC) which is extremely rare and has three subtypes as benign, borderline and cyst adenocarcinoma is a type of retroperitoneal tumors. To our knowledge, there are only 30 cases benign PRMC [1, 2] and only one case treated by retroperitoneoscopically in the English literature [3]. After obtaining her informed consent for the case report to be published, we present 31th benign PRMC and the second case which was treated laparoscopically by retroperitoneal approach.

CASE PRESENTATION

34 year old woman presented to our hospital with chronic,

blunt, right flank pain for one year. On physical examination, an elastic soft tumor was palpable on her right lower abdomen and routine laboratory tests were unremarkable. The level of Carbohydrate Antigen (CA 19-9), CA 125 and Carcino-Embryonic-Antigen (CEA) were normal. There was a cystic mass pushing back the right kidney, measuring 10*7 cm in the abdominal ultrasonography. Non-contrast computed tomography revealed homogeneous, thin-walled, unilocular retroperitoneal cystic mass without solid components and calcifications that measured 9*6 cm near the lower pole of the right kidney (Figure 1a,b). The definitive preoperative diagnosis could not be established with these findings.

Laparoscopic resection of the tumor by the retroperitoneal approach was performed. A 10-mm trocar was placed the tip of the 12th rib as a camera port after dissection of the retroperitoneum by preperitoneal balloon dissector. The second 12-mm trocar was inserted just 2 cm above the right anterior iliac spine on the posterior axillary line and the third 5 mm trocar

was inserted just below the costal arch on the anterior axillary line. We detected that the cyst neither adheres to the right kidney nor has pedicle to other organs during the surgery. The cyst was enucleated and put in a laparoscopic through the 12-mm trocar. The cyst was perforated and sucked within the laparoscopic bag. Later, it was removed through the incision of 12 mm trocar. There were no post-operative complications. The patient was discharged from the hospital at the second postoperative day and had no recurrence of cyst during the 6 months follow-up. The pathological examination of the cyst showed a PRMC (Figure 2a,b,c).

DISCUSSION

Due to the most retroperitoneal tumors are malignant [4],

PRMC must be differentiated from other cystic benign neoplasms like lymphocele, pancreatic pseudo cyst and cystic lymphangioma or malign ones like cystic teratoma, cystic mesothelioma and pseudomyxomaretroperitonei [1]. Although preoperative diagnosis is important, accurate diagnosis of PRMC is very difficult, since these tumors don't have any pathognomonic clinical features. There are no sensitive radiological imagines, reliable laboratory tests or serum tumor markers. Computed Tomography or Magnetic Resonance Imaging could detect the tumor, show the retroperitoneal origin, the characteristics and relation of the tumor to the other organs. However, it is not reliable in differentiating benign from malign retroperitoneal tumor. Serum tumor markers such as CA-125, CA 19-9, CEA, CA 15-3 and Alpha-Fetoprotein could be benefit at the diagnosis and

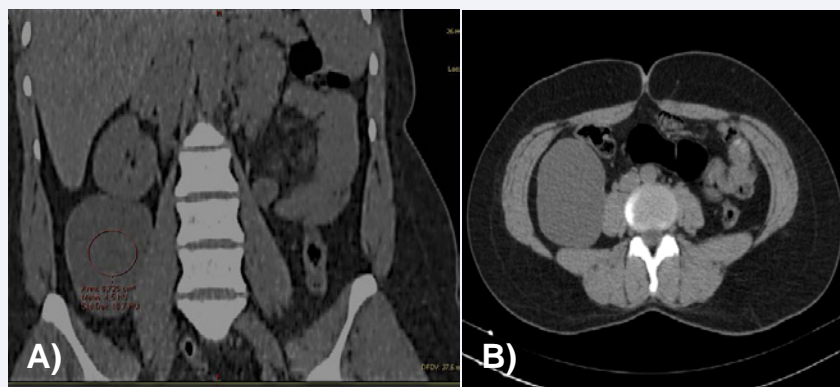


Figure 1 Non-contrast computed tomography of the abdomen.

(A)- The well circumscribed cystic mass is seen in right perirenal space.

(B)- The cystic lesion, occupying the right flank and iliac fossa, has 4.5 HU with cystic density value and 9x8x6 cm in dimensions.

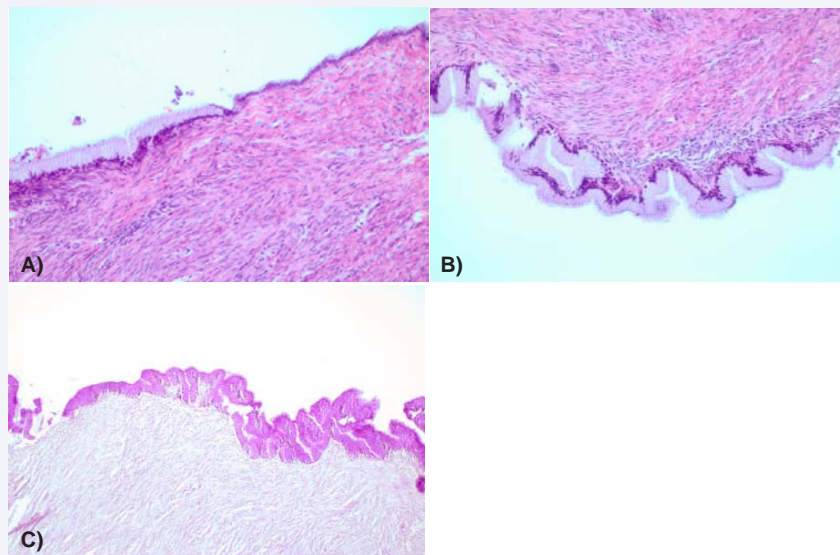


Figure 2 (A)-The Lining epithelium of the cyst composed of tall columnar cells with clear cytoplasm and basal nuclei; also low cuboidal cell resembling mesothelial cells. Wall of the cyst without goblet cells characterizing benign cyst. Stroma is densely cellular and collagenous with closely packed spindle cell. (HXE, original magnification×10)

(B)- The photomicrograph shows a mucin-producing columnar epithelium with underlying fibrous connective tissue. (hematoxylin-eosin, original magnification×10)

(C)- PAS/diastase in tall columnar cells is positive. (periodic-acid-schiff and diastase, original magnification×20)

Abbreviations: HU: HounsfieldUnit; PAS/Diastase: Periodic-Acid-Schiff and Diastase; HXE: Dematoxylin-Eosin.

follow-up in the rare cases [5]. As a result, the final diagnosis could be evaluated by the histological examination of the lesion.

To avoid the risk of infection, recurrence and progression to malignancy, complete surgical resection of cystic lesion has been recommended [6,7]. While open laparotomy for enucleation of the cyst is usually used, transperitoneal [8,9] and retroperitoneal laparoscopic excision has been also reported [3]. Not to have the risk of the injury of intra-abdominal organs and not to need to mobilize the bowel are the advantages of retroperitoneal approach than transperitoneally. The laparoscopic procedure has the benefits like less postoperative pain, lower morbidity and an earlier recovery, but if the malignancy is suspected during the operation, preventing discharge of the cystic fluid and excision of the cystic wall completely would be more important to eliminate the risk of peritoneal implantation and tumor recurrence.

REFERENCES

1. Paraskevskou H, Orfanos S, Diamantis T, Konstantinidou, Patsouris E. Primary retroperitoneal mucinous cystadenoma. A rare case with two cysts and review of the literature. *Hippokratia*. 2014; 3: 278-281.
2. Zevallos Quiroz JC, Toran Monserrat FJ, de Santiago Urquijo FJ, CormenzanaLizarribar EP. Primary retroperitoneal mucinouscystadenoma, casereport. *CirEsp*. 2015 .
3. Fujita K, Yamamoto Y, Yamaguchi S. Laparoscopic resection of primary retroperitoneal mucinous cystadenoma by retroperitoneal approach. *Int J Urol*. 2011; 18: 607-608.
4. Calo PG, Congiu A, Ferrel C, Nicolosi A, Tarquini A. [Primary retroperitoneal tumors. Our experience]. *Minerva Chir*. 1994; 49: 43-49.
5. Isse K, Harada K, Suzuki Y, Ishiguro K, Sasaki M, Kajiura S, et al. Retroperitoneal mucinous cystadenoma: report of two cases and review of the literature. *Pathol Int*. 2004; 54: 132-138.
6. Lai EC, Chung KM, Lau WY. Primary retroperitoneal mucinous cystadenoma. *ANZ J Surg*. 2006; 76: 537.
7. Arribas D, Cay A, Latorre A, Córdoba E, Martínez F, Lagos J. Retroperitoneal mucinous cystadenoma. *Arch Gynecol Obstet*. 2004; 270: 292-293.
8. Ishikawa K, Hirashita T, Araki K, Kitano M, Matsuo S, Matsumata T, Kitano S. A case of retroperitoneal mucinous cystadenoma treated successfully by laparoscopic excision. *Surg. Laparosc. Endosc. Percutan. Tech*. 2008; 18: 516-519.
9. Chen JS, Lee WJ, Chang YJ, Wu MZ, Chiu KM. Laparoscopic resection of a primary retroperitoneal mucinous cystadenoma: report of a case. *Surg Today*. 1998; 28: 343-345.

Cite this article

Kaynak Y, Kaya C, Hacioglu BA, Aynaci M (2016) Primary Retroperitoneal Mucinous Cystadenoma Resected Retroperitoneoscopically. *J Urol Res* 3(1): 1043.