

## Case Report

# Synchronous Vulvar and Vaginal Metastasis from a Type II Papillary Renal Cell Carcinoma A Case Report

Ijeoma N. Chibuzo<sup>1\*</sup>, Augustine O. Takure<sup>1,2</sup>, Sikiru A. Adebayo<sup>1,2</sup> and Olayiwola B. Shittu<sup>1,2</sup>

<sup>1</sup>Department of Surgery, University College Hospital Ibadan, Nigeria

<sup>2</sup>College of Medicine, University of Ibadan, Nigeria

**\*Corresponding author**

Ijeoma N. C. Chibuzo, Division of Urology, Department of Surgery, University College Hospital, P.M.B 5116, Nigeria, Email: ijeomanc2002@yahoo.com

Submitted: 30 January 2016

Accepted: 19 February 2016

Published: 26 February 2016

ISSN: 2379-951X

**Copyright**

© 2016 Chibuzo et al.

**OPEN ACCESS****Keywords**

- Synchronous
- Vulvar
- Vaginal
- Metastasis
- Renal cell carcinoma
- Type II papillary

**Abstract**

**Background:** Metastatic synchronous vulvo-vaginal cancers are rare. Reports of a renal primary tumour are sparse, and where existent, are usually attributed to the clear cell variety.

**Case report:** A 43 year old woman presented with a six year history of right flank swelling, pain, weight loss, and a hard irregular non-tender mass in the right flank. An abdominopelvic Computerised Tomographic (CT) Scan showed a large lobulated heterogenous right renal mass displacing and compressing adjacent structures. There was no evidence of metastasis seen. A hard vaginal mass developed within three months of presentation, confirmed by histology to be metastatic type II papillary renal cell carcinoma (RCC). She had a right nephrectomy but was lost to follow – up afterwards.

**Discussion:** RCC has a myriad of potential metastatic sites. The clear cell variety is known to metastasize to the vulva or vagina. Reports of isolated vaginal metastasis from a Type II papillary RCC and an oncocytic papillary variant are documented. There is to our knowledge, no prior report of synchronous vulvar and vaginal metastasis from a Type II papillary variety.

**Conclusion:** Type II papillary RCC can metastasize synchronously to the vulva and vagina.

**INTRODUCTION**

Vulvar cancers account for 0.8% of female cancers and 4.7% of genital tract cancers. Eight percent of vulvar cancers are metastatic in origin [1]. The primary tumour is often of genital origin, but may be from the kidney or urethra in 18% of cases [2]. Vaginal metastasis is rare following renal cancer. To date, about 80 cases of metastatic vaginal tumours from a primary renal malignancy have been reported [3-6]. Vulvar and clitoral metastases are even rarer. Four cases were reported over a forty year period [1]. We report a case of synchronous vulvar (including clitoral) and vaginal metastasis from a right-sided Type II papillary renal cell carcinoma.

**CASE REPORT**

The patient was a 43 year old Nigerian woman who presented with a six year history of a right flank swelling, pain and weight loss. She had no haematuria. On examination, she was wasted and

had right supraclavicular lymphadenopathy. She had tachycardia and an elevated blood pressure of 180/96 mmHg. Her abdomen was asymmetrically distended with a hard irregular non-tender mass in the right flank extending from the right costal margin to the pelvic brim, and across the midline to the left iliac fossa. She had external prolapsed haemorrhoids.

Computerised Tomographic (CT) Scan of the abdomen and pelvis showed a lobulated heterogenous mass in the upper pole and middle of the right kidney, measuring 19.8cm x 17.2cm x 10.9 cm. It displaced and compressed the renocaval veins, adjacent viscera and mesentery (Figure 1). There was no evidence of metastasis at the time.

She did not present for follow- up until three months later. The review then, revealed a hard mass in the lower third of the right lateral vaginal wall measuring 4 x 3 cm (Figure 2). The cervix and adnexae were normal. There was no contact or spontaneous bleeding. Speculum examination of the vagina

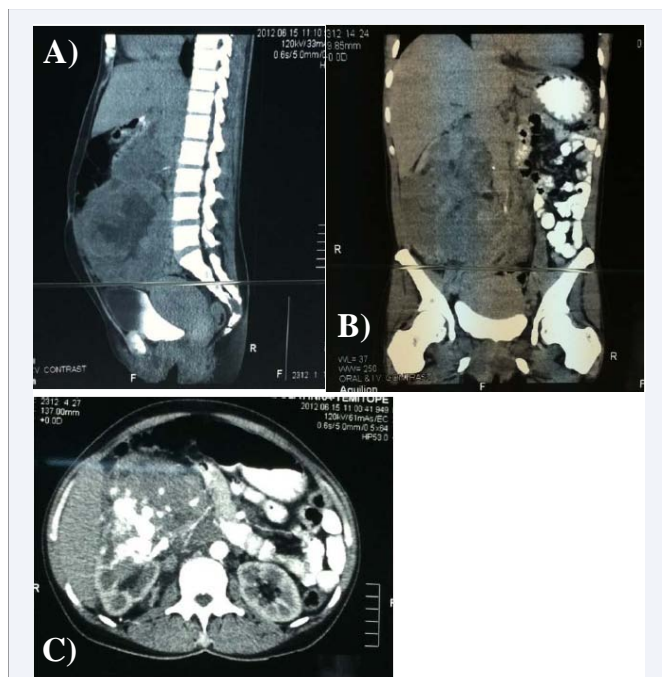
confirmed the presence of the mass. Two palpable masses were felt in the anterior rectal wall 4 cm from the anal verge. She had a right nephrectomy. Intra-operative findings were a huge vascular right renal tumor, with enlarged paracaval and mesenteric lymph nodes. The mass was adherent to the duodenum and transverse colon.

Histopathological examination revealed a multinodular greyish-white tissue measuring 20 x 15 x 13 cm which weighed 2013 g. The adjacent ureter and renal vessels were present. The cut surface was greyish white, orange and brown with interspersed cystic spaces.

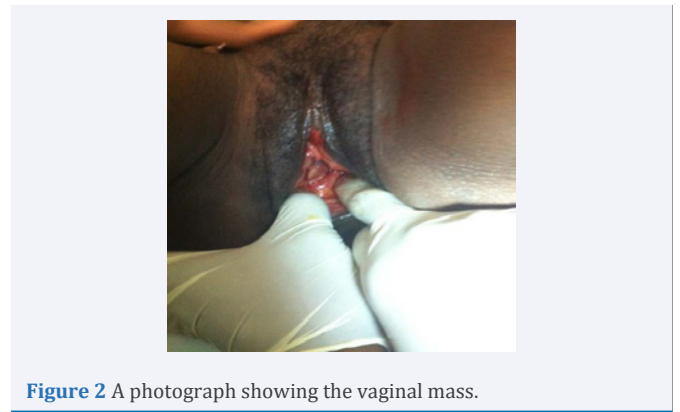
The tumour was enclosed in an irregular capsule at the lower pole of the kidney. The tumour did not breach the renal capsule. There was no tumour involvement of the renal vessels or ureter. Microscopic examination revealed malignant epithelial cells in a complex papillary formation with delicate fibrovascular cores, vesicular nuclei and abundant acidophilic cytoplasm. The features were in keeping with a Type II papillary renal cell carcinoma.

Her post-operative recovery was uneventful and she was discharged on the 12th day after surgery. She presented three months later with vulvar pain, and in acute urinary retention. There was a friable growth occluding the urethral meatus as well as mucosal ulceration of the labia minora. There were hard nodular masses in the clitoris, labia majora and minora (worse on the right), and the entire right vaginal wall, occluding its lumen. The growth bled briskly on contact. An emergency suprapubic cystostomy was necessitated following a failed urethral catheterisation. She was subsequently catheterised par urethram at the next review.

An abdominopelvic ultrasound scan done reported a 7.1 cm



**Figure 1** Non-contrast and contrast-enhanced abdomino-pelvic CT images showing a huge vascular right renal mass. No evidence of renal or inferior vena caval thrombus was seen.



**Figure 2** A photograph showing the vaginal mass.

x 6.6 cm mass in the region of the vagina, extending anteriorly to the bladder. No evidence of hepatic, nodal or peritoneal metastasis was seen.

A biopsy of the perineal masses was consistent with metastatic disease (Figure 3). She was lost to follow-up thereafter.

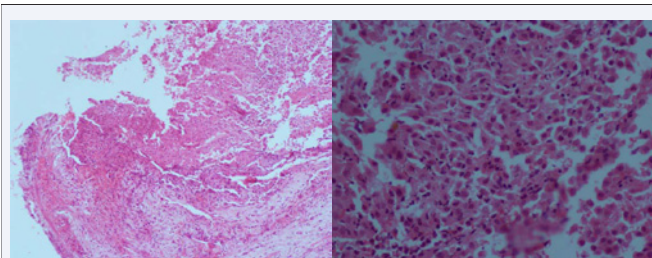
## DISCUSSION

Renal cell cancer (RCC) has been recognised to have a diverse array of sites for potential metastases. The commonly documented modes of presentation of metastatic disease include presentation with synchronous metastasis ab initio [7] or as a metachronous lesion in a patient who has had nephrectomy. Less commonly, in less than 5%, it may be asymptomatic, being an incidental finding of radiologic imaging [8, 9]. Distant metastases from RCC are commonly seen in the lungs (50% to 60%), bones (30% to 40%), liver (30% to 40%), lymph nodes, and brain (5%), but metastases may involve any organ [2]. Rare sites of metastasis include the mediastinum, pancreas, adrenal gland, parotid gland, maxilla, pharynx and urogenital structures [10,11]. In Nigeria, late presentation is common [12], with patients presenting with locally advanced or metastatic disease.

RCC could be of various histological subtypes namely the clear cell variety (75 – 85%), papillary variety (Types I, II and oncocytic variant; 10-15%), and less commonly, the chromophobe (<4%), collecting duct (1%), medullary types (1%) and other non-specified types (6 – 7%) [3,4,13,14].

The clear cell variety is the histological subtype that is most associated with vaginal metastasis [15]. F. Henke, in 1906, first described vaginal metastasis from a renal cell carcinoma [5]. E. Grafenberg, in 1908, was the first to describe vulvar metastasis from a hypernephroma [5]. To our knowledge, there has only been a single report of vaginal metastasis from a type II papillary subtype, and another report of vaginal metastasis from an oncocytic papillary variant in the English literature [2,3]. The metastatic papillary renal cell carcinoma has a poor prognosis, and there is no successful therapy for it at present [13]. The Type II papillary variety has been reported to have an even worse outcome than Type I, and runs a more aggressive course [3,9,14,16]. However, there are isolated reports of spontaneous regression of metastatic type II papillary renal cell carcinomas [16].

Various pathways have been documented which clearly explain vulvar, clitoral or vaginal metastasis from a left renal



**Figure 3** The histology of the vulvar biopsy specimen showing metastatic papillary carcinoma (Courtesy Dr. A. Lawan, Department of Pathology, University College Hospital Ibadan). Magnification: x 100 Magnification: x 400.

carcinoma, which is more commonly responsible [7,15]. These pathways, which involve retrograde venous extension (from the left renal vein, through the left ovarian vein, pampiniform plexus, and finally, to the pubic veins), do not, as succinctly, account for vulvar, vaginal or clitoral metastasis from a right – sided tumour [1,5,16]. Vaginal and vulvar metastases are thought to arise more commonly from direct spread from a mass located within the pelvis. Clitoral metastasis, in turn, is thought to arise from contiguous spread from the vulvo-vaginal tumors [1]. The presence of vulvar metastasis is thought to correlate with widespread disease<sup>1</sup>. In this patient, the enlarged right kidney extended into the pelvis. This may give credence to the theory of contiguous spread. Other mechanisms put forward to explain vulvo-vaginal metastasis from a right renal tumour include (1) retrograde flow from the right renal vein, through the vena cava, to the right ovarian vein and then to the uterovaginal plexus; (2) an anatomic variation connecting the right renal vein to the ovarian vein, and then through the pampiniform plexus to the pubic veins; (3) an obstructive renal vein thrombus promoting retrograde spread via tributaries, (4) retrograde transport along periureteric lymphatics to the vagina or (5) implantation metastasis by urine containing malignant epithelial cells [1,5,7]. Limited proof exists for the two latter hypotheses [7]. The CT scan and histopathological results of the nephrectomy specimen of the index patient showed no evidence of thrombus in the renal vein, making the second and third postulates less likely.

Debois [1] reported that spread from a renal tumour is more likely to be to the lower third and anterior wall of the vagina, and it would usually be on the same side as the primary tumour. He also suggested that isolated metastasis occurs more frequently than multiple ones [1]. The findings in our patient were consistent with the former postulate, as the metastasis was in the lower third of the vaginal wall on the right. Although our patient also had multiple sites of metastasis as had been documented in some other reports [5,8], this is however the only report of synchronous vulvar and vaginal metastases from a type II renal papillary cell carcinoma.

## CONCLUSION

Renal cell carcinoma is prolific in its metastatic potential. A right – sided and type II papillary renal cell carcinoma can metastasize to the vulva and vagina synchronously.

## REFERENCES

1. Debois JM. Chapter 4 – Metastasis to the urogenital system in TxNxM1. In: The anatomy and clinics of metastatic cancer. Kluwer academic publishers. Boston. 2002.
2. Sountoulides P, Metaxa L, Cindolo L. Presentations and rare metastatic sites of renal cell carcinoma – a review of case reports. J Med Case Reports. 2011; 5: 429.
3. Chuang XE, Loh HL, Sim HG, Fong KL, Tan MH. Papillary renal cell carcinoma with metastatic laparoscopic port site and vaginal involvement: a case report. J Med Case Reports. 2011; 5: 131.
4. Bergen S, DiSaia PJ, Liao SY. Cancer of the vulva. Armenian Medical Network. www.Health.am. 2006.
5. Sharnoff JG, Sala AM. Vaginal metastases from hypernephroma: A report of four cases. Am J cancer. 1936; 28: 20–30.
6. Queiroz C, Bacchi CE, Oliveira C. Cytologic diagnosis of vaginal metastasis from renal cell carcinoma. A case report. Acta Cytol. 1999; 43: 1098 -1100.
7. Nerdrum TA. Vaginal metastasis of hypernephroma; Report of three cases. Acta Obstetrica et Gynecologica Scandinavica. 1966; 45: 515-524.
8. Bracarda S. Metastatic renal cell carcinoma: Pathogenesis and the current medical landscape. Eur Uro 2009; 8: 787 -792.
9. Kuroda N, Toi M, Hiroi M et al. Review of papillary renal cell carcinoma with focus on clinical and pathobiological aspects. Histol Histopathol. 2003; 18: 487–494.
10. Hoseman S. Advanced renal cell cancer. University of Texas MD Anderson Cancer Center. OncoLog. May 2012; 57.
11. Thyavihally YB, Mahantshetty U, Chamarajanagar RS. Management of renal cell carcinoma with solitary metastasis. World Journal of Surgical Oncology. 2005; 3: 48.
12. Bioku MJ, Saliu AN, Ikuerowo SO. The operative challenges of advanced renal cell carcinoma with vena caval involvement: A report of three cases. Hindawi Publishing Corporation. Case reports in Urology. 2011; 2011: 514373.
13. Yang XJ, Tan M, Kim HL. A molecular classification of papillary renal cell carcinoma. Cancer Res. 2005; 65: 5628.
14. Xia QY, Rao Q, Shen Q, Shi SS, Li L, Liu B, et al. Oncocytic papillary renal cell carcinoma: a clinicopathological study emphasizing distinct morphology, extended immunohistochemical profile and cytogenetic features. Int J Clin Exp Pathol. 2013; 6: 1392–1399.
15. Allard JE, McBroom JW, Zahn CM, McLeod D, Maxwell GL. Vaginal metastasis and thrombocytopenia from renal cell carcinoma. Gynecol Oncol, 2004; 92: 970–973.
16. Power NE, Poon SA, Mazzola C, Jonathan L. Silberstein, Robert J. Motzer, Ana M. Molina, et al. Case reports: Spontaneous regression of metastatic type II papillary renal cell carcinoma. BJUI. 2011.

### Cite this article

Chibuzo IN, Takure AO, Adebayo SA, Shittu OB (2016) Synchronous Vulvar and Vaginal Metastasis from a Type II Papillary Renal Cell Carcinoma A Case Report. J Urol Res 3(2): 1047.