

Case Report

Massive Dilation of the Ureter: An Endoscopic Management of Persistent Urinary Leak after Partial Nephrectomy

Pardalidis Panagiotis², Andriopoulos Nick¹, Karamanis Angelos¹, Kosmaoglou Eleni¹ and Pardalidis Nick^{1*}

¹Department of Urology, Athens Medical Centre, Greece

²Imperial School of Medicine, UK

***Corresponding author**

Nick Pardalidis, Athens Medical Center, Athens, Greece, Tel: 302106862458; Fax: 302106108753; Email: npardali@otenet.gr

Submitted: 29 February 2016

Accepted: 16 May 2016

Published: 18 May 2016

ISSN: 2379-951X

Copyright

© 2016 Nick et al.

OPEN ACCESS

Keywords

- Partial nephrectomy
- Urinary leakage
- Endoscopic dilation of ureteral

Abstract

Introduction: The incidence of urinary leakage is increased as nephron sparing surgery becomes more used for the management of small renal masses.

We present an endourological approach in a patient with a persistent urinary leak after partial nephrectomy by placing two synchronous ureteral stents to improve drainage and avoid further potential surgery.

Patients and Method: A 39 years old patient presented with a urine leak on the fifth postoperative day after an open partial nephrectomy. Initially, the leakage was managed with a placement of a 6Fr double J stent. However, due to persistence of leakage after a month, two ureteral stents (a 6Fr double J stent and a 14Fr endopyelotomy stent) were placed. With this maneuver, the ureter was dilated to 20 Fr and a bladder catheter was placed to complete the drainage.

Results: At 3 weeks, a CT urography was performed which showed complete resolution of the urinary leakage compared to previous examination. The stents were removed the following day and the patient required no further intervention. The follow up examination was continued for 24 months without any symptom of the patient and any sign of leak recurrence.

Conclusion: Endoscopic approach to urinary leak after partial nephrectomy obtaining high ureteric gauge can be a good alternative, avoiding more aggressive surgical approaches.

ABBREVIATIONS

CT: Computed Tomography

INTRODUCTION

Partial nephrectomy is the standard treatment for most T1a lesions [1]. Urinary fistulae are a complication of partial nephrectomy which ranges between 2% and 10% in most large series [2-4]. The optimal management depends, mainly, on kind and amount of the leak, vascularization around the leak and surgeon's preferences. Normally, ureteral stenting only can resolve the problem, but in 38% of the cases persistent urinary leakage can be a challenging complication [5]. Prolonged ureteral stenting is the next step before proceeding to nephrostomy placement or surgical repair.

In our case, a persistent urine leak was successfully treated

after placement of two different in diameter stents in the renal unit, in an effort to provide maximum drainage and therefore facilitate the closure of the fistula. We describe this endoscopic technique of managing prolonged urinary leakage, before further intervention with more invasive procedures be considered.

CASE PRESENTATION

A 39 year old patient with a previous history of Crohn's disease, presented with an asymptomatic 3cm left renal tumor located at the lower pole, as a random finding in a CT scan examination. The patient underwent partial nephrectomy, through extra peritoneal approach. The initial post-operative period was uneventful.

On the 5th post-operative day, the patient presented urine leak from the existing retroperitoneal suction drain. Initially, a 6Fr

double J stent was placed in the renal unit along with continuous bladder drainage by a urethral catheter.

Two weeks later the urine leak was still persistent and we decided to perform double ureteral stenting using two different stents (a 6Fr double J stent and a 14/7Fr Retromax plus endopyelotomy stent) in order to achieve maximum dilation of the ureteral up to 20Fr in an effort to provide adequate drainage and therefore seal the leak. The two stents were directed in the kidney by gently manipulation under fluoroscopic guidance and finally a urethral catheter was left in place. The following morning a CT urography was performed, revealing an area of extravasation from a lower pole calyx (Figure 1).

Within three weeks after placement of the stents, leak from the suction drain had ceased and a CT urography was performed which showed complete healing and no sign of leak compared with the previous examination (Figure 2). The next day a retrograde pyelography was performed, before the removal of the stents, which confirmed no sign of extravasation from the calyx. The patient was discharged from the hospital and no further intervention required. Follow up examination with CT urography was performed at 12 and 24 months without any sign of leakage recurrence (Figure 3,4).

DISCUSSION

Urine leakage is an undesirable complication after partial nephrectomy, which can usually resolve by drainage with a ureteral stent. However, in some cases it is possible that a single stent may not be able to drain adequately. According to Kundu *et al.*, 69% of the patients with urine leak will heal spontaneously with conservative treatment (drain, good nutrition, rest and exercise to promote healing) in the absence of clinical symptoms.

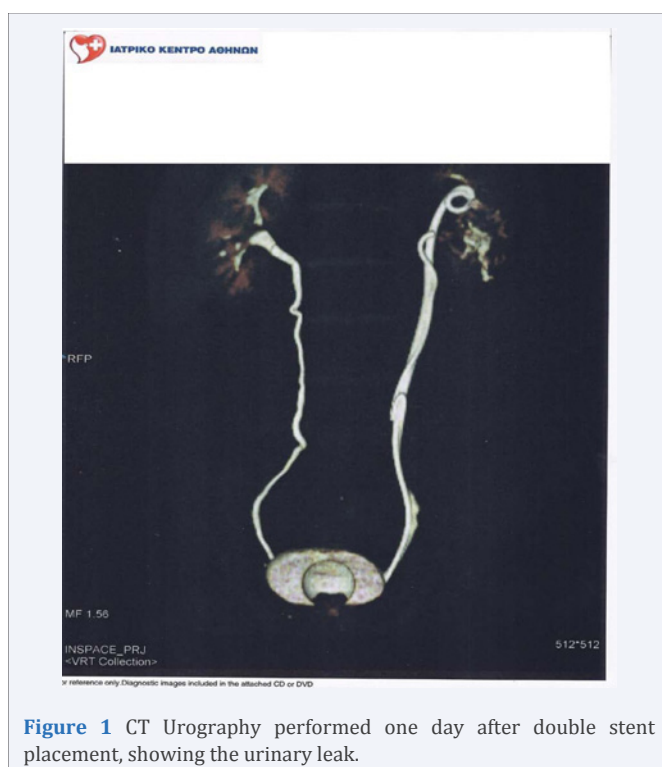

Figure 1 CT Urography performed one day after double stent placement, showing the urinary leak.

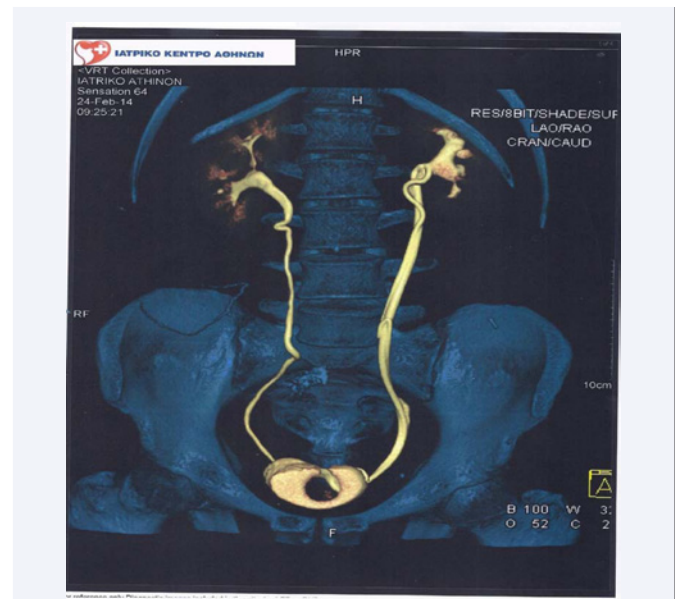


Figure 2 CT Urography at 12 months with no leak.

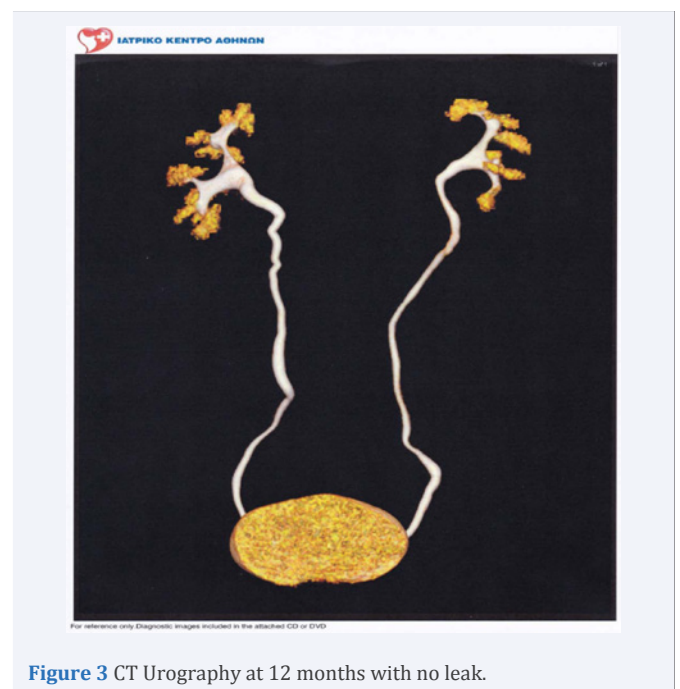


Figure 3 CT Urography at 12 months with no leak.

They report that the median time to resolution is approximately 2 months. The decision to intervene is multifactorial and depends on patient decision, physician's preference and the presence of clinical symptoms (flank pain, fever) [6].

A number of different methods have been described for the management of persistent urine leak. Dual stents have been previously used as a method to prevent ureteral obstruction from extrinsic compression [7]. Double drainage is a well described alternative to manage prolonged urinary leakage [8].

Cinetepe *et al.*, described the use of desmopressin to close a urinary fistula, using oral desmopressin at 0.2mg/day [9]. Such treatment is not commonly used in the case of a persistent urinary

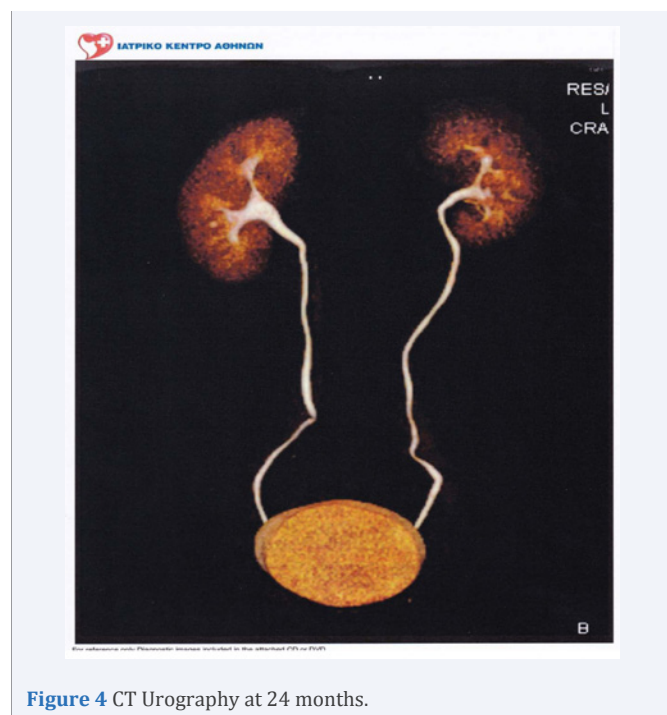

Figure 4 CT Urography at 24 months.

fistula after partial nephrectomy, as it can cause hyponatremia and renal function impairment.

Girard *et al.*, have proposed the use of a Malecot 16Fr catheter to dilate the ureter by a retrograde approach but this technique requires the ureter to be prepared using a double j stent. Another drawback is the length of the catheter, which can provoke occlusion [10].

Percutaneous drainage is usually used if endoscopic manipulations prove to be unsuccessful. Nevertheless this kind of treatment has a high rate of morbidity (bowel perforation or vascular injury) [11].

We strongly believe that dual stent placement offers wide dilation of the ureter and therefore can provide an optimal draining gauge, so it can be useful for cases of persistent urinary leak after nephron sparing surgery. This method provides adequate urinary drainage, facilitating rapid closure of the urine leak site. Furthermore, it is possible that a single stent may be occluded by mucus and epithelial debris, therefore it won't provide adequate extraluminal and intraluminal drainage to seal the urinary leak [12,13].

The advantage of the technique we described using two stents with total diameter of 20Fr, is the maximum dilation of the ureter, in order to avoid percutaneous access or open surgical

reintervention, with the drainage being exclusively performed endoscopically.

Conclusively, double wide diameter ureteral dilation can be a good alternative in cases where single stent drainage provides unsatisfactory results.

REFERENCES

1. Campbell SC, Novick AC, Beldegrun A, Blute ML, Chow GK, Derweesh IH, et al. Guideline for management of the clinical T1 renal mass. *J Urol.* 2009; 182: 1271-1279.
2. Simmons MN, Gill IS. Decreased complications of contemporary laparoscopic partial nephrectomy: use of a standardized reporting system. *J Urol.* 2007; 177: 2067-2073.
3. Stephenson AJ, Hakimi AA, Snyder ME, Russo P. Complications of radical and partial nephrectomy in a large contemporary cohort. *J Urol.* 2004; 171: 130-134.
4. Gill IS, Kavoussi LR, Lane BR, Blute ML, Babineau D, Colombo JR Jr, et al. Comparison of 1,800 laparoscopic and open partial nephrectomies for single renal tumors. *J Urol.* 2007; 178: 41-46.
5. Meeks JJ, Zhao LC, Navai N, Perry KT Jr, Nadler RB, Smith ND. Risk factors and management of urine leaks after partial nephrectomy. *J Urol.* 2008; 180: 2375-2378.
6. Kundu SD, Thompson RH, Kallingal GJ, Cambareri G, Russo P. Urinary fistulae after partial nephrectomy. *BJU Int.* 2010; 106: 1042-1044.
7. Liu JS, Hrebinko RL. The use of 2 ipsilateral ureteral stents for relief of ureteral obstruction from extrinsic compression. *J Urol.* 1998; 159: 179-181.
8. Alsikafi NF, Steinberg GD, Gerber GS. Dual stent placement for the treatment of a persistent urine leak after partial nephrectomy. *Urology.* 2001; 57: 355-357.
9. Cimentepe E, Unsal A, Akbulut Z, Balbay MD. Prolonged urinary drainage from nephrostomy tract after percutaneous nephrolithotomy can be treated with oral desmopressin. *Scand J Urol Nephrol.* 2004; 38: 266-267.
10. Girard F, Thanigasalam R, Theveniaud PE, El Hajj A, Eimer C, Sibileau E, et al. Prolonged urinary leakage after partial nephrectomy: a novel management pathway. *Urology.* 2014; 83: 485-488.
11. Bruner B, Ashley R, Leibovich B, Blute M, LeRoy A. Case report: percutaneous catheter management of persistent urine leak due to iatrogenic infundibular stenosis after partial nephrectomy. *J Endourol.* 2009; 23: 37-41.
12. Jarrett TW, Lee CK, Pardalidis NP, Smith AD. Extensive dilation of distal ureter for endoscopic treatment of large volume ureteral disease. *J Urol.* 1995; 153: 1214-1217.
13. Brewer AV, Elbahnasy AM, Bercowsky E, Maxwell KL, Shalhav AL, Kahn SA, et al. Mechanism of ureteral stent flow: a comparative in vivo study. *J Endourol.* 1999; 13: 269-271.

Cite this article

Panagiotis P, Nick A, Angelos K, Eleni K, Nick P (2016) Massive Dilation of the Ureter: An Endoscopic Management of Persistent Urinary Leak after Partial Nephrectomy. *J Urol Res* 3(3): 1055.