

Case Report

Modified Technique by De La Cruz and Jean in Pediatric Kidney Transplantation for Ureterovesical Implantation

Pierre Jean Aurelus¹, Hermilo De La Cruz Yáñez¹, Filiberto Martínez Ramírez² and Alfonso Yamamoto Nagano¹

¹Department of Gastro-transplantation, Hospital de Pediatría Centro Médico Nacional Siglo XXI, México

²Department of Pediatric Anesthesia, Hospital de Pediatría Centro Médico Nacional Siglo XXI, México

***Corresponding author**

Pierre Jean Aurelus, Hospital de Pediatría Centro Médico Nacional Siglo XXI (Instituto Mexicano Del seguro Social "IMSS"), México, Tel: 52555-6276900; Email: aurelusjean@yahoo.com.mx

Submitted: 16 April 2017

Accepted: 31 August 2017

Published: 02 September 2017

ISSN: 2379-951X

Copyright

© 2017 Aurelus et al.

OPEN ACCESS

Keywords

- Pediatric-Kidney-Transplantation
- Urological-complications
- Ureter-implantation

Abstract

Introduction: Vasculature and ureterovesical anastomosis are known like the most important surgical aspect of renal transplantation. Underwent, we used the Ricard technique modified by De La Cruz and Jean to diminished those urological complications. The objective of this work is given to know this modified technique and review the outcomes, with more emphasis in vesicoureteral reflux in pediatric patients following kidney transplantation.

Patients and methods: Retrospectively during 6 months, we analyzed the outcomes of 16 renal transplant recipients with ureteral implantation underwent the Ricard Technique modified by De La Cruz and Jean.

Results: We observed: eritrocituria (hematuria) was 13.3 ± 1.85 in 25% of patient in the first 3 months post operatively and interrupted after removing the double J stent. Mean plasma creatinine level at 2 months of transplanted was 0.85 ± 0.38 mg/dl. Ureteral meatal stenosis (obstruction) was presented in 31.2% patients that manifested like minimum hydronephrosis. Urinary tract infection was observed in 12.5 % of patients. There were no cases of urinary fistula and urinary reflux during 6 months of the outcomes followings.

Conclusion: Reflux vesicoureteral is one of the most frequent complications between urinary complications following kidney transplantation. The Ricard modified by De La Cruz and Jean technique has been found to be a quite successful as reimplantation technique in pediatric kidney transplantation to minimize this complication. However, this modified technique is associated with a higher risk of complicated obstruction, what is it, its weakness.

INTRODUCTION

Vasculature and ureterovesical anastomosis are known like the most important surgical aspect of renal transplantation [1]. They may be associated with important morbidity and may even be responsible for graft loss. Following kidney transplantation, urological complications like urinary leakage, ureteral stricture, vesicoureteral reflux, significant hematuria and ureteral obstruction have been described with prevalence between 1% and 30% [1,2]. Within in them, ureteral complication is one of the most common surgical complications [1,3]. The ureterovesical anastomotic technique can influenced the urological complication rate, since a number of different ureterovesical techniques have been developed with the objective to minimize those complications [4,5]. Furthermore, The most frequently used technique is the extravesical Campos Freire technique, better known as Lich-Gregoir (LG) technique [1,3,6] in which the ureter is tunneled in the submucosal space to prevent reflux [3]. In pediatric Population, there is no different prevalence of those complications. Underwent, we used the

Ricard technique modified by De La Cruz and Jean to diminished those complications. The objective of this work is given to know this modified technique and review the outcomes, with more emphasis in vesicoureteral reflux of those pediatric patients following kidney transplantation.

PATIENTS AND METHODS**Description of ureteral reimplantation techniques**

The extravesical reimplantation was first described by Witzelin 1896, then again by Gregoir at the German Congress of Surgery in April 1961, and soon thereafter by Lich et al, who published the technique in November 1961. The Lich-Gregoir (LG) technique, it consisted of anastomosis of the distal ureter to the bladder mucosa, which was then buried in a muscular tunnel intended to provide a valve effect. On the other hand, the Ricard modified technique by De La Cruz and Jean, it consisted of an extravesical ureteral reimplantation, after the kidney perfusion, the donor ureter is identified and prepared its distal end and

performed a longitude curt of 1.5cm in this part (Figure 1). Since we inverted 2 cm of the ureter onto itself to create a nipple valve that fixed with PDS 6-zero in both sides (anterior and posterior) and inserting a double J stents, (Figures 1-3). Since, an incision is made in the bladder wall musculature at the dome for 2.5cm to expose the mucosa of the bladder wall; another incision of 1 cm is made in the bladder mucosa and introduced into bladder through this incision the nipple valve with the Double J that was fixed it to the bladder mucosa with a running instead of interrupted 5-zero PDS sutures. The tunneling procedure is performed in a similar manner to LG by imbricating the seromuscular layer to create the antireflux mechanism. Underwent this modification, the Richard modified by De La Cruz and Jean provide two antireflux mechanisms in pediatric kidney transplantation (Figures 4-6) and the double J stents had been removed between 8 and 12 weeks post-transplant (Figure 7).

Patients

We searched in our hospital electronic database for all patients who underwent kidney transplantation and retrospectively we performed an observational and descriptive review between January 2008 and December 2010, we evaluated the vesicoureteral outcomes of 16 peditrics patients with kidney transplantation in our center in the first six month after graft kidney transplantation. We included all patients who had the Ricard modified by De La Cruz and Jean with double J stents using like surgical procedure. Underwent this technique, we reported the demographic characteristics including the renal function, urinary leakage, vesicoureteral reflux, hematuria, urinary infection and ureteral obstruction.




Figure 1 Longitudinal curt distal ureter.

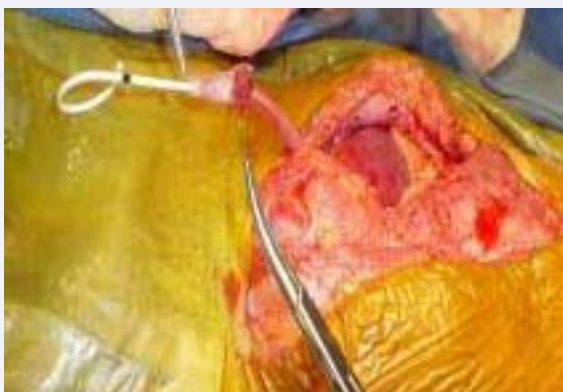

Figure 2 Nipple performed and JJ stents.

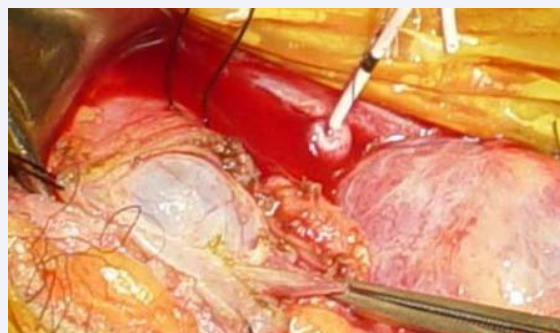


Figure 3 Creation of 2.5-cm submucosal tunnel.

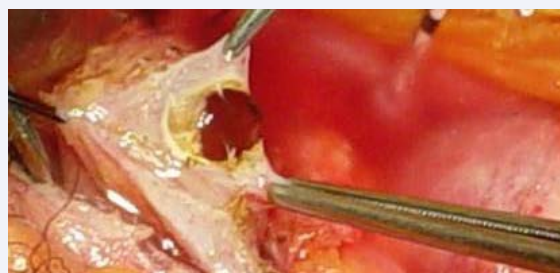

Figure 4 Nipple incision into the bladder.

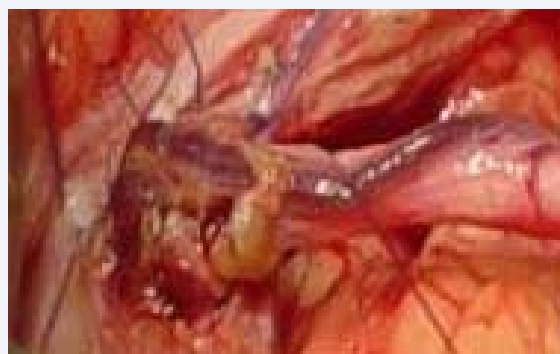


Figure 5 Nipple anastomosis: ureter to mucosa.

RESULTS

The mean age of the recipients was 12.5 ± 1.2 years; there was however a borderline preponderance of males patients (55%). The mean weight was 41.9 ± 1.7 kg and 1.37 ± 0.18 m of size. The previous treatment had been hemodialysis in 12.9% and peritoneal dialysis in 87.1% patients. The time in waiting list for transplant was 90.2 ± 15.4 months. The majority of patients (80.6%) received a living-donor graft.

Respecting ureteral complications, we observed: eritrocituria (hematuria) was 13.3 ± 1.8 in 25% of patient in the first 3 months post operatively and interrupted after removing the double J stent. Mean plasma creatinine level at 2 months of transplanted was 0.85 ± 0.38 mg/dl. Ureteral meatal stenosis (obstruction) was presented in 31.2% patients that manifested like minimum hydronephrosis. Urinary tract infection was observed in 12.5 %

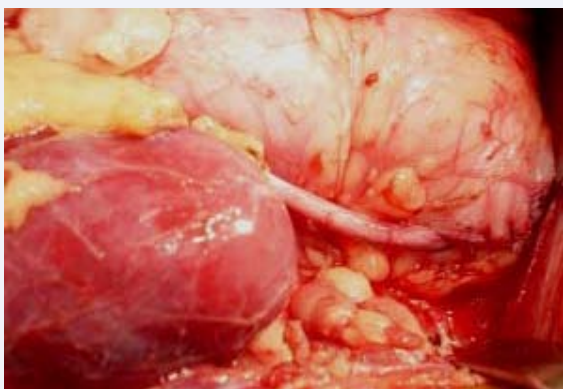


Figure 6 Sutured detrusor to detrusor muscle.

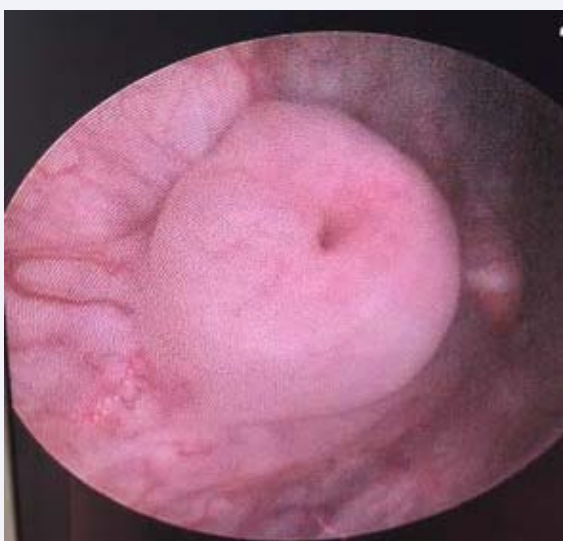


Figure 7 Intravesical nipple valve three months after transplantation.

of patients. There were no cases of urinary fistula and urinary reflux during 6 months of the outcomes followings.

DISCUSSION

A variety of methods have been used to manage urine drainage like: Politano-Leadbetter, Lich-Gregoir, Shanfield, Taguchi, Barry, nipple-valve like Ricard techniques. All those techniques have been used with the finality to minimize ureterovesical complications in kidney transplantation [4-9]. Since several studies found that there are a significant association between the duration of cold ischemia and development of extensive ureteral stricture [10-12]. Comparative studies have demonstrated that extravesical reimplantation techniques are superior to intravesical reimplantation with respect to operative times and decreased complications [6,8,12,13]. Generally, the median time to diagnosis of ureteral complication is occurred during the first 3 posttransplantation months [12,14]. In fact, the following in our study was for six months. In our center, to determine the optimal extravesical reimplantation technique in pediatric kidney transplantation, we modified the Ricard technique in: the manner to create the nipple valve and in the manner to fixing it,

we used double J stents and we performed a tunneling like the LG technique. Underwent these changes, we observed in our patients a satisfactory outcome with a low rate of post-transplant complications in: urinary tract infection, hematuria and reflux vesicoureteral. The incidence of reflux in LG technique, the most using in ureteral reimplantation in kidney transplantation, is in rates ranging from 34 to 70%, and ureteral obstruction at the ureterovesical junction is in range from 1.3 to 8.3% [7,10,12,13].

In an attempt to minimize these complications, one pediatric transplant group has reported the use of a 2-cm submucosal antireflux tunnel to significantly decrease their rates of reflux [6]. Another group performed a nipple-valve technique for ureteroneocystostomy [5,8]. Ureterovesical reflux as complication after kidney transplantation is considered controversial, as it usually causes no clinical symptoms [1,3]. In our patients we performed the nipple valve with a previous curt in the distal ureter to prevent the stenosis and we performed the tunnel like it is in Lich-Gregoir technique and we had not observed reflux. On the other hand we had more obstruction than literature mentioned in Lich-Gregoir [5,3,10]. Ureteral obstruction is not uncommon, it is occurring beyond the first postoperative month remains frequent [2-8] and mostly related to ureteral stenosis [12,14,15]. Therefore, we performed this technique to minimize the reflux frequency in the graft, like our objective in this study. Since the first successful renal transplant by Murray et al., vesicoureteral reflux, obstruction of meatal stenosis and urinary infection are the major concerns regarding ureteral reimplantation [2,8,14-16]. Although, we observed non-reflux vesicoureteral in the Ricard modified technique, it could also theoretically predispose to stenosis or obstruction at the ureterovesical junction like we observed in 12% of patients in our study, higher than LG technique reported in literature 8.3% [5,7,15-17]. The important for the transplant surgeon is therefore to create a functional ureterovesical anastomosis that prevents reflux but also avoids the development of meatal stenosis or obstruction [5,14,15]. Knowledge, Pediatric kidney transplant recipients are predisposed to the development of vesicoureteral reflux into the graft after transplantation [3,5,15,16].

Another complication that seems to occur significantly more frequently in the lich Gregoir report, is the urinary tract infections. It occurred in 43.6% of patients in the study of Jeffrey L et al., in the same sense Hooghe et al., reported a significant difference between the Leadbetter-Politano and LG methods in terms of urinary leak [5,8,11]. Bladder symptoms such as frequency, urgency, dysuria and hematuria are theorized to be caused by local mucosal stent irritation of nerves located in the submucosa concentrated in the bladder. Even though several studies referred that some complications are more common with non-stented anastomoses than stented anastomosis [3,13]. Although in our study we observed 31.3% of patients with urinary tract infection. Several studies have shown an increase in urinary tract infections with ureteral stenting [1,10,17]. Underwent extreme care taken during dissection and ureteral stents are commonly used to provide upper urinary tract drainage in multiples techniques [3,8,9,18]. In the same manner in the Ricard modified we used double J stents and we had not observed morbidity associated to the stents Therefore, more patients and longer follow up are required to study its performance.

CONCLUSION

Reflux vesicoureteral is one of the most frequent complications between urinary complications following kidney transplantation. The Ricard modified by De La Cruz and Jean technique has been found to be a quite successful as reimplantation technique in pediatric kidney transplantation to minimize this complication. However, this modified technique is associated with a higher risk of complicated obstruction, what is it, its weakness. Underwent, the treatment is to perform a new reimplantation. Therefore, early diagnosis is of paramount importance and the most important point is performing a graft Doppler ultrasound every month to detect hydronephrosis in the first 3 months after removing the double J stents. However, we observed good outcomes by using this technique to provide graft implantation complications, when it is performed by experienced surgeons.

ACKNOWLEDGEMENTS

To IMSS, Patients, Ortega Rodríguez Ma Del Carmen and Jean Family.

REFERENCES

- Alberts Victor P, Idu Mirza M, Legemate Dink A. ureterovesical anastomotic techniques for kidney transplantation: a systematic review and meta-analysis. *Transpl Int*. 2014; 27: 593-605.
- Kayler L, Kang D, Molmenti E. Kidney Transplant Ureteroneocystostomy Techniques and Complications: Review of the Literature. *Transplant Proc*. 2010; 42: 1413-1420.
- Ecke Thorsten H, Bartel Peter, Hallmann Ateffen. Evaluation of Symptoms and Patients' Comfort for JJ-ureteral stents with and without Antireflux-membrane Valve. *J Urol*. 2010; 75: 212-216.
- Moreira P, Parada B, Figueiredo A, Maia N, Nunes P, Bastos C, et al. Comparative Study between Two Techniques of Ureteroneocystostomy: Taguchi and Lich-Gregoir. *Transplant Proc*. 2007; 39: 2480-2482.
- Vasdev N, Coulthard MG, Lambert H. The modified Barry technique to prevent vesicoureteric reflux in paediatric renal transplant recipients: Initial recipient outcomes. *J Pediatr Urol*. 2012; 8: 97-102.
- Jeffrey VL, Yew Jay, David GW, Craig SV, Singer JS, Rosenthal JT, et al. Long-Term Comparative Outcomes Between 2 Common Ureteroneocystostomy Techniques for renal Transplantation. *J Urol* February. 2007; 177: 632-636.
- Benoit G. Surgical technics of kidney transplantation. *Prog Urol*. 1996; 6: 594-604.
- Van Arendonk KJ, Goldstein SD, Salazar JH, Lau HT. A nipple-valve technique for ureteroneocystostomy in pediatric Kidney transplantation. *Pediatr Transplantation*. 2015; 19: 42-47.
- Lee RS, Bakthavatsalam R, Marsh CL. Ureteral Complication in Renal Transplantation: A Comparison of the Lich-Gregoir versus the Taguchi Technique. *Transplant Proc*. 2007; 39: 1461-1464.
- Ameer Ahmad, Aljiffry Murad, Jamal Mohammad, Hassanain Mazen, Doi S, Fernandez M, Metrakos P, et al. Complications of ureterovesical anastomosis in adult renal transplantation: comparison of the Lich-Gregoire and the Taguchi techniques. *Ann Transplant*. 2011; 16: 82-87.
- Pan X, Xue W, Tian P, Ding X, Yan H, Feng X, et al. Follow-up evaluation of a new ureteral anastomosis technique in renal transplantation. *Zhongguo Xiu Fu Chong Jian Wai Ke Zhi*. 2008; 22: 998-1002.
- Kaskarelis I, Koukoulaki M, Georgantas T, Bairamidis E, Kokkinos C, Ieronymou M, et al. Ureteral Complications in Renal Transplant Recipients Successfully treated With Interventional Radiology. *Transplant proc*. 2008; 40: 3170-3172.
- Riediger Carina, Muller Michael W, Bachmann Jeannine, Bairamidis E, Kokkinos C, Ieronymou M, et al. Native ureteropyelostomy: an effective therapy for urinary tract complications following kidney transplantation. *ANZ J Surg*. 2014; 84: 643-648.
- Ali-Asgari Majid, Dadkhah Farid, Ghadian Alireza. Impact of ureteral Length on Urological Complication and Patient Survival after Kidney Transplantation. *Nephro Urol Mon*. 2013; 5: 878-883.
- Zafarghandi R. Mahdavi, Sheikhi ZH. Extensive Ureteral Stricture in Renal Transplant Recipients: prevalence and Impact on Graft and Patient Survival. *Int Jorg Transplant Med*. 2013; 4: 165-171.
- Lasaponara F, Manassero F, Catti M, Rossi R, Ferrando U. The use of the small caliber JJ stent with anti-reflux valve in double kidney transplant. Personal experience. *Minerva Urol Nefrol*. 2002; 54: 9-13.
- Sackett DD, Singh P, Lallas CD. Urological involvement in renal transplantation. *International J Urol*. 2011; 18: 185-193.
- Pike Thomas W, Pandanaboyana Sanjay, Hope-Johnson T. Ureteric reconstruction for the management of transplant ureteric stricture: a decade of experience from a single Centre. *Steunstichting ESOT*. 2015; 28: 529-534.

Cite this article

Aurelus PJ, De La Cruz Yáñez H, Ramírez FM, Nagano AY (2017) Modified Technique by De La Cruz and Jean in Pediatric Kidney Transplantation for Ureterovesical Implantation. *J Urol Res* 4(3): 1088.