

Research Article

Urethral Prolapse in Young Girls: A Report of Eight Cases

Yddoussalah O^{1*}, Oudrhiri M², Sumba H¹, Karmouni T¹, Elkhader K¹, Koutani A¹, IBN Attya Andaloussi A¹, F Ettayebi², and Zerhouni H²

¹Department of Urology B, Mohamed V University, Morocco

²Pediatric Surgical Emergency Department, Rabat Children's Hospital, Morocco

*Corresponding author

Othmane Yddoussalah, Department of Urology B, Mohamed V University, CHU Ibn Sina, Faculty of Medicine and Pharmacy, residence Wifaq building 2 apartments 7 -Hay Riad- rabat, Morocco, Tel: 0021268517870; Email: yddoussalah.urob@gmail.com

Submitted: 26 February 2018

Accepted: 15 March 2018

Published: 17 March 2018

ISSN: 2379-951X

Copyright

© 2018 Yddoussalah et al.

OPEN ACCESS

Abstract

Urethral prolapse is a complete eversion of the distal urethral mucosa through the external meatus. It is a rare condition in children that relates to girls with a peak frequency of four to six years, more commonly in black girls. This condition can be a forensic problem, in fact the clinical presentation of the urethral prolapsed is mainly a vulvar bleeding. Urethral prolapse can be definitively diagnosed without laboratory or radiographic evaluation by demonstrating that the edematous tissue surrounds the meatus circumferentially.

We retrospectively analyzed the records of 8 cases of urethral prolapse in girls admitted to the Emergency Department Pediatrics Surgical, over a period of 17 years (1998 - 2014). In our series, the age of diagnosis was between 05 and 12 years with a median age of 08 years. 100% of our girls were Caucasian. The treatment is the subject of great controversy between surgery and conservative treatment, all of our patients underwent surgical treatment except for one patient. The risk of complications, including urethral stricture, and recurrence, is not rare, due to a poorly conducted medical treatment or poorly mastered surgery.

In our series, the outcome was favorable in all our patients. An early withdrawal of the urinary catheter can help to shorten the hospital stay, and thus, a lower cost of hospitalization.

Keywords

- Urethral
- Prolapse
- Girl

INTRODUCTION

Urethral mucosal prolapse is rare in young girls [1]. It is a benign disease, seen in most cases as a circular protrusion of the distal urethra through the external meatus [2]. For most cases, medical treatment and follow-up are sufficient, but failure of this or possible complications may necessitate a surgical correction with very few complications [3].

This study reports eight cases of urethral prolapse, highlighting the pathology and therapeutic options of this condition.

MATERIALS AND METHODS

It is a retrospective study of 8 cases managed at the Surgical Pediatrics Emergency Department, Rabat Children's Hospital, Morocco, between February 1998 and April 2014. The age, the aetiology, the socio-economic status of the parents, the clinical aspects, associated symptoms and the treatment applied were studied. We also appreciated the infectious status of these patients, especially search for repetitive urinary tract infections.

RESULTS

Epidemiologically: None of our patients of black ethnic and 7/8 of the patients is in pre-puberty. Patients' age ranged from 5 to 12 years (mean age: 8 years). We find on the (Table 1) below the major demographics of whole 8 cases.

The major reason for hospitalization is vulva bleeding: 5/8, 62.5%, while 37.5% consulted for a process in the urethral area.

Clinical examination carried out allowed the diagnosis of urethral prolapse in 6/8 girls or 75%, which appears in most cases as a bead circumferential, pseudo-tumoral mass, more or less voluminous, pink or purplish, oedematous, bleeding on touch. In 25% of cases general anaesthesia was required as a better examination condition for the diagnosis of urethral prolapse (Figure 1-2).

Abdominal radiography without preparation was done in one patient; it did not show any abnormality.

Two patients underwent pelvic ultrasound, the latter showed no abnormalities.

Table 1: The major demographics of whole 8 cases.

Number of cases	1	2	3	4	5	6	7	8
Age [Years]	8	5	5	11	12	9	5,5	5
Ethnic group	White ethnic	White ethnic	White ethnic	White ethnic	White ethnic	White ethnic	White ethnic	White ethnic
Antecedents	-	-	Pharyngitis's has repetition	-	-	convulsions feverish to the age of 5 years	Acute pyelonephritis the age of 1 year	-

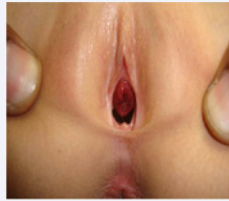

Figure 1 Mucosal prolapse through the urethral meatus in a 5-year-old girl.

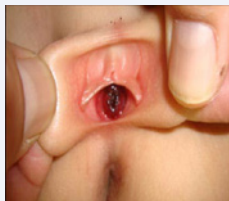

Figure 2 Purple pseudo tumour swelling in a girl of 07 years.

Initial treatment consisted of parental reassurance that urethral prolapse was a benign urological pathology and not sexual abuse.

One of the eight patients had non-surgical treatment. The non-surgical treatment consisted of the regulation of a vulvar toilet with application of povidone iodine and prophylactic antibiotic (which is readjusted according to the sensitivity result) and oral or suppository anti-inflammatory drugs.

The remaining seven patients had surgical treatment under a general anaesthesia. After a rigorous asepsis of the perineum area, with a Foley's urethra catheter Ch 6-10 in place, a circumferential resection of the prolapsed urethral mucosa followed by immediate muco-mucous suture, was achieved using the four-quadrant technique (Figure 3-4).

Post-operatively, the urethral Foley catheter was maintained for 5 days, after which it was removed (Figure 5). hospitalisation period was 5 days after surgical management.

The post-operative course was 100% favorable, the patients were reviewed at 1 month and then at 6 months after surgery: no cases of urethral stenosis, urinary retention, or recurrence.

DISCUSSION

Urethral prolapse is defined as the eversion of the urethral mucosa. It was first described nearly 250 years ago by Solingen

in 1732, and since then fewer than 400 cases have been recorded.

The youngest age reported was a newborn female only 5 days old (Barnes, 1953). Urethral prolapse remains an uncommon affection: the largest series are reported by Da Silva-Anoma S et al 65 cases collated in nine years [4,5]. Our series of 8 cases has been collected in 16 years. Patients generally belong to a low socio-economic group and are of black ethnicity without any antecedents in particular or risk factor. In our series 100% of girls are Caucasian, which proves that the pathology does not concern only the black race.

The exact cause of urethral prolapse remains unknown. The most popular theory is based on weakness attachment of internal longitudinal muscle fibers, circular, obliques and the urethral

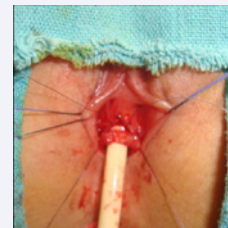


Figure 3 Excision of surplus.

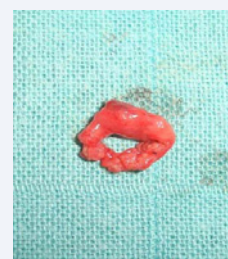

Figure 4 The Excised Ring prolapsed mucosa and suture.

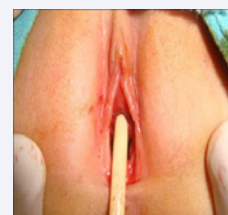


Figure 5 Postoperative aspect.

mucosa. The separation of these plans because of elevated intra-abdominal pressure would explain the occurrence of urethral prolapse [6]. Chronic cough, constipation, trauma, urinary and vaginal infections, malnutrition, excess urethral mucosa and physical exertion would be predisposing factors [7].

This condition occurs in girls commonly under 10 years; usually the patients' age ranges from 4 to 7 years [2,3]. In our study, the mean age was 8 years.

Genitourinary bleeding in the girls has always posed a diagnostic problem ranging from sexual abuse to other organic pathologies such as urethral prolapse [8,2].

Urethral prolapse is a rare cause of consultation, probably due to under reporting of cases [9]. The main presenting symptom is vaginal bleeding, [10,11] as in our experience given in this report.

Diagnosis of urethral prolapse is essentially clinical [12] as a circular protrusion of the distal urethra through the external meatus.

The systematic prescription of a pelvic ultrasound in front of everything Gynecological problem of the child is not rule. The clinical examination is often sufficient, and the interpretation of the ultrasound data must be cautious and take into account physiological variations as a function of age. Pelvic ultrasound or MRI may be helpful in eliminating a differential diagnosis or if there is doubt after the well-done clinical examination.

Translabial perineal ultrasound is a common approach in paediatrics. It is practicable in all patients without any technical problems and without anesthesia. The main differential diagnosis of a paediatric interlabial mass corresponds to: ectopic (prolapsed) ureterocele, imperforate hymen with vaginal dilatation, Gartner's cyst, rhabdomyosarcoma, and urethral diverticulum [13].

Untreated or late diagnosis, prolapse urethral changes to strangulation and necrosis [14,15].

Until 1985 the treatment of urethral prolapse was surgical. Currently therapeutic strategy of urethral prolapse offers two treatment options: medical treatment and surgical treatment [16-18].

Medical treatment involves the use of sitz baths, the application antibiotics and steroids, locally applied estrogens to use 2 to 3 times a day, the total duration of treatment is 2 weeks without exceed one week of hospitalization, treatment may be continued in outpatient if necessary. The essence of the sitz bath is to decrease swelling and edema [19].

Surgical treatment remains the reference treatment; it allows the restoration of functional anatomy, especially in cases of severe prolapse with necrotic mucosa [20].

Ligation around a Foley probe is no longer used because of complications (recurrence, infections, pain postoperative. Complete and circumferential surgical excision prolapsed mucosa ensures good results within a from 24 to 72 hours [12].

Some authors think that surgical excision is almost never necessary and recommend a simple manual reduction under anesthesia which can be curative, if not significantly reduces the

prolapse. Indeed, this technique was in use from the beginning of the last century described by Sauferlin [21].

Postoperative complications following urethral prolapse re-pair may include urethral stenosis and urinary incontinence. Urethral stenosis can occur from the development of scar tissue at the distal urethra. To help prevent urethral scarring, certain author prefers to perform this procedure on healthy estrogenized tissue and ensure complete approximation of the urethral mucosa to the vaginal epithelium to prevent retraction of the urethral mucosa. Postoperative urinary incontinence may occur owing to the diminished urethral length following excision; however, this is rare given that the continence mechanism is rarely involved with distal urethral excision. The severity of incontinence will depend on the amount of urethral tissue excised along with the patient's baseline urethral functioning [22].

The prolapse of the urethra in the girl is a condition whose prognosis is good with a satisfactory aesthetic result.

CONCLUSION

Urethral prolapse can be definitively diagnosed without laboratory or radiographic evaluation by demonstrating that the edematous tissue surrounds the meatus circumferentially. Initial treatment consists of parental reassurance, observation, and warm soaks. If the prolapse does not demonstrate improvement, excision of the prolapsing tissue may be necessary. We believe that our surgical technique facilitates removal of the prolapsed tissue and anastomosis of the residual urethral mucosa.

CONSENT OF PATIENTS

Written informed consent was obtained from the patient's next of kin for publication of this case report and any accompanying images. A copy of the written consent is available for review by the Editor-in-Chief of this journal.

REFERENCES

1. Mollard P. *Precise of urology of the child: the female urethra*. Paris: Masson; 1984; 387.
2. Akani CI, Pepple DK, Ugboma HA. Urethral prolapse: A retrospective analysis of hospitalized cases in Port Harcourt. *Niger J Med*. 2005; 14: 396-399.
3. Pouya M, Van Cangh PJ, Wese FX, Opsomer RJ, Saleh M. [Mucous prolapse of the urethra]. *Acta Urol Belg*. 1995; 63: 23-29.
4. Da Silva Anoma S, Sefton E, Shenoy MU, Rance CH. Urethral prolapse in premenarchal girls. *BJU International*. 2000; 86: 402.
5. Da Silva-Anoma S, Bertin KD, Ossenou O, Gaudensv, Yao D, Roux C. Prolapse of the urethral mucosa in young girls from the Ivory Coast. *Ann Urol (Paris)*. 2001; 35: 60-63.
6. Lowe FC, Hill GS, Jeffs RD, Brendler CB. Urethral prolapse in children: Insights into etiology and management. *J Urol* 1986; 135:100-103.
7. Fernandes ET, Dekermacher S, Sabadin MA, Vaz F. Urethral prolapse in children. *Urol*. 1993; 41: 240-242.
8. Essiet A, Ikpi E, Essiet GA, Nkposong EO. Urethral prolapse: a case report and commentary on management. *Afr J Urol*; 2007; 13: 50-53.
9. Falandry L. [Prolapse of the urethra in black girls: Personal experience in 11 cases. *Med Trop (Mars)*. 1994; 54: 152-156.
10. Lopez C, Bochereau G, Eymeri JC. Urethral mucosal prolapse in girls:

- Apropos of 24 cases. *Chir Pédiatr.* 1990; 31:169-72.
11. Valerie E, Gilchrist BF, Frischer J, Scriven R, Klotz DH, Ramenofsky ML. Diagnosis and treatment of urethral prolapsed in children. *Urology* 1999; 54: 1082-1084.
12. Sanda GO, Soumana A, Oumarou H. Le prolapsus muqueux de l'urètre chez la fillette : A propos de 22 cas colligés en dix ans et une revue de la littérature. *African Journal of Urology.* 2012; 18: 93-96.
13. Tomà P, Magistrelli A, Lucchetti MC. Urethral prolapse in a paediatric patient with urogenital bleeding: diagnosis by imaging. *Int Urogynecol J.* 2017; 28: 1755-1756.
14. Ho KL, Chu SM, Tam PC. Reduction of strangulated urethral prolapse using local anesthesia with hyaluronidase. *J Urol.* 2003; 169: 288.
15. Mianne D, Beatrix O, Faure JM, Boyer C, Altobelli A, Gatinois Y. Le prolapsus étranglé de l'urètre chez la femme.
16. Trotman MDW, Brewster EM. Prolapse of the mucosa in pre-pubertal west Indian girls. *Br J Urol.* 1993; 72: 503-506.
17. Redman J. Conservative management of urethral prolapse in female children. *Urology.* 1982; 19: 505-506.
18. Turner R. Urethral prolapse in female children. *Urology.* 1983; 2: 530-533.
19. Richardson DA, Hajj SN, Herbst AL. Medical treatment of urethral prolapse in children: *Obstet Gynecol.* 1982; 59: 69-72.
20. Jerkins GR, Verheek K, Noe HN. Treatment of girls with urethral prolapse. *J Urol.* 1984; 132: 732-733.
21. Sauferlin H. Über den vorfall des Harnohre bei der Frau. *Z. Geburtshilfe Gynaekol.* 1929; 94: 630.
22. Hill AJ, Siff L, Vasavada SP, Paraiso MF. Surgical excision of urethral prolapse. *Int Urogynecol J.* 2016; 17.

Cite this article

Yddoussalah O, Oudrhiri M, Sumba H, Karmouni T, Elkhader K, et al. (2018) Urethral Prolapse in Young Girls: A Report of Eight Cases. *J Urol Res* 5(2): 1101.