SciMedCentral

Annals of Vascular Medicine & Research

Review Article

Animal Models of Intimal Thickening in Coronary Artery Bypass Vein Graft Disease

Amaradasa K, Christodoulou A, Wadey K, Johnson JL, and George SJ*

Department of Translational Health Sciences, Bristol Medical School, University Of Bristol, UK

***Corresponding author**
George SJ, Department of Translational Health Sciences, Bristol Medical School, University Of Bristol, Bristol, BS2 8HW, UK, Tel: +441173423154.

Submitted: 09 February 2026

Accepted: 02 April 2026

Published: 03 April 2026

ISSN: 2378-9344

Copyright

© 2026 Amaradasa K, et al. Made available under a Creative Commons Attribution (CC-BY) 4.0 Licence.

OPEN ACCESS

Keywords

- Coronary artery disease; Animal Models; Intimal Thickening; Plaque formation

Abstract

Coronary artery disease (CAD) is the single leading cause of mortality, affecting a third of the population worldwide. CAD is characterised by progressive atherosclerotic plaque formation within the coronary artery wall due to lipid and inflammatory cell infiltration. Atherosclerotic plaques are susceptible to rupture or erosion, exposing plaque contents to circulating blood, thereby triggering thrombus formation. Although healing can occur, repeated episodes of rupture or erosion, alongside thrombosis organisation and incorporation into the vessel wall, can lead to partial or complete vessel occlusion, restricting blood flow and causing myocardial ischaemia. Severe cases can result in myocardial infarction.

ABBREVIATIONS

Apoe-/-: Apolipoprotein E knock out; CABG: Coronary Artery Bypass Grafting; CAD: Coronary Artery Disease; EC: Endothelial Cell; ECM: Extracellular Matrix; EVH: Endoscopic Vein Harvesting; LAD: Left Anterior Descending; LDL: Low-Density Lipoprotein; LITA: Left Internal Thoracic Artery; OVH: Open Vein Harvesting; SVG: Saphenous Vein Graft; VGD: Vein Graft Disease; VSMC: Vascular Smooth Muscle Cell.

INTRODUCTION

Coronary artery disease (CAD) is the single leading cause of mortality, affecting a third of the population worldwide [1,2]. CAD is characterised by progressive atherosclerotic plaque formation within the coronary artery wall due to lipid and inflammatory cell infiltration [3,4]. Atherosclerotic plaques are susceptible to rupture or erosion, exposing plaque contents to circulating blood, thereby triggering thrombus formation [3,4]. Although healing can occur, repeated episodes of rupture or erosion, alongside thrombosis organisation and incorporation into the vessel wall, can lead to partial or complete vessel occlusion, restricting blood flow and causing myocardial ischaemia. Severe cases can result in myocardial infarction [5].

To preserve coronary artery patency, patients receive medical management, which includes lifestyle changes and pharmacological therapy (e.g. antiplatelet drugs, β-blockers, statins and/or ACE (angiotensin-converting enzyme) inhibitors). If necessary, they may undergo percutaneous coronary intervention, or in more complex or high-risk cases, coronary artery bypass grafting (CABG) [1-7]. Currently, there are approximately 13,000 CABG procedures performed annually in the UK [8]. Although alternative conduits may be used, the most commonly used are the left internal thoracic artery (LITA), the radial artery, and the long saphenous vein. The LITA displays excellent long-term patency rates (>90% at 10 years) and the radial artery shows similarly good patency (85-90% at 10 years) [9-11]. However, saphenous vein grafts (SVGs) present high rates of failure with as many as 40-60% grafts failing within 10 years of surgery due to the development of vein graft disease (VGD) [4].

Despite its inferior long-term success rates, the saphenous vein remains widely used as arterial conduits including the LITA and radial artery may be insufficient or unsuitable. The LITA can vary in calibre along its length, may occasionally be diseased, and has limited reach; consequently, it is usually reserved for bypassing the left anterior descending (LAD) artery and is often insufficient for multi-vessel grafting [4]. The radial artery is more prone to vasospasm than other arterial grafts, particularly in patients with comorbidities, and its smaller

luminal diameter can complicate anastomosis and cause size mismatch [12-14]. Furthermore, safe harvesting of the radial artery may be contraindicated in patients with inadequate collateral ulnar artery circulation [14,15]. Conversely, the saphenous vein is easy to harvest, provides large luminal diameter, and offers substantial length, enabling surgeons to bypass multiple occluded sites [16].

In this review article, we briefly outline the pathophysiology of human VGD, discuss important considerations in choosing an appropriate VGD model, and evaluate existing models of VGD. Our primary focus is animal models of intermediate VGD, characterised by intimal thickening, though we briefly consider models of late VGD, which display superimposed atherosclerotic plaques.

PATHOPHYSIOLOGY OF HUMAN SAPHENOUS VEIN GRAFT DISEASE

VGD results from complex pathophysiological processes driven by 1) surgical trauma, and 2) a maladaptive response of the saphenous vein to the arterial haemodynamic environment, which can lead to partial or complete occlusion of the graft. Most mechanistic and aetiological insights into human vein-graft intimal thickening are drawn from experimental models as direct evidence from human studies is comparatively scarce and predominantly supports associations rather than causal inference. In this section, we restrict our focus to what can be directly concluded from human studies interrogating VGD pathophysiology. The progression of VGD in humans involves three distinct phases: acute thrombosis, intimal thickening and accelerated atherosclerosis.

Acute Thrombosis

Early vein graft failure (<1 month after surgery) occurs in 3-12% of grafts by hospital discharge [17], and in 10-15% within the first month [18,19]. It is primarily a result of acute thrombotic occlusion, typically associated with graft harvesting and handling, pre-existing vein abnormalities, or technical issues such as size mismatch, anastomotic error, or poor distal runoff [19,20]. Integrity of endothelial cell (EC) coverage of the luminal surface is central to early graft patency as the endothelium is fundamental in maintaining an antithrombotic and anticoagulant environment. Vein graft harvesting and handling practices vary widely (as described in section 3.1.1), though all, to a greater or lesser extent, impose mechanical trauma and ischaemia-reperfusion injury, compromising EC coverage. Following implantation, sudden and sustained exposure of the saphenous vein ECs to systemic arterial pressures (systolic: ~100-140mmHg vs ~5-15mmHg in veins), increased wall shear stress (~10-15dyn/cm^2 vs ~1-6dyn/cm^2 in veins) and pulsatile blood flow induce EC activation [9,21]. This damaged and dysfunctional endothelium is more permissive to increased platelet adhesion and acute thrombosis [22]. The pro-thrombotic state is induced by EC loss resulting in exposure of subendothelial extracellular matrix (ECM) and tissue factor to circulating blood, and activated or dysfunctional ECs having reduced anti-coagulatory potential [20,23,24]. Additionally, a pro-coagulatory state is promoted by a down-regulation in nitric oxide, prostacyclin, thrombomodulin, and heparan sulphate proteoglycans, as well as an increase in levels of surface von Willebrand Factor [20,23-25].

Intimal Thickening

Intermediate VGD is characterised by pathological intimal thickening and occurs within 1-12 months post-surgery, with approximately 15% of SVGs failing within one year [26]. Following implantation into the arterial circulation, the saphenous vein undergoes extensive remodelling, known as arterialisation [24,27]. Though aspects of this remodelling may be beneficial and reinforce the vessel wall against the arterial haemodynamic environment, the response can become maladaptive, with excessive intimal thickening and adverse inward remodelling causing progressive stenosis or reduced lumen uniformity [28].

Intimal thickening is strongly associated by a vascular smooth muscle cell (VSMC) phenotypic switch: quiescent, contractile VSMCs become synthetic, and migrate and proliferate into the intima [Figure 1] [29-31]. The molecular mechanisms governing VSMC activation in VGD is highly complex and context dependent. In brief, evidence from human studies show that EC injury caused by CABG surgery, and subsequent thrombus formation, results in release of von Willebrand factor antigen and platelet factor 4 [32]. There is also inflammation characterised by an increase in macrophages, T-lymphocytes and leukocytes also occurs [33-36]. Platelet adhesion and pro-inflammatory signals collectively promote VSMC activation, migration and proliferation, thereby driving intimal thickening [37]. During intimal thickening, ECM composition is altered including deposition of collagen, fibronectin and thrombospondin, which is associated with reduced vascular compliance and increased stiffness [37] .

Accelerated atherosclerosis

Late VGD, occurring more than one year after CABG surgery, is primarily due to accelerated, superimposed atherosclerosis. Accelerated atherosclerotic lesions in SVGs differ morphologically from spontaneous lesions in

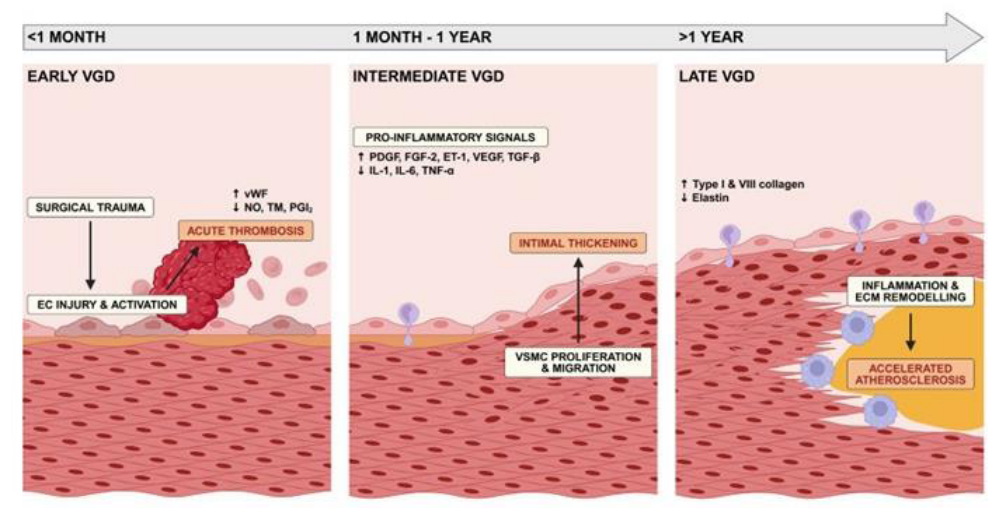

Figure 1 Pathophysiology of human saphenous vein graft disease.
Progression of VGD with three distinct phases. During early VGD (within I month), surgical manipulation leads to EC Dysfunction. This increase platelet adhesion which causes acute thrombosis. In intermediate VGD (within I month-1 year), VSMCs proliferate and migrate into the intima, resulting in intimal thickening. During late VGD (after 1 year), inflammation and ECM remodeling causes accelerated, superimposed atherosclerosis. Created with Biorender.com

native arteries [38,39]. Findings from observational post-mortem and post-surgical studies revealed that native vessel atherosclerotic plaques are focal, eccentric, calcify frequently and have well-defined fibrous caps [38,39]. In contrast, SVG atherosclerotic plaques develop quicker around the site of intimal thickening, lesions appear more diffuse and concentric, are less calcified and have poorly developed or even absent fibrous caps [39-42]. The SVG atherosclerotic plaques are densely infiltrated by foam cells and inflammatory cells, which contribute to the formation of a large necrotic core, associated with plaque rupture and thrombus formation [42].

Accelerated atherosclerosis is the predominant cause of stenosis in SVGs, reducing the patency rate to 40-60% at 10 years post-surgery [4,43]. The accelerated nature of atherosclerosis in SVGs is driven by a combination of factors, including mechanical stress from adaptive vascular remodelling, ischaemia-reperfusion injury and amplified inflammation, as mentioned above. EC pro-inflammatory phenotype promotes vascular inflammation and intimal thickening, which serve as a foundation for accelerated atherosclerosis. Pro-inflammatory cytokines such as interleukin-1, interleukin-6 and tumour necrosis factor-α stimulate VSMC proliferation and activate matrix-degrading enzymes, weakening plaque stability [44,45]. SVGs have increased infiltration by macrophages, granulocytes, and lymphocytes, and expression of class II antigens on the endothelium (features not typically seen in spontaneous atherosclerosis) [44,46,47]. Furthermore, diseased SVGs have been observed to have accumulated ECM, associated with enhanced stenosis and lipid accumulation [36]. ECM remodelling facilitates the transition from adaptive arterialisation to pathological intimal thickening and ultimately to advanced atherosclerotic plaque formation.

Although this article only briefly covers models of late VGD as it predominantly focuses on models of intermediate VGD suppressing intimal thickening is considered as a therapeutically attractive approach to blunt or delay atherosclerotic plaque formation and thereby suppress vein graft failure and enhance patient benefit [48,49].

CHARACTERISTICS OF AN APPROPRIATE MODEL OF VGD

Appropriate animal models serve as invaluable tools for evaluating therapeutic interventions, advancing surgical techniques, investigating molecular and physiological mechanisms, and verifying risk factors and markers. The value of any model is underpinned by its clinical relevance and depends on its ability to mimic complex human pathophysiology. Additional considerations include cost-effectiveness, technical feasibility and reproducibility, and ethical acceptability. Selection of an appropriate VGD model may also be guided by study-specific requirements, such as the availability of genetically modified strains, responsiveness to known disease risk factors, or the

feasibility of using accurate and clinically relevant outcome measurements. No single model is likely to meet all these criteria; hence, the specific research objective should be used to carefully guide model selection.

Similarity with human pathophysiology

Translational value is dependent on several basic factors: the comparability of the surgical procedure to CABG in clinic, the resemblance of the haemodynamic profile and vascular anatomy to humans, and the clinical relevance of outcomes measured.

Surgical procedure: In a clinical setting, to varying degrees, VGD is initiated by surgical trauma. Therefore, in experimental studies, reproducing key aspects of the CABG surgical procedure is critical to strengthening the translational potential. However, ensuring translational relevance across the full range of evolving clinical practices is challenging.

A number of saphenous vein harvesting techniques are utilised including traditional open vein harvesting (OVH), the 'no-touch' technique, the bridging technique, endoscopic vein harvesting (EVH), and the emerging minimally invasive 'no-touch' (MINT) technique [Figure 2]. By contrast, in experimental vein-graft animal models, open exposure and harvesting are typically used as this approach is technically simple and reliably produces a measurable neointimal response for mechanistic and interventional studies. Numerous studies have stressed that the degree of handling and manipulation inherent in OVH compromises graft patency by inducing endothelial injury, medial ischaemia, adventitial damage, and disruption to the vasa vasorum [50]. The no-touch technique was developed to address concerns with open harvesting by harvesting the saphenous vein with an intact pedicle of surrounding tissue – including the adventitia, perivascular fat, vasa vasorum and nerve fibres – thereby minimising surgical trauma [51-54]. Some randomised controlled trials and meta-analyses have demonstrated improved short- and long-term patency rates with no-touch harvesting compared to open harvesting [55], though other studies report conflicting results [56]. In animal models, the no-touch technique has rarely been used [57-59].

The bridging technique and EVH were introduced to reduce leg wound burden, including postoperative pain, infection, and bleeding, associated with OVH and 'no-touch [56,60]. Though both approaches successfully reduce wound size and postoperative wound complications, increased mechanical manipulation under the skin, and traction and compression during vein extraction [61], may impact graft patency, though recent advances have

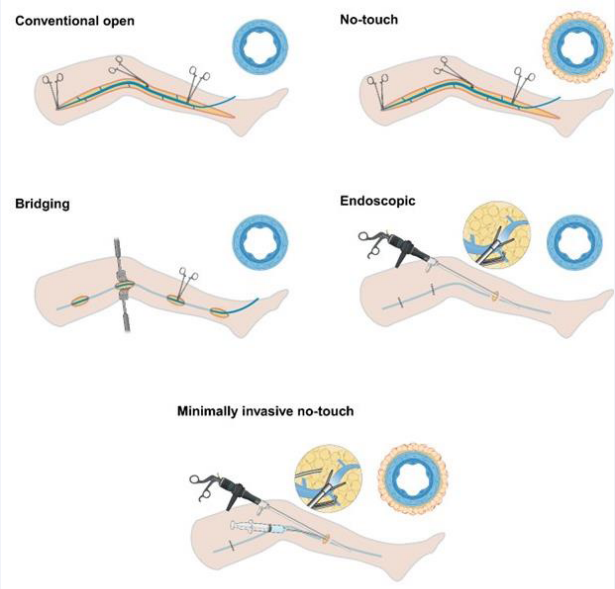

Figure 2 Saphenous vein harvesting techniques used for CABG surgical procedure.
In conventional open harvesting, a large continuous incision is made at the site of the saphenous vein (SV). The no-touch technique was developed later to minimize handling and manipulation of the SV by keeping the surrounding tissue intact, highlighted by the SV cross-section. Bridging technique involves creating smaller step incisions to harvest he SV, reducing scarring, wound complications, bleeding risks and infections post-surgery. Endoscopic technique is minimally invasive and uses specialized equipment to explant the SV through a small incision on the skin. Minimally invasive no-touch (MINT) technique used hydrodissection to preserve SV quality. Created with BioRender.com.

improved outcomes with EVH [62,63]. CABG EVH uptake is approximately 80% in the US, and around 50% in the UK and European countries [64,65]. However, EVH is rarely used in experimental animal models; where described, its use is limited to assessing the effects of EVH on conduit integrity, rather than vein-graft disease endpoints [66]. Consequently, current animal models do not evaluate or capture the outcomes of EVH leg-wound morbidity as well as potential secondary systemic effects.

Following saphenous vein harvest, intraluminal distension is typically performed by flushing with heparinised solution under pressure to open valves, identify potential leaks, increase luminal diameter and relieve spasms [67-69], and remains a widespread practice. High-pressure, manual distension can generate supraphysiological intraluminal pressures (>600mmHg) and has been associated with endothelial damage, impaired VSMC contractility, and increased inflammation [36,68,70,71]. These concerns have led many centres to adopt controlled low-pressure distention or no-distension techniques [72,73]. However, in many experimental models, high-pressure distension is routinely used as a "pre-implant injury" to accelerate the onset and progression of VGD.

An additional consideration is the intraoperative graft storage solution. Evidence indicates that saline, though still widely used in clinical practice, has a detrimental impact on endothelial viability and function [72]. A range of alternative preservation media including autologous heparinised whole blood, buffered solutions, pyruvate-based solutions, and cardioplegic and papaverine solutions, as well as the proprietary DuraGraft have been proposed or developed to mitigate or reduce EC injury. However, there is currently no consensus on which solution is superior. In the UK, selection of the graft storage solution is at the discretion of the surgeon, resulting in substantial variability across centres [74]. In animal studies, saline remains the most commonly used intraoperative storage solution along with heparinised saline [75]. Autologous heparinised whole blood has been occasionally used in large animal models [76].

In standard CABG using a saphenous vein conduit, the often reversed saphenous vein graft is typically anastomosed (end-to-side) proximally to the ascending aorta and distally to the target coronary artery beyond the site of stenosis [77]. This configuration introduces regions of low and oscillatory shear stress that promote EC dysfunction and inflammation, which ultimately drive focal intimal thickening. These features are most faithfully replicated in the technically demanding experimental CABG animal models (further discussed in sections 4.4-4.6). By contrast, many pre-clinical animal models of VGD use arteriovenous interposition grafting in a different vascular bed, in which an arterial segment is excised and replaced with a venous conduit using end-to-end anastomoses, generating a more uniform, predominantly laminar flow dynamic. An alternative is the arteriovenous bypass graft or shunt model, created by end-to-side anastomosis of a vein graft onto artery; this preserves bifurcation-type haemodynamics and may therefore offer greater translational value than interposition grafts.

The above mentioned dedicated vein-graft models are technically demanding, particularly in small animal models such as rodents. Consequently, rodent studies often use more feasible surrogate models of altered flow and vessel injury (including balloon angioplasty, wire denudation and arterial ligation) to investigate intimal thickening. In these models, neointima formation is driven by endothelial denudation and reduced shear stress, with intimal lesions typically developing within 2 to 4 weeks [4]. The limitations of these models, particularly from a translational perspective, are discussed under sections 3.1.2, 4.1 and 4.2.

For translational research, experimental animal models should evolve alongside changing clinical practices to maintain relevance; otherwise, technique-specific influences on VGD pathobiology may be overlooked. This underscores the importance of robust reporting standards and methodological transparency to enable recapitulation of key features of human VGD.

Haemodynamics and vascular anatomy: For studying intimal thickening in VGD specifically, vein graft models that capture the pathological responses of venous material to surgical trauma and arterialisation are essential. Arterial injury and flow-modulation models, such as balloon angioplasty, wire denudation and arterial ligation, are comparatively technically simple, robust, cheap, and are excellent for dissecting basic mechanisms underlying intimal thickening, including EC dysfunction, VSMC migration and proliferation, and inflammatory cell recruitment. However, the fundamental drivers of VGD are not conserved in these models, particularly, the substrate in both model types is artery, not vein. Hence, such key features of VGD including ischaemia-reperfusion injury, progressive dilation from a thin media with low VSMC and elastin content, compliance-mismatch, maladaptive responses of the venous endothelium to high shear stress, and disturbed flow at anastomosis and valve sites [78], are not reproduced in arterial injury and flow-modulation models. For translational studies, it is therefore essential

to use dedicated vein graft models that replicate the challenges of surgical injury and venous arterialisation.

An additional consideration is the size of the experimental animal as flow patterns and haemodynamics do not scale linearly (as reviewed by Acuna et al [79]. Computational flow dynamic modelling of disturbed flow regions such as anastomoses sites, predicts that in small animals, small vessel diameters generate Reynolds numbers that favour laminar flow; in large animals with large vessel diameters comparable to humans, high Reynolds numbers allow flow dynamics that approach turbulence. Furthermore, pulsation frequencies are typically higher in smaller animals compared to larger animals. As reviewed by Windberger *et al.*, whole blood viscosity also has high interspecies variability, with dogs and pigs diverging from human values the least, and mouse and rabbit the most [80]. Hence, when the primary objective is to study haemodynamics-driven vein graft pathology, large animal models are better suited.

Across the commonly used species, vessel wall architecture is conserved and exhibits the typical intima-media-adventitia organisation, though ECM composition, microvasculature, and valvular anatomy differ. Differences in ECM composition influence venous biomechanics, such that vessel distensibility, compliance, and vein-artery compliance-mismatch in animal models may not generalise to humans [81,82]. Additionally, in smaller animals, the vasa vasorum is sparse or limited, whereas in larger animals, its density and distribution within the vessel wall are comparable to that of human veins. This is likely due to transmural oxygen availability decreasing when the vessel wall exceeds a certain thickness (0.5mm, or 29 lamellar units, in mammals) and luminal diffusion alone is no longer sufficient for oxygen and nutrient delivery. Accordingly, rodents and other small animal models may overstate transmural hypoxia post-arterialisation [83,84], particularly relative to human saphenous veins harvested with the 'no-touch' technique, which preserves the vasa vasorum. Of note, in small animal vessels, shorter diffusion distances may also enhance vessel wall uptake of therapeutics compared to human veins, potentially overestimating exposure, efficacy and adverse side-effects. Finally, smaller species lack or have fewer valvular sinuses, thereby diminishing their ability to model valve site stenosis in humans [85]. All these species-specific differences should inform data interpretation.

Clinical relevance of outcome measures: In human aortocoronary SVGs, intimal thickening can be detected as early as 2 weeks post-implantation, and usually stabilises between 6 and 12 months, with neointimas typically being diffuse and concentric in appearance [28,86,87]. In vein graft models, vessel wall thickening can be observed in smaller species by as early as 1 to 2 weeks, with growth plateauing by 4 weeks in mice [88], by 20 weeks in rats [89], and by 12 weeks in rabbits [90]. In larger species, rapid intimal thickening is evident between 1 and 4 weeks, with continued but more gradual progression from 1 to 9 months in porcine models [91], and up to 12 months in ovine models [92], mirroring human disease trajectory more closely. Across species, vein graft neointimas are diffuse and concentric, as in humans [88,89,91,93,94].

Disease aetiology is broadly comparable between human and animal models, with initiation driven by endothelial denudation and dysfunction, followed by inflammatory cell infiltration, VSMC de-differentiation, migration, proliferation and ECM deposition. However, some notable differences with respect to molecular mechanisms may exist. Histological evaluation of diseased human SVGs with respect to intermediate and late VGD are characterised by ECM-deposition and a thick neointimal layer accompanied by atherosclerotic plaques [36,95,96]. Similarly, porcine SVGs become progressively thickened due to intimal thickening and ECM deposition [97,98]. However, pigs (and other animals: mice, rats and dogs) do not naturally develop atherosclerosis in the same way as humans due to low circulating levels of LDL-cholesterol [99-104], and thus further genetic modifications are usually required to account for the multifactorial nature of VGD. Added to this, interspecies variation of monocyte subsets (reviewed in Ebert *et. al.* [105], may contribute to chronic inflammation and irregular patterns of intimal thickening and atherosclerosis development in different animals compared to humans.

To assess SVG patency, several measures are undertaken during and following CABG. Intraoperative measurements usually consist of fluorescence imaging angiography, transient time flow measurement, Doppler ultrasonography or invasive coronary angiography [106]. Considering the short patency rate of SVGs, long term non-invasive measurements are utilised including computed tomographic angiography, magnetic resonance angiography and transthoracic Doppler echocardiography, although invasive coronary angiography may be necessary to assess further reintervention [106]. Findings from animal studies and humans are crucial for understanding VGD. Is it however important to ensure that measurements are clinically relevant to human practise. In rodents, there are limited ways to validate graft patency invasively considering the small murine vasculature. Usually, miniature equipment is utilised including Doppler and duplex ultrasonography, bioluminescence imaging or

micro-computed tomography angiography [107-110]. With increased size, there is increased clinical relevance due to the technical ability to use medical-level equipment to perform such measurements. In rabbits and pigs, Doppler ultrasound and computed tomography angiography are utilised [111,112], whereas in sheep, invasive angiography is more frequently performed [92,113,114].

Additional considerations: Additional translational considerations include the incorporation of clinically relevant comorbidities, particularly hyperlipidaemia: though hyperlipidaemia is an integral feature of vein graft atherosclerosis models, its potential influence on the earlier stages of vein graft VGD should also be recognised. Other common comorbidities, such as hypertension, diabetes mellitus, smoking status, and chronic systemic inflammation, may also be selectively incorporated depending on the research question. Such clinically relevant comorbidities also influence baseline graft pathology, with reports associating greater pre-existing intimal thickness and vein wall calcification with increased intimal thickening and graft stenosis in human and *ex vivo* studies [115-117]. Though these baseline features may be challenging to recapitulate in an experimental animal model, their translational relevance should be acknowledged when interpreting data. Age, biological sex, and routinely prescribed medications, such as anti-platelet and lipid-lowering drugs, could also be considered to ensure animal models more closely reflect human vein-graft pathology.

Practical considerations

In principle, translational potential and clinical relevance should be the primary determinants of model selection; however, in reality, practical constraints, including cost, technical feasibility, and ethical acceptability, are major factors that often influence the final choice.

Cost and resource considerations: Simply, animal studies are expensive. Costs also scale exponentially with species size, and the costs can limit sample sizes and thereby statistical power. Routine costs include space, housing, feeding, and animal maintenance by husbandry technicians. In housing fees alone, sheep, pigs, canines and rabbits have been exstimated to be approximately 80-, 60-, 90- and 30-fold more expensive than mouse studies, respectively [118]. The cost of drugs or alternative medicines, surgical consumables, and post-operative care materials also increases significantly with species size. Long-term follow-ups amplify all these expenses.

Regarding infrastructure and equipment, small animal work requires benchtop stations, a microsurgical setup and basic monitoring; large animal facilities need clinical-grade sterile operating theatres, and advanced imaging and monitoring systems. Rodent work can be supported by limited veterinary oversight and one or two research staff trained in-house (an additional expense), whereas large animal studies require a specialist, multidisciplinary team comprised of surgical, anaesthetic, veterinary and other supporting personnel, and demand more intensive and continuous care.

With vein graft models, attrition rates are generally modest in small animals (5-16% in mouse models [119], and near-zero in large animals (notwithstanding CABG-type models, see section 3.2.2), so do not contribute considerably to the overall study cost. Other expenses may include licences and regulatory and ethical oversight, though these vary by country. Ultimately, the scientific and translational value of a model has to be weighed against financial feasibility [120,121].

Technical feasibility and reproducibility: In clinical practice, saphenous vein CABG is arguably one of the most technically complex procedures in cardiac surgery, making it inherently difficult to fully replicate in experimental models. Though off- and on-pump porcine and canine CABG models have been established [122-125], they have not become a routinely used translational platform for studying VGD. This is likely because these models are resource-heavy, require advanced microsurgical skill and cardiothoracic expertise, and, in some cases, exhibit high intra-operative mortality due to ventricular tachycardia or fibrillation, lowering ethical acceptability [125-127].

Instead, the less but still technically demanding carotid or aortic bypass graft models and the arteriovenous interposition graft models have been widely adopted in translational research [128]. The end-to-side configuration in carotid or aortic bypass grafts presents greater technical difficulty than the end-to-end arrangement in interposition grafts, with kinking, leaks, and occlusion posing recurrent challenges and anastomotic angle contributing to variability. In small animals, suture-based anastomosis of venous grafts into arterial circulation is particularly technically demanding, introduces variability, and raises intraoperative mortality and graft failure rates (reviewed in Peng *et al*, [119]. For these reasons, anastomotic cuffs have been widely implemented owing to their relative simplicity, high reproducibility and reduced risk of bleeding, thrombosis and mortality [129].

Arterial-injury and flow-modulation models are frequently performed in small animal models for procedural simplification (see sections 4.1 and 4.2),

however these are not true, dedicated vein graft models. Hence, the development of experimental vein graft models has required balancing clinical relevance with technical feasibility, reproducibility, and ethical considerations.

Ethical acceptability: The 3R principles (Replacement, Reduction, Refinement) provide a framework for responsible scientific use of animals in scientific research and apply to all species. However, *perceived ethical acceptability* varies greatly between species. Rodents typically carry a lower ethical burden, perhaps partly due to their long-standing cultural classification as pests or vermin [130]. Conversely, the use of companion species, such as dogs and cats, is highly ethically sensitive, limiting their use in biomedical research [131]. Due to their cognitive complexity and advanced social behaviour, monkeys and non-human primates (NHP), are subject to the highest ethical scrutiny, such that their use is tightly regulated and becoming increasingly rare [132]. NHP models are exceptionally uncommon in VGD research: we have identified only two reports describing saphenous vein aorto-coronary artery bypass grafting in chacma baboons [133,134]. Given its limited use, NHP models are not further discussed in this review. Livestock animals, such as pigs and sheep, have better acceptability rates than companion or non-human primate models, but still raise greater ethical concern than rodents. However, as they improve the chances of successful clinical translation, they are often the preferred option [135]. Therefore, model selection should be guided by weighing ethical acceptability against potential translational value.

ANIMAL MODELS

We have reviewed the strengths and limitations of clinically relevant CABG models, carotid-bed arteriovenous grafts, as well as the carotid artery injury and flow-modulation models using different species. We have excluded models where venous grafts are placed into the femoral, iliac or infragenual beds, as these models are predominantly used to study peripheral artery disease.

Mouse

Mouse disease models have been extensively used to study intimal thickening. These include injury (balloon injury, wire denudation), flow modulation (ligation) and interposition grafting models. Generally, key benefits of using mice in vein-graft intimal thickening research include lower costs, the wide availability of genetically modified strains, fast breeding cycles, and good reproducibility rates through inbred strains.

Balloon injury: The balloon injury model is performed by insertion of a miniature balloon catheter in an artery, usually the carotid artery or the abdominal aorta [136,137], followed by inflation of the balloon. This causes significant disruption of the internal elastic lamina and endothelial denudation, which results in vascular inflammation, VSMC activation and intimal thickening as previously described by Matter *et. al.* [136].

One of the main challenges faced by researchers is the lack of commercially available miniature balloons required to precisely distend murine arteries [138]. The small murine vasculature requires in-house designed miniature-balloons which compared to commercially available larger balloons don't include pressure gauges and thus may not be suitable to accurately control distention pressure [137]. Poorly controlled distention pressures can result in model failure and affect reproducibility. Arterial overdistention can lead to aneurysm formation and arterial tearing, whereas inadequate distention may fail to reliably induce robust intimal thickening [136,137]. The genetic background of mice can also affect intimal thickening development rates. For example, balloon injury performed in Apolipoprotein E knock out ($Apoe^{-/-}$) mice exposed to a high fat diet can induce intimal thickening [136], but not as effectively as other larger animal models (dogs, pigs, sheep) undergoing interposition grafting or bypass grafting.

Despite careful considerations and modifications of this model, balloon injury may not be the best procedure to study VGD-related intimal thickening due to the lack of resemblance to the CABG procedure itself. It has greater relevance in the context of balloon angioplasty and in-stent restenosis.

Wire denudation: Wire denudation entails the insertion of a flexible wire catheter into the carotid artery via an arteriotomy and mechanically scraping the endothelium and damaging the vascular wall, resulting in EC loss, VSMC activation and intimal thickening within two weeks following injury [139,140].

Microsurgical wire injury in mice is deemed technically challenging and is highly dependent on operator skill. The arteriotomy should not be too large to reduce the risk of haemorrhage and arterial tearing [141]. Neointimal development can be strongly influenced by injury severity: limited injury often results in endothelial loss, but no VSMC proliferation [141-143], whereas deeper injury with disruption of the internal elastic lamina more reliably induces VSMC proliferation in addition to endothelial injury and dysfunction [141-143]. Besides the procedure itself, as in the balloon injury model, the mouse genetic background

can also influence neointimal response. Hui *et al.,* previously demonstrated strain-dependent variability in both intimal thickening and atherosclerotic lesion development following wire denudation injury [140]. Under a high-fat diet, C57BL/6 mice developed atherosclerotic lesions but showed minimal intimal thickening, whereas, FVB/N mice were found to be resistant to atherosclerotic lesion development yet developed moderate intimal thickening, though not as severe as that observed clinically [140,141].

The limitations of wire denudation are comparable to balloon injury, with both experimental models not being true, dedicated vein graft models. Wire denudation may be more appropriate for in-stent thrombosis and restenosis investigations.

Ligation: The carotid ligation model involves a midline cervical incision to expose the left carotid artery, followed by its complete ligation and occlusion using a suture knot [144]. This leads to the cessation of blood flow in the left carotid artery, which causes EC dysfunction, inflammation, thrombosis, VSMC activation and in turn, intimal thickening [144]. The lack of blood flow in the left carotid artery is compensated by increased shear stress in the contralateral carotid artery, enabling investigation of the effects of altered shear stress on arterial remodelling [144].

Variations of this method involve partial occlusion of the left or right carotid artery using a ligature or cuff. The stenotic segment of the artery generates high laminar shear stress, distal to the stenosis, low and oscillatory shear stress is produced, which contributes to the development of intimal thickening [145,146]. A cuff may be more appropriate for flow restriction compared to a ligature, as it provides a well-defined restrictive diameter selected by the operator, improving reproducibility.

Generally, the carotid ligation model offers greater technical feasibility compared to other mouse models, as it does not require arteriotomy of the carotid artery, thereby reducing the risk of haemorrhage, arterial tearing and model failure. Intimal thickening usually develops within two-four weeks of carotid ligation [140], with strain-dependent differences in rate and extent of intima development [147]. However, the procedure does require consistent placement of the cuff or suture at the same site along the carotid artery in all mice.

Although a widely used mouse model of intimal thickening, carotid ligation it does not recapitulate key features of CABG. The carotid ligation model is better suited to examining shear stress-driven remodelling.

Interposition grafting: Less frequently, the arteriovenous interposition grafting model is used in mice. This model utilises the donor-recipient system whereby a vein (jugular or inferior vena cava) is harvested from a donor mouse to replace a segment of an artery (carotid, femoral or aorta) in the recipient mouse via either an end-to-end or end-to-side anastomosis [88,148-150]. The primary benefit of this model is that it reproduces key components of VGD, including surgical trauma and venous arterialisation, thereby enhancing comparability to CABG in clinical settings (see section 3.1.2) [88,105]. However, the graft becomes acellular following implantation and is repopulated by host circulating and arterial cells [148], which differs significantly from human graft pathophysiology where graft cells contribute to intimal thickening.

Another limitation of murine interposition grafting is the technical challenge posed by the small murine vasculature, making successful arteriovenous anastomosis highly dependent on operator skill and experience. Anastomotic error increases the risk of model failure due to excessive bleeding and thrombosis [119]. Anastomotic integrity is most frequently assessed using ultrasound imaging, though limited spatial resolution can reduce confidence [88]. Alternatively, computed tomography (CT) and magnetic resonance imaging (MRI) scans can provide better visualisation but these come at an increased cost [151]. To reduce technical variability and attrition rates, anastomosis can be facilitated by the use of a cuff. Briefly, a cuff is placed over the ends of the exposed artery, the arterial ends are everted over the cuff, and the vein graft is sleeved over and be secured with sutures [148].

Despite successful grafting, this model does not generally develop substantial intimal thickening, even with long-term follow-ups exceeding 6 months [119]. This can often be attributed to the inbred strain selected. Modifications of this method, such as flow-restriction using a ligature or cuff applied to the graft itself or proximal artery, have been employed to introduce turbulent flow and thereby exacerbate intimal thickening [129]. However, these modifications bring additional technical challenges, particularly with obtaining accurate pressure measurements in small blood vessels and validating turbulent flow [129].

Rat

Although used less frequently than mice, rat models provide a larger rodent alternative for studying intimal thickening. Approaches used to induce intimal thickening are broadly similar between mice and rats. Due to their larger vessel calibres, rats offer better operability, and

therefore less variability in outcomes, compared to mice (inner common carotid artery radius: 0.41-0.55mm in rats vs. 0.22-0.35mm in mice) [152,153]. Additionally, rats also yield more tissue for diverse analysis. However, due to longer reproductive cycles, rats are less genetically tractable than mice, offering fewer genetically engineered strains; furthermore, they are also more expensive to maintain, reducing scalability. If required, clinically relevant comorbidities can be incorporated: for example, the spontaneously hypertensive rat for hypertension studies, and the obese Zucker rat or Wistar Kyoto fatty rat for diabetes research, and the $Apoe^{-/-}$ rat for hypercholesterolaemia [154,155]. Importantly, though $Apoe^{-/-}$ rats display dyslipidaemia, they do not develop obvious atherosclerotic lesions; moreover, addition of partial carotid ligation has yielded mixed findings on whether plaque formation is induced [156,157].

Of the arterial injury and flow modulations models, carotid balloon angioplasty remains one of the best characterised rat procedures for studying vascular remodelling. In rats, this model is supported by the use of widely commercially available balloons catheters and inflation devices that allow monitoring of distension pressures [158-160]. However, as discussed in section 3.1.2 and 4.1, such models are better suited to interrogating mechanisms of intimal thickening related to in-stent restenosis and balloon angioplasty, rather than the distinct pathophysiological processes underlying vein-graft intima formation.

Interposition grafting is utilised less frequently in rats, with autologous interposition of the right external jugular vein into the common carotid artery being the most preferred model [161], although some studies interpose the jugular vein into the abdominal aorta [162,163]. Their larger vessel calibre compared to mice also facilitates the use of non-invasive duplex sonography to assess graft patency [110]. The procedure does however still require a skilled operator and specialised microsurgical equipment, as small anastomotic inconsistencies and errors can introduce variability in intimal thickening and increase risk of early model failure [110,161]. Arteriovenous diameter mismatch also poses an anastomotic challenge with this model [110]. Though less clinically relevant, cuffs, or adjuncts including fibrin glue or formalin-fixed interstitial sheaths, can be used to avoid anastomotic tearing and over-distention, and to help accommodate arteriovenous diameter mismatch [110,161,162]. In contrast to mice, autologous interposition grafts are usually preferred in rats, avoiding alloimmune effects and the additional cost and ethical burden of donor-recipient systems. In cases where the donor-recipient model is utilised, the donor superficial epigastric vein or inferior vena cava is interposed into the recipient abdominal aorta [110,164].

Rabbit

The most common lapine model of CABG-related VGD is the reversed external jugular vein to common carotid artery interposition graft with end-to-end anastomoses [142-145]. The New Zealand White, Japanese White, Chinchilla and Giant Chinchilla breeds are preferred for their larger size and vessel diameters. Deviations from this core model include: 1) end-to-side anastomoses with the carotid artery segment between the two anastomoses left patent, partially ligated, or completely ligated and divided [165-167]; 2) additional flow-modifying adjuncts, such as external mid-graft ligatures [168,169], partial or complete ligation of the distal internal carotid artery and branches of the external carotid artery [170,171], and arteriovenous fistula placement[172,173]. cuff-based anastomotic techniques [172-174], common carotid vein patches constructed from external jugular vein, with the distal common carotid ligated to generate markedly low wall shear stress [173,174]. These variations aim to improve comparability to humans, study specific haemodynamic and biological parameters, or enhance technical feasibility and reproducibility.

The human saphenous vein and rabbit external jugular vein have broadly comparable vessel diameters (external (distended)/luminal (no-touch): 4.2±0.6mm/2.9±0.4mm in human saphenous vein [175,176] vs. external/luminal diameter: 2.5-3.5mm/3.0±0.3mm in New Zealand White rabbit external jugular vein [177,178], permitting testing of clinically relevant perivascular devices, including polyester meshes, scaffolds, and films, as well as endoluminal devices such as stents [58,179-183]. In rats, such platforms need to be miniaturised and are therefore less directly representative of clinical devices [184-187]. Larger vessel calibres in rabbits also allow the use of intravascular imaging techniques such as intravascular ultrasound, enabling *in vivo* assessment of intimal thickening, luminal area, and vein graft patency [188]. In addition, rabbit external jugular vein walls are substantially thinner than human saphenous vein walls [189], the implications of this for intimal thickening are unknown, and in studies testing endovascularly or peri-vascularly delivered drugs, the shorter transmural diffusion distance should be taken into account when extrapolating findings to humans.

Although not the primary focus of this review, rabbit models of vein-graft atherosclerosis are also valuable for studying late VGD. However, rabbits are highly sensitive to dietary cholesterol, rapidly developing extreme hypercholesterolaemia with levels far exceeding

pathological values reported in most human CABG patients [190-192]. To avoid these extreme lipid levels that may limit translatability, as well as induce hepatic injury in rabbits, in some vein-graft studies, dietary cholesterol content is monitored and adjusted to maintain serum cholesterol levels within a pre-defined range (typically within 200-800mg/dL) [193,194]. Furthermore, pronounced platelet aggregation responses are associated with diet-induced hypercholesterolaemia in rabbits; hence, for studies specifically interrogating late vein-graft thrombosis, findings from cholesterol-fed rabbits should be interpreted with caution [195-197].

Dog

Historically, dogs have been fundamental to the development of CABG techniques, with Alexis Carrel's pioneering carotid-coronary artery grafting work dating back to as early as 1910 [198]. However, canine CABG models are not routinely used today. When used, approaches include end-to-side saphenous vein grafting between the aorta and LAD, as well as between the LITA and LAD [125,127,128]. One of the reasons for their limited use is the relatively high intraoperative mortality rates (approximately 13%), primarily an outcome of ventricular arrhythmias [127]. Additionally, dogs have a well-developed coronary collateral network, which provides protection against myocardial infarction, reducing clinical relevance [199]. Furthermore, coronary circulation patterns vary between canine subjects (mongrels or purebreds), resulting in altered outputs; whereas variation in other large animal models, such as porcine, is similar to that of humans [200].

Of the carotid-bed canine models, the most widely applied is the jugular or femoral vein-to-carotid artery interposition graft. An alternative modelp that has also been adopted is the bypass-style approach with end-to-side anastomoses, where the native carotid artery segment between the two anastomoses sites is ligated and divided [57]. These models are technically less demanding and associated with lower mortality compared to canine CABG models. Canine, swine and ovine models of vein-graft intimal thickening have recently been systematically reviewed by Fashina *et al.* [128].

Research involving dogs comes with high costs and increased public perceptions, as highlighted in sections 3.2.1 and 3.2.3. Additionally, dogs should not be housed individually, as they have high demands and require more exercise and attention [120,121]. Dogs are naturally resistant to atherosclerotic plaque development even when maintained on a high-fat diet, such that CAD and stroke are rare and not typically associated with obesity in dogs [101,102]. This has been attributed to their high-density lipoprotein dominant lipid profiles in the absence of metabolic disease [201]. Therefore, dogs are likely less suitable for studying vein-graft atherosclerosis.

Pig

Porcine models used to study vein graft intimal thickening include CABG, arteriovenous interposition grafting and arteriovenous bypass grafting. The technically simpler and preferred pig model of carotid artery-to-jugular or saphenous vein interposition or bypass grafting has been systematically reviewed by Fashina *et al.* [128]. Porcine CABG models have been described using: 1) end-to-side anastomosis of the internal thoracic vein between the ascending aorta and the LAD [202,203], superficial epigastric vein (analogous to the human SV) between LITA and LAD [97,204,205]. However, the anatomical configuration of the porcine heart renders exposure of the ascending aorta technically challenging, complicating anastomosis [126]. This may influence experimental outcomes such as intimal thickening, as even minor changes in anastomotic angle can alter haemodynamics [200,206]. Additionally, echocardiographic assessment of the left ventricle can be challenging as pigs have thick thoracic cages [122,126]. Finally, as in canine CABG models, pigs are susceptible to developing perioperative ventricular fibrillation, contributing to increased mortality rates [126,202].

In vein-graft models, normocholesterolaemic pigs reliably develop neointimas that have a high level of similarity with the human pathophysiology due to comparability of vein and artery size and methods of autologous saphenous vein removal and preparation, but not vein-graft atherosclerosis. In a study by Angelini *et al.*, Landrace pigs fed an atherogenic diet developed modest hypercholesterolaemia (11.2±1.2mmol/L), such that foam cells were detected in carotid-saphenous vein interposition grafts at 12 weeks post-implantation, consistent with early atherosclerotic plaque development [207]. Work by Thim et al., demonstrated that, in down-sized Rapacz minipigs with familial hypercholesterolaemia (attributed to a LDL receptor mutation) fed an atherogenic diet (plasma total cholesterol: >20mmol/L), advanced atherosclerotic lesions with lipid-rich necrotic cores formed in oversized internal jugular vein grafts interposed into the common carotid artery [100,208]. Graft diameter was correlated with the presence of advanced lesions, implicating low flow and reduced shear stress as contributing factors [100]. Plaque rupture and atherothrombosis was not observed, though the authors noted that such events may occur silently

and that reproducible experimental animal models of spontaneous plaque rupture and thrombosis do not exist [100]. Longer follow-up may capture these outcomes, but at substantial additional cost [100].

Sex-related anatomical, hormonal and growth differences in pigs introduce biological variability that may influence outcomes [209]. Thus, female pigs are commonly used to minimise intra-experimental variability. Practical considerations also promote the use of female pigs as male pigs display aggressive behaviour towards other pigs, complicating group housing [209]. Castration can be used to attenuate aggression and hormone-related variability; however, castrated males should be recognised as a distinct sex category [210].

Sheep

Ovine models of intimal thickening in VGD include CABG and the technically simpler carotid-to-jugular, femoral vein or radial artery arteriovenous interposition or bypass grafts (reviewed by Fashina *et al.*[128,92,93,113,114,211-216].

The ovine CABG procedure typically entails end-to-side anastomosis of the saphenous vein to the descending aorta (inflow) and to the LAD or circumflex coronary artery (outflow) [92,113,114] [Figure 3]. A less common variation of this standard model involves use of the brachiocephalic trunk as the inflow vessel to improve technical feasibility, though this reduces clinical relevance [215,216]. Ovine studies are often longitudinal, with follow-ups extending up to a year following surgery, enabling assessment of longer-term outcomes [217]. A notable anatomical difference is that sheep (and dogs) have left-dominant coronary circulation, such that the myocardium is predominantly supplied by the left coronary system, whereas humans and pigs are right-dominant [218]. Procedurally, sheep are susceptible to intractable ventricular fibrillation, particularly with perioperative hypothermia and even short periods of ischaemia [216,219], and therefore anti-arrhythmic medication (e.g. amiodarone) and beta-blockers (e.g. propranolol or esmolol) are commonly administered, alongside careful temperature management [215,216,219]. Finally, in ovine CABG models, median sternotomy carries a high risk of sternal wound infection and mediastinitis, as sheep spend 8-9 hours a day in sternal recumbency [216,219]. Consequently, a left lateral thoracotomy is recommended to reduce sternal wound complications [216].

Despite many parallels between ovine and humans coagulation systems, sheep display higher thrombotic susceptibility and reduced responsiveness to standard anti-platelet drugs (e.g. clopidogrel, ticagrelor and aspirin) [220]. Accordingly, many protocols involve more aggressive anti-coagulation (e.g. heparin: 85 units/kg), with additional dosing titrated to achieve a clotting time of more than 200 seconds [220,221].

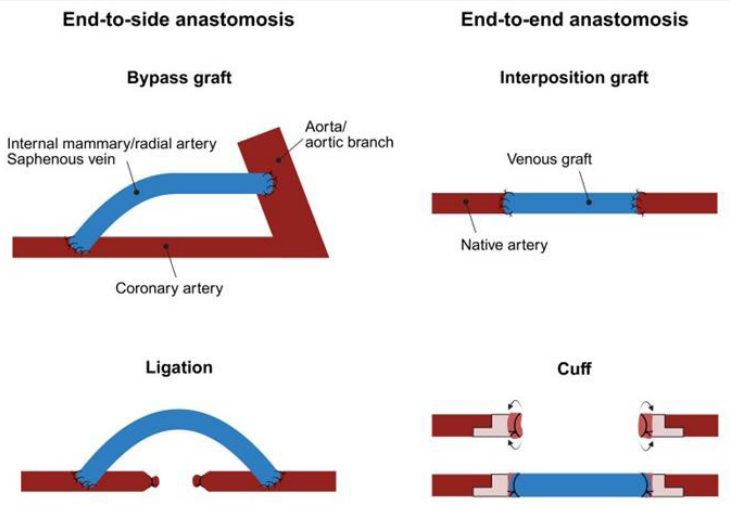

Figure 3 **Anastomosis techniques for graft implantation**
End-to-side anastomosis technique joins the open end of one vessel to the side of another vessel. In the clinical setting, it is standard to use this technique for CABG (BYPASS GRAFT), where the blocked site is bypassed by diverting blood flow. Many animal models of ligation have variations of this anastomosis technique, where the graft is implanted to the sides of a ligated vessel. End-to-end anastomosis technique forms one straight path by joining two open vessel ends together. Animal models of interposition grafting uses this technique to implant a venous graft into a part of the artery. Animal models of interposition grating uses this technique to implant a venous graft into a part of the artery. Animal models also use cuffs to perform an end-to end anastomosis, where the exposed arterial ends are everted over cuffs, and the graft is sleeved over and secured with sutures. Created with BioRender. Com.

In addition to this, sheep are more prone to emotional distress in response to restraint and isolation compared to other domesticated animals [222]. Therefore, it is important to implement low stress handling and habituation, minimise the frequency of procedures, and prioritise non-invasive procedures to monitor graft patency. For example, in sheep studies, where possible, Doppler ultrasonography is usually preferred over invasive fluoroscopic angiography to assess graft patency and flow [217,220].

ADDITIONAL MODELS

Ex vivo models utilising surplus human saphenous vein tissue are a valuable platform for studying intimal thickening in VGD. Advantages of these systems include preservation of vessel architecture and cell-cell interactions, capture of patient heterogeneity, tight control over experimental conditions, and avoidance of species-specific differences inherent to animal models. human saphenous vein *ex vivo* models are often positioned as a bridge between *in vitro* discovery work and vein-graft animal studies, aligning well with the 3Rs ethical framework (see section 3.2.3).

These *ex vivo* models involve obtaining fresh, surgically-prepared, surplus segments of saphenous vein from patients undergoing CABG surgery and maintaining them under controlled, sterile laboratory conditions [223,224]. Adventitial tissue is commonly removed to limit neointimal fibroblast contamination. In the static culture system, vein is opened up longitudinally and pinned down with the luminal surface facing upwards. However, the absence of flow renders ECs more susceptible to apoptosis. To recapitulate the arterial environment more closely, human saphenous vein segments can also be cultured in dynamic perfusion systems to simulate pulsatile flow and pressure. In these systems, peristaltic pumps and pressure controllers enable precise regulation of flow and pressure [225-227], though the use of these setups requires experience and expertise.

Ex vivo systems do however lack systemic physiological influences present *in vivo*, including immune responses, hormonal regulation, and circulating progenitor cell populations, limiting their ability to fully reproduce the complexity of the vascular environment. Migration and recruitment of cells from adjacent native artery is also inherently absent in these isolated *ex vivo* systems [228,229]. Lastly, human saphenous vein *ex vivo* models are not suitable for studies of long-term remodelling due to progressive loss of cell viability and function with extended culture. Also, from a practical perspective, access to surgeries and fresh patient-derived may be limited at some research centres; in such cases, porcine saphenous vein is sometimes used as an alternative [225-227].

CONCLUSIONS

Despite decades of preclinical research, there are currently no approved therapies in routine clinical use that specifically target intimal thickening in coronary artery bypass VDG. Closing such translational gaps requires improving the translatability of experimental animal models. This need must be balanced against cost, the facilities and expertise available, and ethical considerations. In this review, we have summarised evidence from the literature to guide selection of the most appropriate intimal thickening model for specific research questions, and presented the clinical relevance, strengths, and limitations of each approach.

Acknowledgements: This work was supported by British Heart Foundation (FS/4yPhD/F/22/34173 and FS/4yPhD/F/20/34125).

REFERENCES

1. Kandaswamy E, Zuo L. Recent Advances in Treatment of Coronary Artery Disease: Role of Science and Technology. Int J Mol Sci. 2018; 19: 424.
2. Raza Raza S, Chang C, Deo SV, Sabik JF 3rd. Current role of saphenous vein graft in coronary artery bypass grafting. Indian J Thorac Cardiovasc Surg. 2018; 34: 245-250.
3. Malakar AK, Choudhury D, Halder B, Paul P, Uddin A, Chakraborty S. A review on coronary artery disease, its risk factors, and therapeutics. J Cell Physiol. 2019; 234: 16812-16823.
4. Martínez-González B, Reyes-Hernández CG, Quiroga-Garza A, Rodríguez-Rodríguez VE, Esparza-Hernández CN, Elizondo-Omaña RE, et al. Conduits Used in Coronary Artery Bypass Grafting: A Review of Morphological Studies. Ann Thorac Cardiovasc Surg. 2017; 23: 55-65.
5. Burke AP, Kolodgie FD, Farb A, Weber DK, Malcom GT, Smialek J, et al. Healed plaque ruptures and sudden coronary death: evidence that subclinical rupture has a role in plaque progression. Circulation. 2001; 103:934-940.
6. Lim SY. Role of statins in coronary artery disease. Chonnam Med J. 2013; 49: 1-6.
7. Lee MS, Park SJ, Kandzari DE, Kirtane AJ, Fearon WF, Brilakis ES, et al. Saphenous vein graft intervention. JACC Cardiovasc Interv. 2011; 4: 831-843.
8. Hulman M, Artemiou P, Bezak B, Hudec V, Glonek I, Bena M, et al. Adult cardiac surgery report 2021: The annual report from the Registry of the National Institute of Cardiovascular Diseases. Bratisl Lek Listy. 2023; 124: 170-174.
9. Caliskan E, de Souza DR, Böning A, Liakopoulos OJ, Choi YH. Saphenous vein grafts in contemporary coronary artery bypass graft surgery. Nat Rev Cardiol. 2020; 17: 155-169.
10. Buxton BF, Hayward PA, Raman J, Moten SC, Rosalion A, Gordon I, et al. Long-Term Results of the RAPCO Trials. Circulation. 2020; 142: 1330-1338.

11. Kasahara H, Shin H, Takahashi T, Murata S, Mori M. Comparison of patency of single and sequential radial artery grafting in coronary artery bypass. Interact Cardiovasc Thorac Surg. 2022; 34: 515-522.

12. Tranbaugh RF, Dimitrova KR, Friedmann P, Geller CM, Harris LJ, Stelzer P, et al. Coronary artery bypass grafting using the radial artery: clinical outcomes, patency, and need for reintervention. Circulation. 2012; 126: S170-S175.

13. Choudhary BP, Antoniades C, Brading AF, Galione A, Channon K, Taggart DP. Diabetes mellitus as a predictor for radial artery vasoreactivity in patients undergoing coronary artery bypass grafting. J Am Coll Cardiol. 2007; 50: 1047-1053.

14. Cancelli G, Audisio K, Chadow D, Soletti GJ, Gaudino M. The evidence for radial artery grafting: When and when not? JTCVS Tech. 2021; 10: 114-119.

15. Nappi F NA, Schoell T, Acar C. Radial Artery Used as Conduit for Coronary Artery Bypass Grafting. Surgeries. 2025; 6.

16. Sabik JF 3rd. Understanding saphenous vein graft patency. Circulation. 2011; 124: 273-275.

17. Xenogiannis I, Zenati M, Bhatt DL, Rao SV, Rodés-Cabau J, Goldman S, et al. Saphenous Vein Graft Failure: From Pathophysiology to Prevention and Treatment Strategies. Circulation. 2021; 144: 728-745.

18. Harskamp RE, Lopes RD, Baisden CE, de Winter RJ, Alexander JH. Saphenous vein graft failure after coronary artery bypass surgery: pathophysiology, management, and future directions. Ann Surg. 2013; 257: 824-833.

19. Goldstein DJ, Puskas JD, Alexander JH, Chang HL, Gammie JS, Marks ME, et al. External Support for Saphenous Vein Grafts in Coronary Artery Bypass Surgery: A Randomized Clinical Trial. JAMA Cardiol. 2022; 7: 808-816.

20. Motwani JG, Topol EJ. Aortocoronary saphenous vein graft disease: pathogenesis, predisposition, and prevention. Circulation. 1998; 97: 916-931.

21. McQueen LW, Ladak SS, Zakkar M. Acute shear stress and vein graft disease. Int J Biochem Cell Biol. 2022; 144: 106173.

22. Guida GA, Angelini GD. Pathophysiology and Mechanisms of Saphenous Vein Graft Failure. Braz J Cardiovasc Surg. 2022; 37: 32-37.

23. de Vries MR, Quax PHA. Inflammation in Vein Graft Disease. Front Cardiovasc Med. 2018; 5:3.

24. Sandoo A, van Zanten JJ, Metsios GS, Carroll D, Kitas GD. The endothelium and its role in regulating vascular tone. Open Cardiovasc Med J. 2010; 4: 302-312.

25. Koupenova M, Kehrel BE, Corkrey HA, Freedman JE. Thrombosis and platelets: an update. Eur Heart J. 2017; 38: 785-791.

26. Domanski MJ, Borkowf CB, Campeau L, Knatterud GL, White C, Hoogwerf B, et al. Prognostic factors for atherosclerosis progression in saphenous vein grafts: the postcoronary artery bypass graft (Post-CABG) trial. Post-CABG Trial Investigators. J Am Coll Cardiol. 2000; 36: 1877-1883.

27. Méndez-Barbero N, Gutiérrez-Muñoz C, Blanco-Colio LM. Cellular Crosstalk between Endothelial and Smooth Muscle Cells in Vascular Wall Remodeling. Int J Mol Sci. 2021; 22: 7284.

28. Lau GT, Ridley LJ, Bannon PG, Wong LA, Trieu J, Brieger DB, et al. Lumen loss in the first year in saphenous vein grafts is predominantly a result of negative remodeling of the whole vessel rather than a result of changes in wall thickness. Circulation. 2006; 114: I435-1440.

29. Muto A, Model L, Ziegler K, Eghbalieh SD, Dardik A. Mechanisms of vein graft adaptation to the arterial circulation: insights into the neointimal algorithm and management strategies. Circ J. 2010; 74: 1501-1512.

30. de Vries MR, Quax PHA. Inflammation in Vein Graft Disease. Front Cardiovasc Med. 2018; 5: 3.

31. Goldstein DJ, Chang HL, Mack MJ, Voisine P, Gammie JS, Marks ME, et al. Intimal hyperplasia, saphenous vein graft disease, and clinical outcomes: Insights from the CTSN VEST randomized trial. J Thorac Cardiovasc Surg. 2024; 167: 1782-1792.

32. Guida G, Ward AO, Bruno VD, George SJ, Caputo M, Angelini GD, et al. Saphenous vein graft disease, pathophysiology, prevention, and treatment. A review of the literature. J Card Surg. 2020; 35: 1314-1321.

33. Rebello KR, LeMaire SA, Shen YH. Aortic Neointimal Formation: The Role of Elastin in Conjunction With Vascular Smooth Muscle Cell Origin. Arterioscler Thromb Vasc Biol. 2021; 41: 2906-2908.

34. Jaminon A, Reesink K, Kroon A, Schurgers L. The Role of Vascular Smooth Muscle Cells in Arterial Remodeling: Focus on Calcification-Related Processes. Int J Mol Sci. 2019; 20: 5694.

35. Wadey K, Lopes J, Bendeck M, George S. Role of smooth muscle cells in coronary artery bypass grafting failure. Cardiovasc Res. 2018; 114: 601-610.

36. Kahle B, Schmidtke C, Hunzelmann N, Bartels C, Sievers HH, Steenbock H, et al. The Extracellular Matrix Signature in Vein Graft Disease. Can J Cardiol. 2016; 32: 1008.e11-1008.e17.

37. Xenogiannis I, Zenati M, Bhatt DL, Rao SV, Rodés-Cabau J, Goldman S, et al. Saphenous Vein Graft Failure: From Pathophysiology to Prevention and Treatment Strategies. Circulation. 2021; 144: 728-745.

38. Lytle BW, Loop FD, Taylor PC, Simpfendorfer C, Kramer JR, Ratliff NB, et al. Vein graft disease: the clinical impact of stenoses in saphenous vein bypass grafts to coronary arteries. J Thorac Cardiovasc Surg. 1992; 103: 831-840.

39. Mautner SL, Mautner GC, Hunsberger SA, Roberts WC. Comparison of composition of atherosclerotic plaques in saphenous veins used as aortocoronary bypass conduits with plaques in native coronary arteries in the same men. Am J Cardiol. 1992; 70: 1380-1387.

40. Huang TH, De Silva K, Allahwala UK, Danson EJ, Karjalainen PK, Kajander OA, et al. In vivo morphologic comparison of saphenous vein grafts and native coronary arteries following non-ST elevation myocardial infarction. Cardiovasc Revasc Med. 2019; 20: 16-21.

41. Kalan JM, Roberts WC. Morphologic findings in saphenous veins used as coronary arterial bypass conduits for longer than 1 year: necropsy analysis of 53 patients, 123 saphenous veins, and 1865 five-millimeter segments of veins. Am Heart J. 1990; 119: 1164-1184.

42. Ratliff NB, Myles JL. Rapidly progressive atherosclerosis in aortocoronary saphenous vein grafts. Possible immune-mediated disease. Arch Pathol Lab Med. 1989; 113: 772-776.

43. Hassantash SA, Bikdeli B, Kalantarian S, Sadeghian M, Afshar H. Pathophysiology of aortocoronary saphenous vein bypass graft disease. Asian Cardiovasc Thorac Ann. 2008; 16: 331-336.

44. Christiansen JF, Hartwig D, Bechtel JF, Klüter H, Sievers H, Schönbeck U, et al. Diseased vein grafts express elevated inflammatory cytokine levels compared with atherosclerotic coronary arteries. Ann Thorac Surg. 2004; 77: 1575-1579.

45. Franke A, Lante W, Fackeldey V, Becker HP, Kurig E, Zöller LG, et al. Pro-inflammatory cytokines after different kinds of cardio-thoracic surgical procedures: is what we see what we know? Eur J Cardiothorac Surg. 2005; 28: 569-575.

46. Tuncay A, Yilmaz Y, Baran O, Kelesoglu S. Inflammatory Markers and Saphenous Vein Graft Stenosis: Insights into the Use of Glucose-to-Lymphocyte Ratio as a Prognostic Marker. J Clin Med. 2025; 14: 2634.

47. Chester AH, Borland JA, Taylor PM, Rose ML, Yacoub MH. Vascular adhesion molecules and immunogenicity in blood vessels used as coronary artery bypass grafts. Eur J Cardiothorac Surg. 1996; 10: 676-683.

48. Ward AO, Caputo M, Angelini GD, George SJ, Zakkar M. Activation and inflammation of the venous endothelium in vein graft disease. Atherosclerosis. 2017; 265: 266-274.

49. Reolizo LM, Williams H, Wadey K, Frankow A, Li Z, Gaston K, et al. Inhibition of Intimal Thickening By PRH (Proline-Rich Homeodomain) in Mice. Arterioscler Thromb Vasc Biol. 2023; 43: 456-473.

50. Souza DS, Arbeus M, Botelho Pinheiro B, Filbey D. The no-touch technique of harvesting the saphenous vein for coronary artery bypass grafting surgery. Multimed Man Cardiothorac Surg. 2009; 2009: mmcts.2008.003624.

51. Souza DS, Johansson B, Bojö L, Karlsson R, Geijer H, Filbey D, et al. Harvesting the saphenous vein with surrounding tissue for CABG provides long-term graft patency comparable to the left internal thoracic artery: results of a randomized longitudinal trial. J Thorac Cardiovasc Surg. 2006; 132: 373-378.

52. Samano N, Geijer H, Liden M, Fremes S, Bodin L, Souza D. The no-touch saphenous vein for coronary artery bypass grafting maintains a patency, after 16 years, comparable to the left internal thoracic artery: A randomized trial. J Thorac Cardiovasc Surg. 2015; 150: 880-888.

53. Johansson BL, Souza DS, Bodin L, Filbey D, Loesch A, Geijer H, et al. Slower progression of atherosclerosis in vein grafts harvested with 'no touch' technique compared with conventional harvesting technique in coronary artery bypass grafting: an angiographic and intravascular ultrasound study. Eur J Cardiothorac Surg. 2010; 38: 414-419.

54. Tian M, Wang X, Feng W, Wang H, Liu S, Liu Z, et al. No-touch versus conventional vein in coronary artery bypass grafting: three year follow-up of multicentre randomised PATENCY trial. BMJ. 2025; 389: e082883.

55. Thelin S, Modrau IS, Duvernoy O, Dalén M, Dreifaldt M, Ericsson A, et al. No-touch vein grafts in coronary artery bypass surgery: a registry-based randomized clinical trial. Eur Heart J. 2025; 46: 1720-1729.

56. Mubarak Y, Abdeljawad A. Leg Wound Complications: A Comparison Between Endoscopic and Open Saphenous Vein Harvesting Techniques. Heart Surg Forum. 2021; 24: E604-E610.

57. Saunders PC, Pintucci G, Bizekis CS, Sharony R, Hyman KM, Saponara F, et al. Vein graft arterialization causes differential activation of mitogen-activated protein kinases. J Thorac Cardiovasc Surg. 2004; 127: 1276-1284.

58. Xie P, Shi E, Gu T, Zhang Y, Mao N. Inhibition of intimal hyperplasia of the vein graft with degradable poly lactic-co-glycolic acid vascular external sheaths carrying slow-release bosentan. Eur J Cardiothorac Surg. 2015; 48: 842-849.

59. Dashwood MR, Loesch A. The saphenous vein as a bypass conduit: the potential role of vascular nerves in graft performance. Curr Vasc Pharmacol. 2009; 7: 47-57.

60. Elbassioni AAM, Amr MA, Hassan HS, Eldomiaty HA. Bridging saphenous vein harvesting versus conventional techniques in patients undergoing coronary artery bypass grafting in Suez Canal university hospital. Journal of the Egyptian Society of Cardio-Thoracic Surgery. 2017; 25: 210-216.

61. Krishnamoorthy B, Critchley WR, Glover AT, Nair J, Jones MT, Waterworth PD, et al. A randomized study comparing three groups of vein harvesting methods for coronary artery bypass grafting: endoscopic harvest versus standard bridging and open techniques. Interact Cardiovasc Thorac Surg. 2012; 15: 224-228.

62. Zenati MA, Bhatt DL, Bakaeen FG, Stock EM, Biswas K, Gaziano JM, Kelly RF, et al. REGROUP Trial Investigators. Randomized Trial of Endoscopic or Open Vein-Graft Harvesting for Coronary-Artery Bypass. N Engl J Med. 2019; 380: 132-141.

63. ampath HK, Lee TJH, Cher CE, Liang S, Cheong OO, Kofidis T, et al. A Comprehensive Clinical Outcome Analysis of Endoscopic Vessel Harvesting for Coronary Artery Bypass Surgery. J Clin Med. 2024; 13: 3405.

64. Eckey H, Heseler S, Hiligsmann M. Economic Evaluation of Endoscopic vs Open Vein Harvesting. Ann Thorac Surg. 2023; 115: 1144-1150.

65. Ran J, Liu Y, Li Y, Li Q, Tang Y, Deng L, et al. The effect of endoscopic vein harvesting in coronary artery bypass surgery. J Thorac Dis. 2020; 12: 1991-1998.

66. Morris RJ, Butler MT, Samuels LE. Minimally invasive saphenous vein harvesting. Ann Thorac Surg. 1998; 66: 1026-1028.

67. Li M, Qian M, Kyler K, Xu J. Endothelial-Vascular Smooth Muscle Cells Interactions in Atherosclerosis. Front Cardiovasc Med. 2018; 5: 151.

68. Osgood MJ, Hocking KM, Voskresensky IV, Li FD, Komalavilas P, Cheung-Flynn J, et al. Surgical vein graft preparation promotes cellular dysfunction, oxidative stress, and intimal hyperplasia in human saphenous vein. J Vasc Surg. 2014; 60: 202-211.

69. Wise ES, Brophy CM. The Case for Endothelial Preservation via Pressure-Regulated Distension in the Preparation of Autologous Saphenous Vein Conduits in Cardiac and Peripheral Bypass Operations. Front Surg. 2016; 3: 54.

70. Pimentel MD, Lobo Filho JG, Lobo Filho HG, de Castro Miguel E, Pinheiro Paiva SK, et al. Effect of preservation solution and distension pressure on saphenous vein's endothelium. Interact Cardiovasc Thorac Surg. 2022; 35: ivac124.

71. Khaleel MS, Dorheim TA, Duryee MJ, Durbin HE Jr, Bussey WD, Garvin RP, et al. High-pressure distention of the saphenous vein during preparation results in increased markers of inflammation: a potential mechanism for graft failure. Ann Thorac Surg. 2012; 93: 552-558.

72. Li FD, Eagle S, Brophy C, Hocking KM, Osgood M, Komalavilas P, et al. Pressure control during preparation of saphenous veins. JAMA Surg. 2014; 149: 655-662.

73. Sandner S, Antoniades C, Caliskan E, Czerny M, Dayan V, Fremes SE, et al. Intra-operative and post-operative management of conduits for coronary artery bypass grafting: a clinical consensus statement of the European Society of Cardiology Working Group on Cardiovascular Surgery and the European Association for Cardio-Thoracic Surgery Coronary Task Force. Eur J Cardiothorac Surg. 2024; 66: ezae400.

74. Ladak SS, McQueen LW, Layton GR, Aujla H, Adebayo A, Zakkar M. The Role of Endothelial Cells in the Onset, Development and Modulation of Vein Graft Disease. Cells. 2022; 11: 3066.

75. Wise ES, Hocking KM, Luo W, Feldman DL, Song J, Komalavilas P, et al. Traditional graft preparation decreases physiologic responses, diminishes viscoelasticity, and reduces cellular viability of the conduit: A porcine saphenous vein model. Vasc Med. 2016; 21: 413-421.

76. Cavallari N, Abebe W, Mingoli A, Sapienza P, Hunter WJ 3rd, Agrawal DK, et al. Short-term preservation of autogenous vein grafts: effectiveness of University of Wisconsin solution. Surgery. 1997; 121: 64-71.

77. Layton GR, Ladak SS, Abbasciano R, McQueen LW, George SJ, Murphy GJ, et al. The Role of Preservation Solutions upon Saphenous Vein Endothelial Integrity and Function: Systematic Review and UK Practice Survey. Cells. 2023; 12: 815.

78. Jackson ML, Bond AR, George SJ. Mechanobiology of the endothelium in vascular health and disease: in vitro shear stress models. Cardiovasc Drugs Ther. 2023; 37: 997-1010.

79. Acuna A, Berman AG, Damen FW, Meyers BA, Adelsperger AR, Bayer KC, et al. Computational Fluid Dynamics of Vascular Disease in Animal Models. J Biomech Eng. 2018; 140: 0808011–08080114.

80. indberger U, Bartholovitsch A, Plasenzotti R, Korak KJ, Heinze G. Whole blood viscosity, plasma viscosity and erythrocyte aggregation in nine mammalian species: reference values and comparison of data. Exp Physiol. 2003; 88: 431-440.

81. Garcia JR, Sanyal A, Fatemifar F, Mottahedi M, Han HC. Twist buckling of veins under torsional loading. J Biomech. 2017; 58: 123-130.

82. Lee YU, Naito Y, Kurobe H, Breuer CK, Humphrey JD. Biaxial mechanical properties of the inferior vena cava in C57BL/6 and CB-17 SCID/bg mice. J Biomech. 2013; 46: 2277-2282.

83. Parma L, Peters HAB, Baganha F, Sluimer JC, de Vries MR, Quax PHA. Prolonged Hyperoxygenation Treatment Improves Vein Graft Patency and Decreases Macrophage Content in Atherosclerotic Lesions in ApoE3*Leiden Mice. Cells. 2020; 9: 336.

84. Mulligan-Kehoe MJ, Simons M. Vasa vasorum in normal and diseased arteries. Circulation. 2014; 129: 2557-6256.

85. Payne H, Brill A. Stenosis of the Inferior Vena Cava: A Murine Model of Deep Vein Thrombosis. J Vis Exp. 2017; 130: 56697.

86. Yamada T, Itoh T, Nakano S, Tokunaga O. Time-dependent thickening of the intima in aortocoronary saphenous vein grafts: clinicopathological analysis of 24 patients. Heart Vessels. 1995; 10: 41-45.

87. Murphy GJ, Angelini GD. Insights into the pathogenesis of vein graft disease: lessons from intravascular ultrasound. Cardiovasc Ultrasound. 2004; 2: 8.

88. Zhang L, Hagen PO, Kisslo J, Peppel K, Freedman NJ. Neointimal hyperplasia rapidly reaches steady state in a novel murine vein graft model. J Vasc Surg. 2002; 36: 824-832.

89. Dilley RJ, McGeachie JK, Prendergast FJ. A morphometric study of vein graft intimal hyperplasia. Plast Reconstr Surg. 1986; 77: 451-454.

90. Dilley RJ, McGeachie JK, Prendergast FJ. A morphometric study of vein graft intimal hyperplasia. Plast Reconstr Surg. 1986; 77: 451-454.

91. Angelini GD, Bryan AJ, Williams HM, Soyombo AA, Williams A, Tovey J, et al. Time-course of medial and intimal thickening in pig venous arterial grafts: relationship to endothelial injury and cholesterol accumulation. J Thorac Cardiovasc Surg. 1992; 103: 1093-1103.

92. Ono M, Kageyama S, O'Leary N, El-Kurdi MS, Reinöhl J, Solien E, et al. 1-Year Patency of Biorestorative Polymeric Coronary Artery Bypass Grafts in an Ovine Model. JACC: Basic to Translational Science. 2023; 8: 19-34.

93. Barra JA, Volant A, Leroy JP, Braesco J, Airiau J, Boschat J, et al. Constrictive perivenous mesh prosthesis for preservation of vein integrity. Experimental results and application for coronary bypass grafting. J Thorac Cardiovasc Surg. 1986; 92: 330-336.

94. Chaux A, Ruan XM, Fishbein MC, Sandhu M, Matloff JM. Influence of vein valves in the development of arteriosclerosis in venoarterial grafts in the rabbit. J Thorac Cardiovasc Surg. 1995; 110: 1381-1389.

95. Węglarz P, Bochenek T, Bajor G, Mizia-Stec K, Krejca M, Trusz-Gluza M. Early Stage of Atherosclerosis in Aortocoronary Saphenous Vein Grafts: Intravascular Ultrasound Study. Braz J Cardiovasc Surg. 2019; 34: 560-564.

96. Bikdeli B, Hassantash SA, Pourabdollah M, Kalantarian S, Sadeghian M, Afshar H, et al. Histopathologic insight into saphenous vein bypass graft disease. Cardiology. 2012; 123: 208-215.

97. George SJ, Wan S, Hu J, MacDonald R, Johnson JL, Baker AH. Sustained reduction of vein graft neointima formation by ex vivo TIMP-3 gene therapy. Circulation. 2011; 124: S135-S142.

98. Francis SE, Hunter S, Holt CM, Gadsdon PA, Rogers S, Duff GW, et al. Release of platelet-derived growth factor activity from pig venous arterial grafts. J Thorac Cardiovasc Surg. 1994; 108: 540-548.

99. Granada JF, Kaluza GL, Wilensky RL, Biedermann BC, Schwartz RS, Falk E. Porcine models of coronary atherosclerosis and vulnerable plaque for imaging and interventional research. EuroIntervention. 2009; 5: 140-148.

100. Thim T, Hagensen MK, Hørlyck A, Drouet L, Paaske WP, Bøtker HE, Falk E. Oversized vein grafts develop advanced atherosclerosis in hypercholesterolemic minipigs. BMC Cardiovasc Disord. 2012; 12: 24.

101. Simon F, Larena-Avellaneda A, Wipper S. Experimental Atherosclerosis Research on Large and Small Animal Models in Vascular Surgery. J Vasc Res. 2022; 59: 221-228.

102. Verkest KR. Is the metabolic syndrome a useful clinical concept in dogs? A review of the evidence. Vet J. 2014; 199: 24-30.

103. Breslow JL. Mouse models of atherosclerosis. Science. 1996; 272: 685-688.

104. Ritskes-Hoitinga J, Beynen AC. Atherosclerosis in the rat. Artery. 1988; 16: 25-50.

105. Ebert MLA, Schmidt VF, Pfaff L, von Thaden A, Kimm MA, Wildgruber M. Animal Models of Neointimal Hyperplasia and Restenosis: Species-Specific Differences and Implications for Translational Research. JACC Basic Transl Sci. 2021; 6: 900-917.

106. Masroor M, Ahmad A, Wang Y, Dong N. Assessment of the Graft Quality and Patency during and after Coronary Artery Bypass Grafting. Diagnostics (Basel). 2023; 13: 1891.

107. Lee YU, Yi T, Tara S, Lee AY, Hibino N, Shinoka T, et al. Implantation of inferior vena cava interposition graft in mouse model. J Vis Exp. 2014; 88: 51632.

108. Chan AHP, Tan RP, Michael PL, Lee BSL, Vanags LZ, Ng MKC, et al. Evaluation of synthetic vascular grafts in a mouse carotid grafting model. PLOS ONE. 2017; 12: e0174773.

109. Maxfield MW, Stacy MR, Kurobe H, Tara S, Yi T, Cleary MA, et al. Novel application and serial evaluation of tissue-engineered portal vein grafts in a murine model. Regen Med. 2017; 12: 929-938.

110. Wang D, Tediashvili G, Pecha S, Reichenspurner H, Deuse T, Schrepfer S. Vein Interposition Model: A Suitable Model to Study Bypass Graft Patency. J Vis Exp. 2017; 119: 54839.

111. Fang Q, Gu T, Fan J, Zhang Y, Wang Y, Zhao Y, et al. Evaluation of a hybrid small caliber vascular graft in a rabbit model. J Thorac Cardiovasc Surg. 2020; 159: 461-473.

112. Bond A, Bruno V, Sulaiman N, Johnson J, George S, Ascione R. In-Situ Vascular Regeneration by Host Cells of Acellular Human Saphenous Vein Implanted in Porcine Carotid Artery. Int J Mol Sci. 2025; 26: 4718.

113. Ben-Gal Y, Taggart DP, Williams MR, Orion E, Uretzky G, Shofti R, et al. Expandable external support device to improve Saphenous Vein Graft Patency after CABG. J Cardiothorac Surg. 2013; 8: 122.

114. Sato Y, Kutnya M, Abebe B, El Kurdi MS, Cox M, Bianco RW, et al.

Histological assessment of a novel restorative coronary artery bypass graft in a chronic ovine model. Front Bioeng Biotechnol. 2025; 13: 1488794.

115. Li FD, Sexton KW, Hocking KM, Osgood MJ, Eagle S, Cheung-Flynn J, et al. Intimal thickness associated with endothelial dysfunction in human vein grafts. J Surg Res. 2013; 180: e55-e62.

116. Marin ML, Veith FJ, Panetta TF, Gordon RE, Wengerter KR, Suggs WD, et al. Saphenous vein biopsy: a predictor of vein graft failure. J Vasc Surg. 1993; 18: 407-414.

117. Wilson YG, Davies AH, Southgate K, Currie IC, Sheffield E, Baird RN, et al. Vein quality influences neointimal hyperplasia in an organ culture model of human saphenous vein. Eur J Vasc Endovasc Surg. 1997; 13: 557-562.

118. Milani-Nejad N, Janssen PM. Small and large animal models in cardiac contraction research: advantages and disadvantages. Pharmacol Ther. 2014; 141: 235-249.

119. Yu P, Nguyen BT, Tao M, Campagna C, Ozaki CK. Rationale and practical techniques for mouse models of early vein graft adaptations. J Vasc Surg. 2010; 52: 444-452.

120. Hecker G, Martineau K, Scheskie M, Hammerslough R, Feuerbacher EN. Effects of single- or pair-housing on the welfare of shelter dogs: Behavioral and physiological indicators. PLoS One. 2024; 19: e0301137.

121. BVAAWF/FRAME/RSPCA/UFAW Joint Working Group on Refinement. Refining dog husbandry and care. Eighth report of BVAAWF/FRAME/RSPCA/UFAW Joint Working Group on Refinement. Lab Anim. 2004; 38: 1-94.

122. Hocum Stone L, Wright C, Chappuis E, Messer M, Ward HB, McFalls EO, et al. Surgical Swine Model of Chronic Cardiac Ischemia Treated by Off-Pump Coronary Artery Bypass Graft Surgery. J Vis Exp. 2018; 133: 57229.

123. Hubert MB, Salazkin I, Desjardins J, Blaise G. Cardiopulmonary bypass surgery in swine: a research model. J Exp Animal Sci. 2003; 42: 135-149.

124. Vural AH, Yalcinkaya S, Türk T, Yümün G, Gül N, Yalcinkaya U, et al. Intracoronary shunt versus bulldog clamp in off-pump bypass surgery. Endothelial trauma: shunt versus clamp. J Surg Res. 2008; 150: 261-265.

125. Falk V, Diegeler A, Walther T, Löscher N, Vogel B, Ulmann C, et al. Endoscopic coronary artery bypass grafting on the beating heart using a computer enhanced telemanipulation system. Heart Surg Forum. 1999; 2: 199-205.

126. Radwan MM, Siddique A, Thankam FG, Kouassi KT, Agrawal DK. Translational model of vein graft failure following coronary artery bypass graft in atherosclerotic microswine. Gen Thorac Cardiovasc Surg. 2022; 70: 445-454.

127. Otaki M, Ogawa T, Inoue T, Oku H. Off-pump coronary bypass grafting to double vessel disease with the pharmacological assist of esmolol. An experimental study. J Cardiovasc Surg (Torino). 2002; 43: 307-311.

128. Fashina O, Abbasciano RG, McQueen LW, Ladak S, George SJ, Suleiman S, et al. Large animal model of vein grafts intimal hyperplasia: A systematic review. Perfusion. 2023; 38: 894-930.

129. Yu P, Nguyen BT, Tao M, Bai Y, Ozaki CK. Mouse vein graft hemodynamic manipulations to enhance experimental utility. Am J Pathol. 2011; 178: 2910-2919.

130. Van Loo PLP, Janssens MRE. Why All Healthy Laboratory Animals Should Be Rehomed, No Matter How Small. Animals (Basel). 2023; 13: 2727.

131. Kol A, Arzi B, Athanasiou KA, Farmer DL, Nolta JA, Rebhun RB, et al. Companion animals: Translational scientist's new best friends. Sci Transl Med. 2015; 7: 308ps21.

132. Carvalho C, Gaspar A, Knight A, Vicente L. Ethical and Scientific Pitfalls Concerning Laboratory Research with Non-Human Primates, and Possible Solutions. Animals (Basel). 2018; 9: 12.

133. Moodley L, Franz T, Human P, Wolf MF, Bezuidenhout D, Scherman J, et al. Protective constriction of coronary vein grafts with knitted nitinol. Eur J Cardiothorac Surg. 2013; 44: 64-71.

134. Zilla P, Moodley L, Scherman J, Krynauw H, Kortsmit J, Human P, et al. Remodeling leads to distinctly more intimal hyperplasia in coronary than in infrainguinal vein grafts. J Vasc Surg. 2012; 55: 1734-1741.

135. Tsang HG, Rashdan NA, Whitelaw CB, Corcoran BM, Summers KM, MacRae VE. Large animal models of cardiovascular disease. Cell Biochem Funct. 2016; 34: 113-132.

136. Matter CM, Ma L, von Lukowicz T, Meier P, Lohmann C, Zhang D, et al. Increased balloon-induced inflammation, proliferation, and neointima formation in apolipoprotein E (ApoE) knockout mice. Stroke. 2006; 37: 2625-2632.

137. Tediashvili G, Wang D, Reichenspurner H, Deuse T, Schrepfer S. Balloon-based Injury to Induce Myointimal Hyperplasia in the Mouse Abdominal Aorta. J Vis Exp. 2018; 132: 56477.

138. Zhang W, Trebak M. Vascular balloon injury and intraluminal administration in rat carotid artery. J Vis Exp. 2014; 94: 52045.

139. Lindner V, Fingerle J, Reidy MA. Mouse model of arterial injury. Circ Res. 1993; 73: 792-796.

140. Hui DY. Intimal hyperplasia in murine models. Curr Drug Targets. 2008; 9: 251-260.

141. Curaj A, Zhoujun W, Staudt M, Liehn EA. Induction of Accelerated Atherosclerosis in Mice: The "Wire-Injury" Model. J Vis Exp. 2020; 162.

142. Tan RP, Hung JC, Chan AHP, Grant AJ, Moore MJ, Lam YT, et al. Highly reproducible rat arterial injury model of neointimal hyperplasia. PLoS One. 2023; 18: e0290342.

143. Warwick T, Buchmann GK, Pflüger-Müller B, Spaeth M, Schürmann C, Abplanalp W, et al. Acute injury to the mouse carotid artery provokes a distinct healing response. Front Physiol. 2023; 14: 1125864.

144. Williams H, Brown BA, Johnson JL, George SJ. Use of Mouse Carotid Artery Ligation Model of Intimal Thickening to Probe Vascular Smooth Muscle Cell Remodeling and Function in Atherosclerosis. Methods Mol Biol. 2022; 2419: 537-560.

145. Kuhlmann MT, Cuhlmann S, Hoppe I, Krams R, Evans PC, Strijkers GJ, et al. Implantation of a carotid cuff for triggering shear-stress induced atherosclerosis in mice. J Vis Exp. 2012; 59: 3308.

146. Korshunov VA, Berk BC. Flow-induced vascular remodeling in the mouse: a model for carotid intima-media thickening. Arterioscler Thromb Vasc Biol. 2003; 23: 2185-2191.

147. Kumar A, Lindner V. Remodeling with neointima formation in the mouse carotid artery after cessation of blood flow. Arterioscler Thromb Vasc Biol. 1997; 17: 2238-2244.

148. Zou Y, Dietrich H, Hu Y, Metzler B, Wick G, Xu Q. Mouse model of venous bypass graft arteriosclerosis. Am J Pathol. 1998; 153: 1301-1310.

149. Cooley BC. Model of murine interpositional vein grafting. Microsurgery. 2005; 25: 209-212.

150. Salzberg SP, Filsoufi F, Anyanwu A, von Harbou K, Karlof E, Carpentier A, et al. Increased neointimal formation after surgical

vein grafting in a murine model of type 2 diabetes. Circulation. 2006; 114: I302-I307.

151. Van Doormaal MA, Kazakidi A, Wylezinska M, Hunt A, Tremoleda JL, Protti A, et al. Haemodynamics in the mouse aortic arch computed from MRI-derived velocities at the aortic root. J R Soc Interface. 2012; 9: 2834-2844.

152. Prim DA, Mohamed MA, Lane BA, Poblete K, Wierzbicki MA, Lessner SM, et al. Comparative mechanics of diverse mammalian carotid arteries. PLoS One. 2018; 13: e0202123.

153. Holt AW, Tulis DA. Experimental Rat and Mouse Carotid Artery Surgery: Injury & Remodeling Studies. ISRN Minim Invasive Surg. 2013; 2013: 167407.

154. Zhang-James Y, Middleton FA, Faraone SV. Genetic architecture of Wistar-Kyoto rat and spontaneously hypertensive rat substrains from different sources. Physiol Genomics. 2013; 45: 528-538.

155. Perez-Leighton CE, Lockridge AD, Teske JA, Alejandro EU, Kotz CM. Chapter 27 - Rat Models of Obesity, Metabolic Syndrome, and Diabetes. In: Suckow MA, Hankenson FC, Wilson RP, Foley PL, editors. The Laboratory Rat (Third Edition): Academic Press. 2020: 987-1002.

156. Lee JG, Ha CH, Yoon B, Cheong SA, Kim G, Lee DJ, et al. Knockout rat models mimicking human atherosclerosis created by Cpf1-mediated gene targeting. Sci Rep. 2019; 9: 2628.

157. Wei S, Zhang Y, Su L, He K, Wang Q, Zhang Y, et al. Apolipoprotein E-deficient rats develop atherosclerotic plaques in partially ligated carotid arteries. Atherosclerosis. 2015; 243: 589-592.

158. Tulis DA. Rat carotid artery balloon injury model. Methods Mol Med. 2007; 139: 1-30.

159. Buglak NE, Bahnson ESM. A Rat Carotid Artery Pressure-Controlled Segmental Balloon Injury with Periadventitial Therapeutic Application. J Vis Exp. 2020; 161: 10.

160. Petrasheskaya N, Tae HJ, Ahmet I, Talan MI, Lakatta EG, Lin L. A Rat Carotid Balloon Injury Model to Test Anti-vascular Remodeling Therapeutics. J Vis Exp. 2016; 115: 53777.

161. Schleimer K, Grommes J, Greiner A, Jalaie H, Kalder J, Langer S, et al. Training a sophisticated microsurgical technique: interposition of external jugular vein graft in the common carotid artery in rats. J Vis Exp. 2012; 69: 4124.

162. Liu SQ. Prevention of focal intimal hyperplasia in rat vein grafts by using a tissue engineering approach. Atherosclerosis. 1998; 140: 365-377.

163. Romero G, Daou J, Dornbrand-Lo M, Barry J, Ballestín A, Akelina Y. Interpositional Vein Graft Using Rat Femoral Vessels. In: Akelina Y, Ballestín A, editors. Microsurgery 101: Tips and Tricks for Microvascular and Peripheral Nerve Repair Techniques. Cham: Springer Nature Switzerland. 2024: 77-83.

164. Fouquet O, Blossier JD, Dang Van S, Robert P, Barbelivien A, Pinaud F, et al. Do storage solutions protect endothelial function of arterialized vein graft in an experimental rat model? J Cardiothorac Surg. 2020; 15: 34.

165. Bahçivan M, Elmali M, Kolbakir F, Göl K. The effect of competitive flow on both the flow and the velocity in venous grafts in a bypass model. Anadolu Kardiyol Derg. 2009; 9: 123-127.

166. Curi MA, Skelly CL, Meyerson SL, Baldwin ZK, Balasubramanian V, Advani SJ, et al. Sustained inhibition of experimental neointimal hyperplasia with a genetically modified herpes simplex virus. J Vasc Surg. 2003; 37: 1294-1300.

167. Li R, Lan B, Zhu T, Yang Y, Wang M, Ma C, et al. Establishment of an animal model of vascular restenosis with bilateral carotid artery grafting. Med Sci Monit. 2014; 20: 2846-2854.

168. He Y, Fernandez CM, Jiang Z, Tao M, O'Malley KA, Berceli SA. Flow reversal promotes intimal thickening in vein grafts. J Vasc Surg. 2014; 60: 471.e1-478.e1.

169. Fernandez C, Jiang Z, Tao M, He Y, Ozaki C, Tran-Son-Tay R, et al. PL10. Accelerated Intimal Hyperplasia Distal to a Focal Stenosis: A New Paradigm in Vein Graft Remodeling. J Surg Res. 2009; 151: 278-279.

170. Berceli SA, Jiang Z, Klingman NV, Pfahnl CL, Abouhamze ZS, Frase CD, et al. Differential expression and activity of matrix metalloproteinases during flow-modulated vein graft remodeling. J Vasc Surg. 2004; 39: 1084-1090.

171. Yucel S, Bahcivan M, Gol MK, Erenler BH, Kolbakir F, Keceligil HT. Reduced intimal hyperplasia in rabbits via medical therapy after carotid venous bypass. Tex Heart Inst J. 2009; 36: 387-392.

172. Jiang Z, Wu L, Miller BL, Goldman DR, Fernandez CM, Abouhamze ZS, et al. A novel vein graft model: adaptation to differential flow environments. Am J Physiol Heart Circ Physiol. 2004; 286: H240-H245.

173. Meyerson SL, Skelly CL, Curi MA, Shakur UM, Vosicky JE, Glagov S, et al. The effects of extremely low shear stress on cellular proliferation and neointimal thickening in the failing bypass graft. J Vasc Surg. 2001; 34: 90-97.

174. Jiang Z, Berceli SA, Pfahnl CL, Wu L, Goldman D, Tao M, et al. Wall shear modulation of cytokines in early vein grafts. J Vasc Surg. 2004; 40: 345-350.

175. Kurazumi H, Suzuki R, Nawata R, Yokoyama T, Tsubone S, Mikamo A, et al. Impact of the no-touch harvesting technique on the vessel diameter of saphenous vein grafts for coronary artery bypass grafting. JTCVS Tech. 2022; 15: 87-94.

176. Human P, Franz T, Scherman J, Moodley L, Zilla P. Dimensional analysis of human saphenous vein grafts: Implications for external mesh support. J Thorac Cardiovasc Surg. 2009; 137: 1101-1108.

177. Liu Z, Hou G, Wang X, Li J. WCN23-0550 A MODIFIED TECHNIQUE FOR ARTERIOVENOUS FISTULA IN RABBITS. Kidney Int Rep. 2023; 8: S323.

178. Bahcivan M, Yucel S, Kefeli M, Kamil gol M, Can B, Tahsin keceligil H. Inhibition of vein graft intimal hyperplasia by periadventitial application of hyaluronic acid–carboxymethyl cellulose: An experimental study. Scand Cardiovasc J. 2008; 42: 161-165.

179. Alp NJ, West NE, Arnold N, Gunn J, Banning AP, Channon KM. Increased intimal hyperplasia in experimental vein graft stenting compared to arterial stenting: comparisons in a new rabbit model of stent injury. Cardiovasc Res. 2002; 56: 164-172.

180. Wu B, Werlin EC, Chen M, Mottola G, Chatterjee A, Lance KD, et al. Perivascular delivery of resolvin D1 inhibits neointimal hyperplasia in a rabbit vein graft model. J Vasc Surg. 2018; 68: 188S.e4-200S.e4.

181. Brauner R, Laks H, Drinkwater DC, Chaudhuri G, Shvarts O, Drake T, et al. Controlled periadventitial administration of verapamil inhibits neointimal smooth muscle cell proliferation and ameliorates vasomotor abnormalities in experimental vein bypass grafts. J Thorac Cardiovasc Surg. 1997; 114: 53-63.

182. Dai L, Yu W, Yu Y. New strategy of using double-network hydrogel extravascular stent for preventing venous graft restenosis after coronary artery bypass grafting. Perfusion. 2023; 38: 1240-1249.

183. Skalský I, Filová E, Szárszoi O, Pařízek M, Lytvynets A, Malušková J, et al. A periadventitial sirolimus-releasing mesh decreased intimal hyperplasia in a rabbit model. Physiol Res. 2011; 60: 585-588.

184. Finn AV, Gold HK, Tang A, Weber DK, Wight TN, Clermont A, et al. A novel rat model of carotid artery stenting for the understanding of restenosis in metabolic diseases. J Vasc Res. 2002; 39: 414-425.

185. Dai C, Zhou Y, Zhang B, Ge J. Bletilla striata Polysaccharide Prevents Restenosis of Vein Graft Through Inhibiting Cell Proliferation in Rat Model. Cell Transplant. 2020; 29: 963689720969173.

186. Haraguchi T, Okada K, Tabata Y, Maniwa Y, Hayashi Y, Okita Y. Controlled release of basic fibroblast growth factor from gelatin hydrogel sheet improves structural and physiological properties of vein graft in rat. Arterioscler Thromb Vasc Biol. 2007; 27: 548-555.

187. Yang Q, Lei D, Huang S, Yang Y, Yang Y, Ye X, et al. Effects of the different-sized external stents on vein graft intimal hyperplasia and inflammation. Ann Transl Med. 2020; 8: 102.

188. Wong AP, Nili N, Jackson ZS, Qiang B, Leong-Poi H, Jaffe R, et al. Expansive remodeling in venous bypass grafts: Novel implications for vein graft disease. Atherosclerosis. 2008; 196: 580-589.

189. Bi L, Wacker BK, Dichek DA. A Rabbit Model of Durable Transgene Expression in Jugular Vein to Common Carotid Artery Interposition Grafts. J Vis Exp. 2018; 139: 57231.

190. Lozano WM, Arias-Mutis OJ, Calvo CJ, Chorro FJ, Zarzoso M. Diet-Induced Rabbit Models for the Study of Metabolic Syndrome. Animals. 2019; 9: 463.

191. Niimi M, Chen Y, Yan H, Wang Y, Koike T, Fan J. Hyperlipidemic Rabbit Models for Anti-Atherosclerotic Drug Development. App Sci. 2020; 10: 8681.

192. Ehsan A, Mann MJ, Dell'Acqua G, Dzau VJ. Long-term stabilization of vein graft wall architecture and prolonged resistance to experimental atherosclerosis after E2F decoy oligonucleotide gene therapy. J Thorac Cardiovasc Surg. 2001; 121: 714-722.

193. Zwolak RM, Kirkman TR, Clowes AW. Atherosclerosis in rabbit vein grafts. Arteriosclerosis. 1989; 9: 374-379.

194. Bi L, Wacker BK, Komandur K, Sanford N, Dichek DA. Apolipoprotein A-I vascular gene therapy reduces vein-graft atherosclerosis. Mol Ther Methods Clin Dev. 2023; 30: 558-572.

195. Ogawa T, Sugidachi A, Asai F, Koike H. Reduced platelet serotonin content in rabbits with dietary hypercholesterolemia. Blood Coagul Fibrinolysis. 2000; 11: 313-319.

196. Sato T, Maegawa H, Kometani M, Fujii T. Collagen-induced calcium influx is enhanced in platelets from hypercholesterolemic rabbits. Thromb Res. 1985; 40: 59-68.

197. Latta EK, Packham MA, Gross PL, Rand ML. Enhanced collagen-induced responses of platelets from rabbits with diet-induced hypercholesterolemia are due to increased sensitivity to TxA2. Response inhibition by chronic ethanol administration in hypercholesterolemia is due to reduced TxA2 formation. Arterioscler Thromb. 1994; 14: 1379-1385.

198. Rocha EAV. Fifty Years of Coronary Artery Bypass Graft Surgery. Braz J Cardiovasc Surg. 2017; 32: Ii-Iiii.

199. Flameng W, Schwarz F, Schaper W. Coronary collaterals in the canine heart: development and functional significance. Am Heart J. 1979; 97: 70-77.

200. Lelovas PP, Kostomitsopoulos NG, Xanthos TT. A comparative anatomic and physiologic overview of the porcine heart. J Am Assoc Lab Anim Sci. 2014; 53: 432-438.

201. Mori N, Okada Y, Tsuchida N, Hatano Y, Habara M, Ishikawa S, et al. Preliminary Analysis of Modified Low-Density Lipoproteins in the Serum of Healthy and Obese Dogs and Cats. Front Vet Sci. 2015; 2: 34.

202. Popov AF, Dorge H, Hinz J, Schmitto JD, Stojanovic T, Seipelt R, et al. Accelerated intimal hyperplasia in aortocoronary internal mammary vein grafts in minipigs. J Cardiothorac Surg. 2008; 3: 20.

203. Steger C BJ, Nagiller J, Wiedemann D, Sterlacci W, Laufer G, Schachner T. Neointimal hyperplasia in a porcine model of vein graft disease: comparison between organ culture and coronary artery bypass grafting. Eur Surg. 2011; 43: 174-180.

204. Angelini GD, Bryan AJ, Williams HM, Morgan R, Newby AC. Distention promotes platelet and leukocyte adhesion and reduces short-term patency in pig arteriovenous bypass grafts. J Thorac Cardiovasc Surg. 1990; 99: 433-439.

205. George SJ, Lloyd CT, Angelini GD, Newby AC, Baker AH. Inhibition of Late Vein Graft Neointima Formation in Human and Porcine Models by Adenovirus-Mediated Overexpression of Tissue Inhibitor of Metalloproteinase-3. Circulation. 2000; 101: 296-304.

206. De Nisco G, Chiastra C, Hartman EMJ, Hoogendoorn A, Daemen J, Calò K, et al. Comparison of Swine and Human Computational Hemodynamics Models for the Study of Coronary Atherosclerosis. Front Bioeng Biotechnol. 2021; 9: 731924.

207. Angelini GD, Lloyd C, Bush R, Johnson J, Newby AC. An external, oversized, porous polyester stent reduces vein graft neointima formation, cholesterol concentration, and vascular cell adhesion molecule 1 expression in cholesterol-fed pigs. J Thorac Cardiovasc Surg. 2002; 124: 950-956.

208. Thim T, Hagensen MK, Drouet L, Bal Dit Sollier C, Bonneau M, Granada JF, et al. Familial hypercholesterolaemic downsized pig with human-like coronary atherosclerosis: a model for preclinical studies. EuroIntervention. 2010; 6: 261-268.

209. Rydhmer L, Zamaratskaia G, Andersson HK, Algers B, Guillemet R, Lundström K. Aggressive and sexual behaviour of growing and finishing pigs reared in groups, without castration. Acta Agriculturae Scandinavica, Section A — Animal Sci. 2006; 56: 109-119.

210. Morgan L, Itin-Shwartz B, Koren L, Meyer JS, Matas D, Younis A, et al. Physiological and economic benefits of abandoning invasive surgical procedures and enhancing animal welfare in swine production. Sci Rep. 2019; 9: 16093.

211. Krejca M, Skarysz J, Szmagala P, Plewka D, Nowaczyk G, Plewka A, et al. A new outside stent – does it prevent vein graft intimal proliferation? Eur J Cardio-Thoracic Surg. 2002; 22: 898-903.

212. Krejca M, Plewka A, Szmagala P, Plewka D, Nowaczyk G, Skarysz J, et al. Outside stenting of the vein graft decreases VEGF-A expression and induces significant down-regulation of VEGFR-1 in the intimal and medial layers after the re-endothelialization period. Med Sci Monit. 2010; 16: Br89-Br96.

213. Klesius AA, Konerding MA, Knez P, Dzemali O, Schmitz-Rixen T, Ackermann H, et al. External Stenting with a New Polyester Mesh Reduces Neointimal Hyperplasia of Vein Grafts in a Sheep Model. Int J Artif Organs. 2007; 30: 930-938.

214. Abbasi K, Shalileh K, Anvari MS, Rabbani S, Mahdanian A, Ahmadi SH, et al. Perivascular nitric oxide delivery to saphenous vein grafts prevents graft stenosis after coronary artery bypass grafting: a novel sheep model. Cardiology. 2011; 118: 8-15.

215. Bar-El Y, Tio FO, Shofti R. An automatic sutureless coronary anastomotic device: initial results of an animal study. Heart Surg Forum. 2003; 6: 369-374.

216. Shofti R, Zaretzki A, Cohen E, Engel A, Bar-El Y. The sheep as a model for coronary artery bypass surgery. Laboratory Animals. 2004; 38: 149-157.

217. El-Kurdi MS, Soletti L, Nieponice A, Abuin G, Gross C, Rousselle S, et

al. Ovine femoral artery bypass grafting using saphenous vein: a new model. J Surg Res. 2015; 193: 458-469.

218. DiVincenti L Jr, Westcott R, Lee C. Sheep (Ovis aries) as a model for cardiovascular surgery and management before, during, and after cardiopulmonary bypass. J Am Assoc Lab Anim Sci. 2014; 53: 439-448.

219. Boumzebra D, Solem JO, Nakeeb S, Halees ZA. The Sheep as a Model for Coronary Artery Surgery Experiments on Beating Heart. J Tehran Univ Heart Cent. 2006; 1: 11-15.

220. Schleimer K, Jalaie H, Afify M, Woitok A, Barbati ME, Hoeft K, et al. Sheep models for evaluation of novel patch and prosthesis material in vascular surgery: tips and tricks to avoid possible pitfalls. Acta Vet Scand. 2018; 60: 42.

221. Ramachandra AB, Wang H, Wnorowski A, Schwarz EL, Pickering J, Heiler JC, et al. Biodegradable external wrapping promotes favorable adaptation in an ovine vein graft model. Acta Biomater. 2022; 151: 414-425.

222. Moolchandani A, Sareen M, Vaishnav J. Influence of restraint and isolation stress on plasma cortisol in male Karakul sheep. Vet Arh. 2008; 78: 357-362.

223. Soyombo AA, Angelini GD, Bryan AJ, Jasani B, Newby AC. Intimal proliferation in an organ culture of human saphenous vein. Am J Pathol. 1990; 137: 1401-1410.

224. Porter KE, Varty K, Jones L, Bell PR, London NJ. Human saphenous vein organ culture: a useful model of intimal hyperplasia? Eur J Vasc Endovasc Surg. 1996; 11: 48-58.

225. Miyakawa AA, Dallan LA, Lacchini S, Borin TF, Krieger JE. Human saphenous vein organ culture under controlled hemodynamic conditions. Clinics (Sao Paulo). 2008; 63: 683-688.

226. Piola M, Prandi F, Bono N, Soncini M, Penza E, Agrifoglio M, et al. A compact and automated ex vivo vessel culture system for the pulsatile pressure conditioning of human saphenous veins. J Tissue Eng Regen Med. 2016; 10: E204-E215.

227. Dummler S, Eichhorn S, Tesche C, Schreiber U, Voss B, Deutsch MA, et al. Pulsatile ex vivo perfusion of human saphenous vein grafts under controlled pressure conditions increases MMP-2 expression. Biomed Eng Online. 2011; 10: 62.

228. Evans CE, Iruela-Arispe ML, Zhao YY. Mechanisms of Endothelial Regeneration and Vascular Repair and Their Application to Regenerative Medicine. Am J Pathol. 2021; 191: 52-65.

229. Tesfamariam B. Endothelial Repair and Regeneration Following Intimal Injury. J Cardiovasc Transl Res. 2016; 9: 91-101.