

Case Report

Pulmonary Hypertension in Trisomy 18: Role of Pre-Operative Cardiac Catheterization in Select Cases

Abhishek Chakraborty¹, D. Byron Holt², Karen Wright² and Hitesh Agrawal^{2*}

¹Le Bonheur Children's Hospital, The University of Tennessee Health Sciences Center, USA

²Pediatric and Congenital Cardiology Associates, The University of Texas at Austin Dell Medical School, USA

*Corresponding author

Hitesh Agrawal, Pediatric Interventional Cardiology, Pediatric and Congenital Cardiology Associates, 1110 E. 32nd Street Austin, TX 78722, USA, Fax: 5123208398; Tel: 5123208388; Email: hiteshdos@hotmail.com

Submitted: 05 November 2020

Accepted: 23 November 2020

Published: 25 November 2020

ISSN: 2378-9344

Copyright

© 2020 Chakraborty A, et al.

OPEN ACCESS

Abstract

Cardiac catheterization was done in a patient with Trisomy 18 and atrio-ventricular septal defect, large inlet VSD, and poly-valvular dysplasia prior to consideration of surgical AVSD repair. The patient had severe pulmonary hypertension with severely elevated end diastolic pressures in both ventricles. Pulmonary vascular resistance was found to be 7.5 Woodunits.m2, with poor reactivity to oxygen and nitric oxide. Patient was thus managed conservatively without any surgical interventions.

INTRODUCTION

Trisomy 18 (T18) is associated with multiple cardiac anomalies [1,2]. Although surgical intervention is feasible, appropriate patient selection is key [3,4]. Important factors that lead to morbidity and mortality in these patients are congestive heart failure and pulmonary hypertension [5,6]. Accurate pre-operative assessment of pulmonary vascular resistance is critical in surgical planning of selected patients with clinical concerns about pulmonary hypertension.

CASE PRESENTATION

We describe a patient with a prenatal diagnosis of T18 who was born at 34.6 weeks due to maternal pre-eclampsia. The cardiac diagnosis was consistent with atrio-ventricular septal defect with a large inlet ventricular septal defect (VSD), and poly-valvular dysplasia. Additional significant co-morbidity included trachea-esophageal fistula, which needed placement of a gastrostomy tube. She also had significant lung disease related to prematurity, and over the course of time evolved into ventilator and tracheostomy dependency.

Surgical AVSD repair was planned following establishment of stable respiratory support (in the form of home ventilatory settings). However, closer to the surgical procedure, around 6-months of age, it was noted that the patient had shown progressive worsening of the right ventricular hypertrophy and bidirectional shunting across the ventricular septal defect. Additionally, her saturations were noted to be in the mid-80s on 30% FIO2. These findings were concerning for pulmonary

hypertension, and thus the patient was referred for cardiac catheterization.

Baseline hemodynamics showed Qp:Qs ratio of 0.7. The mean pressure in the main pulmonary artery was severely elevated to 55 mmHg, with pulmonary capillary wedge pressure of 10 mmHg, and pulmonary vascular resistance of 7.5 Wood units/m². The right ventricular end-diastolic pressure was elevated to 15 mmHg (Table 1). After introduction of pulmonary vasodilators with 100% oxygen and 40 ppm of nitric oxide, the Qp:Qs increased to 1.5, but there was minimal change in the pulmonary vascular resistance which measured 5.6 Wood units/m² (Table 2). He also had severely elevated end diastolic pressures of 15mmHg in both ventricles at baseline. Based on significant pulmonary hypertension with poor reactivity to pulmonary vasodilators, the patient was deemed a poor surgical candidate and was

Table 1: Baseline hemodynamic and saturation data (On 21% FiO₂).

Pressure Data	Saturation Data
Right atrium: 14/10 Mean 9 mm Hg	Superior venacava: 69%
Right Ventricle: 80/15 mmHg	Pulmonary artery: 73%
Main Pulmonary artery: 75/42 Mean 55 mmHg	Assumed PV: 90% (lung disease)
Left pulmonary artery wedge: Mean 10 mmHg	
Left Ventricle: 80/15 mmHg	
Ulnar artery: 91/47, Mean 62 mmHg	Ulnar artery: 81%
Qp/Qs: 0.7:1	
PVRI = 7.5 WU.m2	

Table 2: Hemodynamics with 100% oxygen and 40 parts per million of inhaled nitric oxide

Pressure Data	Saturation Data
Right atrium: 12/9 Mean 7 mm Hg	Superior venacava: 79%
Right Ventricle: 70/15 mmHg	Main and right pulmonary artery: 85%, PaO ₂ : 54
Main Pulmonary artery: 77/37 Mean 53 mmHg	Assumed PV: 97%, PaO ₂ : 97
Right pulmonary artery: 77/37 Mean 53 mmHg	
Right pulmonary artery wedge: Mean 9 mmHg	
Left atrium: 9/10 Mean 7 mm Hg	Ulnar artery: 97%, PaO ₂ : 97
Qp/Qs: 1.5:1	
PVRI = 5.6 WU.m2	

discharged home with medical management for pulmonary hypertension. The patient currently is 14-month-old living with severe pulmonary hypertension, and being managed medically with Sildenafil. The family declined initiation of Bosentan. In the interim, there have been several hospital admissions due to pulmonary hypertensive crises, mostly in the setting of acute infections.

DISCUSSION

Trisomy 18 is associated with multiple congenital cardiac heart defects including atrial septal defects, ventricular septal defects, atrio-ventricular septal defects, patent ductus arteriosus, and valvular dysplasia [2, 6-8]. Historically, the natural course of illness in most of these patients is death in the first year of life, most commonly related to central apnea and aspiration, potentially unrelated to heart defects [7,8]. Over the past two decades, with advances in surgical techniques and evolution of multi-disciplinary management, an increasing number of these infants are undergoing a variety of interventions, including cardiac surgery [7-12]. A recent review of the Society of Thoracic Surgeons Congenital Heart Surgery database (STS-CHSD), showed that 70% of STS centers performed surgery on T18 patients. In a span of 8 years (between 2010 to 2017), 270 cardiac surgeries were done in T18 patients, with a significant number being high risk patients (26.7% in STAT 4 and STAT 5 categories) [11]. Incidence of perioperative complications remain high (55%) in T18 patients with a significant in-hospital mortality up to 15.6% [9]. Additionally, the overall five-year survival for patients with Trisomy 18 remains grim (12.3%) [9]. Hence, careful planning and risk assessment, prior to undergoing cardiac surgical interventions is very important.

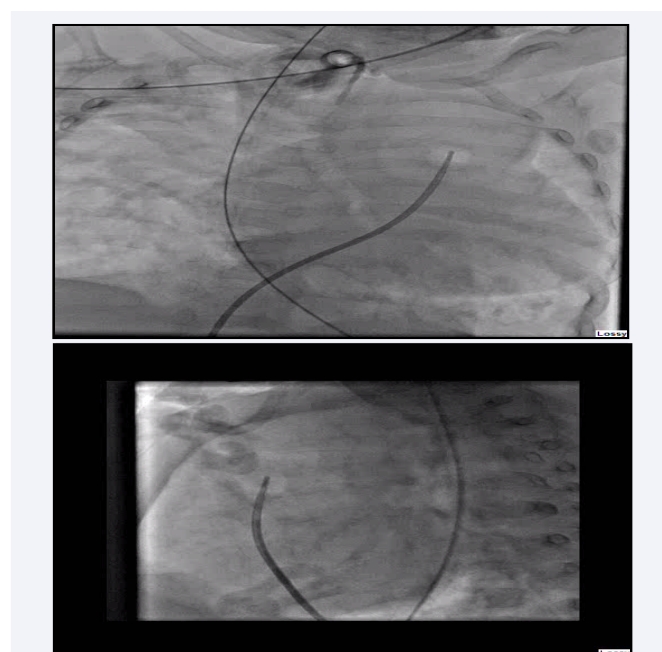
Pulmonary hypertension is common in T18 patients, and is an important contributor to morbidity [5,6,12]. In a retrospective multicenter study from Japan published recently, pulmonary hypertension was present in up to 42% of T18 patients [11]. Similarly, a retrospective review of the Pediatric Cardiac Care Consortium (PCCC) identified pulmonary hypertension in 10.8% of T18 patients undergoing cardiac surgery [10]. A single center retrospective study published recently identified that in patients with complete repair, a large majority (75%) had evidence of pulmonary hypertension post-operatively.¹² At discharge, nearly half of the patients (45%) required supplemental oxygen, and

27% were placed on an additional pulmonary vasodilator, such as sildenafil or bosentan [12]. Thus, it is evident that pulmonary hypertension is prevalent in a substantial number of T18 patients, both pre-operatively, as well as after surgery. This contributes to the post-operative morbidity/mortality, requiring additional therapies and hospital length of stay.

Echocardiogram is a good non-invasive imaging modality for serial evaluation of these patients. However, direct measurement of pulmonary artery and right ventricular pressures is considered gold standard for assessment of pulmonary hypertension. In addition, the contribution of shunts, and the response to pulmonary vasodilators can be assessed as well, to guide surgical planning. Patients with pulmonary over-circulation (Qp:Qs >1.5) and reactive pulmonary vascular bed will benefit from closure of the shunts. However, surgical intervention is contraindicated in patients with severe pulmonary hypertension, a non-reactive pulmonary vascular bed and Qp:Qs <1.

Pre-operative ventilator dependency, prematurity, earlier age and weight at procedure, pulmonary hypertension and ductal dependent cardiac lesions portend worse prognosis for these patients. Hence, clinical decision making requires a multi-disciplinary team approach between primary care, neonatologists, cardiologists, surgeons and the family. Ongoing longitudinal research is required in these patients to establish standard of care and to improve quality of life of these individuals (Video 1,2).

In summary, pulmonary hypertension is common in T18 patients with congenital heart disease. This has a significant bearing on surgical planning for those individuals suspected to



Videos 1,2 Video 1 and 2 show AP and lateral projections of a main pulmonary artery angiogram. The angiogram shows a dilated main and branch pulmonary arteries. The pulmonary arterioles appear dilated with abrupt tapering suggestive of chronic changes. On levo-phase the contrast returns to a dilated left atrium and left ventricle.

have pulmonary hypertension. Cardiac catheterization prior to surgery is extremely useful in select cases to determine the degree of pulmonary hypertension, and vaso-reactivity to pulmonary vasodilators. Those with non-reactive pulmonary hypertension should be managed medically.

REFERENCES

- Carey JC. Trisomy 18 and trisomy 13 syndromes. In: Cassidy SB, Allanson JE, eds. *Management of Genetic Syndromes*. Hoboken, NJ: John Wiley & Sons, Inc.; 2010: 807–823.
- Van Praagh S, Truman T, Firpo A, Bang-Rodrigo A, Fried R, McManus BR, et al. Cardiac malformations in trisomy-18: a study of 41 postmortem cases. *J Am Coll Cardiol*. 1989; 13: 1586-97.
- Janvier A, Farlow B, Barrington K. Cardiac surgery for children with trisomies 13 and 18: where are we now?. *Semin Perinatol*. 2016; 40: 254-260.
- Witters G, Van Robays J, Willekes C, Coumans A, Peeters H, Gyselaers W, et al. Trisomy 13, 18, 21, Triploidy and Turner syndrome: the 5T's. *Look at the hands. Facts Views Vis Obgyn*. 2011; 3: 15-21.
- Tahara M, Shimosono S, Nitta T, Yamaki S. Medial defects of the small pulmonary arteries in fatal pulmonary hypertension in infants with trisomy 13 and trisomy 18. *Am J Med Genet A*. 2014; 164: 319-23.
- Musewe NN, Alexander DJ, Teshima I, Smallhorn JF, Freedom RM. Echocardiographic evaluation of the spectrum of cardiac anomalies associated with trisomy 13 and trisomy 18. *J Am Coll Cardiol*. 1990; 15: 673-7.
- Nelson KE, Rosella LC, Mahant S, Guttman A. Survival and surgical interventions for children with trisomy 13 and 18. *JAMA*. 2016; 316: 420-8.
- Kosiv KA, Gossett JM, Bai S, Collins RT. Congenital heart surgery on in-hospital mortality in trisomy 13 and 18. *Pediatrics*. 2017; 140: e20170772.
- Cooper DS, Riggs KW, Zafar F, Jacobs JP, Hill KD, Pasquali SK, et al. Cardiac surgery in patients with trisomy 13 and 18: An analysis of the society of thoracic surgeons congenital heart surgery database. *Journal of the American Heart Association*. 2019; 8: e012349.:673-7.
- Peterson JK, Kochilas LK, Catton KG, Moller JH, Setty SP. Long-term outcomes of children with trisomy 13 and 18 after congenital heart disease interventions. *Ann Thorac Surg*. 2017; 103: 1941-9.
- Kato E, Kitase Y, Tachibana T, Hattori T, Saito A, Muramatsu Y, et al. Factors related to survival discharge in trisomy 18: A retrospective multicenter study. *AJMG*. 2019; 179: 1253-9.
- Peterson R, Calamur N, Fiore A, Huddleston C, Spence K. Factors influencing outcomes after cardiac intervention in infants with trisomy 13 and 18. *Pediatr Cardiol*. 2018; 39: 140-7.

Cite this article

Chakraborty A, Holt DB, Wright K, Agrawal H (2020) *Pulmonary Hypertension in Trisomy 18: Role of Pre-Operative Cardiac Catheterization in Select Cases*. *Ann Vasc Med Res* 7(5): 1121.