

Research Article

Review on Practical Guidance of Veterinary Clinical Diagnostic Approach

Tagesu Abdisa*

College of Agriculture and Veterinary Medicine, Jimma University, Ethiopia

*Corresponding author

Tagesu Abdisa, Jimma University, College of Agriculture and Veterinary Medicine, School of Veterinary Medicine P.o Box 307, Jimma, Ethiopia, Tel: 251933681407; Email: abdisatagesu@gmail.com ; tagesuabdisa@yahoo.com

Submitted: 27 April 2017

Accepted: 18 May 2017

Published: 19 May 2017

ISSN: 2378-931X

Copyright

© 2017 Abdisa

OPEN ACCESS

Abstract

Animal disease problems have been investigated by veterinarians through undertaking a careful and clinical examination with the objective of recognizing the nature of the affection. So, that effective treatment and control measure is adopted. Clinical examination is one of the fundamental for diagnosing animals which are presented to clinic. Veterinary clinical examination relies on knowledge of Anatomy, Physiology, Pathology and Animal behavior, skills in the methods and techniques of clinical examination, clinical sign and pathogenesis of the diseases which are the basic requirements for clinician in his/her good diagnostic approach. The diseased animals which are presented to veterinary clinic can be analyzed by veterinarian or clinician, the clinician approach through asking the owners complaint, which request for professional assistance by giving animal history. The accurate and complete history of patient may get from focusing on collection of patient data, present, past and environmental history in appropriate to patient animals. The veterinarian can approach to animals by the method of restraining in order to handle in safe condition. Physical examination is the examination that applies to animals by general inspection, palpation, and percussion and auscultation methods used to detect clinical signs of abnormalities. Clinical examination can be undergone by taking vital sign, general clinical examination and systemic examination of animals. Animals which have been diagnosed by veterinarian may have medication, through the injection or oral route with an appropriate dose of drug related to body weight, age and condition of animals. In conclusion, the veterinary clinical diagnostic approach is the core and the most important to generate accurate clinical examination, investigation of animal's disease problem and guide how to handle the animals and the methods of restraining of animals. The objective of this review paper is helps to understand and know how the procedure of veterinary clinical diagnostic undergoes and treatment of animals takes place, to guide and give knowledge on systemic and general examination of domestic animals.

Keywords

- Clinical examination
- History taking
- Medication
- Physical examination
- Clinical diagnosis

INTRODUCTION

Clinical examination is a fundamental part of the process of veterinary diagnosis. It provides the veterinarian with the information required to determine the disease or diseases producing the clinical abnormalities. In addition, the information derived from the clinical examination should assist the veterinarian in determining the severity of the pathophysiological processes present. Without a proficient clinical examination and an accurate diagnosis, it is unlikely that the treatment, control, prognosis and welfare of animals will be optimized [1-5].

The organs or systems involved, the location, type of lesion present, the pathophysiological processes occurring and the severity of the disease can be deduced from the information gained during the clinical examination. The success of clinical examination relies heavily on the knowledge of the clinician and usually assumes a single condition is responsible for the abnormalities. Many clinicians begin their examination by performing a general examination which includes a broad search

for abnormalities [6,7]. The system or region involved is identified and is then examined in greater detail using either a complete or a problem oriented examination. For this sound knowledge of Anatomy, Physiology, Pathology and Animal behavior, skills in the methods and techniques of clinical examination, knowledge of etiology, clinical sign and pathogenesis of the diseases are the basic requirements for clinician to make diagnosis. The objectivity of this review on practical veterinary diagnostic approach is as the following:

- Guide to how to handle the animals and the methods of restraining of animals
- It helps to understand and know the procedure of clinical diagnostic, how to take history
- To understand the general and systemic examination of domestic animals
- Having knowledge of how to examine, treat and identified the complex disease of animas

- It guides to give knowledge on how to prepare and administration of veterinary drugs

Literature review

The practical guidance of veterinary diagnostic approach: Veterinary clinical examination relies on knowledge of Anatomy, Physiology, Pathology and Animal behavior, skills in the methods and techniques of clinical examination, clinical sign and pathogenesis of the diseases which are the basic requirements for clinician in his/her good diagnostic approach [8]. The diseased animals which are presented to veterinary clinic can be analyzed by veterinarian or clinician, the clinician approach through asking the owners complaint, which request for professional assistance by giving animal history. The clinical examination ideally proceeds through a number of steps. The owner's complaint, the history of the patient, the history of the farm and the signalment of the patient are usually established at the same time by interview with the owner or keeper of the animal [9]. The following points are going to be taken before diagnosing presented animals.

Taking of patient history: History taking or anamnesis is the process of obtaining information on the animal patient about its illness, onset of illness and feeding practice through careful questioning of the owner. In Veterinary practice, the disease is presented indirectly in the form of a complaint by the owner or the attendant. Thus, it is very necessary to have all the information from the owner. Most of the time, the owner or attendant fails to provide pertinent and adequate history and inaccurate history may lead to misdiagnosis. The clinician must substantiate these with rational question utilizing professional knowledge [1,5]. The disease problem of patient animals is difficult to diagnose without knowing the history of animals, the history should be taken from the owners of the patient and recording the owner's complaint. Disease information should include the group(s) affected, the numbers of animal affected (morbidity) and the identities of the animals affected; the number of animals that have died (mortality) should be established. In order to get the accurate and complete history of patient the following things should be focused; patient data, present history, past history and environmental history. Patient data is essential to identify the patient and it includes: Owner's name, Owner's address: postal address, telephone, kebele, peasant association, Species, breed, sex, age, name, ID No., body weight, Description including color, marking, polledness, and other identification marks of patient [8,9].

Presented history of patient: It comprises of recording the sequential events from the start of the patient chronic. Questions about physiological functions such as appetite, urination, defecation, rumination, respiration, sweating, milk production, gait, posture and also of the first symptoms shown by the animal should be asked. All these information deal with the current problem of the animal and the events associated with it. The point which going to be asked is that as follows [1,5,8]:

Locations of the problems: Following up and attention at the complaint that a farmer has to say and from there you can tentatively say the likely system involved in that condition, for instance:

- Digestive system involvement will be shown as absence of rumination, appetite, bloat or diarrhea.
- Respiratory system involvement will be indicated presence of nasal discharge, coughing, dyspnea.
- Urinary system involvement will be manifested as frequent urination, passing red coloured or cloudy urine.
- Musculo-skeletal and nervous system involvement will be manifested as lameness, inco-ordination, and paralysis.

Nature of illness: The clinician should be able to assess and find out the time of onset of disease, any change management practices and signs noticed by the farmers.

- To assess to know the duration of disease whether it is peracute, acute, subacute or chronic
- To know number of animal diseased and morbidity rate and mortality rate of animals
- Determine whether any drug has been given for animals, before patient come to clinic for assurance
- And the following question should be pointed:
 - When did the farmer notice the disorder? (time)
 - Did it occur suddenly/slowly? (acute /sub-acute / chronic nature)
 - What were the signs noticed? (anorexia/drop in milk yield/ others)
 - Are the animal fed / grazed in pasture / forest grazed? (getting information on management practices e.g. ketosis seen in stall fed animals, while babesiosis seen in forest grazed animals)
 - Is there any other animal affected with similar condition in the same herd / in other farmer's herd in the village (to find out if the disease is rapidly spreading)?
 - Ask if there has been any introduction of new animal to the herd / village (sick animal may have been bought from affected area and disease has started)
 - Is the affected animal vaccinated against food-and-mouth disease (FMD), anthrax, hemorrhagicsepticemia (HS), Black quarter (BQ) (to find out if the animal is protected against common diseases)

Past history

Inquiring into the past history may help in arriving at a diagnosis. History of drenching a day or two earlier may cause aspiration pneumonia. History of past disease may be co-related to the present illness. Past history will also give idea if such condition prevailed previously in the area.

- Ask if such condition was reported previously too (reveal endemic nature of disease, or occurrence of a new disease)
- Does this occur at certain period of time? (find out the seasonal occurrence of the disease)
- Was the disease reported from other places in the locality? (area of spread / occurrence can be found out)

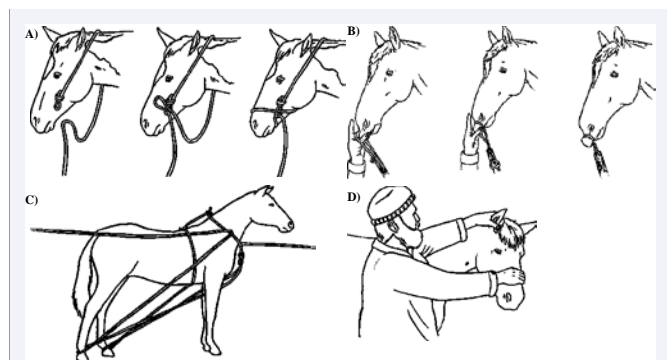


Figure 1 pictures of how to restraint horse [12]; **A: Halter** If a horse or donkey's head is restrained, it can be led or held for procedures such as injections. A halter can be made from a piece of sisal or cotton rope. Avoid using nylon rope against the skin. **B: The Lip twitch** → The twitch is useful to restrain a horse before a painful procedure, to examine it or give it treatment. It is known that a twitch placed correctly on the nose causes the release of natural pain-killing substances in the horse's body. **C: Two Rope Casting** → used to prevent kicking and it can be done safely without danger of being kicked. It is done to avoid being kicked when helping a mare that is having a difficult birth and make it lie on its side. **D: Mild restraint** without a twitch

outdoors may include the presence of toxic material, grazing management, biosecurity and regional mineral deficiencies. Risk factors indoors may include ventilation, humidity, dust, stocking density, temperature, lighting, bedding, water availability, feeding facilities and fitments. Environment or surrounding of the animals may help in the diagnosis of disease. E.g.-Animal grazing on pasture irrigated with sewerage water may suffer from nitrate poisoning. Parasitic diseases are more in animals, which are kept in marshy lands. Recent spraying of weedicide or insecticides may poison the animals. Environmental history can be divided

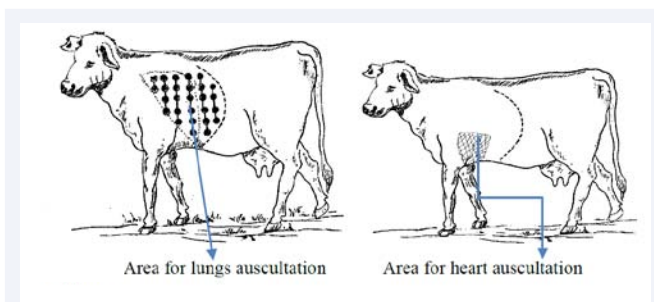


Figure 3

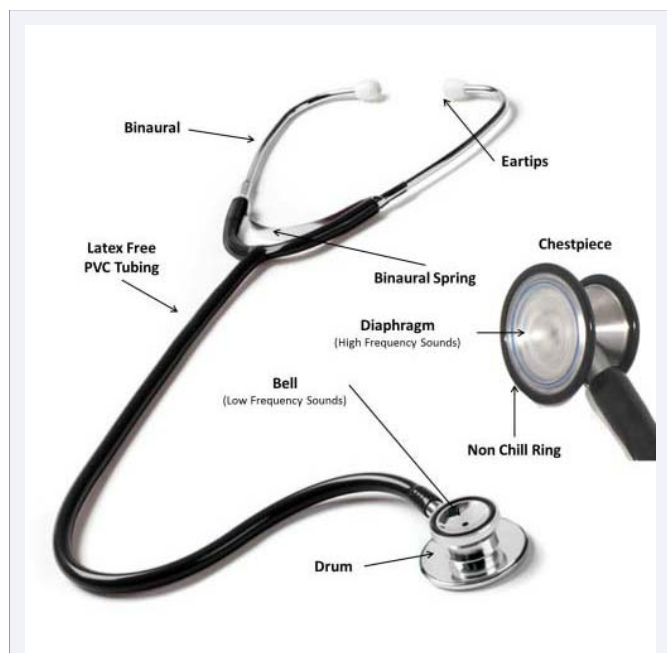

Figure 2 Part of Stethoscope.

- Has any animal recovered from such a sickness? (to aid in prognosis)
- Is the disease restricted to certain age group / sex? (BQ is seen in animals between 1 – 3 years of age in both sexes [2,4].)

MANAGEMENT AND ENVIRONMENTAL HISTORY

The environment in which the animals were kept at the time of the onset or just before the onset of the illness should be carefully examined. The animals may be housed or outside. Risk factors




Figure 4 Picture of manual thermometer.

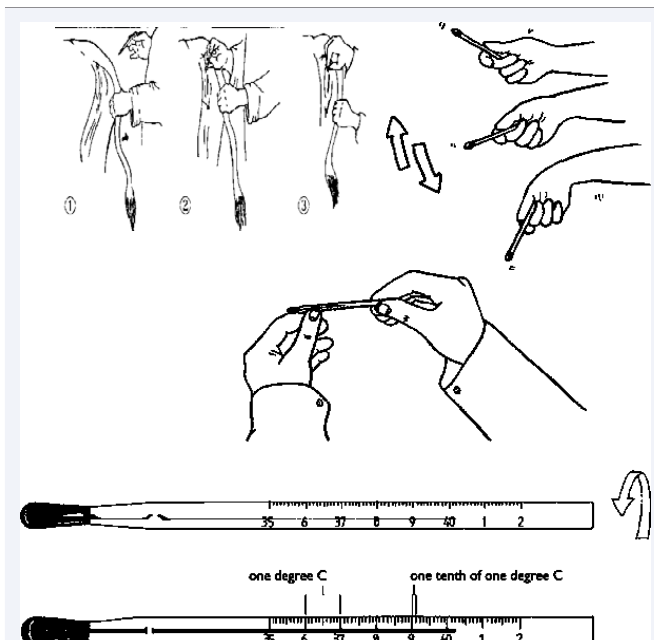


Figure 5 Picture procedure how to take and read temperature of animals [12]. **A:** procedure how to insert thermometer to animal's anus; **B:** If the reading is not below 36°C, shake the mercury down to the bulb. Use flicking motions, taking care not to hit the thermometer on anything. **C:** Take the thermometer out of its case and hold it between the thumb and forefinger. Roll it until you can see a broad silver band of mercury.

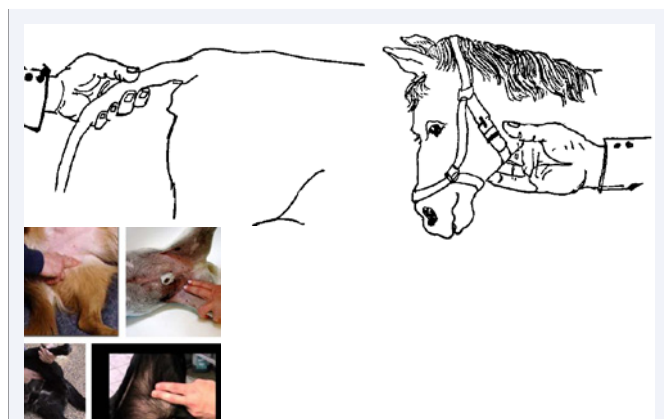


Figure 6 Site of pulse taking in animals; A: cattle, B: horse, C: small animals.

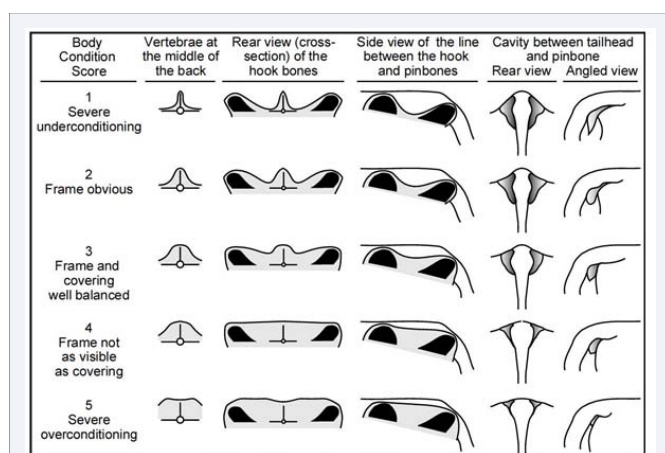


Figure 7 Body condition score of animal.

into outdoor environment and indoor environment [9].

Outdoor environment history

It regard to the topography of land where animals are reared, vegetation, type of agriculture practiced in the locality, use of chemicals in agriculture (pesticide, weedicide) and system garbage disposal in the area. Animals that are grazed are likely to be infested by parasites and prone to vector borne diseases like babesiosis, trypanosomiasis, or animals that are grazed in the marshy area including paddy filed are likely to be infested by liver fluke etc.

Indoor environment history: *it regards with the types of animal house.* The following should be look assessed how is the house of animals is designed:

- If there is proper ventilation,
- In the rural area, traditionally animals are housed in the ground floor of the house where there hardly any ventilation and this will predispose the animals to respiratory diseases,
- If the animals are stall fed check
- If the animals are provided with enough drinking water,

- If the floor is dry and clean, damp and dirty floor may lead to mastitis in milking animals,
- If the bedding materials are used
- If the materials are changed daily or topped daily to keep the animals dry and clean.
- If the animals are housed separately see
- If the height of the roof is at a required level,
- If it is too low, in hot places animals may be subjected to heat stress in summer months,
- If it is too high animals will be exposed to rain.

The methods how to approach to animals

Restraints the term used to imply control of an animal and may be necessary for medical reasons and nonmedical procedures. Animals are often resisting to the clinical examination procedures. The animal must be restrained so that it can be examined carefully, safely and with confidence. The methods of restraint should be done, in order to able to carry out the examination safely and without danger to the clinician and assistants, the methods available may be classified as the following [6,9].

- ❖ Physical restraint.
- ❖ Chemical restraint
- ❖ Verbal/Moral restraining

Physical restraint

It is important to perform all the physical manipulations in a quiet and gentle manner in order to carry out the examination safely without causing danger to the clinician or his assistants and to avoid disturbing the patient. Restraining methods for equine, cattle, Pet animal, sheep and goats

Restraints of the equine

Equipment used for restraint and handling should be effective without causing stress to the horse and should be designed for maximum safety of the handler and horse. A horse should be approached from the front and slightly to the left (near) side because they are accustomed to being handled on that side. They become nervous when handled from the right side [10]. Any restraint method used to assist normal management or treatment of the horse should be the most mild and effective method available, and should be applied for the minimum amount of time necessary to carry out the task. A halter and lead rope is the most common form of restraint. Generally, the safest knots are those that can be quickly untied even if the horse has pulled on it. When used by knowledgeable handlers, other acceptable forms of restraint include hobbles, twitches, lead chains, stocks and chutes [11]. Tethering is a form of restraint that brings a high risk of injury to horses unless used correctly. For the purpose of this Code, tethering means attaching a long rope or chain to the halter or leg hobble so the horse can graze. Tethering does not refer to tie stalls or briefly tying a horse to a fixed object [11]. The following lists are the method how to restrain horse [8,10]:

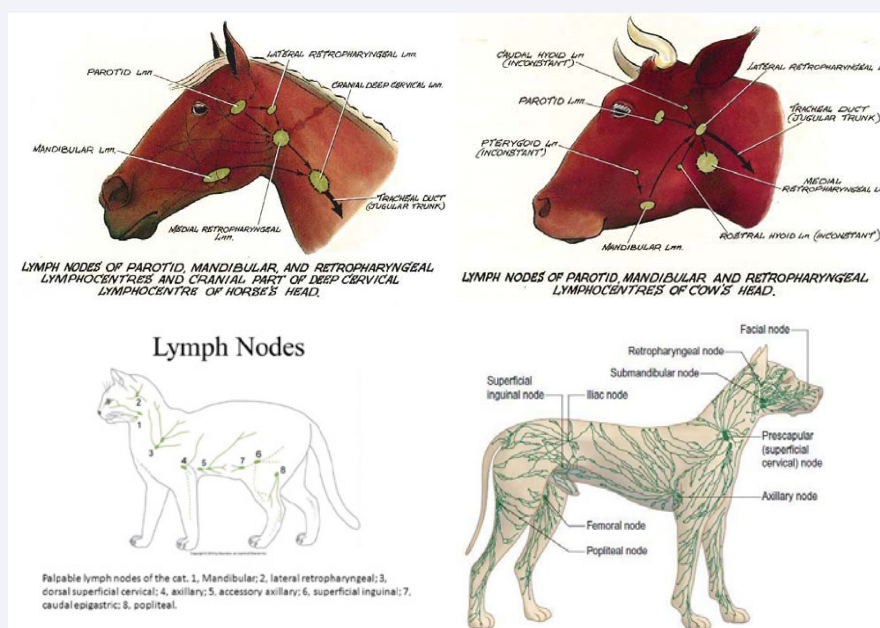


Figure 8 Anatomical location of animal lymph node, A: Horse; B: Cattle; C: cat; D: Dog.

- Applying a halter.
- Rope twitch
- The hand twitch
- Neck skin grip: To restrain the horse, grasp the loose skin of the neck.
- Twitch is applied to the upper or lower lip or to the ear
- Nose twitch
- Lifting the fore-leg and hind-leg by unaided hands or with Leg twitch
- A loop of strong cord or soft rope is applied to the appropriate part
- Two ropes one-person horse casting
- Two ropes four people's horse casting
- Two ropes three-person cattle casting
- Chest twitch: Chest twitch is used for exceptionally restless cattle.
- Procedure chest twitch: A rope is tied around the chest and held under tension by a strong pole twisted in a rope loop. However, chest twitch should be used only when there is no other method of restraint.
- **Nose lead:** It restrains cattle by applying pressure to the nasal septum.
- **Procedure of nose lead:** It is shaped like a pair of tongs with a large ball at the end of each arm, which fits against the nasal septum. Usually, it has a chain or rope at the end. Hold the lead out for the animal to sniff. As the animal raises its head to sniff, slip the nose lid into the nostrils and close quickly. Then tie the rope to the post for continuous restraint but remember it loses effect when the nasal septum becomes numb. Manually holding the nasal septum with index finger and thumb *nose grip* and slip in the nose lead. It is advisable to avoid using nose lead too frequently on the animal as it may become "head shy".
- **Restraint using a crush:** A crush can be used to restrain many animals at a go. It can be constructed of posts or planks or steel tubing. However, the internal surface should be free of sharp edges or projections that can injure the animal. So, it should comprise of an assembly area with a funnel ending in a closed pen with the final run being just wide enough for one animal and sufficiently high enough to prevent it from jumping. Backward movement is prevented by a transverse bar inserted just behind the animal [13].

Restraint of the cattle

Restraint of cattle depends on breed, age, sex and knowledge of animal behavior. For example, bulls are unpredictable and should be handled with care. Aggressive bulls for instance, will paw the ground with front feet, lower and shake the head. They may also make mowing sounds. Nervous cows will keep head and tail up and may have an anxious expression in their eyes [8,13]. The followings are the methods for restraint of cattle:

- The nasal septum is gripped between the thumb and one finger or with 'bull-holder'
- Leg twitches are also employed
- One rope locking two horns on a post or tree
- One rope two-person cattle casting

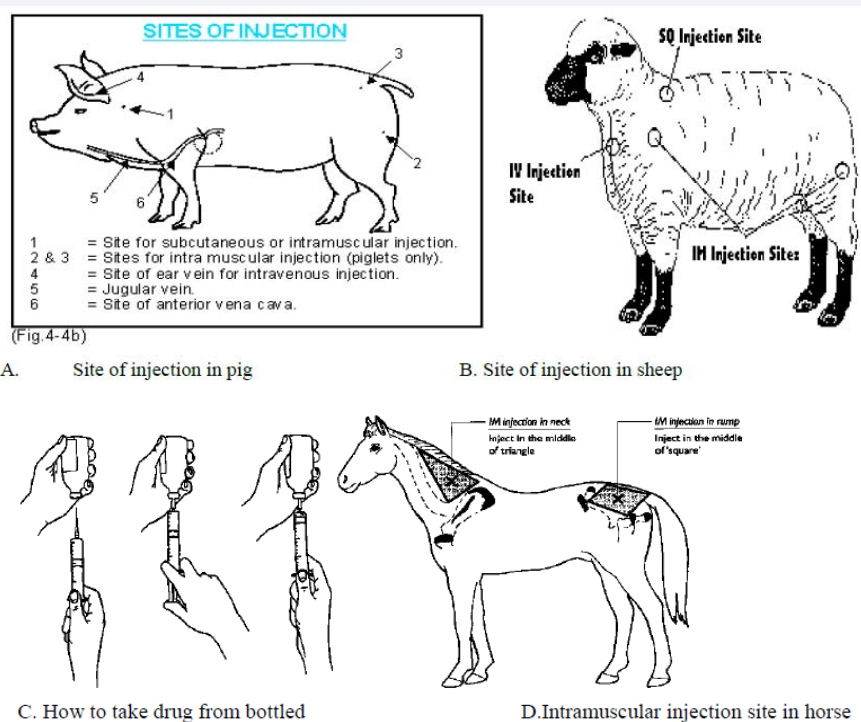


Figure 9 Site of parenteral injection in domestic animals
How to load a syringe during taking drug [12].

Restraint of sheep and goat

Sheep have an intense instinct to remain with the flock and as such, it is best to handle them as a flock initially before isolating the animal you want to perform certain procedures on. When disturbed, they will stamp their front feet and will use the head to attack. Hence, always work gently, calmly and with assurance around them. Sheep have very fragile bones that can easily be broken and heavily woolled sheep may become hyperthermised if chased around [13]. The following are the methods how to restraint and holding sheep [13].

Capturing a sheep

The sheep can be captured by driving the flock into a small pen or enclosure and then approach an individual animal slowly. Swing your arm around the neck and front quarters and quickly wrap your other hand around the hindquarters or grasp the tail if present.

Shepherds crook

Hook a rear leg at the hock, quickly immobilizes sheep as above.

Halters: Can be used but remember sheep have a short nose and should be careful not to block the nostrils.

Restraint of goat

Goats do not tolerate rough treatment and will struggle violently if not properly handled. Therefore, restraint time should be as short as it is necessarily possible [18].

Walls and fences: Push the goat against the fence or wall with your legs and hip and leave your hands free for other procedures. You can also push the hindquarters against a wall and then put your hand around the neck to keep it still for temperature taking or injection.

Restraint on lateral recumbency: The goat is placed parallel to your legs; the jaws are grasped with one hand while the inside rear leg is grasped with the other hand. Bring the leg forwards. The goat will be thrown off balance and fall on the ground.

Restraint of the Head: This is best when the goat is pushed in a corner and the body held against a wall.

Procedure: Grasp the beard (if bearded) with one hand and encircle the neck with the other arm to stabilize the head.

Use of horns: This should only be for a short time as goats react violently when horns are held. Moreover, horns should not be used in very old goats as they break easily.

Cheek hold: Place one hand on either side of the cheeks and wrap fingers around the mandibles to hold firmly. You can examine the eyes or take blood from the jugular.

Collars: Leather collar or neck chain can be used in dairy goats to lead or restrain them. They may be temporary or permanent (collars). Neck chains should be made of small, flat links, which don't catch easily as the goat rubs against a fence.

Restraint of Pet animals

Cats have always relied on speed, agility, caution, needle

sharp teeth and dagger-like claws for survival. Therefore, they should be approached in a feeble manner. Restraint techniques of cat are as following [10,13]:

Leg restraint: Always place an index finger or middle finger between two legs. This provides a better grip to prevent escape.

Head – Mandible hold: The palm of the hand is placed under the cat's chin and the fingers are used to grasp mandible.

Scruff of the neck: Hold as much of the loose skin on the back of the cat's neck as possible. This prevents the cat from turning its head to bite.

Restraint with towel: Cover the head with a towel or cover the entire cat; then lift it up, isolate the needed part and uncover it. This is good for injection or examination.

Restraint bag: Feline restraint bag (cat bag) is normally used to restrict the movement of the cat and also to protect the handler from scratches.

Restraint with the adhesive tape: Apply adhesive tape around the legs starting with the hind legs then followed by the four legs.

Gauze muzzle: They can be commercially available (leather muzzles) or home made using gauze.

Procedure of gauze muzzle

Make an over hand knot in the middle of the gauze to form a loop. Next, lower the loop over the cat's muzzle and tighten it on both ends of the gauze. Bring the gauze under the jaws, which are tied together under the mandible using an overhand knot with both ends brought behind the ears.

In **restraint of dog** the following devices prevent injury when used correctly and judiciously [10].

Muzzles: Commercial muzzles are made of leather, wire or fabric. There are also gauze or nylon rope muzzles.

Gauze or rope muzzles: For dogs with long noses, you do not need to pass the passive end between the eyes to secure the loop over the nose before tying the bow gauze after passing behind the ears.

Blanket and towels: These are used to remove unfriendly dogs from cages.

RESTRAINT OF POULTRY AND BIRDS

Free movement of the sternum is essential for respiration in birds. They possess no diaphragm and their lungs do not expand and contract. They breathe through expansion and contraction of their air sacs facilitated by their inter costal muscles. Thus, any undue pressure on their sternum would restrict breathing. We have all heard of instances where a bird has died in someone's hand. More than likely they had closed their hand around the chest inhibiting respiration. When handling a bird, fingers should never be closed around the chest, rather cupped in the hand to allow for sternal movement. During handling carefully monitor the bird for any signs of discomfort, stress or breathing difficulty. Due to struggling, the bird could contort and twist in such a way to constrict the air passages. Also during restraint, efforts to es-

cape can lead to hyperthermia, especially if in a towel, so be alert if the bird begins to pant heavily [10]. There are five basic means of holding a bird's head.

- ❖ Extend the head between the index and middle finger,
- ❖ Grasp the head with the thumb and index finger on either side of the head at the temporo-mandibular joint,
- ❖ Using three fingers, place the thumb and middle finger just below the eyes and the index finger over the head, called the 'helmet grip,'
- ❖ Crook the index finger behind the back of the head and gently place the thumb behind the lower mandible,
- ❖ Gently circling the neck with the thumb and index finger as a tubular restraint collar would.

Chemical restraint

Chemical restraint may be defined as the use of drugs to bring about sedation or neuroleptosis, neuroleptanalgesia, neuroleptanaesthesia or short duration general anaesthesia. This is a reversible process whose purpose is to produce convenient, safe, effective and inexpensive means of restraint so that clinical procedures may be carried out with minimum of stress, pain, discomfort, and toxic effects to the patient, the anaesthetist or the clinician [13]. Drugs that is useful for this purpose includes: Acepromazine, Acetylpromazine, Chlorpromazine, Promazine and Trimeprazine; members of this group can be used in most species of animals, Butorphanol, lloral hydrat [8,13].

Verbal/moral restraining

It is more practiced by owner e.g., feed provision, massaging, calling name of animal etc. When the horse is alert, the ears are flicked forwards and the horse is usually curious of one's approach. A nervous horse will continuously flick the ears back and forth especially when there is activity behind it while an angry or fearful horse will pull its ears backwards. This should however not be confused with laid-back ears where a horse is concentrating on a difficult task such as calf roping or barrel racing. The tail always indicates the horse's attitude. A wringing or circling Restraint of Domestic, Laboratory and Wild Animals tail is an indication of nervousness. A tail held straight down indicates pain or sleeping, while a tail clamped tight indicates fear. Nevertheless, each horse is an individual and should be treated accordingly. Horses can be calmed by an even tone of voice and are most cooperative when handled quietly and decisively. They can also, be easily "bribed" with a handful of delicious foods like oats, carrots etc. Scratching behind ears, eye ridges and the neck will convince the horse you are friendly [5,10]

Physical examination

The main aim of physical examination isto applies general inspection, palpation, percussion and auscultation methods used to detect clinical signs of abnormalities.

General inspection

It is done some distance away from the animal; sometimes goround the animal or herd/flock, in order to get the general impression about the case [2]. Attention should be paid to the fol-

Table 1: The structures that can be palpated and what they are palpated for are:.

No	organs	Palpated for
1.	Superficial arteries	Pulse
2.	uterus	Pregnancy
3.	muscles	Pain/swelling
4.	bone	Fracture/growth
5.	Stomach, intestine	Pain
6.	esophagus	Obstruction
7.	rumen	Bloat, impaction

Table 2: Normal temperature of domestic animals.

No	Animal species	Temperature/°C
1.	Cattle/ adult	37.8 -39.2
2.	Calve	38.5 -39.8
3.	Horse/adult	37.2 - 38
4.	Foal	37.5 -38.5
5.	Sheep	38.9 - 40
6.	Goat	38.6 -40.2
7.	Pig/adult	37.8- 38.9
8.	Piglet	38.9 - 40
9.	Small dog	38.6 -39.2
10.	Large dog	37.5 -38.6
11.	Cat	37.8 -39.2
12.	chicken	41.7

Table 3: Site of pulse taking in domestic animals.

No	Animals	Site of pulse taking
1.	Equine	External maxillary artery Transverse facial artery Median artery Great metatarsal artery
2.	Cattle and pig	Middle coccygeal artery Facial artery Median artery
3.	Sheep, Goat, Calf.	Femoral artery.
4.	Piglet, Dog and Cat.	Femoral artery.

Table 4: Normal Range of pulse rate in animals.

No	Animals	Pulse rate/minute
1.	Cattle	60 - 90
2.	Young calves	100-120
3.	Horse	28 - 42
4.	Foal up to 1 year	70-80
5.	Sheep	68 - 90
6.	Goat	68 - 90
7.	Pig	60 - 90
8.	Dog	90 - 130
9.	Cat	110 - 130
10.	Chicken	200 - 400

Table 5: The respiratory rate of domestic animal per minute.

No	Species of animals	Respiration rate/minute
1.	Cattle	25 - 30
2.	Horse	8 - 16
3.	Sheep	10 - 20
4.	Goat	10 - 20
5.	Pig	10 - 20
6.	Dog	16 - 30
7.	Cat	20 - 30
8.	Chicken	15 - 30

Table 6: The normal colour of mucous membrane of different animals.

Animal	Colour of mucous membrane
Cattle, sheet and goat	Pale pink
Horse	Pale roseate
Pig	Reddish
Dog	Pale roseate
Cat	Pale pink

The color of mucous membrane may change occurs in various diseases as follow by the following [19]:

lowing items: (Behavior, Appetite, Defecation, Urination, Pasture, Gait, Body condition, Body conformation), Lesions on outer surface of the body can be observed: (Skin and coat, Nose, Mouth, Eyes, Legs and hoofs, Anus).

Palpation

Palpation is used to detect the presence of pain in a tissue by noting increased sensitivity and use fingers, palm, back of the hand, and fist, in order to get the information about the variation in size, shape, consistency and temperature of body parts and lesions, e.g., the superficial lymph nodes. The terms, which can be used to describe the consistency of parts during palpation, are [1,14]:

- ❖ **Resilient**, when a structure quickly resumes its normal shape after the application of pressure has ceased (e.g., Normal rumen)
- ❖ **Doughy**, when pressure causes pitting as in edema
- ❖ **Firm**, when the resistance to pressure is similar to that of the normal liver (e.g., neoplasia/tumor)
- ❖ **Hard**, when the structure possesses bone-like consistency (e.g., Actinomycotic lesion)
- ❖ **Fluctuating**, when a wave-like movement is produced in a structure by the application of alternate pressure (e.g., hernia, hemorrhage/hematoma)
- ❖ **Emphysematous**, when the structure is swollen and yields on pressure with the production of a crackling or crackling sound.

Percussion

Method of examination in which part of body to be exam-

Table 7: Examples of primary and secondary skin lesions.

Primary skin lesions	Description	Examples	Secondary skin lesions	Notes
Spot	Circumscribed red area of skin which is not elevated or swollen	Flea bites	Erosion	Destructive separation of the epidermis (contagious pustular dermatitis of sheep and goat).
Papule	Firm elevation of skin surface caused by cellular infiltration	Pox	Ulcer	Circumscribed shallow destructive area of tissue with or without elevated edges (equine ulcerative lymphangitis)
Vesicle	Elevation of superficial layer of skin with accumulation of serous fluid beneath it.	FMD, vascular stomatitis, pox	Crust	A firm mthass consisting of dry inflammatory exudate or blood.
Blister	<i>A large vesicle</i>		<i>Dandruff</i>	<i>Secondary to ectoparasites</i>
Pustule	<i>A pus-filled vesicle</i>			

ined is struck with sharp blow using fingertips to produce audible sound. Sound thus emitted will indicate the nature of the tissue / organ involved for example rumen when bloated will emit drum like sound. Some of the organs that can be examined by percussion are: gastro-intestinal tract, abdomen and thorax, frontal and nasal sinuses. The objectives of percussion are to obtain information about the condition of the surrounding tissues and, more particularly, the deeper lying parts. Percussion can examine the area of the subcutaneous emphysema, lungs, rumen and rump. Sounds produced from various structures can be described as following list [1,3,5]:

- ❖ Dull / flat – sound without resonance or echo, this type of sound can be heard on percussion of thick muscles or bone.
- ❖ Full sound – sound heard is with resonance but not booming like drum. This type of sound is heard from tissues like lungs that contain air inside.
- ❖ Tympanic sound – drum like sound can be heard, and this type of sound is heard from bloated rumen, abomasums and intestine.

Immediate percussion

Using fingers or hammer directly strike the parts being examined.

Mediate percussion

Finger-finger percussion; Pleximeter-hammer percussion. The quality of the sounds produced by percussion is classified as [3].

- **Resonant:** This is characteristic of the sound emitted by air containing organs, such as the lungs.
- **Tympanic:** The sound produced by striking a hollow organ containing gas under pressure, e.g., tympanitic rumen or caecum.
- **Dull:** Sound emitted by a solid organ like the liver or heart.

MODIFIED PERCUSSION

Ballottement percussion

Tactile percussion or ballottement: is method in which palpation and percussion are combined together to feel structures

that cannot be felt by either of these methods applied singly. This is normally used for pregnancy diagnosis in cows when the foetus cannot be palpated through per rectum. Here a firm-pushing stroke is applied on to the uterus and the hand after pushing is kept in contact with uterus so that the foetus will bound and strike on it. While firm pushing is done, this sets fluid in uterus into motion and foetus is made to bounce [1]. This modified percussion is used to detect late pregnancy in small ruminants, dogs and cats. And also, used for detection rebound of floated material shows pregnancy.

Procedure: Apply a firm and interrupted push on the uterine region of the abdomen of small ruminants.

Fluid percussion

Used to detect fluid in the abdomen.

Procedure

Apply a push on one side of the abdomen, percussion on the other side. The presence of wave-like fluid movement shows accumulation of fluid in the abdomen, e.g., ascites [9,15].

Auscultation

Word auscultation comes from 'auscultona' meaning 'to listen'. This is a technique of listening to the sounds produced from organs in the abdominal and thoracic cavities. In olden days listening to these sounds were done with naked ears. This had certain limitations like the skin on animal being dirty and infested by parasites it was not healthy for the clinicians and was difficult to keep ears in contact on animal body due to constant movement. Therefore, an instrument was later developed for this purpose

Table 8: Location of heart in equines and ruminants [16].

Area	Equines	Ruminants
Base	From 2 nd to 6 th intercostal space	From 3 rd to 6 th rib
Apex	Half an inch from the last sternal segment	One inch from the diaphragm
Posterior border	Opposite to the 6 th rib	Opposite to the 5 th rib
Left surface	Composed of left ventricle and extends from 3 rd to 6 th rib	Extends from 3 rd to 4 th rib
Right surface	Extends from 3 rd to 4 th rib	Not examined

and this is called stethoscope [3,9].

The main objective of auscultation is that to listen the sounds produced by the functional activity of an organ located within a part of the body. This method used to examine the lung, trachea, heart and certain parts of the alimentary tract.

Types of auscultation

Direct auscultation: Procedure: Spread a piece of cloth on the part to be examined using two hands to fix the cloth and keep your ears close to the body, then listen directly.

Indirect auscultation: Use stethoscope.

Procedure: Fix the probe of the stethoscope firmly on the part of the body to be examined and listen to the sounds produced by the functional activities of the body carefully.

Steps in auscultation

Place the ear piece into the ears, hold the chest piece and give a gentle tap on diaphragm, if no sound is heard adjust it by holding rubber tube with one hand and turning the chest piece with the other until there is 'click' sound. Tap again there should be amplified sound heard. Place the chest piece over the desired area and listen to the sound hear or lungs accordingly. Areas for listening to heart and lungs sounds are shown below, for rumen left flank region can be used [9].

Succusion (shaking)

It is the method used to determine the presence of fluid in the body cavities like thoracic and abdominal cavity. Here the animal is shaken from side to side to set fluid into motion so that audible fluid sound is produced. This is difficult in large animals and can be applied only in small animals like dogs and cats [9].

Clinical Examination of the Patient

General physical examination: Physical examination can be carried out by taking vital sign such as; Temperature taking, Pulse taking, Respiration taking, Capillary Refill Time (CRT), Physical body condition, Normal demeanor, Abnormal demeanor [8,9].

Temperature taking: Temperature is the measure of how hot or cold the animal body is. On the basis of the ability to regulate body temperature animals are divided into two groups via homeotherms and poikilotherms. Homeotherms are those animals including man that can regulate their temperature in relation to the environmental temperature. Poikilotherms are those animals that are unable to regulate their body temperature in relation to the environmental temperature. eg. Amphibians, Reptiles and fishes. Heat is generated in the body via the intracellular oxidation of food and the muscular activities. It is lost via the physical process of conduction, convection, and radiation and through the evaporation, respiration and excretion [1].

The body temperature is taken using a mercury or digital electronic thermometer placed carefully into the rectum. The thermometer should be lubricated before insertion and checked (in the case of a mercury thermometer) to ensure that the mercury column has been shaken down before use. It should be held whilst it is in the rectum. Sudden antiperistalsis movements in the rectum may pull the thermometer out of reach towards the

colon. The thermometer is left in position for at least 30 seconds; the clinician should ensure the instrument is in contact with the rectal mucosa, especially if a lower than expected reading is obtained. The thermometer must be cleaned after removal from the patient. It must not be wiped clean on the patient's coat. If the animal's temperature is higher or lower than anticipated it should be checked again [1,9].

Procedure: how to take temperature and how to recording temperature [12,16].

The places, which can be used to take temperature, are rectum or vagina (approximately 0.5 degree centigrade higher in vagina).

- The thermometer should be sterilized by disinfectant (antiseptics) before use. Wet the thermometer with cold water or put some petroleum jelly (Vaseline) on the end to make it more slippery.
- It should be well shaken before recording of temperature to bring the mercury column below the lowest point likely to be observed in different species of animals. If the reading is not below 36°C, shake the mercury down to the bulb. Use flicking motions, taking care not to hit the thermometer on anything.
- The bulb end of the thermometer should be lubricated with liquid paraffin or glycerin or soap especially in case of small pup and kitten.
- Insert the thermometer in a rotational way and gentle manner. Care should be taken so that the bulb of the thermometer remains in contact with the rectal mucous membrane.
- The thermometer should be kept in site for at least 3-5 minutes.
- Pull out the thermometer, clean it and read the number.
- Put a halter or head collar on the horse or donkey and have an assistant hold the head.
- Read the value to define and explain a state of fever, hypothermia, and febrile or non-febrile animals.

Method of recording temperature

1. Keep the bulb of the thermometer immersed in the antiseptic solution for sterilization.
2. Bring down the column of the mercury before recording

Posture	Disease/disorders
Cow sit on sternum with head flexed to one side and resting on the flank	Milk Fever
Abducted elbow with extension of head and neck accompanied by mouth breathing in farm animals	Pneumonia
Arched back with tense abdomen	Peritonitis
Extension and rigidity of limbs, neck, ear and jaw	Tetanus
A male dog urinating like a bitch	Cystitis

Table 10: Abnormality of gait in domestic animals.

Gait	Disease
Lameness and disinclination to move	Laminitis, foot rot
Stiff gait	Arthritis
Walking in circles / head pressing	Gid (Coenurus)/otitis/ listeriosis
Dragging of the hind leg	subluxation of medial patellar ligament

Table 11: Site of parenteral injection in domestic animals.

No	Animal species	Intramuscular injection site	Intravenous injection site
1.	Horse, Buffalo	Rump, thigh, neck	Jugular vein
2.	Cattle, yak	Rump, thigh	Jugular vein
3.	Sheep, Goat	Thigh	Jugular vein
4.	Dog, cat	Thigh	Cephalic, saphenous veins
5.	Chicken	Chest, pectoral muscle	Wing vein
6.	Pig	Thigh	Ear vein

the temperature by shaking.

- Lubricate the bulb with liquid paraffin or Glycerine or soap and water, when the thermometer is to be used in pup or kitten.
- Insert the bulb of the thermometer into the rectum and tilt to one side so that the bulb of the thermometer touches the mucous membrane of the rectum.
- Keep the thermometer in this position for one minute.
- Take it out, wipe the faeces with cotton and read the temperature directly

of thermometer: Thermometer reading will reveal if the temperature of animal being examined is normal, above normal (fever) or below normal (subnormal). Based on this finding action taken will vary.

Fever: Denotes the elevation of body temperature of animal above normal. It is a general reaction of animal and human body to the action of infectious agents like bacteria, virus, parasites and exogenous substances like bacterial toxins. Sign of fevers are Animal will refuse to eat either completely or partially (anorexia), hair on the body might be seen standing up, dullness, and dry muzzle.

Fever management: There are preparations to reduce temperature. Preparations like paracetamol, Phenylbutazone is normally given to control fever (refer drug index for these preparations) in addition keeping animals in cool place [3].

Subnormal temperature / hypothermia: The temperature of animal drops below normal and this occurs when animals get exposed to extreme cold for example when a calf is exposed to heavy rain, when animal is in shock and a clinical condition like milk fever. Here the animal body is unable to regulate body temperature or the heat regulatory mechanism fails to generate heat to compensate the heat loss from the body.

Signs of hypothermia: Shivering, chattering of teeth, cold extremities and skin on touch, and reduced pulse and respiratory rates are observed.

Hypothermia management: Place the affected animal in warm place or provide shelter to protect from rain, rub extremities and apply liniments if available, provide warm porridge if animal has appetite, inject warm DNS / NS, inject calcium preparations in the case of milk fever the temperature will automatically rise.

Pulse taking: Pulse is defined as the regular expansion and contraction of the arterial wall caused by the flow of blood through it at every heartbeat. Pulse gives information with regard to the cardio-vascular abnormalities. It is influenced by exercise, excitement, annoyance, relative humidity, environmental temperature. Pulse can be adapted from the number of heart beats per minute by using stethoscope in less manageable animals. The rhythm of pulse should also be noticed while taking pulse. The pulse rate can rise rapidly in nervous animals or those which have undergone strenuous exercise. In such cases the pulse should be checked again after a period of rest lasting 5 to 10 minutes [3,9].

Procedure how to examine and take pulse:

- Place the digits on the artery to be examined
- Applying gentle pressure until the pulse wave can be detected

Note the pressure or pulsation of the arteries felt on the finger digits. It is useful to be able to find out how fast the heart is beating. For example, it can help you decide whether colic is serious. An adult horse's heart beats more slowly than ours, especially when the horse is fit. It takes practice to find the pulse. There are several places where it can be felt. Using a watch with a second hand, count how many beats can be felt in a minute. Feel for it under the bone (mandible) at the side of the face [12]. Or feel for it behind the fetlock joint. Feel for it just above the hoof on the inside of the leg. It is useful to practice finding the pulse here because, if the horse has laminitis, this pulse will feel stronger. If you know what the pulse normally feels like here, it will help you recognize when it is different [12]. Count the number of beats per minute (counting should be done at least for 30 seconds and multiplied by 2); notice the quality and rhythm of pulse.

Method to record pulse:

- Hold the tail / limb.
- Locate the artery for recording pulse accordingly.
- Place the tip of the index / middle finger on the artery.
- Count the pulse for one minute and record it.

Factors influencing pulse:

- Species: different species of animal have different pulse rate, which is number of rise and fall of arterial wall per minute.
- Size: higher in small than in large animals.
- Age: higher in young than adult animals.

- 4- Sex: male slightly lower than female animal.
- 5- Parturition & Late stage of pregnancy: relatively more pulse rate
- 6- Exercise: increase pulse rate.
- 7- Ingestion of food: cause momentary increase in frequency of pulse.
- 8- Posture: pulse rate reduced about 10% when animal is recumbent than when standing [17,18].

Respiration taking: Respiratory movements can be observed at the right flank. Any change in the rate indicates respiratory involvement. Thoracic respiration is seen in animals suffering from acute peritonitis and abdominal respiration in pleurisy. Double expiratory movements are seen in emphysema in horses [3,14].

Types of respiration:

- 1. Costal respiration:** In this type of respiration thoracic muscles are mainly involved and the movement of the rib cage is more prominent. It is seen in dogs and cats.
- 2. Abdominal respiration:** This type of respiration is seen in ruminants viz cattle, goat, sheep and yak. Here the abdominal muscles are involved and movement of the abdominal wall is noticed.
- 3. Costo- abdominal respiration:** In this type of respiration muscles of both thorax and abdomen are involved so the movement of the ribs and the abdominal wall are noticed

The respiration rate is measured through counting of either contraction or expansion of the thorax and abdomen which can be observed during clinical examination. A method for respiration rate taking includes [4,9]:

- **Inspection:** Stand behind and to one side of the animal, and observe the movement of the thoracic and abdominal areas of the body.
- **Palpation:** Put one hand in front of the nostril, feel the exchange of the gas; or put one hand on the lung area or the thorax and feel the respiratory movements.
- **Auscultation:** Use stethoscope, listen to the respiration sound in the trachea or lung area.

Inspiratory or expiratory movements of the chest wall or flank can be counted. In cold weather, exhaled breaths can be counted. If the animal is restless the clinician should count the rate of breathing for a shorter period and use simple multiplication to calculate the respiratory rate in breaths/minute. Mouth breathing is abnormal in cattle and is usually an indication of very poor lung function or a failing circulation.

Visible mucous membrane: The mucous membrane in the eyes, mouth and vagina in the case of females can be examined to determine the health status of an animal. Examination of the mucous membrane should be done in natural light (sunlight) not in the lamplight. The abnormalities of color of mucous membrane are caused by different factors like *Pallor of the mucous membranes* may indicate anaemia caused by direct blood loss or by haemo-

lysis, A *blue tinge* may indicate cyanosis caused by insufficient oxygen in the blood, A *yellow colour* is a sign of jaundice, the mucosae may be *bright red* (sometimes described as being 'injected mucous membranes') in febrile animals with septicaemia or viraemia, Bright red colouration of the conjunctiva is often seen, for example, in cases of bovine respiratory syncytial virus infection. A *cherry-red* colouration may be a feature of carbon monoxide poisoning. A *greyish tinge* in the mucosae may be seen in some cases of toxemia – such membranes are sometimes said to be 'dirty'. High levels of methaemoglobin, seen in cases of nitrate and/or nitrite poisoning, may cause the mucosae to be *brown* coloured [3,9]. The normal colour of different species of animal is listed below table:

The color of mucous membrane may change occurs in various diseases as follow by the following [19]:

Anaemic mucous membranes:

- Blood loss anaemia.
- Parasitic infestations leading to haemolysis.
- Tumours or leucosis.
- Iron deficiency anemia.
- Long-standing infectious diseases.
- Exposure to X-rays and some medications.

Congested mucous membranes:

- High environmental temperatures and exercise.
- Any disease resulting in fever.
- Diseases of the heart, brain and its membranes.

Yellowish or icteric mucous membranes:

- Icterus of jaundice occurs due to increase of blood bilirubin concentration (blood parasites, leptospirosis, hepatitis, cholangitis, cholecystitis and cholangiohepatitis).
- Infectious anaemia and contagious pleuropneumonia of horses.
- Chronic gastric dilatation.

Cyanosed mucous membranes:

- Bluish discoloration of visible mucous membranes resulting from presence of reduced haemoglobin in blood capillaries.
- Myocarditis, pericarditis.
- Plant and mineral intoxications.

Swelling of mucous membranes: Inflammation of mucous membranes results in its swelling; in which case the mucous membranes may also be hot and tender (i.e. showing cardinal signs of inflammation). Marked swelling of conjunctival mucous membranes is characteristic of equine influenza. A slight degree of swelling is noticed in contagious pleuropneumonia of horse and cattle plague, anthrax and fowl diphtheria [19].

Capillary Refill Time (CRT)

Capillary refill time (CRT) is defined as "time required for re-

turn of color after application of blanching pressure to a distal capillary bed [20]. This is taken by compressing the mucosa of the mouth or vulva to expel capillary blood, leaving a pale area, and recording how long it takes for the normal pink colour to return. In healthy animals, the CRT should be less than 2 seconds. ACRT of more than 5 seconds is abnormal, and between 2 and 5 seconds it may indicate a developing problem. An increase in CRT may indicate a poor or failing circulation causing reduced peripheral perfusion of the tissues by the blood [8,9].

Methods how to examine mucous membrane by capillary refill time as follow:

- ❖ This is taken by compressing the mucosa of the mouth or vulva to expel capillary blood, leaving a pale area
- ❖ Recording how long it takes for the normal pink color to return.
- ❖ In healthy animals, the CRT should be less than 2 seconds.
- ❖ A CRT of more than 5 seconds is abnormal, and between 2 and 5 seconds may indicate a developing problem

Physical body condition: Body condition scoring is an important management practice used by producers as a tool to help optimize production, evaluate health, and assess nutritional status. Different scores can be given for individual animal and can further classified as normal, fatty, lean/thin, emaciation [9].

Condition Score 1: Very thin: This animal's skeletal structure is very prominent. Notice the deep depressions next to the spine, between the pelvis and rib cage, between the hooks and pins, and around the tail head.

Condition Score 2: Thin: The animal's skeleton is still very apparent. The individual spinous processes are clearly visible, but there is a small amount of fat tissue over the spine, hooks, and pins.

Condition Score 3: Medium (Normal body condition): The animal appears smooth over the spine, ribs, and pelvis and the skeletal structure can be easily palpated. The hooks and pins are still discernible, with a moderate, rather deep depression between the pelvis and rib cage, hooks and pins, and around the tail-head.

Condition Score 4: Fat: There are no spinous processes detectable, and no depression in the loin area, which gives the top-line of the animal a flat, tabletop appearance. The ribs can no longer be felt, and the pelvis can only be felt with firm pressure. The hooks and pins have a rounded appearance due to areas of fat covering.

Condition Score 5: Very Fat: The animal appears rounded and smooth with a square-shaped appearance, because of the amount of fat filling in the loin. The skeletal structure is no longer visible, and can only be palpated with excessive pressure.

Normal demeanor

When, on being approached, an animal makes a normal response to external stimuli, such as movement and sound, the demeanor is said normal (bright). Normal reaction under these circumstances may consist of elevating the head and ears, turn-

ing towards and directing the attention at the source of stimuli, walking away and evincing signs of attack or flight [8].

Abnormal demeanor: Behavioral change/ response to external stimuli. The Abnormal demeanors in domestic animals are as follow list [8,9]

- Decreased response (depression): dull (apathetic); dummy state; comma.
- Excitation or increased response: apprehension (mildly anxious); restlessness; mania; frenzy.
- Posture: It denotes the anatomical configuration when they remain in stationary situation. How does it stand? How does it sit? How does it lie?
- Gait: It indicates about the locomotory process of an animal.
- Body conformation: shape and size of the different body regions relative to other regions

Regional or systematic clinical examination

Clinical Examinations of the head and neck region: Before handling the head a further *visual inspection and observation* of the head and neck is advisable as whether the following question are present [9]:

- ❖ Movements of head and neck – normal or abnormal
- ❖ Carriage of head – normal or tilted,
- ❖ Can the animal see?
- ❖ Can the animal hear?
- ❖ Ocular or nasal discharge,
- ❖ Salivation – normal or excessive,
- ❖ Ability to prehend, masticate and swallow food
- ❖ Mobility of the neck.

The perspective of this examination is to identify pale and discolored mucous membranes; assess problems of oral cavity and deranged appetite. The following points are to be considered:

- ❖ Visible mucous membrane
- ❖ Eyelids, conjunctivae and eyes
- ❖ Nasal regions and nasal mucous membrane
- ❖ Prehension, mastication and deglutition
- ❖ Salivation
- ❖ Teeth eruption

Procedure:

- Visible mucous membrane examined by visual inspection to note the presence of lesions, discharge, glaucoma, nystagmus.
- Examine the nose and nasal sinuses; lesions, discharges should be noted by percussion, palpation
- Examine the mouth and appetite; oral lesions, salivation,

feed intake should be noted. The rigidity of tetanus, the cunning leer or maniacal expression of rabies and acute lead poisoning are cases in point.

The symmetry and configuration of the bony structure should be examined. Doming of the forehead occurs in some cases of congenital hydrocephalus and in chondrodysplastic dwarfs, and in the latter there may be bilateral enlargement of the maxillae. Swelling of the maxillae and mandibles occurs in osteodystrophia fibrosa; in horses swelling of the facial bones is usually due to frontal sinusitis; in cattle enlargement of the maxilla or mandible is common in actinomycosis. opisthotonos is an excitation phenomenon associated with tetanus, strychnin poisoning, acute lead poisoning, hypomagnesemic tetany, polioencephalomalacia and encephalitis [3]. Visible discharge should be noted; protrusion of the eyeball, as occurs in orbital lymphomatosis, and retraction of the bulb, as occurs commonly in dehydration, are important findings; spasm of the eyelids and excessive blinking usually indicate pain or peripheral nerve involvement; prolapse of the nictitating membrane usually characterizes central nervous system derangement, generally tetanus [3]. Excessive salivation or frothing at the mouth denotes painful conditions of the mouth or pharynx or is associated with tremor of the jaw muscles due to nervous involvement. Swellings below the jaw may be inflammatory, as in actinobacillosis and strangles, or edematous, as in acute anemia, protein starvation or congestive heart failure.

Examination of skin and appendages

The skin provides protection against minor physical injuries supports hair growth and offers some defence against microbial invasion. The condition of the skin is a reflection of the general health of the animal, deteriorating in cases of ill health, ill thrift and debility. In some conditions, such as jaundice, the skin may provide through discolouration direct diagnostic evidence of a specific disease process. In other conditions, such as parasitism or severe mineral deficiency, a nonspecific general deterioration of skin health may occur causing a greater number of hairs than normal to enter the telogen or resting phase and a delay in their replacement, leaving the coat in poor condition with little hair. Sebaceous secretions may be reduced, allowing the skin to become abnormally dry and inflexible and less able to perform its normal defence role in an already debilitated animal. In other cases, sebaceous secretion increases causing the skin to have either a greasy or a dry seborrheic, flaky Appearance [9]. Structures or parts associated with skin as its appendages are hoofs, hairs, horns, quills, claws, nails, sebaceous glands and sweat glands. Discrete skin lesions range in type from urticarial plaques to the circumscribed scabs of ringworm, pox and impetigo. Diffuse lesions include the obvious enlargements due to subcutaneous edema, hemorrhage and emphysema. Enlargements of lymph nodes and lymphatics are also evident when examining an animal from a distance [3,4].

The perspective point to assessing the condition of skin and coat to identify clinical signs of skin lesions such as:

- Condition of the coat
- Elasticity of the coat
- Pruritus

- Primary and secondary skin lesions
- Dermatitis
- Hyperkeratosis or parakeratosis
- Presence of ectoparasites.

Discoloration of the skin may arise due to anaemia, cyanosis, jaundice, hyperaemia. In febrile conditions hair may be erect and in all chronic diseases with disturbances in nutrition, hair become rough, lusterless dry and coarse. Alopecia (Loss of hair) may occur due to diseases like ring worm, scabies, eczema, Iodine and Vit A deficiencies, Procedure: Examine the skin and coat: grasp the skin of the upper part of the body and notice the elasticity, visual inspection of the condition of the coat and presence of skin lesions should be noted. the abnormalities which occurred from skin due to disease and others are summarized in (Table 7).

Examinations of the thoracic cavity

Examination of the thoracic cavity guide to show the regional anatomy of the lungs and the heart, and perform physical examination of the lung and the heart area. Regional anatomy of the lungs -locate the lung area. The lung is located on the external surface of the thoracic region by forming an imaginary triangle by using the points at the angle of the scapula, olicranun process and the second intercostals space from the last [8,9].

Physical examination of the thorax (lung area)

- Inspection -note respiratory movements
- Palpation -check the presence of pain by applying pressure
- Percussion -notice resonant sound
- Auscultation -note bronchial sounds (trachea and anterior part of the lungs) and alveolar sounds

Palpation

Chest palpation can be useful to identify thoracic pain which may be caused by rib fractures and pleuritis. Gentle pressure should be applied to the thorax using the palm of the hand and the animal observed for a pain response. The entire thorax should be explored in a systematic manner to identify focal areas of pain. In addition to pain, subcutaneous emphysema may be detected as a spongy sensation which may be accompanied by crackling noises. This clinical sign is sometimes seen in outbreaks of respiratory syncytial virus (RSV) and is caused by rupture of emphysematous bullae in the lungs [9].

Auscultation

During auscultation, the stethoscope should be moved systematically to cover the whole of thoracic lung fields with the aim of identifying any abnormal sounds present, their location and their occurrence in relation to the respiratory cycle. The location of an abnormal sound is deduced from the position of maximal intensity. Particular attention should be given to the apical lobe if bacterial pneumonia is suspected or the diaphragmatic lobe if lungworm is suspected [3,9].

Regional anatomy of the heart -locate the heart area

The heart is suspended by great vessels and located on the

left median mediastinum of ventral thorax. The left side of the heart apex reaches the chest wall. After locating the heart the following should be noted through physical examination (palpation, percussion, auscultation) the following would be examined [9,16,19].

- Heart rate
- Abnormal variation in heart rate
- Heart sounds
- Normal heart sounds (dub-lab)
- Adventitious heart sounds (murmurs)
- Pericardial frictional sounds
- Venous pulsation (jugular pulsation)

Anatomical locations of valves:

- Mitral valves:

Examined on the left side in the 5th intercostals space, 4 inches above the sternal extremity of 5th rib

- Tricuspid valves:

Present on the right side in the 3rd intercostals space and 3 inches above the sternal extremity of the 4th rib.

- Aortic semi-lunar valve:

Present on the left side in the 4th intercostals space level with the shoulder point [16].

Clinical examinations of the abdominal and associated digestive organs

Objective: to undertake clinical examination of the abdomen and identify disturbances of the digestive system. The examination of abdominal of ruminant as following [9]:

The examination of rumen is performed by inspection, palpation, percussion and auscultation; stomach tube can be used as well. In bloat case, the left side would be bulged, and the motility would be decreased.

The examination of reticulum: TRP by back grasp, below pole lifting, up and down hill leading, hand palpation.

The examination of omasum: done by exploratory puncture. The examination of the displacement of abomasums is done by inspection, palpation, and auscultation. The disorder of stomach can be detected by taking stomach contents sample: Insert the stomach tube or nasal tube after cleaning, disinfecting and lubrication or trocarisation.

Rectal examination of the internal abdominal structures: cut and smooth the nail; wear shoulder long glove; lubricate; cone shape of the fingers; insert in rotating way; notice: the hand cannot open, or even grasp organs inside. It's necessary or possible to use tranquilizer to reduce the sensitivity of the rectum in horse. In bloat case, the pressure in the abdomen would be very high, so it would be difficult to insert the hand inside.

Conditions occurring in ruminant [9]

- *Reticulum* – actinobacillosis/actinomycosis infection of

the oesophageal groove, neoplasia of the oesophageal groove, reticular abscess, reticuloperitonitis.

- *Rumen* – secondary free gas bloat, frothy bloat, ruminal acidosis, cold water ruminal atony, neoplasia of rumen, rumen collapse syndrome, rumen foreign body, rumen impaction, vagal indigestion.
- *Omasum* – omasal impaction.
- *Abomasum* – right abomasal dilatation (RDA) and torsion, abomasal rupture, left abomasal displacement (LDA), abomasal impaction (dietary), abomasal ulceration, abomasal neoplasia.
- *Small intestine* – Johne's disease, salmonellosis, winter dysentery, bovine virus diarrhoea, gut tie (intestinal strangulation), foreign body intestinal obstruction, intussusception, neoplasia of small intestine, prolapse of the intestines through the mesentery, torsion of the root of the mesentery, small intestine rupture post calving, spasmodic colic
- *Large intestine* – caecal dilatation and torsion.
- *Rectum* – rectal perforation, rectal prolapse
- *Abdomen/peritoneum* – ascites, uroperitonium, fat necrosis, focal or diffuse peritonitis, acute pneumoperitonium.
- *Liver* – abscessation, hepatitis, cholangitis.

Auscultation of the rumen help in recognizing the rate, quality and rhythm of the normal ruminal movements. The ruminal movements arise from the churning action of the organ. The rate of ruminal movement in health animals is 2-5 in cattle, 3-6 in sheep, 2-4 movements every two minutes in goats. It decreases in cases of rumen atony; diseases of reticulum, omasum and abomasum; impaction and late stage of tympany; also in severe feverish conditions and in traumatic reticuloperitonitis. Increased rate is seen in early stage of digestive disorders such as tympany and the form of vagus indigestion with hypermotility [19].

Absence of movements occurs in the following [9,16]:

- ❖ Severe dilation of the rumen with gases (tympany) or with food (impaction).
- ❖ Toxic conditions.
- ❖ The quality could be described as strong in healthy animals, weak in cases of ruminal atony and very strong as in early stages of digestive disorders such as tympany and vagus indigestion with hypermotility.

Clinical Examinations of the feces

Objective: To see Character of the feces and abnormal constituents in feces

Procedure:

- Observe the surface of the faeces, where mucus and blood always exists
- The colour of the faeces surface, the odour of the feces
- Fishy smell generally indicates bleeding, and abnormal constituents in feces [9].

Examination of the urogenital system

In the horse and cow only the left kidney is accessible for palpation from the rectum. The right kidney lies further forward and cannot be reached by the hand. In the horse, the left kidney extends back to about four inches behind the last rib and its inner border is separated from the median line by about the same distance. In ruminants, it is loosely suspended below the lateral processes of the first lumbar vertebrae. Sometimes it may be shifted over to the right side. In dogs the kidneys lie in the lumbar region. The manifestations of the urinary tract diseases include abnormal constituents and appearance of urine, changes in the volume of daily urine flow and frequency, pain and dysuria and uremia [19].

Objective: To identify the regional anatomy, undertake clinical and physical examination of urinary system and assess urinary abnormalities, perform clinical examination of female and male reproductive organs as well as the mammary glands and teats. Identify the anatomic structure of the kidney on live animal: the left kidney is located ventral of the transverse process of the 3rd to 5th lumbar vertebrae. The kidney can be examined by inspection, external palpation, rectal palpation, and urinalysis. The examination of the urinary bladder is performed by stimulating the sense of urination from the lower part between the two hind legs on small animals or rectal palpation on large animals. Attention should be paid to the paralysis of the bladder and retention of urine and rupture. Clinical examination of male genital organs- visual inspection and palpation are employed to examine the testes, prepuce and the penis after withdrawing from the prepuce. Here orchitis, cryptorchidism, scrotum hernia, obstruction of urethra by calculi, phimosis, paraphimosis, inflammation of the prepuce, testes and penis are noted [3,5,9].

Clinical examination of female genital organs- visual inspection and palpation of the vaginal region, use of vaginal speculum to examine the inside of vagina and intra-rectal examination of the cervix, uterus and ovaries would be performed [3,8,9].

- Take the sample of urine examine through physical methods
- Fresh urine is collected with test tube after stimulating urination by palpating the perineal region or by inserting catheter
- Clinical examination of the mammary glands and meat-inspection and palpation to detect the presence of swelling and lesions on the teats/decrease in size and shape, any discharge, temperature of the udder, consistency, and pain reactions are performed
- Clinical examination of milk samples: after collecting the milk samples in clean test tubes one can apply different physical and laboratory examinations
- For the gross examination of the milk, the change of the color, odor, viscosity and flakes in the milk should be identified.

Palpation

External palpation of the kidneys in the horse is not performed due to the considerable thickness and rigidity of the ab-

dominal wall. Kidneys can be palpated through the abdominal wall in the majority of small and medium sized dogs. In sheep, goat and pigs, external palpation of the kidneys is of little value. In the cat, kidneys are large and pendulous therefore easily palpable. Identification is aided by recognition of the hilus on the attached border. In cattle, rectal palpation may help in examination of the kidneys [19].

Examinations of the nervous and musculoskeletal system

Objective: For examination and detection of clinical signs of various problems associated with the nervous and musculoskeletal systems.

Procedure:

The examination of the nervous system:

1. Observe the behavior of the animal
2. Note responses of the animal while applying different stimuli
 - Examine the brain by corneal reflex, the pupil reflex
 - Examine the spinal cord of the neck and thorax by withers reflex
 - Examine the spinal cord of the back part by applying hoof stimuli and anus stimuli
 - Move the animal to and from or uncomfortable position to examine the locomotors
3. Examine the joints long bones and different muscles: arthritis, dislocation of the joints, rickets or osteocalcin, muscular atrophy, central or peripheral origin paralysis [3,9].

Examination of skeletal muscle of an animal

The musculoskeletal system is composed of the bones of the skeleton, joints, ligaments, muscles and tendons. In addition to the nervous system, the musculoskeletal system is important for the maintenance of posture and for locomotion. *The aim of the clinical examination is to identify the site and the cause of the lameness.* Identification of the affected limb, the site of the lesion within the limb and assessment of the severity of the lesion, are primary aims of the initial part of the examination. Localization to a foot or an upper limb problem may be possible by observation. Abnormalities of posture and gait, weight bearing and gross swellings, wounds and deformities should be noted [9]. Posture means the anatomical configuration of animals when they remain standing. And sitting in other words, it means how the animal stands and sits. Postural abnormalities can be of great help in making a diagnosis.

Gait: Gait is denotes the locomotor processes of the animals. A locomotor disturbance of the animal is judged by the movements (Walking, running, trotting, circling etc.) There are certain diseases, which interfere with the process of locomotion. The gates of the dog are commonly used patterns of locomotion that can be divided into two main groups: symmetric and asymmetric. With symmetric gaits such as the walk, trot, and pace, the movement of the limbs on one side of the dog's body repeats the mo-

tion of the limbs on the opposite side with the intervals between foot falls being nearly evenly spaced. With asymmetric gaits such as the gallop, the limb movements of one side do not repeat those of the other and the intervals between foot falls are unevenly spaced. When considering gaits, one full cycle is referred to as a stride [21].

Examination of superficial lymphnodes of animals

Objectives: to compared each paired node for size and consistency with the contralateral node.

Method: Grossly enlarged lymph nodes may have been seen during observation of the patient before it is handled. Observation and palpation is possible when the animal is restrained.

Anatomical Location of lymphnodes (LN)

Lymph nodes are round or bean-shaped structures that are widely distributed throughout the body. Imbedded in connective tissue or fat, they are concentrated in the cervical, axillary, and inguinal regions – the neck, armpits, and groin, respectively. They are typically less than ½ inch in length, depending on the size of the animal. The lymph nodes filter the lymph before returning it to the veins [2,9].

Submandibular lymph nodes: situated and are palpable on the medial aspect of the ‘angle of the jaw’ where the horizontal and vertical rami of the mandible meet. (Normal size is 1.5 to 2 cm).

Prescapular lymph nodes: It lies subcutaneously and underneath the cutaneous muscle just anterior to the shoulder joint (Normal size 1 cm × 3.5 cm)

Axillary lymph nodes: Found on each side of the chest in the armpit area. Normally only palpable in young calves without heavy muscling (Normal size 1.5 cm)

Popliteal lymph nodes: These nodes are found surrounded by dense muscle tissue immediately behind the stifle. It found on each rear leg on the opposite side of the knee. They are relatively superficial and easy to feel (normal size 1-1.5 cm)

Inguinal lymph nodes: These are usually palpable as a small group of fairly mobile and firm structures adjacent to the inguinal canal. (Normal size 0.5 cm)

Supramammary lymph nodes: These are normally readily palpated on the caudal aspect of the udder just above the upper limit of the mammary glandular tissue, normal size 2.5 cm [8,23].

PREPARATION AND ADMINISTRATION OF MEDICAMENTS

Drug dosage form

The body condition of a livestock is generally assessed by visual observation. The references to an animal being too thin, in good flesh, or obese all relate to the animal’s weight. Therefore, the weight of an animal can be used as a measurement tool to determine its well-being, or the presence of problems which may threaten the health of the horse. Several methods can be used to determine the body weight of livestock in an approximate scale. The domestic animals body weight estimation equation as following [24].

*Equation of equine body weight estimation:

$$\text{Weight (kg)} = (\text{girth measurement in cm})^2 \times (\text{length measurement in cm})$$

11,900

*Equation of Bovine body weight estimation:

$$\text{Live weight in lbs.} = \text{Length} \times \text{Girth square}$$

300

Because of the variety of dosage forms in veterinary medicine and the diversity of animal and bird species treated, drug or dosage delivery sometimes requires the development of specific devices to ensure fast, safe, effective and low cost efficient treatment. Formulation of Drug Dosage Forms of Animals are listed as following [25].

Oral dosage forms: Refers to administration of drug through the mouth. The most commonly used preparations are solid oral dosage forms such as tablets, capsules, granules, powder, paste and boluses.

Parenteral dosage forms: the most common parenteral dosage forms are stable aqueous solutions and subcutaneous implants.

External dosage forms

- Ointment- semisolid preparation for external application.
- Cream- a viscous semisolid, consisting of oil in water emulsion or water in oil emulsion.
- Dusting powder e.g., popular antibacterial agent applied on animal wounds.
- Lotion- an aqueous solution or suspension for local application.

Spray- a drug applied in liquid form by pressure.

Inhalation dosage forms: gaseous and volatile liquid anaesthetic agent (drugs), given by inhalation, e.g., Halothane

Routes of drug administration

Medications are administered to cattle by injection for a variety of reasons. For example, vaccines (biological) are injected to prevent disease, and antibiotics or anthelmintic may be injected to treat bacterial or parasitic infections, respectively. Other medications may be given by injection for supportive medical care, to relieve pain or to enhance production. Injection may be the best, or the only, route of administration for a particular medication [23].

The route of drug administration in domestic animals are summarized as following form [8,12,22,23 and25]: **Oral administration:** There are large numbers of pharmaceutical preparations available for oral administration. Solid dosage forms (powders, tablet, capsules, pills, etc.) and liquid dosage forms (syrups, emulsion, mixture, drench, electrolytes, etc.)

Parenteral administration (IV, IM, SC, Id, epidural, subconjunctival): It refers to a drug administration by injection directly in to the tissue fluid or blood without having to cross the intestinal mucosa. **Intravenous route (IV):** Gives swift, effective and highly predict-

able blood concentration and allows rapid modification of dose and is used for emergency treatment.

In most animals (horse, cattle, sheep and goat) usually given through **jugular vein**, in **pig-ear veins**, in the dog and cat-**cephalic vein** and recurrent **tarsal vein**.

Intramuscular (IM) route: Absorption occurs either haematogenous or via lymphatic and is usually fairly rapid except for long acting preparation.

Subcutaneous (SC) route: Preferred when slow and continuous absorption of drug is required. The injected drug disperses through the loose connective tissues. They dissolve in tissue fluid before it can enter either capillaries or lymphatic.

Intradermal route (ID): Used for testing hypersensitivity test and for vaccination.

Epidural route: Refers to deposition of drug up on or outside the dura matter. E.g., Introduction of local anesthetics between the first and second coccygeal vertebra to eliminate straining.

Subconjunctival: Disposition of a pharmaceutical preparation beneath the conjunctiva.

Topical or local application: It refers to external application of drug to the body surface for localized action at accessible site, such as skin, eyes, body orifices, body cavity.

Drug dose calculation

If drugs are used incorrectly, disease organisms can build up resistance making drugs ineffective. This usually happens from under dosing or overdosing drugs. It is best to calculate the correct dosage based upon the weight of each animal determined by using a scale or estimated by using heart girth measurement [22,24]. Dose is the quantity of the drug to be administered at one time and expressed in mg/kg or IU/kg.

Dose: $Body\ weight \times Dose\ Rate\ Concentration$

- How to load a syringe during taking drug [12] Be sure the needle is firmly attached.
- Draw some air into the syringe by pulling back the plunger.
- Turn the bottle of medicine upside-down, insert the needle through the centre of the rubber stopper and slowly inject air into the bottle.
- Now draw the medicine into the syringe.
- Keep the bottle above the syringe so any air bubbles in the syringe go to the top.
- Push the plunger carefully so the air comes out.
- Now see if the right amount is in the syringe (the top of the plunger should be on the line for the proper dose).
- Withdraw more medicine or squirt some back into the bottle until the right amount is in the syringe.

ACKNOWLEDGEMENT

First and Above all, I would like to praise Almighty God for

providing me this opportunity and granting me the capability to proceed successfully.

Secondly, I would like to thank the ICT center of Jimma University College of Agriculture and Veterinary Medicine for their guide and support me by internet and computer access.

REFERENCES

1. Fundamentals of Veterinary Medicine, Clinical Examination UNIT2: 2006.
2. Kahn CM Merck Veterinary Manual. 10th edn. Whitehouse Station, Merck, NJ, USA. 2010.
3. Radostits OM, Gay CC, Hinchcliff KW, Constable PD. Veterinary Medicine: A textbook of the diseases of cattle, sheep, pigs and goats, horses. 10th edn. St. Louis: Saunders (Elsevier). 2007.
4. Radostits OM, Mayhew IG, Houston DM. Veterinary clinical examination and diagnosis. London: WE Saunders. 2000.
5. Ajello SE. The Merck Veterinary Manual, 8th edition, Published by Merck and Company, INC, USA. 1998.
6. Ballard B, Rockett J. Restraint and Handling for Veterinary Technician and Assistants. Delmar, Cengage Learning, USA. 2009.
7. Frandson RD, Wilke WL, Fails AD. Anatomy and Physiology of Farm Animals. 7th edn. Wiley-Blackwell, USA. 2009.
8. Duguma A. Practical Manual on Veterinary Clinical Diagnostic Approach. J Vet Sci Technol. 2016; 7: 337.
9. Jackson P, Cockcroft P. Clinical Examination of Farm Animals. Blackwell Science, UK. 2002.
10. Sakas PS. Basic pet bird care. Essentials of Avian Medicine: A Guide for Practitioners, Second Edition. American Animal Hospital Association Press Publ. Niles, IL. 2002.
11. Practice for the Care and Handling of Equines. 2013.
12. Hadrill D. Horse healthcare. A manual for animal health workers and owners. 2002.
13. Charles M, Eddy GM. Restraint of domestic, laboratory and wild animals: A Manual for Veterinary Students, Practitioners and Animal Handlers. 2003.
14. Kelly WR. Veterinary Clinical Diagnosis. 2nd edn. Bailliere Tindal & Cassell, London, UK. 1974.
15. Riviere JE, Papich MG. Veterinary Pharmacology & Therapeutics. 9th edn. Wiley-Blackwell, USA. 2001.
16. Chauhan RS, Agarwal DK. Text book of Veterinary, Clinical and Laboratory Diagnosis. 2nd edn. Jaypee Publishers, New Delhi, India. 2008.
17. Factor affecting pulse rate.
18. Fulwider WK. 8 Dairy Cattle Behaviour, Facilities, Handling, Transport, Automation and Well-being. Livestock Handling and Transport: Theories and Applications. 2014; 116.
19. Internal medicine: website available at: <http://www.aun.edu.eg/developmentvet/Internal%20medicine/amly3.htm>
20. Gorelick MH, Shaw KN, Baker MD. Effect of ambient temperature on capillary refill in healthy children. Pediatrics. 1993; 92: 699-702.
21. Nunamaker DM, Blauner PD. Normal and abnormal gait. Textbook of small animal orthopaedics. 1985; 1083-1095.
22. Dawson L, J Allen, B Olcott. Meat Goat Herd Health Procedures and Prevention. In: T.A. Gipson, R.C. Merkel, K. Williams and T. Sahlh

- (Eds.). Meat Goat Production Handbook. Langston University. 2007; 65-96.
23. Griffin Dicky D, Smith David R, Grotelueschen Dale M. "G98-1351 Proper Injection Procedures for Cattle". Historical Materials from University of Nebraska-Lincoln Extension. 1998; 349.
24. National Veterinary Drug Formulary. Second Edition Department of Livestock, Ministry of Agriculture & Forests. 2013.
25. Tiwari S, Mitkare A, Bhangale P. Veterinary dosage forms: review. Int J of App Pharm. 2014; 6: 20-29.

Cite this article

Abdisa T (2017) Review on Practical Guidance of Veterinary Clinical Diagnostic Approach. *J Vet Med Res* 4(4): 1085.