

Review Article

Review on Equine Epizootic Lymphangitis and its Impact in Ethiopia

Tagesu Abdisa*

Jimma University College of Agriculture and Veterinary Medicine, School of Veterinary Medicine, Ethiopia

*Corresponding author

Tagesu Abdisa, Jimma University College of Agriculture and Veterinary Medicine, School of Veterinary Medicine, P.O Box 307, Jimma, Oromia, Ethiopia.
Phone: 251933681407, Email: abdisatagesu@gmail.com; tagesuabdisa@yahoo.com

Submitted: 18 May 2017

Accepted: 12 June 2017

Published: 14 June 2017

ISSN: 2378-931X

Copyright

© 2017 Abdisa

OPEN ACCESS

Abstract

Epizootic lymphangitis is one of the major chronic contagious disease of equine which cause pyogenic, ulcerative, and generalized spreading pyogranulomatous, multifocal dermatitis with lymphadenitis, and a cord like appearance of the subcutaneous lymphatic vessels. It is caused by dimorphic fungus, *Histoplasma capsulatum* var. *farciminosum* species. Equine Epizootic lymphangitis can be seen commonly in the extremities along front and hind legs, chest wall, belly and the neck. The disease is endemic in some countries of West, North, North east Africa, East Africa (Ethiopia) and Asia including India, Pakistan and Japan, where it is mostly diffused in areas characterized by humid and hot climates. The incidence of epizootic lymphangitis disease will become high only when large numbers of animal's population were collected together such as seen in military situations or congregation for racing, in addition mortalities were low. The mode of transmission of Epizootic lymphangitis disease includes transmission by direct or indirect contact of *Histoplasma capsulatum* var. *farciminosum* with traumatized skin, by biting flies, by ticks or by inhalation of fungus. There are three forms of epizootic lymphangitis disease in horse exist in Ethiopia: cutaneous, ocular, and respiratory. The cutaneous form is most common, causing a chronic, suppurative, ulcerating pyogranulomatous dermatitis and lymphangitis. Diagnosis of epizootic lymphangitis depends on the clinical sign, history of animals and laboratory confirmation. And, differential diagnosis which confuse with different disease for instance; The skin form of the disease may be confused with the skin form of glanders, ulcerative lymphangitis, indolent ulcers sporotrichosis, strangles and cutaneous lymph sarcomas. Treatment of Epizootic lymphangitis is mandatory to prevent spreading of the infection, whereas for disease control, culling infected horses and adoption of hygiene measures (e.g., cleaning and disinfection) and insects control are required. Control of this disease should be by vaccination and appropriate wound management with administration of iodine, intravenous injection of sodium iodide and amphotericin B. The objective of this paper is to overview the causative agent, diagnosis, control and prevention of equine Epizootic Lymphangitis.

Keywords

- Epizootic lymphangitis
- *Histoplasma capsulatum*
- Vaccination
- Contagious disease
- Amphotericin B.

INTRODUCTION

Ethiopia has the largest equine population in Africa and eighth in the world [1]. The equines are an estimated 80% of the world equine population, 90% million equine, is found in the developing world, including 97% of mules, 96% of donkeys and 60% of horses and most of these will be used for work [2]. It is reported that two million horses, 0.36 million mules and seven million donkeys comprise the working equine population in Ethiopia and this represents the largest population of equine in Africa [3].

Equines play an important role in the transport of farm product, fodder, fire wood, agricultural inputs, construction and waste materials [4]. Working equids have a direct impact on the lives of rural people by reducing the transport burdens of water, fuel, wood and goods [5], transporting people and in some areas

for agricultural purposes [5-7]. Although, Ethiopia has large number of Equines, the productivity of these animals is decreased by the infectious and non-infectious disease. Disease and health problems affecting working equids and their productivity in Ethiopia have been previously documented and include harness-related wounds and sores, colic, epizootic lymphangitis, and African horse sickness [8-12]. There is, however, little information on working equids-owners' perceptions and prioritization of these disease and health problems in Ethiopia, or elsewhere. In two participatory studies in Ethiopia, the most frequently encountered problems were respiratory problems, colic, musculoskeletal and hoof problems, back sores and Equine epizootic lymphangitis [13,14]. This paper is focused on the most common and series disease which cause decreasing the population and productivity of equine in Ethiopia and also the treatment of Epizootic lymphangitis by traditional way.

One of the infectious diseases which influence on the health and productivity of equine is epizootic lymphangitis, which cause inflammation of regional lymph nodes. Epizootic lymphangitis is a chronic, contagious, disease of horses, donkeys and mules which can infect humans, characterized clinically by a pyogenic, ulcerative, and generalized spreading pyogranulomatous, multifocal dermatitis with lymphadenitis, and a cord like appearance of the subcutaneous lymphatic vessels (lymphangitis) were detected [15]. It was seen commonly in the extremities along front and hind legs, chest wall, belly and the neck. Moreover, it can also be detected as an ulcerating conjunctivitis of the palpebral conjunctiva with excessive ocular serious discharge, or rarely as a multifocal pneumonia [16].

The organism might also invade open fresh or non-fresh lesions including ruptured strangles abscesses and male castrated wounds [17]. The disease has been called pseudofarcy or pseudoglanders. Moreover another synonym is Equine Histoplasmosis, Histoplasmosis Farciminosi, Pseudoglanders, African Farcy, Equine Blastomycosis, and Equine Cryptococcosis. Equine AIDS which may be a more accurate name for the disease [16,17]. In Ethiopia, the local name of epizootic lymphangitis termed as 'biichee fardaa' in Afaan Oromoo. The OIE classify Epizootic lymphangitis as a list B disease [18].

The disease was results from infection by a dimorphic fungus, *Histoplasma capsulatum* var. *farciminosum*. Which were also known as *Cryptococcus farciminosus*, *Zymonema farciminosus* and *Saccharomyces farciminosus* [15]. HCF (*Histoplasma capsulatum* var. *farciminosum*) is a dimorphic saprobic fungus causing epizootic lymphangitis (EL) in horses, donkeys and mules. This fungus is endemic in some countries of West, North, Northeast Africa, and Asia including India, Pakistan and Japan, where it is mostly diffused in areas characterized by humid and hot climates [17]. The organism exists as yeast in animal tissues and a saprophytic mycelium in the environment, in addition the disease has been reported in camels, cattle and dogs, furthermore experimental infections have been established in mice, guinea pigs and rabbits [16]. The mode of transmission of the disease is not well established. Nevertheless, direct contact with infective materials through injured skin or through cutaneous abrasions is the most common mode of infection. However, the injured skin is either infected directly by contaminated pus, nasal or ocular discharge or indirectly by soil or contaminated harnesses, grooming instruments, feeding and watering utensils, wound dressings or flies [19].

The disease is more common in the tropics and subtropics regions, than in temperate areas [16]. It has been shown that warm, moist conditions always allow the organism to survive in the soil for months. Furthermore, the disease was mostly sporadic. However, the incidence will become high only when large numbers of animal's population were collected together such as seen in military situations or congregation for racing, in addition mortalities were low [19].

LITERATURE REVIEW

General description of equine epizootic lymphangitis

Epizootic lymphangitis, grouped as a list B disease of the Office International des Epizootics, was first described in 1873

by Rivolta as a chronic infection of horses, mules and donkeys caused by the thermally dimorphic fungus, *Histoplasma capsulatum* var. *farciminosum*, and are characterized clinically by a spreading, suppurative, ulcerative pyogranulomatous dermatitis and lymphangitis. The organism has also been classified by the genus name *Zymonema*, *Cryptococcus*, *saccharomyces* or *Blastomyces* [20,21].

Aetiology

The causative agent, *Histoplasma capsulatum* var. *farciminosum*, is a thermally dimorphic fungus. *Histoplasma farciminosum* was formerly described as an independent species, but this assessment has been changed and it is now considered to be a variety of *H. capsulatum* due to the close morphological similarities of both the mycelial and yeast forms [22]. Antigenically, *H. capsulatum* var. *farciminosum* and *H. capsulatum* var. *capsulatum* are indistinguishable. However the latter is the cause of disseminated histoplasmosis, is endemic in North America and has a wide host range [23]. Classically, members of the genus *Histoplasma* have been classified into three separate varieties, *H. capsulatum* var. *capsulatum*, *H. capsulatum* var. *duboisii*, and *H. capsulatum* var. *farciminosum*, defined by host species and pathogenesis [24].

However, *Histoplasma spp.* have more recently been grouped into eight clades on the basis of multilocus sequence typing of isolates combined with the geospatial distribution of their sources [25]. *H. capsulatum* var. *farciminosum* has long been considered an equine-specific pathogen, but the application of molecular biology techniques has identified a broader host and geographic range for *H. capsulatum* var. *farciminosum*, with clinical cases being reported in dogs, badgers and even humans [26-28]. The phylogeny of *Histoplasma spp.* has been examined using a range of different gene loci [25,26,28,29].

As it has been frequently reported for fungi, sequence variation in the internal transcribed spacer (ITS) region of the rRNA operon provides a resolving power sufficient to discriminate between closely related species and variants and can contribute to the design of specific PCR-based detection protocols [28,30-32]. Isolates and/or sequences of both equine and human origin from Africa are underrepresented in studies on the phylogeny of histoplasmas [33,34] which is at odds with their prevalence in these regions [35,36]. Phylogenetic analysis of a few historic cultures of specimens from equine clinical cases has been described [28,32], but no studies have reported the application of PCR to detect *H. capsulatum* var. *farciminosum* directly in clinical specimens. DNA sequences of four protein-coding genes have been analyzed to elucidate the evolutionary relationships of *H. capsulatum* varieties. This indicated that *H. capsulatum* var. *farciminosum* is deeply buried in the branch of SAm Hcc group A, (H60 to -64, -67, -71, -74 and -76), looking as if it were an isolate of South American *H. capsulatum* var. *capsulatum* [37].

Histoplasma capsulatum is an ascomycetous fungus closely related to *Blastomyces dermatitidis*. It is potentially sexual, and its sexual state, *Ajellomyces capsulatus*, can readily be produced in culture, though it has not been directly observed in nature. As mentioned above, *H. capsulatum* groups with *B. dermatitidis* and the South American pathogen *Paracoccidioides brasiliensis* in the recently recognized fungal family Ajellomycetaceae. It is dimor-

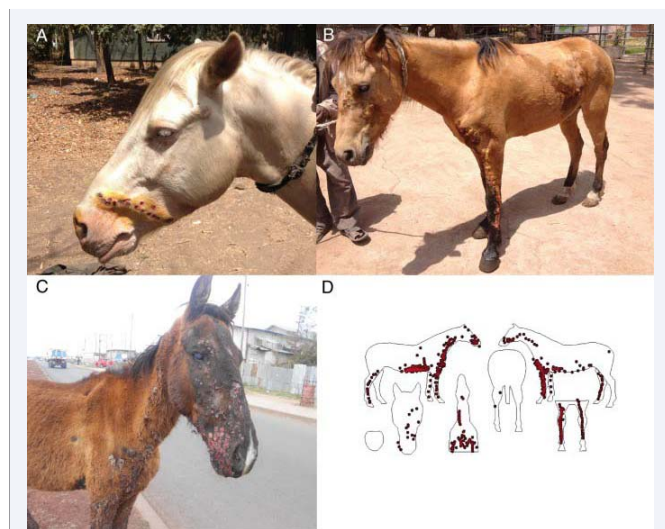


Figure 1 Cutaneous EZL lesions observed in the infected horses. (A) Mild case, in which lesions are evident in only one body area; (B) moderate case, in which lesions are distributed over the left forelimb and other body sites and moderate cording is seen on the forelimb; (C) severe case, in which multiple coalescent nodules appear over all four limbs and extensive lesions appear on the face; (D) spatial distribution of cutaneous lesions of Epizootic lymphangitis.

Source: [Ankit Rohatgi; available at <http://arohatgi.info/WebPlotDigitizer>]

phic and switches from a mould-like (filamentous) growth form in the natural habitat to a small budding yeast form in the warm-blooded animal host [38,39].

General structure, cell metabolic and description of *Histoplasma capsulatum*

Histoplasma capsulatum is a fungal pathogen that can result in a wide range of clinical presentations, from asymptomatic through fatal infection. It usually causes lung disease called Histoplasmosis or Darling's disease. It is called Darling's disease because it was found by Samuel Darling in histopathologic specimens about a century ago [40,41].

Histoplasma capsulatum reproduces when it is in the mold form of the fungus and is heterothallic. *H. capsulatum* is the anamorphic classification, while the teleomorph or perfect form is known as *Ajellomyces capsulatus*. Many approaches have been used to differentiate *H. capsulatum* strains. Three variants have been described based on host predilection, clinical presentation, geographic distribution, or serology: variant *duboisii* in Africa, variant *farciminosum* in horses, and variant *capsulatum* for the majority isolates [41].

The structure of *H. capsulatum* has not yet been studied with detail. There have been studies that focused on the polysaccharides composition of the cell walls [41]. The genome of *H. capsulatum* has also not yet been totally sequenced; however, certain strains of DNA have been studied. For examples, the G217B, G186A, and the Downs strain [41]. It will be useful to sequence the genome of *H. capsulatum*, because it can help answering many biological questions that scientists have. For example, the capacity to undergo the morphologic transition to the yeast phase, the

different genes code for different functions necessary for survival, and the phase specific genes regulation [42]. Originally *H. capsulatum* strains were classified into two types based on the polysaccharide composition of the cell walls. G217B belongs to type I, and it lacks α -(1, 3)-glucan in its cell wall, while G186A belongs to type II because it has large amounts of α -(1,3)-glucan in its cell wall. This was interesting because for G186A variants that lack α -(1,3)-glucan are avirulent whereas G217B contains no α -(1,3)-glucan but is fully virulent. Therefore, the relationship between α -(1, 3)-glucan and the *H. capsulatum* pathogenesis is relatable [41,43].

Different nutrients and compounds are required for the growth of *Histoplasma capsulatum* in different stages of its development. The nutritional requirements for the mycelia stage are simple; the organism can grow in a 25°C with glucose as its sole source of carbon and ammonia as its source of nitrogen. During the yeast phase, *H. capsulatum* requires more complex compounds and a higher temperature environment.

For the yeast phase, it first needs sulfhydryl-containing compounds for initiation of yeast development and cysteine or cystine along with certain growth factors such as biotin, thiamine, or thiotic acid in order to maintain the morphology [44]. Cysteine plays an important role in the morphogenesis of *H. capsulatum*. It allows the cell to perform respiration for both phases and during the transition. There are two terminal oxidase pathways for *H. capsulatum*: the cytochrome system which is blocked by cyanide and antimycin; the other, an unidentified alternative oxidase that is specifically blocked by salicylhydroxamic (SHAM) [42]. Another nutrient that is important for the growth of *Histoplasma capsulatum* is Iron. Iron is essential in redox reaction related to its existence in reduced Fe²⁺ and oxidized Fe³⁺ states. For a pathogen to be successful, it must have counter mechanisms for acquiring iron in the host microenvironment which it exists due to the limited amount of free soluble iron in an animal. There are a few approaches for the iron acquisition of *H. capsulatum* that have been studied. These strategies are: siderophores, acidic pH, reductive activities, and receptors for host iron-binding compounds. None of these approaches is unique because they can also be seen in other organisms; however, the coexistence of such plethora in a single microbe is distinctive [41,42].

EPIDEMIOLOGY

Epizootic lymphangitis disease which caused by *H. capsulatum* var. *farciminosum* is endemic in some countries of West, North, Northeast Africa, East Africa (Ethiopia) and Asia including India,

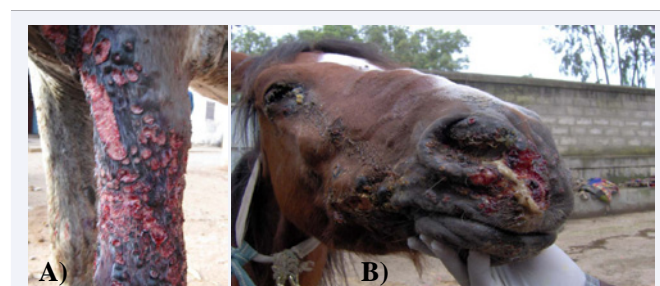


Figure 2 Cutaneous Form(A); Respiratory Form(B) of Epizootic lymphangite in horse.

Pakistan and Japan, where it is mostly diffused in areas characterized by humid and hot climates [17]. It is a thermally dimorphic fungal soil saprophyte and the mycelial form is present in soil, while the yeast form is usually found in lesions [17]. HCF (*H.capsulatum* var. *farciminosum*) is highly resistant to the effects of physical and chemical agents. It may survive for up to ten weeks in non-sterile water at 26°C [45,46]. The disease is more common in the tropics and subtropics and is endemic in North, East and North-east Africa, and some parts of Asia, including some countries bordering the Mediterranean Sea, India, Pakistan and Japan [47,48]. The disease is common in Ethiopia, especially in cart horses, affecting an average of 18.8% of horses in warm, humid areas between 1500 and 2300 meters above sea level [49,50].

The prevalence of the disease increases with assembling of animals. It was much more common, historically, when large numbers of horses were stabled together for cavalry and other transportation needs. Mainly, it is horses, mules, and donkeys that are affected by the disease, although infection may occur in camels, cattle and dogs [22].

The infection rate of EZL varies with the geographic area and the age of the animal. Horses under six years of age are most susceptible [51]. Horses under six years of age are more susceptible [15]. Four different forms of HCF infections are described: asymptomatic, cutaneous, conjunctival/ocular and respiratory. The first one, asymptomatic, occurs in patients which present fibrocalcific skin lesions at previous sites of infection and which are positive to intradermal sensitivity or other serological tests [15]. The incubation period (IP) of the disease is from 3 weeks to 12 months. It causes considerable debility but low mortality that doesn't usually exceed 10% to 15% and the main loss results from the inability of animals to work for several weeks because of extremely painful lesions [52].

Mode of transmission

The mode of transmission of EZL (Epizootic lymphangitis) includes transmission by direct or indirect contact of HCF with traumatized skin, by biting flies, by ticks or by inhalation of HCF [53-55]. In the endemic areas in certain regions of the world, the occurrence of seasonal dusty winds expose horses to the inhalation of dust and spores, leading to pneumonia [52,18]. As reported that, the wounds which caused by harness are the major predisposing factors of Epizootic Lymphangitis in carthorses in Ethiopia [56].

Fungal spores can be transmitted to healthy animals by direct contact with infected animals or with inanimate objects or fomites, such as grooming equipment, bedding, saddler, etc., and enter the skin through cutaneous abrasions. Biting flies of the genera *Musca* and *Stomoxys* may contribute to spreading the infections, while tick bites most likely represent a predisposing factor for EL in mules [15,17]. According to Singh, 1965 direct contact with infective materials through injured skin or through cutaneous abrasions is the most common mode of infection. Spread of infection can also occur by indirect contact through contaminated objects such as grooming tools, feeding and watering utensils, and harnesses and through wound dressings [52]. Records also exist for the transmission of the disease from stallions to mares during copulation [57].

The possibility of experimental infection of 6 horses is reported by Ameni G. in which the IP is much longer in horse inoculated with mycelial organisms than that of with the yeast form [58].

Pathogenesis of epizootic lymphangitis

After gaining entry through wounds, HCF invades subcutaneous tissue, sets up a local granuloma or ulcer and disseminates through the lymphatics to regional lymph nodes or, in severe cases, to other organs. Nodular lesions develop in the skin along the lymphatics and in the lymph nodes. These lesions eventually ulcerate and drain a thick, mucopurulent material containing yeast cells. Nodules occur wherever there is skin trauma (particularly under the harness and on the extremities). Horses that have a heavy systemic burden of fungi may succumb to pneumonia or failure of other affected organs [15,51,52]. The ocular form of the disease results from inoculation of the organism into the eye, likely by biting flies [51]. Both conjunctivitis and rhinitis may occur as the extension of the skin form, because the animals will scratch the skin lesions by their teeth and lips, thereby spreading it to the surrounding organs [59]

Clinical sign

Clinical signs of Epizootic lymphangitis are described based on the pathological lesions; otherwise the body temperature and general character of the animals are not changed. On the other hand, most of the animals will lose their body condition [51,59]. There are three clinical form of epizootic lymphangitis in horse as cutaneous, ocular and pulmonary form. The cutaneous form of the disease, after which the disease was named, is the most common. Clinical signs are observed several weeks to 6 months after infection. The initial lesion is an open granulomatous wound along the course of a lymphatic vessel, which has a tendency to ulcerate, or to undergo alternating periods of discharge and closure for some weeks before healing with residual scar formation [59]. Lesions are most common in the forelimbs, the chest wall, and the neck. In severe cases, skin over the entire body may be affected Initial nodules appear anywhere on the body but commonly on lower limbs, chest, and neck. Nodules rupture, discharging thick pus, and the ulcerated lesions subsequently scar and heal. Lesions progress locally along lymphatics, which become beaded and rope-like with enlarged regional lymph nodes. Repeated cycles of ulcerating and healing nodules occur. [59,60].

The ophthalmic form of the disease is less frequent. Infection may occur as conjunctivitis or a naso-lachrymal infection. Initial infection is characterized by a watery discharge from one or both eyes and some swelling of the eyelids, followed by the development of papules and ulcerating button-like growths on the conjunctiva and/or on the nictitating membrane [61]. The pulmonary form of the disease is infrequent, which usually occurs as a late development in the cutaneous form of the disease [18]. The nasal lesions are characterized by serous secretion, multiple small gray nodules, and or ulcers [59]. They are mostly confined to the upper respiratory tract. They usually found near the external nares and they may extend to the muzzle, or they may be found deep in the nasal cavity and in the pharynx, nasal sinuses, the larynx and the bronchi [52]. Some horses are asymptomatic carriers of HCF and they do not show clinical signs. They can be

identified clinically by the identification of fibro-calcification of skin lesions at previous sites of infection, or based on serologic evidence of antibodies, and positive reactions to intra dermal tests. These methods do not distinguish exposure from chronic infection [53]. Such horses will give a positive result to an intra dermal sensitivity test and positive reactions to serological tests [53]. Six bacterial contaminant genera are isolated from lesions of epizootic lymphangitis and some of them are frequently found that they potentially contribute to the clinical signs, pathogenesis and to the severity of the disease, leading sometimes to death in severely infected horses [62].

Pathology and clinical manifestations

There are three forms and three stages of the disease. The three forms are cutaneous (skin), ocular, and respiratory forms. The three stages are early, moderate and severe stages. Some horses are asymptomatic carriers of HCF. The form that the disease takes seems to depend primarily on the route of entry [49]. EZL (Epizootic lymphangitis) causes painful skin lesions that lead to lameness and loss of use of working equids, if the route of entry is by contact of infected material with traumatized skin. It may cause sinusitis, pneumonia via inhalation of contaminated dust, it may cause rhinitis by contact with skin lesions, and it may cause keratoconjunctivitis if transmitted by flies [59]. In all the three forms of the disease, severe inflammatory reaction, oedema, necrosis & pyogranulomatous nodular lesions are observed [63]. Generally, the granulomatous nodular lesions are usually confined to the skin, subcutaneous tissues, lymph vessels and lymph nodes. But in some cases, the lesions may extend to the underlying joints, resulting in arthritis, peri-arthritis or peri-ostitis. The granulomatous nodular lesions and abscesses may be found in the lungs, spleen, liver, testes and other internal organs in some cases [51,52].

The lesions usually heal spontaneously after 2–3 months, resulting in stellate scar formation [18]. The cutaneous form of the disease is the most frequent one, that epizootic lymphangitis is most commonly characterized by a cord-like appearance of the subcutaneous lymphatic and ulcerative cutaneous pyogranulomas [59]. HCF may cause sinusitis, and/or pneumonia via inhalation of contaminated dust, it may also cause rhinitis by contact with skin lesions, and it may also cause keratoconjunctivitis being transmitted by flies [51,52]. Epizootic lymphangitis can also present as an ulcerating conjunctivitis, or rarely as a multifocal pneumonia [15,50]. When mucosal lesions occur, 9 most are confined to the upper respiratory tract and eyes [15]. Cutaneous lesions are also seen in the respiratory form of the disease but are accompanied by nasal discharge and severe coughing [64]. Typical lesions of epizootic lymphangitis are pyogranulomatous nodules that may be appreciated in lymphatic vessels. Pyogranulomatous nodules and the liquefied foci have also been found in the pleura, spleen, liver, testes, tunica vaginalis, and bone marrow [52]. Interstitial pneumonia may also be recognized and lesions may be present in other organs [64].

Growth lesion

Gross lesions are manifested by pyogranulomatous, purulent discharge of thickened superficial lymphatic vessels and enlargement and inflammation of regional lymph nodes [15]. Regional

lymph nodes are swollen, soft, and reddened and may contain purulent foci. Lymphatic vessels may be found distended with pus [64]. At necropsy, areas of the skin and subcutaneous tissue are thickened, and the skin may be fused to the underlying tissues. When the thickened skin is incised, it presents the lardaceous appearance of granulation tissue and it contains a number of small, yellow, purulent foci between which the lymphatics are dilated and filled with pus and serous fluid [52]. The skin covering the nodules and the subcutaneous tissues may become thickened, fibrous, indurated, and firmly fused to the underlying tissues [52,59,64]. In the early stages, the swollen nodes contain many small foci of softening, but later the foci coalesce and are heavily encapsulated and they may rupture to form ulcers [52]. There is often thickening, or 'cording', of lymphatics, with the formation of pyogranulomatous nodules that have a thick, fibrous capsule [18]. Nodules in the skin have a thick, fibrous capsule and the affected lymphatic vessels are usually thickened or distended. Both nodules and lymphatics contain purulent exudates [65]. The forelimbs, neck, and head are common sites to observe the nodular and chronic suppurating lesions, however they are also observed on different body parts including the scrotal regions. In advanced cases, the nodules and ulcers may involve almost all body parts and may have unpleasant odor [59].

DIAGNOSIS

Diagnosis of epizootic lymphangitis depends on the clinical sign, history of animals and laboratory confirmation. The clinical signs of Epizootic lymphangitis in horses in endemic regions are often the basis of diagnosis; however confirmatory tests should be followed. Several confirmatory tests have been described. Laboratory diagnosis of epizootic lymphangitis usually is by stained smears of the cutaneous exudate based upon demonstration of the typical yeast-like, double-contoured cells in pus collected aseptically from the lesion and confirmed by culturing the pathogen [63,64]. Microscopic examination of Giemsa or Gram-stained smears of pus/ swabs aspirated from a nodule reveal Gram-positive yeast forms with a halo (unstained capsule-like) structure [56,59]. According to Ameni, 2007, it reveals hyaline septated and branched hyphae. The yeast form of the organism appears in pus as a double-contoured oval or ovoid body, measuring 2.5-3.5 μm by 3-4 μm [15]. Culture of HCF from body fluids or tissues is the "gold standard" for confirming the diagnosis but it may be impractical since it may be difficult and time-consuming to grow from body fluids and tissues. Moreover false-negative results are likely to occur [64,66]. The fungus HCF can be cultured or isolated on special media such as Sabouraud dextrose agar but it dies quickly in specimens, unless these are collected in antibiotic solutions, refrigerated and cultured promptly [51,56].

Serologic tests for the presence of antibodies in the blood are also the possible options, but they may not have a high degree of specificity for active disease. It may reflect past exposure or asymptomatic infection. Tube agglutination and passive hemagglutination tests have been reported to identify increased titers in horses with epizootic lymphangitis [45], which can be used as a practical screening test. A serum agglutination titer of 1: 80 or higher is reported to be positive [63]. Fluorescent antibody, AGID, and ELISA tests have also been described [45,67]. ID and CF tests also have been reported as useful tests [68]. Differential

diagnosis includes glanders, strangles, ulcerative lymphangitis and sporotrichosis, especially when these diseases occur under the same environmental conditions [69]. Histofarcin test could play a significant role in detecting early infection and in differential diagnosis [50,56]. The organisms are pleomorphic, often described as slightly lemon-shaped basophilic masses, varying from 2 to 5 µm in diameter, that are surrounded by a 'halo' when stained with H&E or Gram's stain AND Electron microscopy has been applied to skin biopsy samples of 1.5–2.0 mm immediately prefixed in phosphate buffered 2% glutaraldehyde solution at 4°C and post-fixed in 1% osmium tetroxide. Ultra-thin sections were cut and stained with uranyl acetate and lead citrate. Examination demonstrated the fine internal structure of the organism, *H.capsulatum* var. *farcimosum*, including the cell envelope, plasma membrane, cell wall, capsule and inner cell structures [15].

Differential diagnosis of EHL

The skin form of the disease may be confused with the skin form of glanders, which is caused by *Burkholderia mallei*, ulcerative lymphangitis, which is caused by *Corynebacterium pseudotuberculosis*, indolent ulcers a caused by *Rhodococcus equi*, sporotrichosis caused by *Sporothrix schenckii*, strangles and cutaneous lymphosarcomas [51, 70].

TREATMENT AND CONTROL OF EPIZOOTIC LYMPHANGITIS

Treatment of epizootic lymphangitis is mandatory to prevent spreading of the infection, whereas for disease control, culling infected horses and adoption of hygiene measures (e.g., cleaning and disinfection) and insects control are required. In recent years, the use of vaccines (i.e., a killed formalized vaccine, attenuated vaccine, and live vaccine) have been proposed as a strategy to eradicate the infection in endemic areas; the administration of the attenuate vaccine (i.e., vaccine developed by exposure of the causative agent to high temperatures) has resulted in a protection rate of 75.5% over >31 months [15]. Intravenous dosing of iodide may be used particularly in endemic areas. The intravenous injection of 100 ml of sodium iodide of a 10% solution, repeated weekly for four weeks is recommended. Different antifungal drugs have also been used and successful treatment with amphotericin B has been reported [51,71]. Many treatment types have been tried, but it was without success. Parenteral amphotericin B and iodides have been reported as effective. Even though Epizootic lymphangitis is highly prevalent and economically important in Ethiopia, the treatment options have not been employed because of the cost of the drugs and their absence in the market [17].

The disease does not have effective treatment so far and the final fate of sick horses is to be left outdoors for scavengers. The disease is rarely responding to treatment. One of the reasons could be due to the complication of the lesions with different bacteria in addition to its chronic nature. In general, *Histoplasma capsulatum* var. *Farcimosum* is less responsive to antibiotics. Nevertheless, its response to drugs like Amphotericin B, sodium iodide and Clotrimazole has been reported from other parts of the world [72].

When it comes to the Ethiopian situation, there is no drug prescribed to Epizootic lymphangitis in any of the veterinary clinics across the country. In case of absence of treatment, sick animals are left out doors for scavengers after their working power is exhausted. In Ethiopia antifungal drugs for Epizootic lymphangitis treatment are not usually available in government and private veterinary clinics [73]. However, traditional medicine has long been practiced to treat some common ailments using plants available in Ethiopia. Natural products and their derivatives have been historically sources of therapeutic agents [74]. This review also focuses on how to treat epizootic lymphangitis in absence and inadequate of modern drugs, therefore the numerous plants are sources of antimicrobial agents, such as *combretum molle*, *xanthium strumarium*, which used to treat Epizootic lymphangitis in traditional way [75,76]. As I got the information from my family and old men the plant which used for treatment of epizootic lymphangitis (*Biichee fardaa*) and ulcerative lymphangitis are like *Ricinus Communis* (*Qobboo*) and *Prunus African* (*Hoomii*). The methods of application and preparation of this plant which has been practice in Ethiopia is that first dried fruit of *Ricinus communis* is powdered and mixed with bark powder of *Prunus africana* and creamed to the ulcerated skin of horse, mule and donkey [my own information].

Control of this disease should be by vaccination (killed formalized vaccine, attenuated vaccine, and live vaccine) and appropriate wound management with administration of iodine, intravenous injection of sodium iodide and amphotericin B. Control and eradication of the disease is usually through elimination of the infection, through slaughter (culling) of infected horses and application of strict hygiene practices to prevent spread of the organism. There are also reports on the use of killed and live attenuated vaccines [77].

REFERENCES

1. Endebu B. Comparative Studies on the Occurrence and Distribution of Epizootic Lymphangitis and Ulcerative Lymphangitis in Ethiopia. The international Journal of Applied Research. 2000; 15: 1.
2. Pritchard JC, AC Lindberg, DC Main and HR Whay. Assessment of the welfare of working horses, mule and donkeys, using health and behavioral pattern. Prev Vet Med. 2005; 69: 265-283.
3. Anon. Federal Democratic Republic of Ethiopia. Central Statistical Agency: Agricultural Survey. 2014.
4. Wilson RT. The Tropical Agriculturalist, Livestock production systems, Distribution and Importance of livestock in the tropics. London: CTAMacmillan. 1995; 5.
5. Garuma S, Lemecha F, Sisay A, Jemal E. Study on gender distribution of ownership of animal-drawn carts and its effect on women's life in Adami Tulu and Dugda Bora districts. In: Draught Animal News, Ed: Centre for Tropical Veterinary Medicine (CVTM), University of Edinburgh, Edinburgh. 2007; 29-34.
6. Gebreab F. Diseases and health problems of donkeys abroad. In: The Professional Handbook of the Donkey, Ed: E. Svendsen, WhittetBooks Ltd, London. 1997; 207-226.
7. Asmamaw K, Alemayehu T, Alemayehu R, Bojia E. A preliminary study of the socioeconomic contribution of working equids in Dalocha District, Southern Ethiopia. In: Seventh International Colloquium on Working Equids, Ed: J. Wade, World Horse Welfare, Norfolk, UK. 2014; 27.

8. Biffa D, Woldemeskel M. Causes and Factors Associated with Occurrence of External Injuries in Working Equines in Ethiopia. *Intern J Appl Res Vet Med*. 2006; 4: 1-7.
9. Curran MM, Feseha G, Smith DG. The impact of access to animal health services on donkey health and livelihoods in Ethiopia. *Trop Anim Health Prod*. 2005; 37: 47-65.
10. Kebede G, Yohanes A, Degefa T, Pearson R. Assessment of health conditions of donkeys kept in urban and rural areas of central Ethiopia. In: D Smith, A Tesfaye, L More. *Alleviating Poverty in Peri-urban Ethiopia by Improving the Health, Welfare and Productivity of Donkeys*. DFID/BHA, Debre Zeit, Ethiopia. 2000; 29-35.
11. Shelima B, Dinka H, Abelti A, Mume T, Geleta T, Chala R. Major constraints and health management of carthorses in the mid rift valley of Ethiopia. In: R Pearson, C Muir, M Farrow, editors. *Fifth International Colloquium on Working Equines*. The Donkey Sanctuary, Addis Ababa, Ethiopia. 2006; 231-241.
12. Yilma J, Gebreab F, Svendsen E, Mohammed A. Health problems of working donkeys in Debre Zeit and Menagesha regions of Ethiopia. In: D. Fielding and R. Pearson. *Donkeys, Mules and Horses in Tropical Agricultural Development*, CVTM, Edinburgh. 1990; 151-155.
13. Admassu B, Shiferaw Y. Donkeys, horses and mules- their contribution to people's livelihoods in Ethiopia. 2011.
14. Scantlebury C, Pinchbeck G, Reed K, Gebreab F, Zerfu A, Aklilu N, et al. Participatory assessment of the impact of epizootic lymphangitis in Ethiopia. *Prev Vet Med*. 2015; 120: 265-276.
15. al-Ani FK. Epizootic lymphangitis in horses: a review of the literature. *Rev Sci Tech*. 1999; 18: 691-699.
16. Radostitis OM, Gay CC, Constable PD, Hinchliff KW. *Veterinary Medicine: A text book of the diseases of cattle, sheep, goats and horses*. 10th ed. WB Saunders Co. 2007.
17. Ameni G. Preliminary trial on the reproducibility of epizootic lymphangitis through experimental infection of two horses. *Vet J*. 2006; 172: 553-555.
18. OIE. Epizootic lymphangitis: Chapter 2.5.4. In *Manual of diagnostic tests and vaccines for terrestrial animals*. Office International des Epizooties, Paris. 2008.
19. Gilbert, RO. Epizootic lymphangitis. In: *Foreign animal diseases*. Richmond, VA: United States Animal Health Association. 1998; 251-255.
20. Abutarbush SM. *Veterinary Medicine—A Textbook of the Diseases of Cattle, Horses, Sheep, Pigs and Goats*. *Can Vet J*. 2010; 51: 541.
21. Radostits OM, Gay CC, Hinchliff KW, Constable PD. *Veterinary Medicine: A textbook of the diseases of cattle, horses, sheep, pigs and goats*. 10th edn. 2007.
22. Ueda Y, Sano A, Tamura M, Inomata T, Kamei K, Yokoyama K, et al. Diagnosis of histoplasmosis by detection of the internal transcribed spacer region of fungal rRNA gene from a paraffin-embedded skin sample from a dog in Japan. *Vet Microbiol*. 2003; 94: 219-224.
23. Robinson W.F. & Maxie M.G. The cardiovascular system. In: *Pathology of Domestic Animals*, Vol. 3. Academic Press, New York, USA. 1993; 82-84.
24. Adenis AA, Aznar C, Couppie P. Histoplasmosis in HIV-Infected Patients: A Review of New Developments and Remaining Gaps. *Curr Trop Med Rep*. 2014; 1: 119-128.
25. Kasuga T, White TJ, Koenig G, McEwen J, Restrepo A, Castañeda E. Phylogeography of the fungal pathogen *Histoplasma capsulatum*. *Mol Ecol*. 2003; 12: 3383-3401.
26. Murata Y, Sano A, Ueda Y, Inomata T, Takayama A, Poonwan N, et al. Molecular epidemiology of canine histoplasmosis in Japan. *Med Mycol*. 2007; 45: 233-247.
27. Eisenberg T, Seeger H, Kasuga T, Eskens U, Sauerwald C, Kaim U. Detection and characterization of *Histoplasma capsulatum* in a German badger (*Meles meles*) by ITS sequencing and multilocus sequencing analysis. *Med Mycol*. 2013; 51: 337-344.
28. Tamura M, Kasuga T, Watanabe K, Katsu M, Mikami Y, Nishimura K. Phylogenetic characterization of *Histoplasma capsulatum* strains based on ITS region sequences, including two new strains from Thai and Chinese patients in Japan. *Nihon Ishinkin Gakkai Zasshi*. 2002; 43: 11-19.
29. Borman A, Linton CJ, Miles SJ, Johnson EM. Molecular identification of pathogenic fungi. *J Antimicrob Chemother*. 2008; 61: 7-12.
30. Irinyi L, Serena C, Garcia-Hermoso D, Arabatzis M, Desnos-Ollivier M, Vu D, et al. International Society of Human and Animal Mycology (ISHAM)-ITS reference DNA barcoding database—the quality controlled standard tool for routine identification of human and animal pathogenic fungi. *Med Mycol*. 2015; 53: 313-337.
31. Jiang B, Bartlett MS, Allen SD, Smith JW, Wheat JL, Connolly PA, et al. Typing of *Histoplasma capsulatum* isolates based on nucleotide sequence variation in the internal transcribed spacer regions of rRNA genes. *J Clin Microbiol*. 2000; 38: 241-245.
32. Landaburu F, Cuestas ML, Rubio A, Elías NA, Daneri GL, Veciño C, et al. Genetic diversity of *Histoplasma capsulatum* strains isolated from Argentina based on nucleotide sequence variations in the internal transcribed spacer regions of rDNA. *Mycoses*. 2014; 57: 299-306.
33. Komori T, Sano A, Yarita K, Kitagawa T, Kamei K, Nishimura K. Phylogenetic analysis of *Histoplasma capsulatum* based on partial sequence of the D1/D2 region of the 28S rRNA gene. *Jpn J Med Mycol*. 2005; 46: 291-295.
34. Theodoro RC, Scheel CM, Brandt ME, Kasuga T, Bagagli E. PrP8 intein in cryptic species of *Histoplasma capsulatum*: evolution and phylogeny. *Infect Genet Evol*. 2013; 18: 174-182.
35. Bahr NC, Antinori S, Wheat LJ, Sarosi GA. Histoplasmosis infections worldwide: thinking outside of the Ohio River Valley. *Curr Trop Med Rep*. 2015; 2: 70-80.
36. Loulergue P, Bastides F, Baudouin V, Chandenier J, Mariani-Kurkdjian P, Dupont B, et al. Literature review and case histories of *Histoplasma capsulatum* var. *duboisii* infections in HIV related patients. *Emerg Infect Dis*. 2007; 13: 1647-1652.
37. Kasuga T, Taylor JW, White TJ. Phylogenetic Relationships of Varieties and Geographical Groups of the Human Pathogenic Fungus *Histoplasma Capsulatum* Darling. *J Clin Microbiol*. 1999; 37: 653-663.
38. Untereiner WA, Scott JA, Naveau FA, Bachewich J. Phylogeny of Ajellomyces Polytolypa and Spiromastix (Onygenaceae) inferred from rDNA sequence and non-molecular data. *Studies in Mycology*. 2002; 47: 25-35.
39. Untereiner WA, Scott JA, Naveau FA, Sigler L, Bachewich J, Angus A. The Ajellomycetaceae, a new family of vertebrate-associated Onygenales. *Mycologia*. 2004; 96: 812-821.
40. Chang, Ryan. Histoplasmosis. *emedicine*. 2005. 25 Aug 2007. <<http://www.emedicine.com/MED/topic1021.html>>
41. Heitman Joseph, Scott G. Filler, Aaron P. Mitchell, John E. Edwards Jr. *Molecular Principles of Fungal Pathogenesis*. *Emerg Infect Dis*. 2006; 12: 1626-1627.
42. Bossche Hugo, Frank Odds, David Kerridge. *Dimorphic Fungi in Biology and Medicine*. 1st ed. 1993.
43. Rappleye CA, Eissenberg LG, Goldman WE. *Histoplasma capsulatum*

- (1,3)-glucan blocks innate immune recognition by the -glucan receptor. Proc. Natl Acad. Sci. 2007; 23: 1366-1370.
44. Johnson Clayton, Jonathan T. Prigge, Aaron D. Warren, Joan E. McEwen. Characterization of an alternative oxidase activity of *Histoplasma capsulatum*. Yeast. 2003; 20: 381-388.
45. Gabal M, Khalifa K. Study on the immune response and serological diagnosis of Equine Histoplasmosis "Epizootic Lymphangitis". 1983; 30: 317-321.
46. Soliman R, Saad M, Refai M. Studies of Histoplasmosis Farciminosii (Epizootic lymphangitis) in Egypt. III. Application for a skin test (Histofarcin) in the diagnosis of epizootic lymphangitis in horses. Mykosen. 1985; 28: 457-461.
47. Ajello L. Comparative morphology and immunology of members of genus *Histoplasma*. A review. Mykosen. 1968; 11: 507-514.
48. Al-Ani F, Hassan F, Al-Juborri K. Sero-diagnosis of epizootic lymphangitis in horses by passive haemagglutination test. J Iraqi Vet. 1989; 7: 1-16.
49. Ameni G, Siyoum F. Study on Histoplasmosis (Epizootic Lymphangitis) in Cart Horses in Ethiopia. J Vet Sci. 2002; 3: 135-140.
50. Ameni G. Epidemiology of Equine Histoplasmosis (Epizootic lymphangitis) in cart horses in Ethiopia. Vet J. 2006; 172: 160-165.
51. Radostits O, Gay C, Hinchcliff K, Constable P. Epizootic Lymphangitis. In Veterinary medicine: A Textbook of The Diseases of Cattle, Horses, Sheep, Pigs and Goats. 10th Ed. Saunders; Elsevier: London. 2006; 14: 78 -79.
52. Jubb K, Kennedy P, Palmer N (Eds.) Epizootic lymphangitis. In Pathology of Domestic Animals, Vol. 3, 5th Ed, Grant M, Wayne F. Eds.: Academic Press, New York, USA. 2006; 98-102.
53. Al-Ani F, Al-Delaimi A. Epizootic lymphangitis in horses: clinical, epidemiological and hematological studies. Pakistan vet. j. 1986; 6: 96-100.
54. Morrow A, Sewell M. Epizootic Lymphangitis. In Handbook on Animal Diseases in the Tropics, 4th Ed, Sewell M, Brocklesby D. Eds.: Bailliere, Tindall, London. 1990; 364-367.
55. Ameni G, Terefe W. A cross-sectional study of epizootic lymphangitis in cart-mules in western Ethiopia. Prev Vet Med. 2004; 66: 93-99.
56. Asfaw R, Ameni G, Mahendra P. Prevalence of Epizootic Lymphangitis in Cart Horses in Southwest Shewa of Oromia Region, Ethiopia. Int J Livest Res. 2012; 2: 146-151.
57. Gillespie J, Timoney J. Hagan and Bruner's infectious diseases of domestic animals, 7th Ed. 1981.
58. Ameni G. Preliminary trial on the reproducibility of epizootic lymphangitis through experimental infection of two horses. Vet J. 2006; 172: 553-555.
59. Ameni G. Pathology and Clinical Manifestation of Epizootic Lymphangitis in Cart Mules in Ethiopia. Journal of Equine Science. 2007; 18: 1-4.
60. Khater A, Iskander M, Mostafa A. A histo-morphological study of cutaneous lesions in equine histoplasmosis (Epizootic lymphangitis) in Egypt. Vet med Assoc. 1968; 28: 165-17.
61. Singh T. Studies on Epizootic lymphangitis: Clinical cases and experimental transmission. Indian J vet Sci. 1966; 36: 45-59.
62. Hadush B, Biratu D, Taddele H, Tesfaye D, Ameni G. Bacterial contaminants isolated from lesions of equine histoplasmosis in cart horses of Mekelle town, northern Ethiopia. Revue Méd Vet. 2014; 165: 25-30.
63. Al-Ani F, Hassan F, Al-Juborri K. Sero-diagnosis of epizootic lymphangitis in horses by passive haemagglutination test. J Iraqi Vet. 1989; 7: 1-16.
64. Al-Ani F, Ali H, Banna H. *Histoplasma farciminosum* infection of horses in Iraq. Vet. Arhiv. 1998; 68: 101-107.
65. Ratib HZ, Abd Ellah MR, Mohamed AM, Aamer, AA. Epizootic Lymphangitis: Proceedings of the 9th International Congress of World Equine Veterinary Association. 2006.
66. Al-Delaimi A, Khairallah A. Application of fluorescent antibody test in the diagnosis of the epizootic lymphangitis. Haryana Vet. 1984; 23: 123-125.
67. Gabal M, Bana A, Gendi M. The fluorescent antibody technique for diagnosis of equine histoplasmosis (epizootic lymphangitis). Zentralbl Veterinarmed B. 1983; 30: 283-287.
68. Soliman R, Saad M, Refai M. Studies of histoplasmosis farciminosii (epizootic lymphangitis) in Egypt. III. Application for a skin test (Histofarcin) in the diagnosis of epizootic lymphangitis in horses. Mykosen. 1985; 28: 457-461.
69. Quinn P, Carter M, Markey B, Carter G. Veterinary clinical microbiology, 1st Ed. Wolfe Publishing Company, London. 1994. 407.
70. Kahn CM, Line S. Epizootic lymphangitis. The Merck veterinary manual, Whitehouse Station, NJ: Merck and Co.; Lehmann P.F. Howard D.H. & Miller J.D. (1996). Veterinary Mycology. Springer-Verlag, Berlin, Germany. 2006; 96: 251-263.
71. Gabal M. The Effect of Amphotericin B, 5-Fluorocytosine and Nystatin on *Histoplasma farciminosum* *in vitro*. 1984; 31: 46-50.
72. Hadush B, Ameni G, Medhin G. Equine histoplasmosis: Treatment trial in cart horses in Central Ethiopia. Tropical Animal Health and Production. 2008; 40: 407-411.
73. Aklilu N, Zerfu A. Socioeconomic impact of epizootic lymphangitis (EL) on horse- drawn taxi business in Central Ethiopia. 2010; 83-86.
74. Yirga G. Ethnobotanical study of medicinal plants in and around Alamata, Southern Tigray, Northern Ethiopia. Journal of Biological Sciences. 2010; 2: 338-344.
75. Fentahun W, Kindu W, Feqadu R, Kiflu B. An *in-vitro* Trial on Antifungal Effect of *Xanthium strumarium* Leaf Extract on the Growth of the Mycelial form of *Histoplasma capsulatum* var *farciminosum* Isolated from Horse. Adv Biotech & Micro. 2016; 1: 555-557.
76. Mishra AK, Mishra A, Kehri H, Sharma B, Pandey A. Inhibitory activity of Indian spice plant, *Cinnamomum zeylanicum* extracts against *Alternaria solani* and *Curvularia lunata*, the pathogenic dematiaceous moulds. Ann Clin Microbiol Antimicrob. 2009; 8: 9-15.
77. Zhang W, Wang Z, Liu Y, Zhang D, Liang P, Fang Y, Huang Y, Gao S. Attenuated vaccine against Epizootic lymphangitis of horses. Chin J vet Sci Technol. 1986; 7: 3-5.

Cite this article

Abdisa T (2017) Review on Equine Epizootic Lymphangitis and its Impact in Ethiopia. J Vet Med Res 4(5): 1087.