

Review Article

Egg Peritonitis: Concepts, Prevention and Control Strategies -A Review

Bashahun Gebremichael* and Gelane Darge

Jimma University College of Agriculture and Veterinary Medicine, School of Veterinary Medicine, Jimma, Ethiopia

***Corresponding author**

Bashahun Gebremichael, Jimma University College of Agriculture and Veterinary Medicine, School of Veterinary Medicine, Jimma, Ethiopia, PO. Box. 307; Fax: 25147 111 0935; Tel: 251 91730 7139; Email: bashahun@gmail.com

Submitted: 08 September 2017

Accepted: 18 October 2017

Published: 19 October 2017

ISSN: 2378-931X

Copyright

© 2017 Gebremichael et al.

OPEN ACCESS**Abstract**

Egg peritonitis documented to be one of the major causes of morbidity and mortality of chickens in poultry farms, resulting in the reduced egg production in the poultry industries. Egg peritonitis can occur in any environment, but is more common in factory farms and in flocks where chickens are highly stressed and exposed to too much artificial light at young age. Ruptured oviduct, reverse peristalsis, genetics and stresses during ovulation are important factors for the problem to occur. Distended abdomen, frequent multiple yolked eggs, cessation in laying and yellow-orange droppings are the most diagnostic clinical signs. Diagnosis can be made through history, physical examination, x-ray, radiography, laboratory and postmortem examinations. Treatment often involves using antibiotics (such as Baytril®, Sulphonamides®, Gentamycin®, etc.) which usually help to treat infection. However, unless the birds are able to stop laying internally, the peritonitis will usually recur. Mild cases of egg peritonitis may be managed medically while severe cases are corrected by surgical intervention. Management of bodyweight, reproductive development, and good sanitation are the best preventive approaches. The aim of this review is to compile available literature on the current status and global distribution of Egg peritonitis and share appropriate information for further investigation.

Keywords

- Distended abdomen
- Egg peritonitis
- Egg yolk
- Morbidity
- Mortality
- Poultry

INTRODUCTION

Poultry have been on earth for over 150 million years, dating back to the original wild jungle fowl, including ducks, geese, turkeys, pheasants, pigeons, peafowl, guinea fowl and chickens in the list of species under the general term poultry. Poultry provide humans with companionship, food and fiber in the form of eggs, meat and feathers [1]. The poultry industry has potential to generate foreign exchange earnings through export of poultry products and may act as a key supplement to revenue from crops and other livestock enterprises, thus avoiding over-dependency on traditional commodities with inconsistent prices. The commercial poultry industry contributes significantly to the incomes of both urban and peri-urban farmers. Urban dwellers too keep poultry from which they derive additional income in addition to other sources. On the other hand, the big commercial producers derive most of their income from the sector as their primary business [2].

Poultry farming is a means of bridging the protein deficiency gap common in many developing countries of the world. However, optimum egg production in poultry industries significantly depends on a healthy and functional reproductive system of the chicken. Egg peritonitis is recognized as one of the most important challenges encountered in the poultry farms, causing loss of poultry and poultry products [3,4].

Egg peritonitis, also called Egg yolk peritonitis, yolk stroke, abdominal sepsis, and abdominal septicaemia [6], is the inflammatory reaction of peritoneum characterized by fibrin or albumen-like material with a cooked appearance among the abdominal viscera. It is a common cause of sporadic death in layers or breeder hens, but in some flocks may become the major cause of death before or after reaching peak production giving the appearance of a contagious disease [5]. The condition occurs after prolapsed or when yolk goes into the abdominal cavity, instead of going down the oviduct and out in the normal way. The peritoneum becomes inflamed due to an infection from bacteria [7].

Yolk material by itself induces a mild inflammatory response and may be reabsorbed by the peritoneum. Since yolk is an excellent growth medium for bacteria, peritonitis may result from secondary bacterial infection leads to secondary ascites and organ inflammation and cause morbidity, mortality and reduced egg production in the affected flocks [8].

Egg peritonitis is a common cause of abdominal distension in chickens. Localized to diffuse fibrinous peritonitis may result, and may lead to secondary ascites and organ inflammation or compromise in chronic cases. The mass of egg yolk in the abdomen can provide a rich medium for bacteria such as *E. coli* to thrive and cause peritonitis. These birds become dull with hot swollen

abdomens and in severe cases they will develop blood poisoning and go into shock and invariably die [9]. Records of the morbidity rate of reproductive diseases of poultry ranged from moderate to as high as 35% while a moderate mortality rate of 15% is common but a significant decline in productivity of up to 40% has often been associated [10]. Egg peritonitis documented to be the most common cause of mortality in commercial layers and breeders and considered one of the serious reproductive problems to commercial poultry industry. However, it appears to be kept out of the research scope mainly due to the fact that farmers are reluctant to report its sporadic occurrence. This consequently resulted in scanty information in field detection techniques and management of egg peritonitis [3,4,11]. Therefore, the aim of this review is to compile available literatures on the current status and global distribution of Egg peritonitis and share appropriate information for further investigation.

LITERATURE REVIEW

Causes of egg peritonitis

Egg peritonitis occurs when the hen matures too many egg follicles at once, and is sometimes the result of a condition known as EODES (erratic ovi-position and defective egg syndrome). With this illness, the yolks inside the hens' body become infected, often with *E. coli* bacteria. The yolks may be deposited internally instead of within an egg, and when the hen's body tries to reabsorb them, the peritoneum can become infected, as egg yolk is a good medium for bacteria to grow. This problem can occur when young hens or pullets are exposed to stress and too much light too early in their maturation, typically in a factory farm setting... although it can occur in home flocks that crowd too many hens together in a small space and use light to encourage early laying [12].

Egg peritonitis can be classified as non-septic egg peritonitis and septic egg peritonitis. In non-septic egg peritonitis, there is no involvement of bacterial infections whereas septic egg peritonitis (the most common type) occurs due to contamination with bacteria, typically *Escherichia coli* (*E. coli*) [14].

Egg peritonitis may be caused by: - Ruptured oviduct, reverse peristalsis, stresses during ovulation, and genetic factors. Some factors such as coming into lay and stress can cause the odd internally laid egg. However, severe oviduct damage, can lead to permanent oviduct problems and therefore they remain internal layers [9]. Peritonitis follows reverse movement of albumen and *E. coli* bacteria from the oviduct into the abdomen. When hens have too many large ovarian follicles, and defective egg syndrome is seen. This condition is accompanied by a high incidence of double-yolked eggs, prolapses of the oviduct, internal ovulation, and/or internal laying that often results mortality [5]. "We wonder if northern climates, where summer days are very long and flocks spend more time indoors, see a higher incidence, too? Thus far we have seen no studies on the issue" [5,6].

In chickens with damage to their oviducts the egg does not form properly and the yolk is laid internally into the belly. This abdomen enlarges causing the chicken to experience discomfort and difficulty breathing [5]. This often occurs after some viral diseases like *Infectious bronchitis* where the disease damages the

reproductive tract [7]. In addition to this, viral diseases (such as *Newcastle disease* and *Avian influenza*) affecting the reproductive tract of birds could lead to frequent oophoritis and egg peritonitis. Furthermore, *E. coli* causes immunosuppressive effect in chicken and makes the birds susceptible to opportunistic pathogens. When intestinal barriers are damaged, the pathogenic bacteria may invade and cause peritonitis [10,11,15].

Epidemiology

Limited information is available regarding the global distribution of Egg peritonitis. However, it has been reported from some Asian and African countries; such as: Pakistan [16], Bangladesh [17], India [10,18] and Nigeria [11]. Egg peritonitis can occur in any environment, but is more common in factory farms and in flocks where birds are highly stressed, exposed to too much artificial lights at young age, and are crowded too closely together in an unsanitary environment [6]. Overweight hens may also have a higher incidence of erratic ovulations and mortality associated with egg peritonitis [5].

Other findings indicate that the incidence of the egg peritonitis was noticed throughout the laying period, however more common during the peak production i.e., 21- 60 weeks of age. Chickens at peak of production are more susceptible due to stress imposed by the stage of lay. As long as the intestinal mucosal barrier is intact, the normal micro flora of chicken is likely to inhibit the translocation of pathogenic *E. coli* from the intestine to the blood stream and organs. When these barriers are damaged, possibly by the stress of coming to lay and peak production, the pathogenic bacteria may invade and cause peritonitis [10,19].

Several researchers have reported that in the egg peritonitis affected farms the mortality rate varies from 0.5% to 10%. For instance, Srinivasan *et al.* [10], reported 0.5% and 7%, Qu *et al.* [20], reported 5.5% and Zanella *et al.* [8], reported 5% to 10% mortality rate.

Pathogenesis

The yolks may be deposited internally instead of within an egg, and when the hen's body tries to reabsorb them, the peritoneum can become infected [6]. Yolk material by itself induces a mild inflammatory response and may be reabsorbed by the peritoneum. Because yolk is an excellent growth medium for bacteria, peritonitis may result from secondary bacterial infection. Localized to diffuse fibrinous peritonitis may result, and may lead to secondary ascites and organ inflammation or compromise in chronic cases [21].

Lodgment of eggs in the oviduct was probably due to reverse peristalsis brought about by breakage of the thin-shelled eggs and *Escherichia coli* bacteria. It is a common cause of sporadic death in layers, as poultry production intensified, however its occurrence has also increased and in some flocks may become the major cause of death and gives the appearance of a contagious disease [22].

Reports indicated that substituted commercial starter rations with ground corn in the first 12, 24 and 36 hours of life have association for the causation of Egg peritonitis. They concluded that corn feeding in early life led to slow absorption of yolk sac

materials [23]. The levels of lysine and methionine also have some effect on absorption of yolk sac in chicks [24]. In addition, feeds with low calcium content may also cause egg peritonitis. It is well known fact that hypocalcemia and other nutritional deficiencies are important factors for the occurrence of this and other diseases in chickens [13,25].

Clinical signs, diagnosis and treatment

Diagnostic signs include distended abdomen, frequent multiple yolked eggs, cessation in laying and yellow-orange droppings [6]. Signs of non-septic and septic egg peritonitis may include; - Abdominal and vent swelling, weight loss, wide based stance, depression, weakness, lethargy, ascites (Figure 1 and 2), respiratory distress, anorexia, yolk colored droppings, fluffed feathers, lack of vocalization, pain, change in regular behavior, secondary-abdominal hernia due to extreme abnormal distention and sudden death [25].

Chickens with egg peritonitis may have a higher white blood cell count and an increase in blood calcium, cholesterol and blood protein. Ultrasound and radiograph are effective methods in detecting reproductive abnormalities like egg peritonitis [26]. In larger commercial flocks, or where a hen is found dead, Egg peritonitis may be diagnosed by performing a post mortem examination [27].

Tentative diagnosis of reproductive-associated coelomitis (peritonitis) is made through history, physical examination and supporting laboratory tests. The hen may have a history of egg production, which may have abruptly stopped. Patients with more advanced disease may exhibit weight loss, abdominal distension, and dyspnea associated with coelomic fluid and air sac compression [28]. Supportive diagnostic tests include a complete blood count, serum chemistries, radiographs, ultrasound and analysis of any fluid recovered from abdominocentesis including cytology, culture and sensitivity. A leukocytosis with a relative heterophilia, as well as a peripheral hypercalcemia, hyperglobulinemia and hypercholesterolemia compatible with pre- and immediate post-ovulation may be noted. Many affected chickens will actually be hypo-calcemic due to calcium depletion subsequent to malnutrition or chronic egg laying [25,29].

Laparoscopy and/or laparotomy may be necessary to identify the causative agent [18]. Some birds have been treated with antibiotics and had the fluid drawn off but the chances of success are slim. It is usually better to have the patient put to sleep [30]. Unfortunately, treatment for Egg peritonitis is rarely successful, and the majority of birds are too sick by the time they are seen by a vet. The best chance of successfully treating egg yolk peritonitis is to catch the disease early, and this can only be achieved by being extremely vigilant of your laying flock. The earlier the case of Egg peritonitis diagnosed, the better the probable outcome. If a chicken is to be treated, antibiotics and good attentive nursing care are essential [25].

Treatment often involves application of antibiotics; such as, Baytril®, Sulphonamides, Oxytetracycline, Gentamycin®, etc., which usually helps to treat infection; however, unless birds are able to stop laying internally, the peritonitis will usually recur [9]. In addition, treatment may include diuretics like Furosemide to clear away the fluid and drugs like Milk Thistle to help the liver




Figure 1 A chicken with Egg peritonitis. Source: poultrykeeper.com

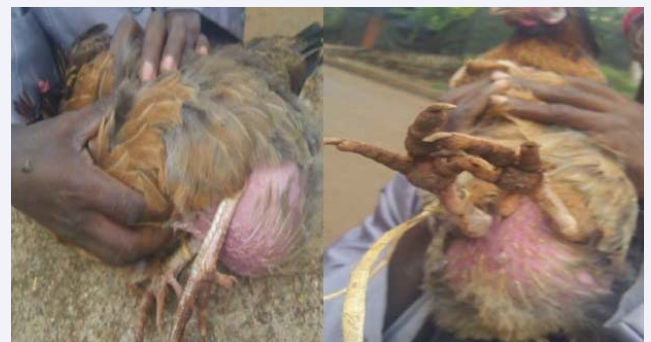

Figure 2 Distended abdomen of a chicken due to Egg peritonitis
Source: A photo captured from a hen with Egg peritonitis at Jimma University College of Agriculture and Veterinary Medicine (JUCAVM) open air veterinary clinic.

repair itself plus antibiotics to prevent further infection. Chickens with non-septic Egg peritonitis can be treated with supportive fluid and additionally antibiotics may be administered in order to prevent secondary bacterial complications. Patients with ascitic fluid may need to have an abdominocentesis to have all the fluid removed [14].

The best chance of successfully treating Egg peritonitis is to catch the disease early, and this can only be achieved by being extremely vigilant at laying flocks [31]. Mild cases of Egg peritonitis may be managed medically while severe cases are corrected by surgical intervention (Figure 3) [11,31,32].

Control and prevention strategies

Management of body weight and uniformity, reproductive development and drinking water sanitation are the best preventive strategies [5]. Avoid supplemental light in the coop especially with young layers, feed a high quality diet, and make sure they have free choice egg shell or oyster shell for calcium at all times and hens have adequate room to move around for exercise. Periodic hormone injections, spaying procedure, maintain sanitary conditions and frequently change the bedding litter. Avoid overcrowding, ammonia buildup, and dry, dusty environments. Provide adequate ventilation, ensure clean drinking water, free from fecal contamination aid in prevention of Egg peritonitis [32,33,34].

An additional Egg peritonitis controlling approach is to

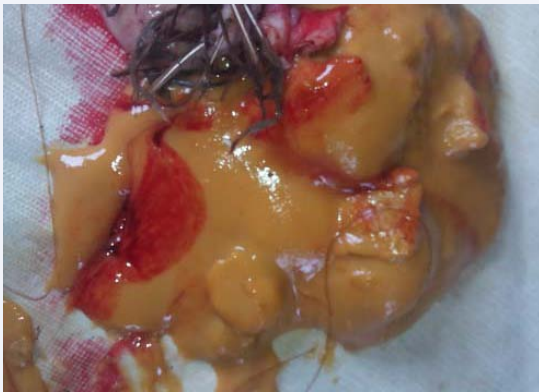


Figure 3 Surgically removed egg yolk material from a hen suffering from Egg peritonitis
Source: A photo captured from a hen with Egg peritonitis at JUCAVM open air veterinary clinic.

administer a hormonal implant that is inserted into the chicken's neck or breast. The implant effectively stops the hen from laying and so the Egg peritonitis symptoms will disappear [30]. To control the Egg peritonitis fecal contamination with *E. coli* should be minimized [10,18,19]. Moreover, keeping flocks under sufficient space (for exercise), good sanitation and biosecurity practices are the key prevention approaches recommended [4,8,12].

Biosecurity measures help prevent the introduction of disease pathogens that may secondarily predispose birds to *E. coli* peritonitis. Two biosecurity measures were negatively associated with *E. coli* peritonitis: 1. placing an anteroom that separates "outside area" from "inside area." 2. Spraying tires of vehicles entering the premises. Using a municipal water source for birds' drinking water was associated with a reduced risk of *E. coli* peritonitis. Chlorination of municipal water may reduce *E. coli* contamination [35].

CONCLUSION

In conclusion, the current review evaluated that only few published works were available on this regard. Thus, this is a good opportunity to researchers who are interested to investigate and fill the gap. Therefore, an urgent call is forwarded to veterinarians to conduct a research on Egg peritonitis at large.

ACKNOWLEDGEMENT

Family members of all authors are highly acknowledged.

REFERENCES

1. Michael JD. The Importance of Poultry in Our Lives. University of Connecticut: Cooperative Extension System office.
2. Byarugaba DK. Structure and Importance of the commercial and village based poultry industry in Uganda. Poultry Sector country review by Animal Production Service of Food and Agriculture Organization for Social Economics, Production and Biodiversity Unit of the Emergency Centre for Trans boundary Animal Diseases of FAO. 2007.
3. Kermer IF. Disorders of Avian Female Reproductive System. *AviPathol.* 2008; 9: 405-419.
4. Medina HA. Peritonitis in Commercial Egg Layers. Proceedings of the

- Midwest Poultry Federation Convention, St. Paul. 2008.
5. Rosales AG. Egg Peritonitis in Poultry. Merck and the Merck Veterinary Manual. Merck & Co., Inc., Kenilworth, NJ, USA. 2016.
6. Chicken Care. Egg Yolk Peritonitis: Overview. LLC. 2017.
7. Daniels T. Poultry Diseases: Reproductive System Problems; Egg Peritonitis. 2008.
8. Zanella A, Alborali GL, Bardotti M, Candotti P, Guadagnini PF, Martino PA. Severe *Escherichia coli* 0111 septicemia and polyserositis in hens at the start of lay. *AviPathol.* 2000; 29: 311-317.
9. The Chicken Vet. Health and Common Diseases: Egg Peritonitis. The home of healthy chicken. 2017.
10. Srinivasan P, Balasubramaniam GA, GopalaTR, Murthy K and Balachandra P. Prevalence and Pathology of Oviduct Impaction in Commercial White Leghorn Layer Chicken in Namakkal Region of India. *VetWorld.* 2014; 2: 553-558.
11. Musa WI, Muhammad ST. Clinical Evaluation and Surgical Management of Some Important Reproductive Problems of Intensively Raised Chickens in Zaria, Nigeria. *Open J AniSci.* 2015; 5: 325-331.
12. My Pet Chicken. Egg Yolk Peritonitis Overview. 2017.
13. Hannah D. Common chicken health concerns. *Pet Care. VioVet Ltd.* 16th July 2014.
14. Vetary. Bird Conditions: Egg Yolk Peritonitis in Birds. 2017.
15. Jorda FTW. Miscellaneous Conditions of Chickens, Turkeys and Ducks. 4th Edition, WB Saunders Co. Ltd. 1998; 392-421.
16. Khan KA, Khan SA, Aslam A, Rabbani IM and Tipu MY. Factors Contributing to Yolk Retention in Poultry: A Review. *Pakist Vet J.* 2004; 24: 1.
17. Tonu NS, Sufian MA, Sarker S, Kamal MM, Rahman MH, Hossain MM. Pathological study on colibacillosis in chickens and detection of *Escherichia coli* by PCR. *Bangladesh J Vet Med.* 2011; 9: 17-25.
18. Srinivasan P, Gurusampalayam A, Balasubramaniam T, Ramasamy G, Krishna M, Perumal B. Bacteriological and pathological studies of egg peritonitis in commercial layer chicken in Namakkal area. *Asian Pac J Trop Biomed.* 2013; 12: 988-994.
19. Leitner G and Heller ED. Colonization of *Escherichia coli* in young turkeys and chickens. *Avi Dis.* 1992; 36: 211-220.
20. Qu FQ, Yong SQ, Jiu B, Zhang DZ, Li HW and Liu S. Diagnosis and control of swollen head syndrome in layers. *Chin J Vet Med.* 1997; 7: 27-30.
21. Egg Yolk Peritonitis. Mar 20, 2017.
22. Chauhan HVS, Roy S. Poultry disease diagnosis and treatment. 3rd ed. New Delhi: New Age International (P) Limited Publication. 2007; 203-208.
23. Pisarski RK, Malec H, Malec L. Effect of initial feeding of broilers on the growth rate, yolk sac absorption and selected blood chemical parameters. *Medycyna Weterynaryjna.* 1998a; 6: 409-412.
24. Wang H, Huo QG, Li SB. Nutrient transfer in yolk sac of feeding chick. *Acta Veterinaria et Zootechnica Sinica.* 1994; 2: 97-104.
25. Romagnano A. Care of the critically ill Breeding Hen. In: Proceedings of the international Aviculturists Society. 2003.
26. Roskopt WJ, Woerpel R. Avian Obstetric Medicine. In: JS Bichard, Sherding RG, Eds, Saunders Manual of Small Animal Practice, 2nd Edition. WB Sanders Company, Philadelphia, London. 2000; 1450-5100.
27. Elliott S. Egg Yolk Peritonitis. The veterinary expert. 15th January 2015.

28. Krautwald-Junghanns ME, Enders F. Ultrasonography in birds. *Sem Avian Exot Pet Med.* 1994; 3: 140-146.
29. Romagnano A. Avian obstetrics. *Sem Avian Exot Pet Med.* 1996; 5: 180-188.
30. <http://simplelifeaiteasy.blogspot.com/2012/03/egg-yolck-peritonitis-diagnosing-sick.html>. 2012.
31. Martin HD. Avian Reproductive Emergencies; Surgical Management. *Vet Medical Record.* 1990; 2: 250-253.
32. <http://www.poultrydvm.com/condition/egg-peritonitis>.
33. Bowles HL. Management of chronic egg-laying with leuprolide acetate. *Proc Assoc Avian Vet.* 2000; 105-108.
34. Barnes HJ, Nolan LK and Vaillancourt JP. Colibacillosis. In: Saif YM, Fadly AM, Glisson JR, Mc Dougald LR, Swayne DE, Nolan LK, editors. *Diseases of poultry.* 12th ed. Iowa State University Press. 2008; 691-738.
35. Centers for Epidemiology and Animal Health. *Escherichia coliperitonitis on Breeder-Chicken Farms in the United States.* Aphis. Technical Brief.

Cite this article

Gebremichael B, Darge G (2017) *Egg Peritonitis: Concepts, Prevention and Control Strategies -A Review.* *J Vet Med Res* 4(9): 1109.