

Research Article

Effect of Trehalose and/or Methotrexate on Swiss Albino Mice

Abeer Khamis¹, Mohammed A. El-Magd², Samah K Nasr Eldeen^{1*}, Wafaa M. Ibrahim², and Afrah F. Salama¹

¹Chemistry Department, Tanta University, Egypt

²Medical Biochemistry Department, Tanta University, Egypt

³Anatomy Department, Kafrelsheikh University, Egypt

***Corresponding author**

Samah K Nasr Eldeen, Chemistry Department, Tanta University, Egypt, Email: science_samah@yahoo.com

Submitted: 19 October 2017

Accepted: 01 November 2017

Published: 06 November 2017

ISSN: 2378-931X

Copyright

© 2017 Eldeen et al.

OPEN ACCESS

Keywords

- Trehalose
- Methotrexate
- Cytotoxic effect

Abstract

Trehalose compound has no cytotoxic effect on naïve mice. It shows protective effects in various cells against harmful stimuli such as heat, dehydration, cold, desiccation and oxidation and it has antitumour effect against Erlich ascites carcinoma. In this study, mice were assigned into four groups: control group, trehalose group (200µg/mouse), methotrexate group (25µg/mouse), trehalose plus methotrexate group, six times a day. On day 14th, mice were euthanized. Biochemical parameters such as hepatic enzymes (alanine aminotransferase, aspartate aminotransferase, alkaline phosphatase), albumin and total protein in serum have been determined. *Glutathione S. transferase*, catalase, totalantioxidants and malondialdehyde in liver tissue, in addition to complete blood count (CBC) and histological studies of all groups were carried out. The results indicate that trehalose has no cytotoxic effect on naïve mice when compared with methotrexate as chemotherapeutic agent and trehalose may be considered as a novel drug.

INTRODUCTION

Trehalose is a natural disaccharide found in organisms ranging from bacteria to plants, including yeasts, fungi and vertebrates. It induces autophagy in an mTOR-independent manner which is conserved catabolic mechanism in which the unwanted organelles and misfolded proteins are delivered to lysosome for degradation [1] and the final metabolic products can be recycled as nutrient for keeping cell homeostasis. It shows protective effects in various cells against harmful stimuli such as heat, dehydration, cold, desiccation and oxidation [2].

The aim of the present study was to investigate the cytotoxic effect of trehalose and/or methotrexate. The criteria to assess the protective effect of methotrexate and/or trehalose include:

1) Measurement of the oxidative stress by assessing the levels of malondialdehyde (MDA), catalase, glutathione -S-transferase (GST) and total antioxidant capacity of liver tissues homogenate and liver functions (transaminases, alkaline phosphatase, total protein and albumin) of all mice groups to reflect changes occurring in the liver of control and injected mice groups.

2) Complete blood count (CBC) of untreated and treated groups to show the effect of tumor and treatment on blood cells.

3) Histological studies of liver tissues of control and injected mice to show the efficacy of the drugs on liver cells.

MATERIALS AND METHODS**Chemicals**

Trehalose, methotrexate, ferric tripyridyltriazine (Fe^{III}-TPTZ)

and other chemical grade have been purchased from Sigma Aldrich company (St. Louis Mo, U.S.A.).

Experimental animals

Female Swiss albino mice, weighing 18-22 g were used as experimental animals throughout the study. Mice were purchased from National Cancer Institute, Cairo University, Egypt. The animals were handled at laboratory standard experimental conditions (temperature 23°C ± 2°C, relative humidity 55% ± 5% balanced diet and free access to water) and were let for about one week before experiments to adapt the laboratory conditions. Animals' procedures were consistent with the guidelines of Ethics by Public Health Guide for the Care and Use of Laboratory Animals [4].

Experimental design

Mice were divided into four groups, each group included 15 mice as follows: Group I: (Negative control group) Mice have been injected with normal saline (0.9%w/v, 200µL/mouse intraperitoneally (i.p) for six times day after day. Group II: (Trehalose injected group) Mice have been injected with trehalose (from Sigma-Aldrich Co. USA) (200µg/mouse, 200µL/mouse (i.p) for six times day after day [3]. Group III: (Methotrexate injected group) Mice have been injected with methotrexate (from Sigma-Aldrich Co. USA) (25µg/mouse, 200 µL/mouse (i.p) for six times day after day [3][5]. Group IV: (Trehalose and methotrexate injected group) Mice have been injected with trehalose (200µg/mouse, 200µL/mouse (i.p)) and methotrexate (25µg/mouse, 200µL/mouse (i.p)) for six times day after day.

Sampling

Mice of all groups were euthanized, blood specimens were collected and assayed for biochemical parameters and complete blood count. Accurately part of weighed liver tissues were homogenized in phosphate buffer pH (7.4) and frozen at -20°C till the enzyme activities were determined to indicate the state of the liver of control and injected groups and finally, part of weighed liver tissues were used for histological studies.

Biochemical parameters assays

Parameter assays: AST and ALT were estimated through measuring oxaloacetate and pyruvate produced respectively [3]. ALP was measured as a liberated phenol in the presence of 4-aminoantipyrine and sodium arsenate as a blocking agent and potassium ferricyanide as a color producing complex. The developed color measured at 510nm [3]. Total protein was estimated using Biuret test in which an intense violet-blue complex is formed with copper salts in an alkaline medium [3]. Iodide is included as an antioxidant and bovine serum albumin. The developed color was measured at 595nm. Albumin was estimated in the presence of bromocresol green at a slightly acidic pH, produces a colour change from yellow to green and green to blue, measured at 630 [3]. Enzyme activities were evaluated using end point assay method. GST: the formation of the adduct due to conjugation of GSH with 1-chloro-2,4-dinitrobenzene (CDNB); the absorbance was observed at 340nm [3]. Catalase: 3 mL buffered H₂O₂ was, mixed by the sample was read for 1min at 250nm [3]. MDA was estimated and measured by colorimetric at 530nm [3]. TAC: At low pH, when a ferric tripyridyltriazine [Fe(III)-TPTZ] complex was reduced to the ferrous form (FeII), an intense blue colour with an absorption maximum at 593 nm developed and hence colour formation exhibited the reducing ability of the sample according to El-Magd *et al.* 2017 [3].

Statistical analysis

One-way analysis of variance (ANOVA) was used to assess significant differences among treated groups and control. The Tukey Test was used to compare all groups with each other and showed the significant effect of treatment. The criterion for statistical significance was set at* means $P \leq 0.05$, (Graph Pad Prism Software).

RESULTS AND DISCUSSION

Efforts have been directed to find a suitable natural neoadjuvant drug to increase efficacy of antitumor agents with low cytotoxicity. Our study showed that there is improvement in liver function tests as ALT, AST, ALP enzyme activities, serum albumin, total protein in trehalose and / or methotrexate injected groups compared to control group (Figure 1,2). Results showed that trehalose has no toxic effect on liver function tests which is in agreement with El-Magd *et al.* 2017 [3], who demonstrated that trehalose shows antitumour efficiency and Kang *et al.* 2014 [6], who demonstrated that trehalose shows protective effects in various cells against harmful stimuli such as heat, dehydration, cold, desiccation and oxidation. The protective effects of trehalose has been demonstrated in neurodegenerative diseases, such as

Alzheimer's disease, progressive supranuclear palsy and corticobasalde generation. It has also been showed that methotrexate at low dose has no toxic effect on liver function tests [7].

Our data showed that intraperitoneal administration of trehalose improve total antioxidant capacity level ($\mu\text{mol/g}$ tissue), catalase enzyme activity (mmole/min/mg protein), Glutathione-S transferase (GST) ($\mu\text{mole/min/mg}$ protein) activity and lipid peroxidation products (MDA) (nmol/g tissue) of the liver compared to control group (Figure 3). El-Magd *et al.* 2017 [3], reported the beneficial effects of trehalose on liver by reducing extent of oxidative stress. It was reported that reactive oxygen species (ROS) are probable mediators of cytotoxicity [8].

Administration of trehalose only and trehalose plus methotrexate maintained normal values of hemoglobin but Hb showed significant decrease $P \leq 0.05$ in methotrexate injected group when compared to the normal animals. There is no significant change in Hb of trehalose injected group in comparison to control group and that confirm that trehalose has no cytotoxic effect on naive mice. The hematological parameters as shown in (Table 1) indicate that trehalose may possess protective action on the hematopoietic system without inducing myelotoxicity. For

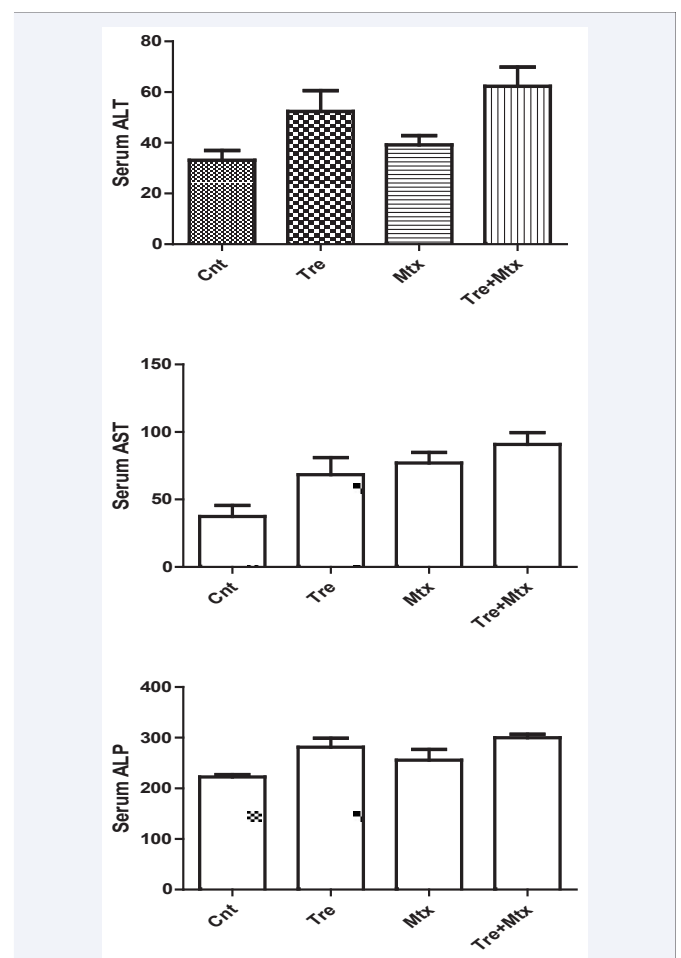


Figure 1 Effect of trehalose and /or methotrexate on serum ALT, AST and ALP in different groups.

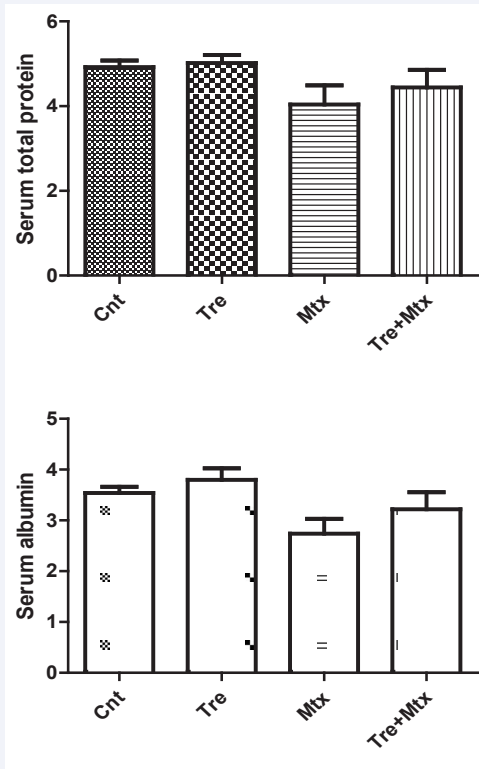


Figure 2 Effect of trehalose and /or methotrexate on serum albumin and total protein in different groups.

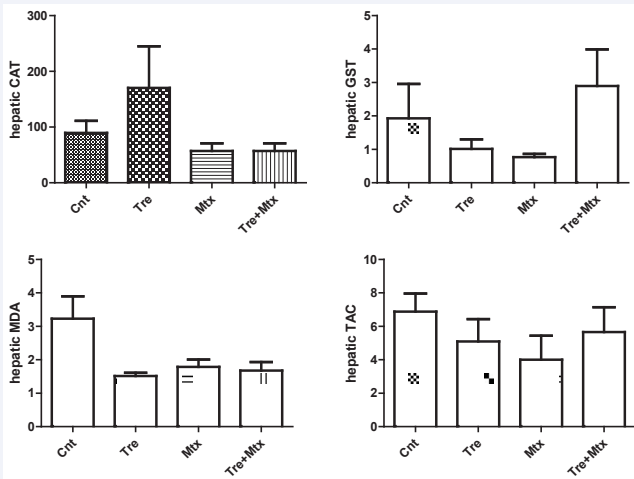


Figure 3 Effect of trehalose and /or methotrexate on liver homogenate antioxidant parameters in different groups.

14 days, trehalose with methotrexate did not exhibit any adverse effect [3,9].

Histopathological examination of mice liver tissues of the different studied groups induced the following: normal (naïve mice) showed normal liver cells radiating from a central vein with normal hepatic cords as shown in (Figure 4). Trehalose injected group showed nearly normal liver with mild congested

vessels as shown in (Figure 5). Methotrexate injected group showed nearly normal liver with mild dilated vessels as shown in (Figure 6). Trehalose plus methotrexate injected group showed nearly normal liver with mild dilated vessels as shown in (Figure

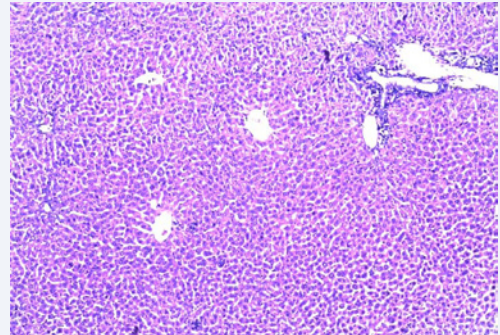


Figure 4 Photomicrographs of mice liver sections stained by H&E show normal hepatocytes, central veins and portal tract in normal mice.

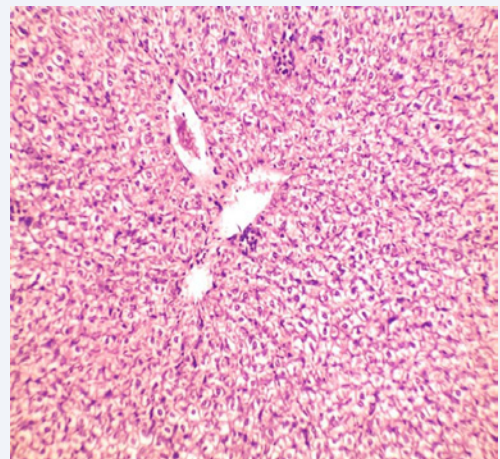


Figure 5 Photomicrographs of mice liver sections stained by H&E show nearly normal liver with mild congested vessels in TRE injected group.

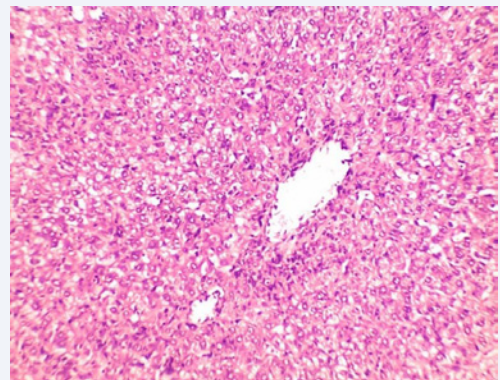


Figure 6 Photomicrographs of mice liver sections stained by H&E show normal liver with mild dilated vessels in methotrexate injected group.

Table 1: Effect of trehalose and /or methotrexate on complete blood picture (CBC) in different groups.

Parameters	Cnt	TRE	MTX	TRE+MTX
Hb g/dl	11.9±0.5	11.35±0.5	8.67±0.8*	8.92±0.98
R.B.C (10 ⁶ /μl)	7.9 ± 0.1	5.5 ± 0.2	6.3 ± 0.3	4.5±0.2
W.B.C (10 ³ / μl)	6.6±1.6	7± 1.1	4.8±0.9	0.3±3.7
Platelets (10 ⁶ / μl)	0.8±0.02	0.7±0.04	0.7 ± 0.01	0.05±0.8
Neutrophils	1± 0.7	3.2±0.24	5±3	4.2±0.6
Lymphocytes	82±1.2	84±1.3	82.7±0.64	83.5±0.64
Monocytes	13±0.9	9.7±0.4	12±0.2	11.7±1.2

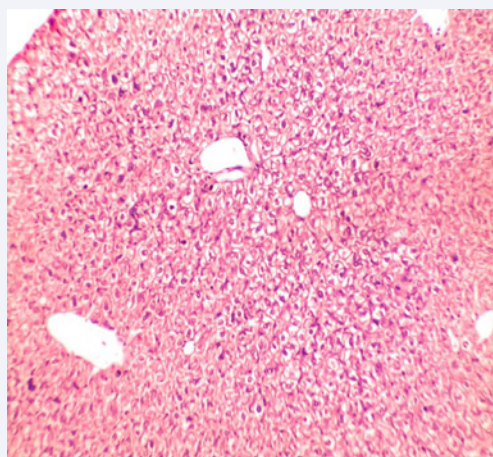


Figure 7 Photomicrographs of mice liver sections stained by H&E show normal liver with mild dilated vessels in TRE+MTX injected group.

7). It is clearly indicated that trehalose may possess protective action on liver tissues.

REFERENCES

- Hartleben B, Wanner N, Huber TB. Autophagy in glomerular health and disease. *Semin Nephrol.* 2014; 34: 42-52.
- Sarkar S, Davies JE, Huang Z, Tunnacliffe A, Rubinsztein DC. Trehalose, a novel mTOR-independent autophagy enhancer, accelerates the clearance of mutant huntingtin and alpha-synuclein. *J Biol Chem.* 2007; 282: 5641-5652.
- El-Magd MA, Khamis A, Nasr Eldeen SK, Ibrahim WM, Salama AF. Trehalose enhances the antitumor potential of methotrexate against mice bearing Ehrlich ascites carcinoma. *Biomed Pharmacother.* 2017; 92: 870-878.
- National Research Council. *Guide for the Care and Use of Laboratory Animals.* 8th edn. Washington: The National Academies Press. USA.
- Ali MM, Hassan SA. Role of Some Newly Synthesized Tetrahydronaphthalenthiazol Derivatives as Anticancer Compounds. *International J Cancer Res.* 2007; 3: 103-110.
- Kang YL, Saleem MA, Chan KW, Yung BY, Law HK. Trehalose, an mtor independent autophagy inducer, alleviates human podocyte injury after puromycin aminonucleoside treatment. *Plos one.* 2014; 9: 113-520.
- Itai Shingo, Yukio Suga, Yusuke Hara, Kouji Izumi, Yuji Maeda, Yasuhide Kitagawa, et al. Co-administration of dexamethasone increases severity and accelerates onset day of neutropenia in bladder cancer patients on methotrexate, vinblastine, adriamycin and cisplatin chemotherapy: a retrospective cohort study. *J Pharm Health Care Sci.* 2017; 3: 3.
- Tong L, Chuang CC, Wu S, Zuo L. Reactive oxygen species in redox cancer therapy. *Cancer Lett.* 2015; 367: 18-25.
- Sreelatha S, Padma PR, Umasankari E. Evaluation of anticancer activity of ethanol extract of *Sesbania grandiflora* (Agati Sesban) against Ehrlich ascites carcinoma in Swiss albino mice. *J Ethnopharmacol.* 2011; 134: 984-987.

Cite this article

Khamis A, El-Magd MA, Nasr Eldeen SK, Ibrahim WM, Salama AF (2017) Effect of Trehalose and/or Methotrexate on Swiss Albino Mice. *J Vet Med Res* 4(9): 1110.