

Review Article

An Intraoral Approach for Mandibular Alveolar Nerve Block in Cattle: Cadaveric Study

Mohamed A Nazih^{1*} and Mohamed W El-Sherif²¹Department of Anatomy, Assiut University, Egypt²Department of Surgery, Assiut University, Egypt

*Corresponding author

Mohamed W El-Sherif, Department of Surgery, Faculty of Veterinary Medicine, New Valley branch, Assiut University, 72511, Al-Kharga, Egypt, Email: drmw1@hotmail.com

Submitted: 25 January 2018

Accepted: 20 February 2018

Published: 21 February 2018

ISSN: 2378-931X

Copyright

© 2018 Nazih et al.

OPEN ACCESS

Abstract

The mandibular alveolar nerve at the point of entry at the mandibular foremen was anatomically determined in bovine in order to reach and desensitize the nerve via the oral cavity. The Mandibular nerve provides sensation to the check teeth, tongue and mandible. Desensitization of the mandibular alveolar nerve enables surgeons to perform procedures effectively and safely in these structures. Extra and intraoral approaches of the mandibular alveolar nerve block are well recognized in human and horses. An intraoral approach to the mandibular alveolar nerve in bovine was presented in the present study based on the anatomical findings. It is hypothesized that the approach was reliable, applicable and safer than the extraoral method.

Keywords

- Intraoral
- Nerve block
- Mandibular
- Alveolar
- Cattle

INTRODUCTION

Many surgical oral diseases can interfere with cattle's prehension of food; Mandibular fracture, dental injuries and decay (periodontal or endodontal diseases), lingual and buccal membrane wounds as well as lacerations are examples of such cases [1], that require surgical intervention under the effect of anesthesia. Although general anesthesia is a choice for surgical intervention in cattle, there are some risks with its use. Many surgical procedures can be performed humanely and safely in cattle by using a combination of physical restraint, sedation, and local or regional anesthesia. Local or regional anesthesia is effective, safe and is still the most desirable and applicable procedure in many situations [2]. Benefits of effective nerve blocks include owner compliance for invasive surgery, ease of administration, minimal equipment requirements, low cost, and reduced incidence of complications [3].

The mandibular region in cattle is anatomically unique; the parotid salivary glands are located ventral to the ear and extended along the caudal border of the mandible. The mandibular glands are centered on the angle of the mandible [3]. The mandibular nerve is sensory to the teeth, oral mucosa, and skin of the lower jaw, as well as the tongue, parotid gland, and part of the ear [4]. Mandibular nerve is commonly blocked to perform surgeries at this region in horses, dogs and cats [5-10].

The intraoral approach for inferior alveolar nerve desensitization has been used in human, dogs and horse [11,12,10]. It has been found in horse that injecting the local anaesthetic rostral to the mandibular foramen resulted in adequate desensitization of the inferior alveolar nerve with minimal complications.

The objectives of this study were to determine average measurements of the location of the mandibular foramen on adult cattle skulls and to demonstrate that an alveolar mandibular nerve block can be performed intraorally on five cadaver heads.

MATERIALS AND METHODS**Anatomical study**

Twenty adult cattle skulls and five fresh heads obtained from slaughter house were examined to document the approximate location of the mandibular foramen. Measurements include the mandibular foramen to the rostral border of the ramus of the mandible and mandibular foramen to the pterygomandibular fold as well as the distance from the mouth commissure to the pterygomandibular fold (Figure 1). All measurements were tabulated and mean value will be estimated by using of Vernier caliper (0-150mm) and documented in Table 1.

Surgical anatomy of structures of the mandibular region was demonstrated according to [4] in bovine.

Intraoral mandibular alveolar nerve block

The landmark measurements were used as a guide to introduce a tool designed to reach the mandibular foremen effectively. The tool designed for intraoral mandibular alveolar nerve block with 20 cm Allis tissue forceps, 6 cm, 16-gauge needle with Luerlock hub on an extension set with syringe attached (Figure 2).

The mouth is opened with mouth gage, the tongue is grasped and fixed on the other side of the mouth, the needle is advanced caudally and inserted into the pterygomandibular

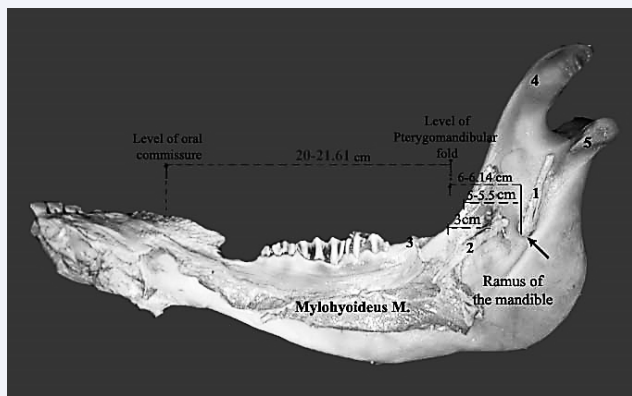


Figure 1 Showing the medial aspect of the right mandibular ramus. 1- Mandibular alveolar nerve 2- Lingual branch of mandibular nerve 3- pterygomandibular fold (cut).

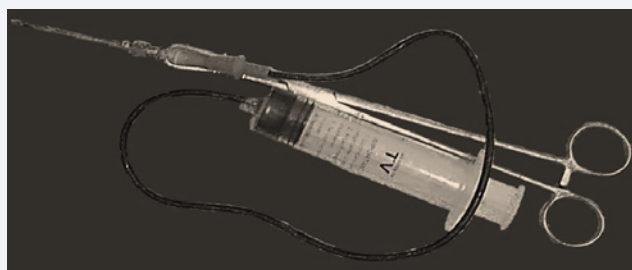


Figure 2 A tool designed for intraoral mandibular alveolar nerve block.

Table 1: Morphometric measurements of the bovine mandible.

Morphometric parameter	Mean + SD
1- Mandibular foramen to cranial border of mandible	5±55
2- Mandibular foremen to the pterygomandibular fold	6±14
3- Distance of mouth commissure to the pterygomandibular fold	20±61

fold immediately below the hard palate. The 6-cm length needle is advanced totally. Five ml methylene blue dye is injected. The mandibular alveolar nerve at the other side is blocked at same manner (Figure 3).

Evaluation and assessment

Infiltration of 5 ml of methylene blue on each side was performed. Dissection was performed to distinguish the area infiltrated and to evaluate if the nerve is included. Evaluation and assessment process is performed according to [13] and [14].

RESULTS

Anatomical findings

The mandibular alveolar nerve passes commonly with the lingual one of the mandibular nerve within an adipose sheath. In the pterygoid region, the inferior alveolar nerve which known by the mandibular alveolar nerve descends rostro ventral and laterally to insinuate in between the pterygoideus lateralis muscle (dorsolateral) and the pterygoideus medialis

muscle (ventromedial). The nerve emerges on the lateral face of the pterygoideus medialis muscle where it detaches the mylohyoideus nerve which proceeds rostroventrally on the lateral aspect of the latter muscle then, it extends ventrally to innervate both the mylohyoideus muscle and the rostral belly of digastricus muscle. The mandibular alveolar nerve inclines toward the medial aspect of the ramus of the mandible to enter the mandibular foramen (Figure 4). The latter is located about 6-6.5 cm from the pterygomandibular fold with the same level of the hard palate. At the point of entrance of the inferior alveolar nerve between the pterygoideus lateralis and medialis muscle, the lingual nerve detaches out with an acute angle and passes rostrally caudal to the pterygomandibular fold by about 2.5-3 cm. where it crosses the rostral border of the pterygoideus medialis muscle in a rostroventral direction, then it inclines ventrally to the styloglossus muscle and sublingual salivary gland.

Assessment of the intraoral mandibular alveolar nerve block approach

The insertion of the needle to distinguish the landmarks was

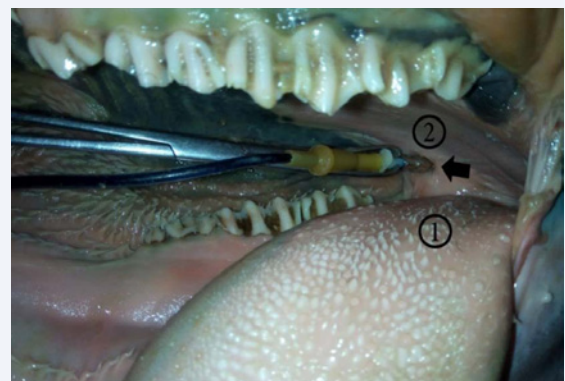


Figure 3 Intraoral mandibular alveolar nerve block. 1- base of the tongue, 2- hard palate, the black arrow indicates the injection site at the pterygomandibular fold.

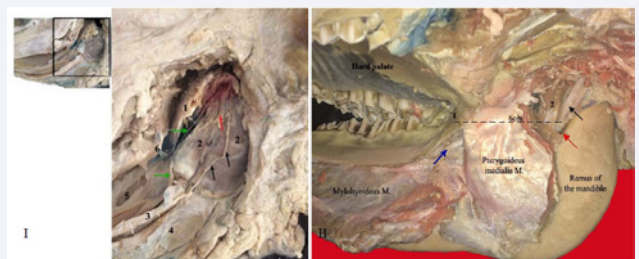


Figure 4 I. Showing the deep dissection of the head (left side) after removing the ramus of the mandible. 1- Pterygoideus lateralis M. 2- Pterygoideus medialis M. 3- Mylohyoideus M. 4- Rostral belly of digastricus M. 5- Styloglossus M. 6- Pterygomandibular fold. The black arrows indicate the mylohyoid nerve. The green arrows indicate the lingual nerve of mandibular N. The red arrow indicates the mandibular alveolar nerve. II. Showing the medial aspect of the right mandibular ramus. 1- Pterygomandibular fold 2- Pterygoideus lateralis M. The black arrow indicates the mandibular alveolar nerve. The red arrow indicates the mandibular foramen, the blue arrow indicates the lingual of mandibular nerve.

easily applied. Dissection of the medial aspect of the mandible revealed infiltration of the methylene blue dye 2 cm area around the mandibular alveolar nerve trunk at its emergence at the mandibular foramen (Figure 5).

DISCUSSION

The anatomical study in the recently intended work, described the course of the mandibular alveolar nerve with its related nerves and muscles as well as the anatomical location of the mandibular foramen from the rostral border of the ramus of the mandible. These findings were nearly achieved by [10], in horse. In this aspect, our present investigation represented the results in both cadaveric and bony states and according to the anatomical findings, the measurements of the mandibular foramen were done from the rostral border of the mandible. The results under discussion achieved that intended the intraoral mandibular nerve block the method of choice rather than the extraoral one. This statement was not recorded and denied by the available literatures. On the other hand [15], in bovine and [16], in kuri cattle focused on the landmarks of the foramen from the caudal, basal and angle of the mandible in the bony state only. Accordingly, they prepared these studies for the extraoral method for the mandibular nerve block.

Regarding the critical anatomical structures in the parotid region in our work which represented in the massive parotid and mandibular salivary glands, parotid lymph node and the great blood vessels (common carotid artery and maxillary vein), the administration of the mandibular nerve block safely indicated intraorally. That was similarly done by [8-10] and [17] in horse.

The recently performed dissection declared out that the mandibular alveolar nerve arose at the same level of the hard palate. It was caudally situated by 6-6.5cm from the pterygomandibular fold, accordingly, the introduced needle should be inserted just ventral to the hard palate in the fold with a caudal direction for about 6- 6.5cm in depth. These results were not correlated with [10], in horse which intended the injection site caudal to the last molar teeth in the pterygomandibular fold.

The results applied in our observations recorded the anatomical course of the lingual branch of the mandibular nerve of cattle, it ran ventrally on the rostral border of the pterygoideus medialis muscle and 2.5-3cm caudally to the pterygomandibular fold. This finding pointed out that for the lingual nerve block, the needle should be inserted mildly deep for about 2.5-3cm in the fold. A result which was not pointed out by any of the available literatures.

The conventional approach to desensitize the inferior alveolar nerve in equine described by [8]. A 130-150 mm long needle is introduced at the medial aspect of the ventral margin of the ramus of the mandible, at the level of the rostral insertion of the masseter muscle. The needle is advanced along the medial side of the ramus to an intersection point of a horizontal line drawn along the buccal occlusal surface of the maxillary cheek teeth and a vertical line drawn from the rostral insertion of the masseter muscle to the lateral canthus of the eye [6], described an alternative approach where the needle is inserted from the caudal aspect of the ramus of the mandible. [10] presented an intra oral approach. The needle is introduced just distal and caudal to the third molar tooth of the quadrant to be anaesthetized.

In concern with the mandibular alveolar nerve block associated with difficulty in assuring that the anaesthetic solution is deposited close to the mandibular foramen, risks of inadvertent damage of structures when performing this block and iatrogenic lingual trauma from inadvertent desensitization of the lingual nerve [10].

The results which demonstrated on the mandibular alveolar nerve block from an extraoral approach were documented for surgical procedures of the mandible in the horse [8,18] and [9]. Intraoral approach of mandibular alveolar nerve block was clinically applied in horses [10]. Successful block and minimal complications were reported as main results of the study. The present study shows successful approach of the mandibular alveolar nerve. Anatomical variations between horse and cattle presented in large continuous salivary glands at the caudal aspect of the mandible and mandibular angle makes the extraoral approach more tissue destructive. Also, anatomical location of the linguofacial vessels caudal to the mandibular alveolar nerve makes the intraoral approach more appropriate and less invasive than the extraoral technique.

The methylene blue dye infiltration demonstrated that the intraoral approach to the mandibular alveolar nerve block allowed an accurate placement of the local anaesthetic at the mandibular foramen. The needle placement at the mandibular foramen was easily performed and the distribution of the local anesthetic adequately infiltrated the area of the mandibular alveolar nerve. The volume of local anesthetic injected (5 ml) that represented by the methylene blue dye adequately covered 2 cm wide area around the mandibular alveolar nerve. The reliability and efficacy of the block should be confirmed by the submission of the approach to clinical cases.

An intra-operative complication includes trauma of the lingual branch or the mandibular alveolar nerves. This is a concern with both the extra and intraoral approaches. The needle used in the present study (Sprotte type) decreases the incidence of nerve trauma and makes distribution of the local anesthetic more

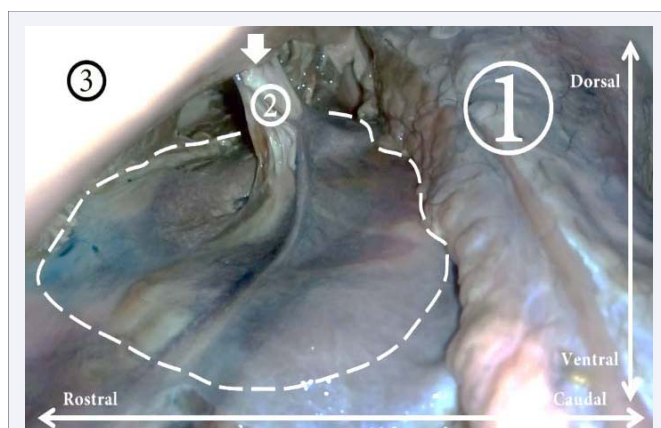


Figure 5 Evaluation of intraoral mandibular alveolar nerve block. 1- parotid salivary glands, 2- mandibular alveolar nerve, 3- ventral border of the mandible, the white arrow indicates the mandibular foramen, the white dotted area stained with methylene blue dye is the desensitized area.

appropriate. Sprotte type needle is used for spinal anesthesia and advised for its minimal dura trauma incidence [19,20].

CONCLUSION

The intraoral mandibular alveolar nerve block approach is based on a good understanding of bovine head anatomy. To our knowledge, this is the first report presents this approach in cattle. tools required are 6 cm Sprotte type needle with an extension PVC tube and a delivery syringe and fitted on Allis tissue forceps that allows the operator to manipulate the needle securely in the oral cavity. The needle is introduced just distal to the hard palate and caudal to the last molar tooth on both sides, on the medial surface of the ramus of the mandible, theoretically, allowing infiltration of the local anesthetic (represented by methylene blue dye) directly over the mandibular alveolar nerve at its entrance to the mandibular foramen. Further studies should be performed to evaluate the reliability, efficacy and safety of the current technique.

REFERENCES

1. Ducharme GN. Surgical diseases of the oral cavity. Susan Fubini, Ducharme Norm G., 1st ed. Farm animal surgery. USA: Saunders. 2004.
2. Edmondson MA. Local and Regional Anesthesia in Cattle. Vet Clin North Am Food Anim Pract. 2008; 24: 211-226.
3. Ivany MJ, Muir WW. Farm animal anesthesia. Susan F, Ducharme GN. 1st ed. Farm animal surgery. USA: Saunders. 2004.
4. Budras K, Habel RE, Wünsche A, Buda S. Bovine anatomy: an illustrated text. 1st edn. Germany: Schlütersche. 2003.
5. Lantz GC. Regional Anesthesia for Dentistry and Oral Surgery. J Vet Dent. 2003; 20: 181-186.
6. Fletcher BW. How to Perform Effective Equine Dental Nerve Blocks. Am Ass of Equine Practnrs. 2004; 50: 233-236.
7. Dixon PM, Dacre I, Dacre K, Tremaine WH, McCann J, Barakzai S. Standing oral extraction of cheek teeth in 100 horses (1998--2003). Equine Vet J. 2005; 37: 105-112.
8. Tremaine WH. Local analgesic techniques for the equine head. Equine Vet Educ. 2007; 19: 495-503.
9. Lowder MQ. Equine dental nerve blocks. Equine Vet Educ. 2012; 24: 124-125.
10. Henry T, Pusterla N, Guedes AG, Verstraete FJ. Evaluation and clinical use of an intraoral inferior alveolar nerve block in the horse. Equine Vet J. 2014; 46: 706-710.
11. Yagiela JA. Anesthesia and pain management. Emerg Med Clin N Am. 2000; 18: 449-470.
12. O' Morrow C. Advanced dental local nerve block anesthesia. Can Vet J. 2010; 51: 1411-1415.
13. Campoy L, Martin-Flores M, Looney AL, Erb HN, Ludders JW, Stewart JE, et al. Distribution of a lidocaine-methylene blue solution staining in brachial plexus, lumbar plexus and sciatic nerve blocks in the dog. Vet Anaesth Analg. 2008; 35: 348-354.
14. El-Khamary A, Nazih M, El-Sherif M, Senosy W. Ultrasound-Guided Pudendal Nerve Block in Male Donkeys. J Vet Med Res. 2017; 4: 1103.
15. Allouch GM. Applied anatomy on the maxilla and mandibular regions of the bovine with special reference to its important in regional anesthesia. Int J Food, Agriculture and Veterinary Sciences. 2014; 4: 58-64.
16. Gambo BG, Yahaya A, Girgiri I, Olopade JO. Morphometric studies of the mandibular and maxillofacial regions of the kuri cattle and implications in regional anesthesia. Folia Morphol (Warsz). 2015; 74: 183-187.
17. Rice MK. Regional nerve block blocks for equine dentistry. J Vet Dent. 2017; 34: 106-109.
18. Harding PG, Smith RL, Barakzai SZ. Comparison of two approaches to performing an inferior alveolar nerve block in the horse. Aust Vet J. 2012; 90: 146-150.
19. Turnbull DK, Shepherd DB. Post-dural puncture headache: pathogenesis, prevention and treatment. Br J Anaesth. 2003; 91: 718-729.
20. Caldwell FJ, Easley KJ. Self-inflicted lingual trauma secondary to inferior alveolar nerve block in 3 horses. Equine Vet Educ. 2012; 24: 119-123.

Cite this article

Nazih MA, El-Sherif MW (2018) An Intraoral Approach for Mandibular Alveolar Nerve Block in Cattle: Cadaveric Study. J Vet Med Res 5(3): 1126.