

## Case Report

# Surgical Management of Large Abdominal Hernia in a Male Goat

Tuli Dey<sup>1\*</sup>, Bibek Chandra Sutradhar<sup>1</sup>, Bhajan Chandra Das<sup>1</sup>, and Sonnet Poddar<sup>2</sup>

<sup>1</sup>Department of Medicine and Surgery, Chittagong Veterinary and Animal Sciences University, Bangladesh

<sup>2</sup>Department of Anatomy and Histology, Chittagong Veterinary and Animal Sciences University, Bangladesh

**\*Corresponding author**

Tuli Dey, Department of Medicine and Surgery, Chittagong Veterinary and Animal Sciences University, Khulshi, Chittagong-4225, Bangladesh, Tel: 8801849210104; Email: shantacvasu@gmail.com

Submitted: 14 February 2018

Accepted: 31 March 2018

Published: 02 April 2018

ISSN: 2378-931X

**Copyright**

© 2018 Dey et al.

OPEN ACCESS

**Keywords**

• Abdominal hernia; Hernial ring; Herniorrhaphy

**Abstract**

The study was planned to perform surgical management of large abdominal hernia in a male goat. An intact 3 months old local male goat was presented at SAQTVH, CVASU with complaint of swelling at ventral abdomen immediately after umbilicus near prepuccial area. The swelling was noticed by owner before one month which was gradually increased in size. The swelling was firm, non-painful and reducible on palpation, with a large hernial ring measuring about >6 cm in width. After routine blood examination, surgical site was aseptically prepared and patient was stabilized with fluid therapy to maintain operative fluid loss. Under sedation and local anaesthesia, an elliptical incision was performed at hernia site to avoid prepuccial opening. Abdominal content was separated from overlying muscles and fascia and mild adhesion of abdominal content was excluded by blunt dissections. After reducing abdominal content with gentle pressure, herniorrhaphy was performed by using sterilized silk with a horizontal mattress pattern between hernia ring and abdominal wall. Proper post-operative care with antibiotic and analgesic therapy was maintained for next five days and complete recovery with proper healing was found after 10 days of operation without any complications.

**ABBREVIATIONS**

SAQTVH: Shahedul Alam Quadery Teaching Veterinary Hospital; CVASU: Chittagong Veterinary and Animal Sciences University

**INTRODUCTION**

Ventral abdominal hernia is one of the most important developmental or accidental defects seen in goat and is a subject of concern for people where goat rearing is largely practiced. It is more common in calves, foals and pigs, but less common in goat and sheep [1]. It occurs due to weak muscles of ventral abdomen and also due to any trauma at ventral abdomen in goat which results in protrusion of abdominal contents into over lying subcutis [2]. Abdominal content in direct contact with skin stimulate formation of adhesions that can interfere with normal digestion if it is not corrected at appropriate time. The size of hernia varies depending on the extent of the hernial defect and the amount of abdominal contents contained within it. Abdominal hernia is less frequent than other hernias in goat [3]. The only effective treatment for abdominal hernia is surgery to restore integrity of the abdominal wall and prevent incarceration and strangulation of herniated contents [4]. Application of bandage, clamps, or ligatures may be helpful in a few cases where the hernial ring is small [1]. Herniorrhaphy is useful in case of large hernial opening but in extensive ventral abdominal hernia may require hernioplasty [5,1]. Herniorrhaphy is the method of correction of hernia by using strong suture materials

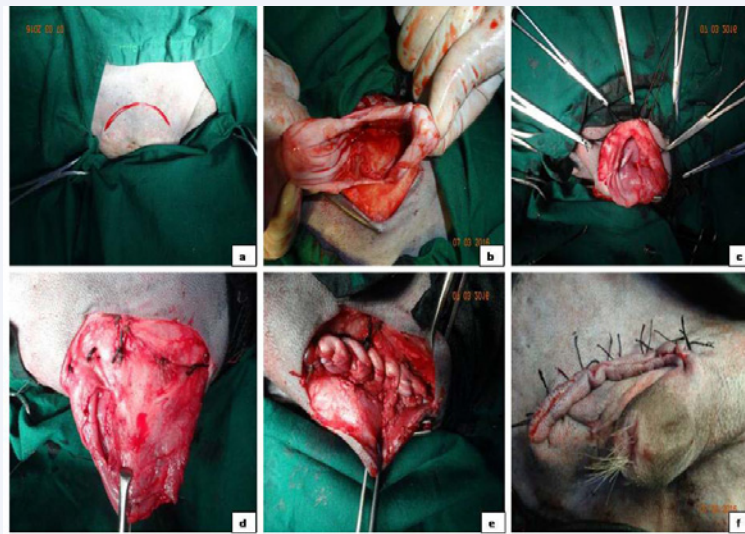
to strengthen the suture and not to recurrence of hernia. In the present study, through an elliptical incision, sterilized silk was used for correction of ventral abdominal hernia of male goat and successful result was found after ten days post-operative care.

**MATERIALS AND METHODS****Case history and observations**

An intact three-months-old local male goat was brought to the Shahedul Alam Quadery Teaching Veterinary Hospital (SAQTVH), Chittagong Veterinary and Animal Sciences University, Khulshi (CVASU), Chittagong, Bangladesh with a large swelling in ventral abdomen just after umbilicus and near to the prepuccial region. Anamnesis suggested that the goat lost its appetite and swelling at ventral abdomen was increasing with its age since one month. Clinical examination revealed the hernial content firm, non-painful and reducible within the hernial ring. The ring was >6 cm in width. Clinical parameters like heart rate, respiratory rate and rectal temperature were within the normal physiological limits. The presented case was diagnosed as ventral abdominal hernia and suggested for surgery to correct the condition.

**Surgical correction and treatment**

The surgical management of ventral abdominal hernia of goat was followed by a standard procedure of [1,3,7]. Before operation of abdominal hernia, routine blood examination was performed and patient was prepared aseptically. The animal was positioned dorso-ventrally and stabilized with 0.9% Sodium



**Figure 1** Surgical Procedure of Large Abdominal Hernia.

A: An elliptical incision on hernial sac, B: Abdominal content through incision site, C: Each single stitch held by hemostat, D: Herniorrhaphy in hernial ring, E: Suture after excluding excess part F: Skin suture with horizontal mattress.

Chloride intravenously. The goat was sedated with diazepam intravenously with a dose rate of 0.5 mg/kg body weight. Local Anaesthesia at surgical site was performed by 2% lidocaine hydrochloride as the dose rate 1 ml/cm area. Proper care was taken to avoid further infection of the prepuceal region. An elliptical incision was performed above the hernial sac to avoid the prepuceal opening (Figure 1A). After skin and subcutaneous tissue dissection, the condition of the hernial sac and ring was examined carefully to confirm the presence or absence of adhesions of the abdominal organs and the identified adhesions were excluded by blunt dissections. The herniated viscera were repositioned in the abdominal cavity by manual taxis (Figure 1B). Then herniorrhaphy was achieved by using sterilized silk as horizontal mattress pattern between the hernia ring and abdominal wall (Figure 1D). Single stitches were preset and held with artery forceps (Figure 1C). Once all of the single sutures were positioned, then they were tied. Excess part of the sac was removed and the muscles and subcutaneous tissue were routinely sutured with catgut (size 2-0). During subcutaneous suturing, proper care was taken to avoid the formation of dead space and the skin was appositioned with horizontal mattress suture using silk (Figure 1E,F). In the post-operative period, an antibiotic named step to penicillin was administered intramuscularly for five days and analgesic ketoprofen intramuscularly was administered for three days. The healing process was clinically evaluated and the surgical wound was completely healed after 10 days of operation.

## RESULTS AND DISCUSSION

Ventral abdominal hernia was seen in the ventral abdominal site near the prepuceal region, this similar finding was found in the study of [3,4]. Due to its location near the prepuce, correction of this type hernia was really difficult. Abdominal hernia was successfully reduced in the presented case. The exact cause of the present case study could not be revealed, it might be due to weakening of the abdominal muscles or violent trauma with blunt

object. These findings were supported by the findings of [1,7,8]. In the presented case, the hernia ring was >6 cm in width and that type of hernia was corrected by using a horizontal mattress pattern and absorbable sutures. This similar finding was described by [8]; where hernial ring size was measuring >3 cm and special precaution was taken at the time of suturing. In the presented case, there were no complications except mild adhesions which was corrected manually and by using blunt dissections. But in the study of [1], complications like adhesions and hydrocele of hernial sac, incarceration and torsions were found and in the study of [3], abscess was found. Herniorrhaphy was commonly used in case of medium to large sized hernia ring and in case of very large hernia ring hernioplasty was more effective. These were described by the study of [8]. In presented case, sterilized silk was used to suture hernial ring and abdominal wall and the excess part was removed to avoid further complication and proper healing. Herniorrhaphy attempted in this case proved successful and the animal recovered uneventfully without any complications at 10th day post-surgery.

## CONCLUSION

Ventral abdominal hernia is uncommon and in possible cases it requires special and careful consideration during surgery. Herniorrhaphy with sterilized silk has improved the effectiveness of operation and post-surgery clinical evaluation revealed complete recovery of this goat. So, this surgical procedure should be recommended for effective management of large abdominal hernia of goat.

## ACKNOWLEDGEMENTS

The author sincerely desires to express her deepest sense of gratitude to Prof. Dr. Bibek Chandra Sutradhar and Prof. Dr. Bhajan Chandra Das, Department of Medicine and Surgery, Chittagong Veterinary and Animal Sciences University, Chittagong, Bangladesh for their guidance at the time of surgery.

## REFERENCES

1. Villar JM, Corbera JA, Spinella G. Double- layer mesh hernioplasty for repairing umbilical hernias in 10 goats. *Turk J Vet Anim Sci.* 2011; 35: 131-135.
2. Monsang SW, Pal SK, Kumar M, Roy J. Surgical Management of Concurrent Umbilical Hernia and Intestinal Fecolith in a white Yorkshire Piglet, Case Report. *Res J Vet Pract.* 2014; 2: 67-69.
3. Jettennavar PS, Kalmath GP, Anilkumar MC. Ventral Abdominal Hernia in a Goat. *Veterinary World.* 2010; 3: 93.
4. Jahromi AR, Nazhvan SD, Gandmani MJ, Mehrshad S. Concurrent bilateral inguinal and umbilical hernias in a bitch Concurrent bilateral inguinal and umbilical hernias in a bitch - a case report. *Veterinarski Arhiv.* 2009; 79: 517-522.
5. Das BC, Nath BK, Pallab MS, Mannan A, Biswas D. Successful management of ventral abdominal hernia in goat: case report. *Int J Nat Sci.* 2012; 2: 60-62.
6. Kumar V, Mathew DD, Ahmad RA, Hoque M, Saxena AC, Pathak R. Sterilized Nylon Mosquito Net For Reconstruction Of Umbilical Hernia In Buffaloes. *Buffalo Bulletin.* 2014; 33: 8-12.
7. Vijayanand V, Gokulakrishnan M, Rajasundaram RC, Thirunavukkarasu PS. Ventral Hernia [Hysterocele- Gravid] In a Goat- A Case Report. *Indian Journal of Animal Research.* 2009; 43: 148-150.
8. Vebclauskas L, Silanskaite J, Kiudelis M. Umbilical hernia indicative of recurrence. *Medicina (Kaunas).* 2008; 44: 855-859.

## Cite this article

Dey T, Sutradhar BC, Das BC, Poddar S (2018) Surgical Management of Large Abdominal Hernia in a Male Goat. *J Vet Med Res* 5(3): 1128.